

Comparison of postoperative analgesia with two different doses of dexmedetomidine as an adjuvant to ropivacaine in adductor canal block for unilateral total knee replacement surgery: A randomized double-blinded study

Naveen M. Karthik, S. Gokul Das, Jasmin Johney, Mathew George, Eldo Issac, Anu Vasudevan¹

Departments of Anaesthesiology and Critical Care Medicine, ¹Biostatistics, Amrita Institute of Medical Sciences and Research Centre, Cochin, Kerala, India

Abstract

Background and Aims: Multimodal analgesia is used to treat severe postoperative pain (POP) in total knee replacement (TKR) surgery. Adjuvants are used with local anesthetics to improve the quality and duration of pain relief. Studies comparing different doses of dexmedetomidine in adductor canal block (ACB) are sparse to date. This study compares postoperative analgesia with two different doses of dexmedetomidine as an adjuvant to 0.2% ropivacaine in ACB for unilateral TKR.

Material and Methods: In this prospective, randomized, double-blinded comparative study, sixty patients were divided into two groups: A and B. Postoperatively perineural catheter was inserted and all patients received 0.2% ropivacaine 20 mL bolus followed by an infusion of 0.2% ropivacaine with dexmedetomidine (0.5 µg/Kg in Group A and 1 µg/Kg in Group B) at 8 mL/h. Postoperative pain, motor blockade, rescue analgesia, hemodynamic parameters, sedation, and adverse effects were recorded. Student t, Chi-square, and Mann–Whitney tests were used.

Results: Most patients were elderly females (M:15, F:45). Postoperatively, from 2nd to 24th hour, pain score was less in Group B ($P < 0.05$). The requirement of rescue analgesic was also less in Group B (A:B 330 µg:60 µg; 23%:6%). Motor blockade assessed using modified Bromage scale and sedation using Richmond agitation sedation scale did not show any statistical difference.

Conclusion: Dexmedetomidine infusion at 1 µg/Kg is a better adjuvant to 0.2% ropivacaine than 0.5 µg/Kg in ACB. It provides better analgesia without producing sedation, motor blockade, hemodynamic changes, or any adverse effects.

Keywords: Adductor canal block, dexmedetomidine, postoperative analgesia, ropivacaine, total knee replacement surgery

Introduction

Pain is defined as “an unpleasant sensory and emotional experience associated with actual or potential tissue damage or described in terms of such damage.”^[1] Total knee replacement

(TKR) surgery is associated with severe postoperative pain which results in immobilization, deep vein thrombosis, cardiac ischemia, delayed recovery and rehabilitation, prolonged hospital stay, and financial burden to the patient.^[2] Hence, multimodal analgesia is preferred to effectively treat postoperative pain. Peripheral nerve blocks are used recently to minimize postoperative pain (POP) and improve the functional status.

Address for correspondence: Dr. S. Gokul Das, Department of Anaesthesiology and Critical Care Medicine, Amrita Institute of Medical Science and Research Centre, Cochin - 682 041, Kerala, India.

Postal address: Anantham, Chendamangalam Road, North Paravur - 683 513, Ernakulam District, Kerala, India.
E-mail: gokuldas75@hotmail.com

This is an open access journal, and articles are distributed under the terms of the Creative Commons Attribution-NonCommercial-ShareAlike 4.0 License, which allows others to remix, tweak, and build upon the work non-commercially, as long as appropriate credit is given and the new creations are licensed under the identical terms.

For reprints contact: WKHLRPMedknow_reprints@wolterskluwer.com

Access this article online	
Quick Response Code:	Website: https://journals.lww.com/joacp
	DOI: 10.4103/joacp.JOACP_493_20

How to cite this article: Karthik NM, Das SG, Johney J, George M, Issac E, Vasudevan A. Comparison of postoperative analgesia with two different doses of dexmedetomidine as an adjuvant to ropivacaine in adductor canal block for unilateral total knee replacement surgery: A randomized double-blinded study. *J Anaesthesiol Clin Pharmacol* 2022;38:428-33.

Submitted: 22-Dec-2020

Revised: 14-Apr-2021

Accepted: 22-Apr-2021

Published: 12-Jan-2022

Femoral nerve block (FNB), commonly performed for pain relief in TKR,^[3] causes weakness of quadriceps muscles limiting early ambulation and increasing the risk of fall.^[4,5] Adductor canal block (ACB) is a novel regional block for TKR having predominantly sensory with minimal motor block.^[6] Adductor canal, also called Hunter's canal, is a conical Musculo-aponeurotic tunnel situated in the mid thigh extending from the apex of femoral triangle to the hiatus magnus.

Adductor canal contains multiple afferent sensory nerves (saphenous, medial femoral cutaneous, medial reticular, and the articular branch of obturator nerve) but only a single efferent motor nerve (nerve to vastus medialis).^[7]

Studies comparing the postoperative analgesia with two different doses of dexmedetomidine as an adjuvant to local anesthetic agents in ACB are sparse to date. Against this background, we compared the efficacy of a higher dose of dexmedetomidine (0.5 $\mu\text{g}/\text{kg}$ and 1 $\mu\text{g}/\text{kg}$) as an adjuvant to 0.2% ropivacaine in ACB for better postoperative pain score without causing any sedation, hemodynamic instability, or adverse effects.

Ropivacaine is a long-acting amide local anesthetic agent with less cardiotoxic effect compared to bupivacaine.^[8] Adjuvants are added to local anesthetic agents to improve the quality and duration of pain relief. Dexmedetomidine, a selective α_2 -adrenoceptor agonist, has sedative, analgesic, and anesthetic properties and has been used as an adjuvant to local anesthetic agents for peripheral nerve blocks.^[9] Due to its sympatholytic action, it produces dose-dependent decrease in blood pressure, heart rate, and cardiac output.

The primary objective of the study was to compare the analgesic efficacy of dexmedetomidine 0.5 $\mu\text{g}/\text{kg}$ versus 1 $\mu\text{g}/\text{kg}$ as an adjuvant to 0.2% ropivacaine in ACB in patients undergoing unilateral TKR surgery. The secondary objective was to compare motor blockade, requirement of rescue analgesics, hemodynamic variables, sedation, and any adverse events during the first 24 hours after surgery.

Material and Methods

The study was conducted at a tertiary care center after obtaining approval from the Institutional Ethics Committee (IEC-AIMS-2019-ANES-043) and registering at the Clinical Trial Registry of India (CTRI/2019/05/019307) during the period from July 2018 to April 2020. A prospective randomized double-blinded comparative study design was adopted.

Sixty consenting patients in the age group of 18–85 years belonging to the ASA PS I, II, and III were included in the

study. Patients who were ASA PS IV, allergic to the study drug, on treatment with beta-blockers, and who underwent robotic or revision TKR were excluded from the study. Patients having contraindication to subarachnoid block, infection at the site for ACB, and known neuropathies were also excluded from the study.

At the end of the surgery, under aseptic precaution and using ultrasound guidance, adductor canal block was administered with 20 mL of 0.2% ropivacaine. A perineural catheter was then inserted and placed anterolateral to the femoral artery at the junction between the middle and distal third of thigh and fixed by tunneling subcutaneously [Figure 1].

After placement of perineural catheter, patients were shifted to intensive care unit (ICU), where they were randomly divided into 2 groups by a randomized computer-generated code. The study drug was diluted by an independent anesthetist in a 50 mL unlabeled syringe and given to the ICU anesthetist for the study. Both the ICU anesthetist and the staff nurse were blinded to the study group. Group A patients received an infusion of 0.2% ropivacaine + dexmedetomidine 0.5 $\mu\text{g}/\text{kg}$ at 8 mL/h. Group B patients received an infusion of 0.2% ropivacaine + dexmedetomidine 1 $\mu\text{g}/\text{kg}$ at 8 mL/h.

After starting infusion of the drug, the staff nurse assigned to the patient observed the following parameters. Pain assessment was done at rest using the Numerical Rating Scale (NRS 0-no pain; 10-worst imaginable pain). Postoperatively pain was assessed every half hour during the first 2 hours followed by every 4 hours for the next 22 hours. During this period if the patient complained of pain (NRS ≥ 4), 30 μg fentanyl was given as a rescue analgesic. If a patient received rescue analgesics more than 3 times during the 24 hours following surgery, it was considered as a failed block and excluded from the study.

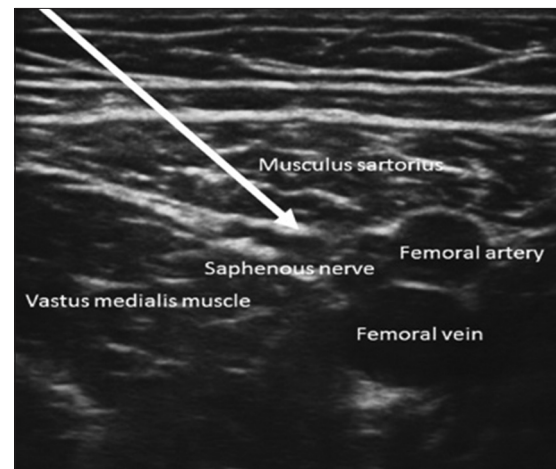


Figure 1: USG guided adductor canal block

Modified Bromage scale was used to assess the motor blockade (Grade 1-Free movement of legs, Grade 2-Just able to flex knees with free movement of feet, Grade 3-unable to flex knees but with free movement of feet, Grade 4-Unable to move legs or feet). Vital parameters like heart rate (HR), systolic blood pressure (SBP), diastolic blood pressure (DBP), and mean artery pressure (MAP) were monitored. Richmond agitation-sedation scale (RASS) was used to assess the postoperative sedation score (-5: unarousable; -4: deep sedation; -3: moderate sedation; -2: light sedation; -1: drowsy; 0: alert and calm; 1: restless; 2: agitated; 3: very agitated; 4: combative). Any adverse events occurring in the 24 hour postoperative period like nausea, vomiting, and dry mouth were also recorded.

All recordings were done at half hour intervals during the first 2 hours followed by 4 hour intervals upto 24 hours. When there was a fall in MAP >20% from the baseline, patient was treated with 250 mL of intravenous (IV) fluids and incremental doses of 50 µg of phenylephrine/3 mg ephedrine (to a maximum of 250 µg phenylephrine or 15 mg of ephedrine). In spite of this, if hypotension persisted, noradrenaline infusion was started at 0.02–0.2 µg/kg/min. A fall in HR <60/min was treated with 0.6 mg of intravenous atropine. As part of multimodal analgesia, all our patients received 1 g intravenous paracetamol at 8 hour interval during the first 24 hours.

Statistical analysis:

Since there was no similar study in the literature with two different doses of dexmedetomidine as an adjuvant to local anesthetic agents in ACB, a pilot study was conducted using 20 patients in each group who underwent unilateral TKR surgery. Based on the mean (2.8) and standard deviation (0.6325) of pain score during the first 24 hours and with 90% power and 95% confidence interval, minimal sample size was calculated to be 16 per group. We decided to include 30 patients in each group, totaling 60 patients.

The statistical analysis was done using IBM SPSS version 20.0 software (IBM SPSS, USA). Data was summarized as mean ± SD, number, and percentage as appropriate. To test the statistical significance of the difference in the mean of continuous variables between two groups, Mann-Whitney U test was applied for skewed data. To test the statistical significance of the difference in the proportion of categorical variables between groups, chi-square was used. A P-value <0.05 was considered statistically significant.

Results

The study was conducted on 60 patients who underwent unilateral TKR with continuous postoperative adductor canal

block in a tertiary care center. We compared the postoperative analgesia of two different doses of dexmedetomidine as an adjuvant to 0.2% ropivacaine in adductor canal block. We also compared the motor block, hemodynamic changes, sedation score, and adverse reactions between the two groups.

There was no statistical difference in demographical parameters between the two groups [Tables 1 and 2] though majority of the patients were females (F:45; M:15) above 60 years of age (A:B-64.50:64.53). Baseline vital parameters (HR, SBP, DBP, MAP, and SPO₂) were comparable between the two groups [Table 3].

The postoperative pain score during the first 2 hours was comparable between the two groups [Table 4, Figure 2]. After the 2nd hour till 24 hours, pain score showed a statistically

Table 1: Comparison of gender distribution between the two groups

	Group		Total	P
	A	B		
Sex				
Female	24 (53.3%)	21 (46.70%)	45	0.552
Male	6 (40%)	9 (60%)	15	
Total	30 (50%)	30 (50%)	60	

Table 2: Comparison of physical characteristics between the two groups

Variable	Category	Mean	Standard deviation	P
Age	A	64.5	9.497	0.988
	B	64.53	8.076	
Height	A	158.93	8.379	0.08
	B	155.23	7.7	
Weight	A	71.1	10.223	0.448
	B	69.1	10.036	
BMI	A	28.03667	3.966	0.417
	B	28.82667	3.506	

Table 3: Comparison of baseline vitals between the two groups

Baseline Variables	Group	n	Mean	Standard deviation	P
HR	A	30	76.6	10.193	0.19
	B	30	73.07	10.305	
SBP	A	30	139.2	16.986	0.36
	B	30	134.9	19.078	
DBP	A	30	76.6	10.105	0.19
	B	30	80.33	11.391	
MAP	A	30	98.2	13.594	0.74
	B	30	97.07	12.343	
SpO ₂	A	30	99.77	0.568	0.22
	B	30	99.57	0.679	

significant difference ($P < 0.05$) between the groups, with a lower pain score in group B as compared to Group A. Seven patients in group A needed rescue analgesic (4 patients twice and 3 patients once), whereas only two patients in Group B needed the rescue analgesic once (A:B–23%:6%). Total consumption of fentanyl was 330 μg in Group A and 60 μg in Group B. No patient had to be excluded from the study due to pain. Four patients in each group had Bromage scale score of 3 at 30 min whereas only one patient in group A and two patients in Group B had a score of 3 at 60 min [Table 5]. From 2nd hour till 24 hours all patients had a Bromage scale score of one. All our patients were calm and alert except two who were restless. There was no statistically significant difference in the vital parameters (HR, SBP, DBP, and MAP) between the groups during the postoperative 24 hours [Figures 3-6]. There was no adverse effect like bradycardia, hypotension, dry mouth, nausea, or vomiting seen in our patients.

We encountered inadvertent disconnection of the peri-neural catheter from the adapter in 15 patients either while providing care or during mobilization. These 15 patients were excluded from the study. This resulted in recruiting 75 cases instead of the planned 60 cases.

Discussion

TKR is associated with severe postoperative pain which restricts mobilization and increases morbidity. Various methods are employed to reduce postoperative pain. ACB provides efficient analgesia without significantly affecting the motor power. Ropivacaine produces less muscle weakness compared to bupivacaine.^[10] Dexmedetomidine, a selective α_2 agonist, has been used as an adjuvant of local anesthetics in peripheral nerve blocks.^[9,11] We did not find any statistically significant difference between the groups with respect to age and sex. Most of our patients were above the age of 60 years and

were females. This may be due to the higher incidence of osteoarthritis in the elderly female population.^[12] There was no difference in pain score between the groups during the first 2 hours. This may be either because of the residual effect of spinal anesthesia or due to the effect of the bolus dose of ropivacaine. After the 2nd hour till the 24th hour, Group B patients had lower pain score compared to Group A [Figure 3]. The percentage of patients who required rescue analgesic (A:B–23%: 6%) and the total consumption of fentanyl (A:B–330 μg :60 μg) was less in Group B. This shows that a higher concentration of dexmedetomidine (1 $\mu\text{g}/\text{kg}$) is a

Table 4: Comparison of pain score between the two groups

Variable	Group	Mean	Std. deviation	Median (IQR)	P
P30	A	1.07	0.868	1 (2)	0.431
	B	0.87	1.074	1 (1)	
P60	A	1.33	1.093	1 (1)	0.174
	B	0.97	0.964	1 (1)	
P90	A	1.33	1.028	1 (2)	0.341
	B	1.1	0.845	1 (1)	
P120	A	1.43	0.971	2 (1)	0.354
	B	1.2	0.961	1 (1)	
P4TH	A	1.93	0.868	2 (2)	0.02
	B	1.47	0.629	1 (1)	
P8TH	A	2.23	0.898	2 (1)	0.012
	B	1.67	0.802	1.5 (1)	
P12TH	A	2.57	0.679	3 (1)	0.002
	B	2	0.643	2 (0)	
P16TH	A	2.63	0.809	2.5 (1)	<0.001
	B	1.8	0.761	2 (1)	
P20TH	A	2.37	0.615	2 (1)	0.015
	B	1.97	0.615	2 (0)	
P24TH	A	2.47	0.629	2 (1)	0.019
	B	2.1	0.548	2 (0)	

Table 5: Comparison of motor blockade between the two groups

Time	Bromage Score	Group A	Group B
30 min	III	4	4
	II	15	13
	I	13	13
60 min	III	1	2
	II	16	15
	I	13	13
90 min	III	0	1
	II	11	8
	I	19	21
120 min	III	0	0
	II	0	1
	I	30	29
Rest of Time period	III	0	0
	II	0	0
	I	30	30

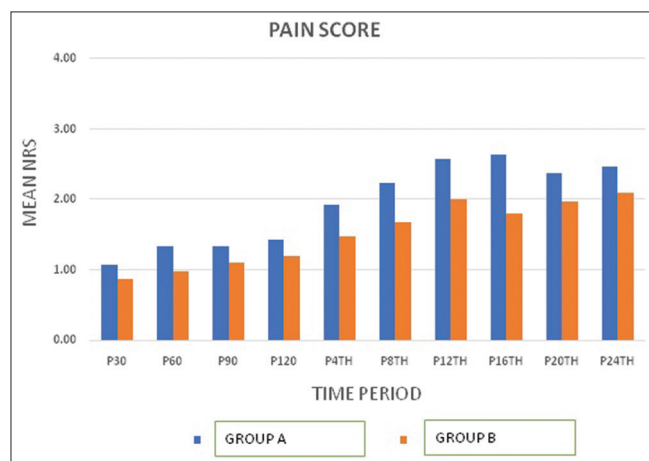


Figure 2: Comparison of pain score between the two groups

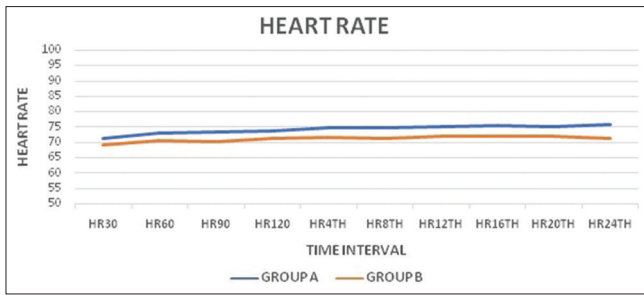


Figure 3: Comparison of heart rate between the two groups

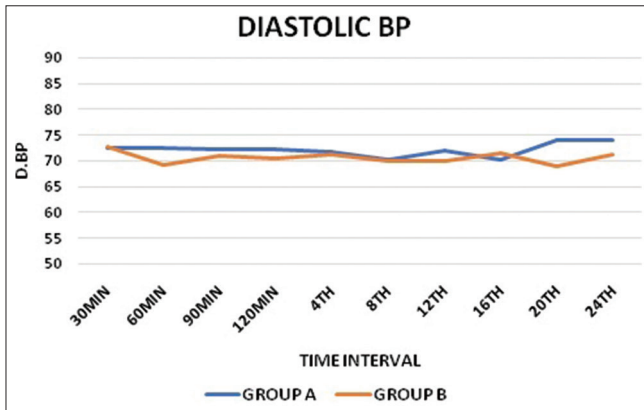


Figure 5: Comparison of diastolic blood pressure between the two groups

better adjuvant than a lower concentration (0.5 $\mu\text{g}/\text{kg}$) for postoperative pain relief. Lund *et al.*^[7] Demonstrated that continuous adductor canal blockade after TKR resulted in low mean pain scores at rest and low mean requirement for supplemental morphine. Packiasabapathy *et al.*^[13] found a higher dose of dexmedetomidine at 2 $\mu\text{g}/\text{kg}$ was a better adjuvant to bupivacaine than 1 $\mu\text{g}/\text{kg}$ in femoral nerve block for perioperative analgesia in patients undergoing TKR.

In the first two hours, a few patients had a modified Bromage scale score (BSS) of 3. This may also be because of the residual effect of spinal anesthesia or due to the bolus dose of ropivacaine. After 2 hours, the BSS was one in both the groups. This is because increasing the dose of dexmedetomidine in ACB has no effect on muscle power. Abdallah *et al.*^[6] found that quadriceps strength was superior with ACB than FNB in patients undergoing anterior cruciate ligament reconstruction. Jaeger *et al.*^[4] compared quadriceps strength with placebo, FNB, and ACB in healthy volunteers and concluded that compared with placebo, ACB significantly reduced quadriceps strength, but the reduction was only 8% from baseline. ACB preserved quadriceps strength and the ability to ambulate better than FNB did.

The hemodynamic changes of dexmedetomidine are due to the systemic absorption of the drug leading to stimulation of α_2 inhibitory neurons in the medullary vasomotor center resulting

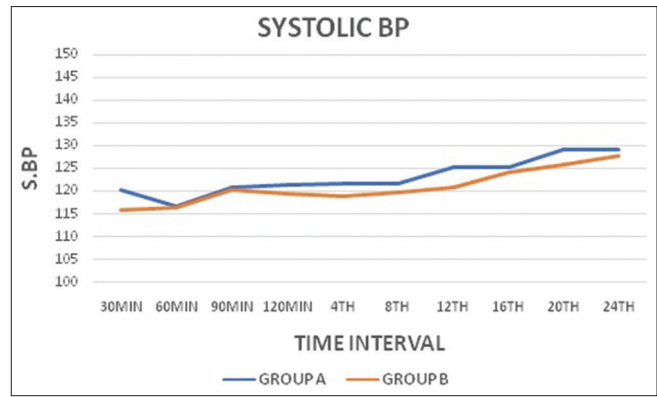


Figure 4: Comparison of systolic blood pressure between the two groups

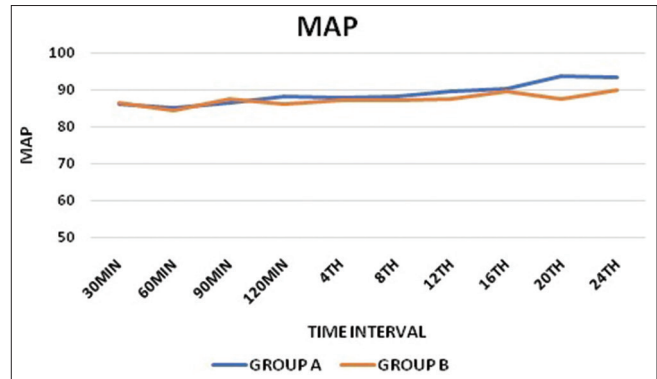


Figure 6: Comparison of mean arterial pressure between the two groups

in hypotension and bradycardia.^[11] In our study, there was no significant hemodynamic variations between the two groups during the monitored 24 hours.

The study by Chandhini S *et al.*^[14] compared the addition of 1 $\mu\text{g}/\text{kg}$ and 2 $\mu\text{g}/\text{kg}$ of dexmedetomidine to 20 mL of 0.25% levobupivacaine in supraclavicular brachial plexus block (SBPB). They found 1 $\mu\text{g}/\text{kg}$ provided a good balance between stable hemodynamics and satisfactory analgesia. Nallam *et al.*^[15] compared two different doses of dexmedetomidine (1 $\mu\text{g}/\text{kg}$ vs 2 $\mu\text{g}/\text{kg}$) as an adjuvant to 0.5% levobupivacaine in peripheral nerve stimulator-guided SBPB. Their study showed that increasing the dose of dexmedetomidine prolonged the analgesic duration and also increased the incidence of adverse effects like bradycardia and hypotension. Esmaglu *et al.*^[16] found that both HR and MAP decreased over time when dexmedetomidine is added to 0.5% levobupivacaine in axillary block.

Drugs with α_2 agonist action produce sedation centrally by activating α_2 -adrenoceptor in locus coeruleus and by inhibiting substance P release in the nociceptive pathway at the level of the dorsal root neurons. All our patients except two were calm and alert. Keplinger *et al.*^[17] studied the pharmacodynamics of dexmedetomidine as an adjuvant

to ropivacaine in peripheral nerve blockade. They found that dexmedetomidine causes clinically relevant dose-dependent sedation, whereas in our study except two all other patients were calm and alert. Abdulatif M *et al.*^[18] compared the effects of different doses of dexmedetomidine (25 µg, 50 µg, and 75 µg) in FNB and found patients in all the three groups were calm and alert.

Limitations of the study

We assessed pain score using NRS which is a subjective assessment and may vary from patient to patient depending on the pain tolerance. The surgeons removed the perineural catheter 24 hours after surgery if the patients had no pain and were comfortable with physiotherapy. Further assessment of pain scores and incidence of breakthrough pain after catheter removal could have shed light on the need for further prolongation of block duration by the adjuvant. We did not assess motor block and pain during movement. Though we had problems with faulty perineural catheters which was communicated to the dealer of the catheter, we were not provided with a rectified one.

There is scope for another study with higher concentrations of dexmedetomidine as an adjuvant to 0.2% ropivacaine in ACB. The question of whether the addition of dexmedetomidine to ropivacaine for a single shot ACB can prolong the duration of analgesia to make it comparable to a 24 hour infusion of local anesthetic is also worth studying.

Conclusion

Dexmedetomidine at a dose of 1 µg/kg is a better adjuvant to 0.2% ropivacaine than 0.5 µg/kg for providing postoperative analgesia in ACB for unilateral TKR surgery. It provides better pain relief without producing excessive sedation, motor blockade, hemodynamic changes, or any adverse effects.

Acknowledgement

Dr. Hari Shankar Gokul Menon, House surgeon, KMC Manipal.

Financial support and sponsorship

Nil.

Conflicts of interest

There are no conflicts of interest

References

- Merskey H, Albe Fessard D, Bonica JJ, Carmon A, Dubner R, Kerr FWL, *et al.* Pain terms: A list with definitions and notes on usage. Recommended by the IASP subcommittee on taxonomy. *PAIN* 1979;6:249-52.
- Li J-W, Ma Y-S, Xiao L-K. Postoperative pain management in total

- knee arthroplasty. *OrthopSurg*2019;11:755-61.
- Paul JE, Arya A, Hurlburt L, Cheng J, Thabane L, Tidy A, *et al.* Femoral nerve block improves analgesia outcomes after total knee arthroplasty: A meta-analysis of randomized controlled trials. *Anesthesiology* 2010;113:1144-62.
- Jaeger P, Nielsen ZJK, Henningsen MH, Hilsted KL, Mathiesen O, Dahl JB. Adductor canal block versus femoral nerve block and quadriceps strength: A randomized, double-blind, placebo- controlled, crossover study in healthy volunteers. *Anesthesiology* 2013;118:409-15.
- Muraskin SI, Conrad B, Zheng N, Morey TE, Enneking FK. Falls associated with lower-extremity-nerve blocks: A pilot investigation of mechanisms. *RegAnesth Pain Med* 2007;32:67-72.
- Abdallah FW, Whelan DB, Chan VW, Prasad GA, Endersby RV, Theodoropolous J, *et al.* Adductor canal block provides noninferior analgesia and superior quadriceps strength compared with femoral nerve block in anterior cruciate ligament reconstruction. *Anesthesiology*2016;124:1053-64.
- Lund J, Jenstrup MT, Jaeger P, Sørensen AM, Dahl JB. Continuous adductor-canal-blockade for adjuvant post-operative analgesia after major knee surgery: Preliminary results. *ActaAnaesthesiolScand*2011;55:14-9.
- Kuthiala G, Chaudhary G. Ropivacaine: A review of its pharmacology and clinical use. *Indian J Anaesth*2011;55:104-10.
- Kumar P, Thepra M, Bhagol A, Priya K, Singh V. The newer aspect of dexmedetomidine use in dentistry: As an additive to local anesthesia, initial experience, and review of literature. *Natl J MaxillofacSurg*2016;7:76-9.
- Bhat SN, Himaldev, Upadya M. Comparison of efficacy and safety of ropivacaine with bupivacaine for intrathecal anesthesia for lower abdominal and lower limb surgeries. *Anesth Essays Res* 2013;7:381-5.
- Gertler R, Brown HC, Mitchell DH, Silvius EN. Dexmedetomidine: A novel sedative-analgesic agent. *Proc (BaylUniv Med Cent)* 2001;14:13-21.
- Hame SL, Alexander RA. Knee osteoarthritis in women. *Curr Rev Musculoskelet Med* 2013;6:182-7.
- Packiasabapathy SK, Kashyap L, Arora MK, Batra RK, Mohan VK, Prasad G, *et al.* Effect of dexmedetomidine as an adjuvant to bupivacaine in femoral nerve block for perioperative analgesia in patients undergoing total knee replacement arthroplasty: A dose-response study. *Saudi J Anaesth*2017;11:293-8.
- Chandhini S, Kumar A, Kumari P, Singh AK, Sharma S, Kumar A, *et al.* Comparison of two doses of dexmedetomidine for supraclavicular brachial plexus block: A randomized controlled trial. *Anesth Essays Res* 2018;12:470-4.
- Nallam SR, Chiruvella S, Karanam S. Supraclavicular brachial plexus block: Comparison of varying doses of dexmedetomidine combined with levobupivacaine: A double-blind randomised trial. *Indian J Anaesth*2017;61:256-61.
- Esmoğlu A, Yeğenoğlu F, Akin A, Türk CY. Dexmedetomidine added to levobupivacaine prolongs axillary brachial plexus block. *AnesthAnalg*2010;111:1548-51.
- Keplinger M, Marhofer P, Kettner SC, Marhofer D, Kimberger O, Zeitlinger M. A pharmacodynamic evaluation of dexmedetomidine as an additive drug to ropivacaine for peripheral nerve blockade: A randomised, triple-blind, controlled study in volunteers. *Eur J Anaesthesiol*2015;32:790-6.
- Abdulatif M, Fawzy M, Nassar H, Hasanin A, Ollaek M, Mohamed H. The effects of perineural dexmedetomidine on the pharmacodynamic profile of femoral nerve block: A dose-finding randomised, controlled, double-blind study. *Anaesthesia* 2016;71:1177-85.