

Received: 2022.03.14

Accepted: 2022.06.16

Available online: 2022.06.28

Published: 2022.08.08

# A 73-Year-Old Man with an Incidental Diagnosis of Deltoid Intramuscular Myxoma Following a History of Trauma

## Authors' Contribution:

Study Design A  
Data Collection B  
Statistical Analysis C  
Data Interpretation D  
Manuscript Preparation E  
Literature Search F  
Funds Collection G

ABCDEF 1 **Christian Akem Dimala**  
AEF 1 **Ibiyemi Oke**  
BDE 2 **Fikru Merechi**  
ABDEF 1,3 **Ryan P. Zimmerman**

1 Department of Medicine, Reading Hospital, Tower Health System, West Reading, PA, USA  
2 Department of Pathology, Reading Hospital, Tower Health System, West Reading, PA, USA  
3 Assistant Professor of Medicine, Drexel University College of Medicine, Philadelphia, PA, USA

**Corresponding Author:** Christian Akem Dimala, e-mail: [Christian.akem.dimala1@alumni.lshtm.ac.uk](mailto:Christian.akem.dimala1@alumni.lshtm.ac.uk)  
**Financial support:** None declared  
**Conflict of interest:** None declared

**Patient:** Male, 73-year-old  
**Final Diagnosis:** Intramuscular myxoma  
**Symptoms:** Shoulder pain  
**Medication:** —  
**Clinical Procedure:** —  
**Specialty:** General and Internal Medicine • Orthopedics and Traumatology

**Objective:** Rare disease

**Background:** Intramuscular myxomas are rare and benign soft-tissue tumors of uncertain differentiation. Predisposing or precipitating factors have not yet been reported. Activating mutation in GNAS (exons 8 and 9) is detected in >90% of sporadic cases. The role of chronic myopathy, tendinopathy, or trauma to muscles in the etiology of these neoplasms is not known. We report an unusual case of a deltoid mass found following longstanding rotator cuff tendinopathy and a recent fall, later confirmed to be an intramuscular myxoma on biopsy.

**Case Report:** A 73-year-old man with a 5-year history of left shoulder pain and rotator cuff tear presented with intractable pain in his left shoulder after a recent fall at home. Physical examination was suggestive of a rotator cuff injury and magnetic resonance imaging (MRI) of the left shoulder revealed a 2.7×2.5×3.7cm T1 hypo- and T2 hyperintense oblong mass-like signal abnormality with heterogeneous, predominantly peripheral enhancement within the deltoid muscle concerning for a malignant mass. Surgical resection was carried out along with left reverse total shoulder replacement, and histopathology revealed findings consistent with an intramuscular myxoma.

**Conclusions:** Intramuscular myxomas are rare, benign tumors. This case report presents one such myxoma incidentally found in a patient with longstanding rotator cuff tendinopathy and a recent fall. Although this co-occurrence is likely incidental, further research and case series review of similar presentations may influence postulations of the pathophysiology of myxomas.

**Keywords:** Tendinopathy • Myxoma • Neoplasms

**Abbreviations:** CT – computed tomography; IST – infraspinatus tendon; MRI – magnetic resonance imaging; PET – positron emission tomography; SSC – subscapularis; SST – supraspinatus tendon

**Full-text PDF:** <https://www.amjcaserep.com/abstract/index/idArt/936654>



1088



—



5



18



## Background

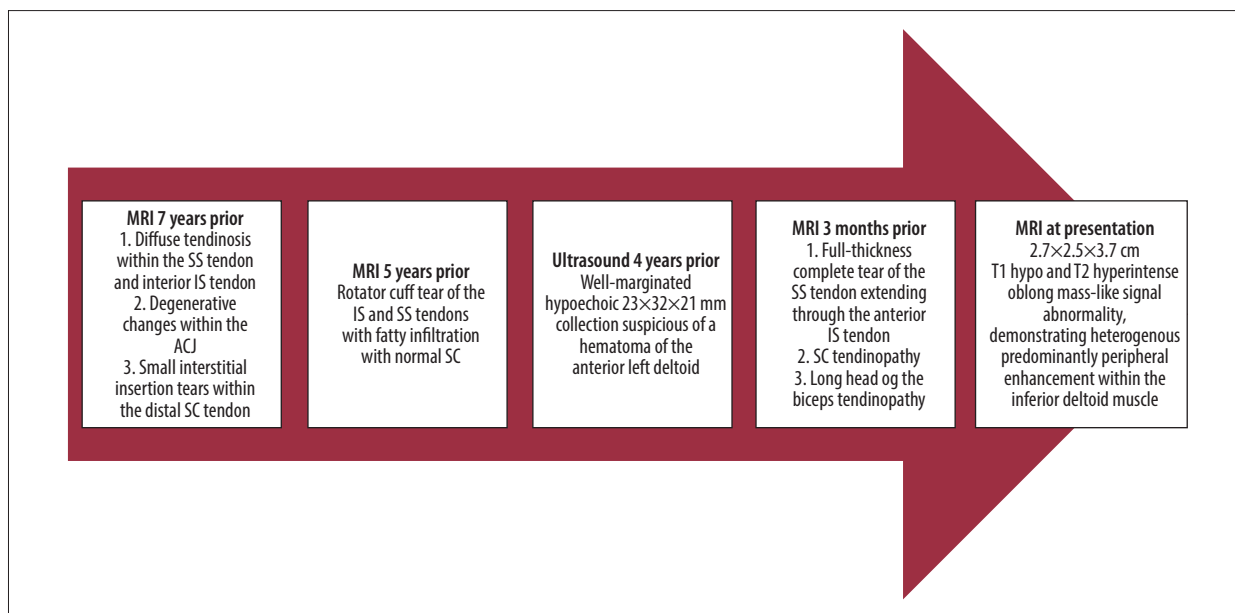
Intramuscular myxomas are rare, benign soft-tissue tumors of uncertain differentiation [1,2]. These painless masses predominantly occur in the large skeletal muscles, especially of the thighs and less commonly in the buttocks, calves, neck, and shoulders [2,4]. Myxoma occurrence in the deltoid muscle is even rarer; fewer than 10% of all intramuscular myxomas occur in the upper arm [3]. These neoplasms comprise stellate cells with thin collagen and mucinous stroma [2,4,5]. There are no known predisposing or precipitating factors reported to date, but activating mutation in GNAS (exons 8 and 9) is detected in most sporadic cases [6]. Intramuscular myxomas have been reported in patients who presented with pain in the affected muscle after trauma or a fall [5]. It is, however, not known if chronic myopathy, tendinopathy, or trauma to muscles predispose to intramuscular myxomas formation. We report an unusual case of a deltoid mass in a patient with longstanding rotator cuff tendinopathy and a recent fall, later found to be an intramuscular myxoma on biopsy.

## Case Report

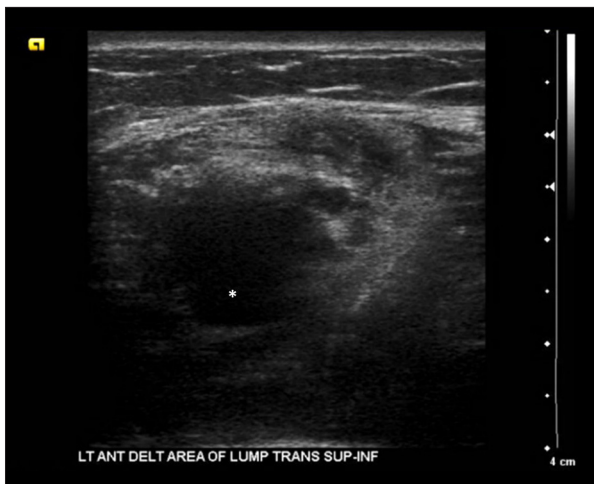A 73-year-old man with a history of paroxysmal kinesigenic dyskinesia, cervical and lumbar neural foraminal stenosis with multiple prior back surgeries, and a 5-year history of left shoulder pain and rotator cuff tear presented with intractable pain in his left shoulder after a recent fall at home.

He had previously consulted at other facilities for this longstanding left shoulder pain and had multiple imaging studies of his left shoulder (Figure 1) and had received steroid injections with little improvement in his symptoms. A magnetic resonance imaging (MRI) scan of his left shoulder 7 years prior to his current presentation showed diffuse tendinosis within the supraspinatus tendon and anterior infraspinatus tendon with associated articular surface partial rotator cuff tear, while another MRI scan of his left shoulder done 5 years prior to the current presentation reported a rotator cuff tear of the infra- and supraspinatus tendons with fatty infiltration and normal subscapularis. Ultrasound imaging of his left shoulder 4 years prior to the current presentation reported a well-margined hypoechoic 23×32×21 mm collection in the anterior left deltoid, likely a hematoma (Figure 2), after he presented with pain and a palpable mass in his left shoulder. A final MRI of his left shoulder 3 months prior to the current presentation showed severe tendinopathy of the rotator cuff muscle tendons (Figure 3).

At his current presentation to our facility, he also reported back pain and a tingling sensation down his left arm. On examination, he had positive glenohumeral crepitus, tenderness along the joint lines anteriorly and posteriorly, and pain with left shoulder motion. Impingement signs I and II, drop arm test, and Speed's test were positive. A left shoulder X-ray showed severe glenohumeral joint arthritis with 75% superior humeral head subluxation and flattening of the humeral head, but there was no fracture. MRI of the left shoulder this time revealed a 2.7×2.5×3.7cm T1 hypo- and T2 hyperintense oblong mass-like signal abnormality, demonstrating heterogeneous predominantly peripheral enhancement within the inferior



**Figure 1.** Flow diagram showing the various radiographic studies of the left shoulder performed prior to current presentation. ACJ – acromioclavicular joint; IS – infraspinatus; MRI – magnetic resonance imaging; SC – subscapularis; SS – supraspinatus.



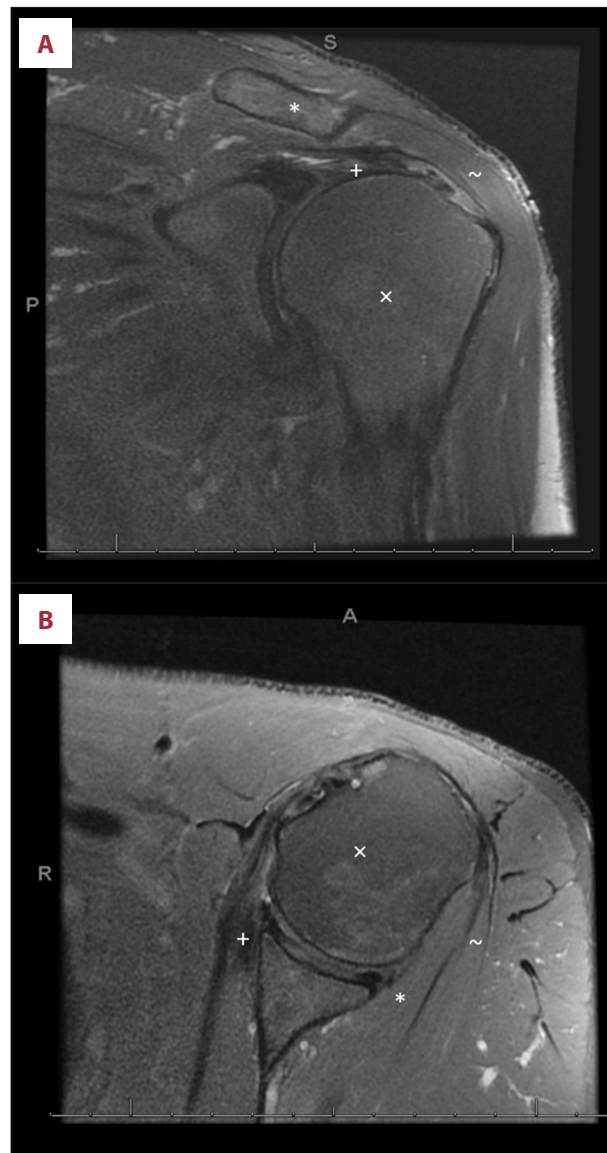
**Figure 2.** Ultrasound of the left shoulder showing a hypoechoic 23×32×21 mm collection in the left anterior deltoid area. Hematoma indicated by asterisk \*.

deltoid muscle (Figure 4). Other abnormalities noted on MRI were degenerative changes of the shoulder with a complete full-thickness tear of the supraspinatus tendon with retraction of the proximal head (Figure 4).

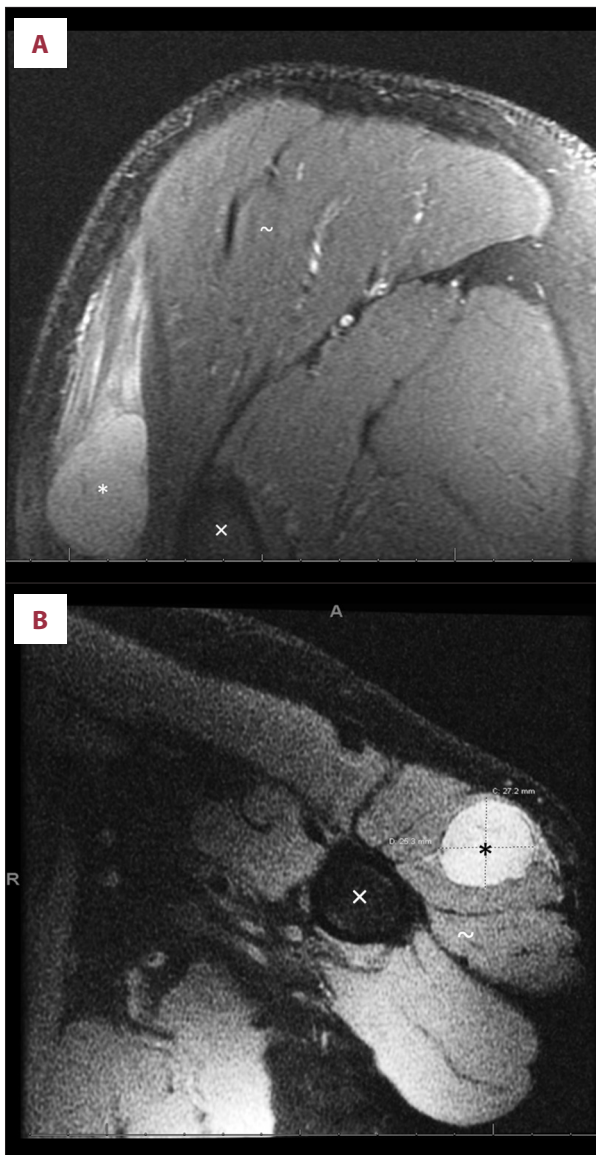
Following orthopedic assessment, his rotator cuff tear was not repairable, and given his severe glenohumeral degenerative changes, he had left reverse total shoulder replacement and excision of the left upper arm mass. Histopathology of the mass revealed a hypocellular lesion with bland nuclei in a background of abundant extracellular myxoid stroma, consistent with an intramuscular myxoma (Figure 5). He had remarkable improvement in his shoulder pain after surgery and progressive improvement of his left shoulder range of movement with physical therapy. At one-year follow up, he regained nearly full range of motion of his left shoulder and there was no evidence of recurrence of the myxoma.

## Discussion

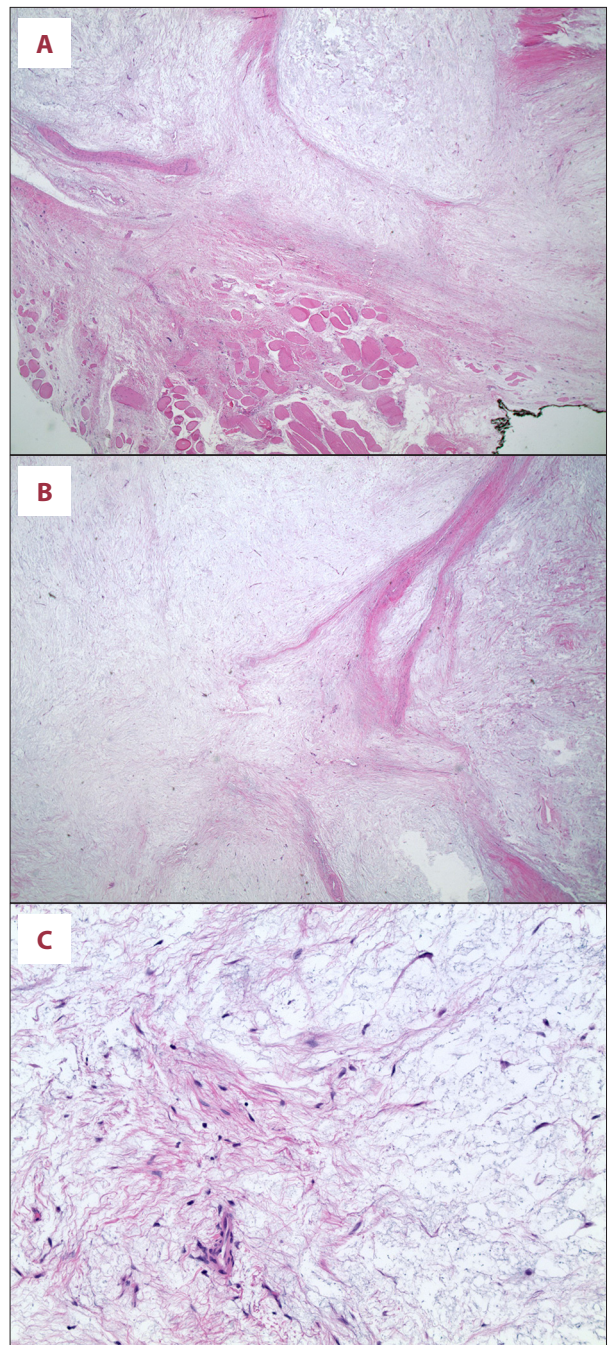
Intramuscular myxomas are rare benign tumors with an incidence of 1 case per million population and a female preponderance [3,7]. These neoplasms of uncertain differentiation present histologically as stellate cells within a myxoid/mucinous stroma [1,3,8,9]. Intramuscular myxomas predominantly occur in large skeletal muscles of the thighs but less so in the buttocks, calves, shoulders, cervical region, and paraspinal muscles of the back [3]. We found fewer than a dozen published cases of intramuscular myxomas of the deltoid muscle [10-16]. They usually present as asymptomatic slowly enlarging masses incidentally found on imaging studies but can also present with pain depending on the extent of compression of adjacent structures.



**Figure 3.** Magnetic resonance imaging with i.v. gadolinium contrast images of the left shoulder showing severe tendinopathy of the rotator cuff muscles. (A) Coronal T2 with fat suppression image (\* acromion, ~ deltoid tendon, x humeral head, + supraspinatus tendon). (B) Axial PD with fat suppression (\* infraspinatus tendon, + subscapularis, ~ deltoid tendon, x humeral head). There is a full-thickness complete tear of the supraspinatus tendon with retraction of the majority of the tendon to the superior humeral head proximally 2.5 cm from the insertion. The tear extends into the anterior aspect of the infraspinatus tendon, involving approximately 50% of the infraspinatus tendon with sparing of the posterior fibers. The teres minor tendon is intact, without significant tendinopathy. There is fatty atrophy of the supraspinatus and infraspinatus muscle bellies and severe osteoarthritis of the acromioclavicular joint.



**Figure 4.** Magnetic resonance imaging with i.v. gadolinium contrast images of the left shoulder showing a 2.7×2.5×3.7 cm oblong mass with the inferior deltoid muscle. (A) Coronal T2 with fat suppression image (\* intramuscular mass, ~ deltoid tendon, x humeral head). (B) Axial PD with fat suppression (\* intramuscular mass, ~ deltoid tendon, x humeral head). Within the inferior deltoid muscle is an oblong mass-like signal abnormality which is T1 hypo- and T2 hyperintense, measuring approximately 2.7×2.5×3.7 cm. Post-gadolinium sequences demonstrate heterogeneous regions of predominantly peripheral enhancement.



**Figure 5.** Histopathology slides of biopsied left deltoid muscle mass. (A) Entrapped skeletal muscle fibers at the periphery of the tumor (lower half represents the skeletal muscle fibers which are splayed by the tumor cells). (B) The tumor is a hypocellular lesion composed of bland cells in a background of abundant extracellular myxoid stroma. (C) Small capillary-sized vessels are seen. Necrosis and mitotic figures are not identified. Uniform spindle-to-stellate-shaped cells with uniform oval nuclei and indistinct eosinophilic cytoplasm are noted.

Activating mutation in *GNAS* (exons 8 and 9) is detected in most sporadic cases [6] and no precipitating factors have been reported in the literature. Although this unusual occurrence of a myxoma after a fall as observed in our patient and a prior case report [5] is likely coincidental, the role of trauma in the pathophysiology of these neoplasms should be questioned. Likewise, the observed chronic rotator cuff tendinopathy in our patient raises the question of the role of chronic myopathy and tendinopathy in the pathophysiology of these tumors due to persistent muscle destruction and remodeling over time.

Diagnosing intramuscular myxomas with imaging presents some challenges given their rarity [1]. Intramuscular myxomas typically present as well-defined ovoid heterogenous hypoechoic masses with some internal echoes and absent internal vascularity on ultrasound [2,17]. MRI usually demonstrates a homogenous mass with low to intermediate signal intensity relative to surrounding muscle on T1-weighted images or a high signal intensity on T2-weighted images [5,7,17,18]. CT scans typically show a well-defined homogenous soft-tissue mass with lower attenuation compared to surrounding muscle [7]. Despite these typical presentations of myxomas on various imaging modalities, it is not unusual for them to be mistaken for other mesenchymal lesions such as lipomatous lesions [12], highlighting the importance of biopsy and/or resection for histopathology studies to ultimately make a diagnosis.

## References:

1. Stout AP. Myxoma, the tumor of primitive mesenchyme. *Ann Surg.* 1948;127(4):706-19
2. Hashimoto H, Tsuneyoshi M, Daimaru Y, et al. Intramuscular myxoma. A clinicopathologic, immunohistochemical, and electron microscopic study. *Cancer.* 1986;58(3):740-47
3. Petscavage-Thomas JM, Walker EA, et al. Soft-tissue myxomatous lesions: Review of salient imaging features with pathologic comparison. *Radiographics.* 2014;34(4):964-80
4. Kindblom LG, Stener B, Angervall L. Intramuscular myxoma. *Cancer.* 1974;34(5):1737-44
5. Zou LY, Brown DA, Li AC. Intramuscular myxoma. *Ultrasound Q.* 2013;29(3):255-56
6. Sunitsch S, Gilg MM, Kashofer K, et al. Detection of *GNAS* mutations in intramuscular/cellular myxomas as diagnostic tool in the classification of myxoid soft tissue tumors. *Diagn Pathol.* 2018;13(1):52
7. Kransdorf MJ, Murphey MD. Imaging of soft tissue tumors. Lippincott Williams & Wilkins; 2006;607
8. Falavigna A, Righesso O, Volquind D, Teles AR. Intramuscular myxoma of the cervical paraspinal muscle. *Eur Spine J.* 2009;18(Suppl 2):245-49
9. Rachidi S, Sood AJ, Rumboldt T, Day TA. Intramuscular myxoma of the paraspinal muscles: A case report and systematic review of the literature. *Oncol Lett.* 2016;11(1):466-70
10. Adamonis S, Enodien B, Taha-Mehlitz S, et al. Intramuscular myxoma of the deltoid muscle in a swimmer: A rare case report and literature review. *Clin Case Rep.* 2019;7(12):2398-401
11. Costamagna D, Erra S, Durando R. Intramuscular myxoma of the deltoid muscle: Report of a case. *BMJ Case Rep.* 2009;2009:bcr08.2008.0678
12. Tirefort J, Kolo FC, Lädermann A. An interesting case of intramuscular myxoma with scapular bone lysis. *Case Rep Orthop.* 2017;2017:1690409
13. Kemah B, Soylemez MS, Ceyran B, et al. A case of intramuscular myxoma presenting as a swollen shoulder: A case report. *J Med Case Rep.* 2014;8:441
14. Piciu D, Barbus E, Piciu A, Fetica B. Mazabraud's syndrome and thyroid cancer, a very rare and confusing association: A case report. *BMC Endocr Disord.* 2015;15:39
15. Schimmöller L, Lehwald N, Antoch G, Kröpil P. Polyostotic fibro-osseous lesions associated with intramuscular soft tissue neoplasms. *Radiol.* 2012;52(10):934-36
16. Périgny M, Dion N, Couture C, Lagacé R. [Low-grade fibromyxoid sarcoma: A clinico-pathologic analysis of 7 cases]. *Ann Pathol.* 2006;26(6):419-25 [in French]
17. Shi J, Dai T, Yang R, Sun Z. Diagnostic value of ultrasonography and other imaging examinations in patients with intramuscular myxoma: A case series and literature review. *Clin Imaging.* 2020;68:161-65
18. Bancroft LW, Kransdorf MJ, Menke DM, et al. Intramuscular myxoma: Characteristic MR imaging features. *Am J Roentgenol.* 2002;178(5):1255-59

## Conclusions

Intramuscular myxomas are rare, benign tumors. This case presents one such myxoma incidentally found in a patient with longstanding rotator cuff tendinopathy and a recent fall. Although this co-occurrence is likely incidental, further research and case series review of similar presentations may influence postulations of the pathophysiology of myxomas.

## Declaration of Figures' Authenticity

All figures submitted have been created by the authors who confirm that the images are original with no duplication and have not been previously published in whole or in part.