



RESEARCH ARTICLE

The role of exogenous epidermal growth factor on Ki-67 proliferation marker expression in the submandibular salivary gland of albino rats receiving doxorubicin [version 1; peer review: 2 approved, 1 approved with reservations]

Mohamed Mansy¹, Malak Soliman², Rabab Mubarak³, Mohamed Shamel⁴

¹Department of Oral Biology, Jazan University, Jazan, Saudi Arabia

²Department of Oral Biology, Cairo University, Cairo, Egypt

³Department of Oral Biology, Cairo University, Vice Dean of faculty of Dentistry, Deraya University, Cairo, Egypt

⁴Department of Oral Biology, The British University in Egypt, Shorouk city, Egypt

V1 First published: 03 Dec 2020, 9:1393
<https://doi.org/10.12688/f1000research.27186.1>
 Latest published: 03 Dec 2020, 9:1393
<https://doi.org/10.12688/f1000research.27186.1>

Abstract

Background: This study was conducted to evaluate the role of exogenous epidermal growth factor (EGF) injection on the Ki-67 immuno-expression in submandibular salivary gland tissue of rats receiving doxorubicin (DXR).

Methods: A total of 21 two-month-old male albino rats, of 200 g body weight, were divided into three groups: control group; DXR group, the rats received 20 mg/kg body weight DXR as a single intra peritoneal injection; DXR+EGF group, the rats received the same dose of DXR and on the next day they were injected intraperitoneally with 10 µg/kg body weight of EGF daily for one week. Histological sections and immunohistochemical expression of Ki67 sections were examined using a ZEISS Primo Star light microscopy and images taken using Tucsen IS 1000 10.0MP Camera.

Results: Ki-67 expression was significantly increased in submandibular salivary glands of rats after DXR injection. However, Ki-67 expression in the glandular tissue was restored to normal levels after EGF injection.

Conclusions: EGF preserved glandular architecture after DXR injection and maintained Ki-67 immune-expression within the glandular tissue near to the normal level.

Keywords

Epidermal growth factor, Ki-67, Doxorubicin, submandibular salivary gland

Open Peer Review

Reviewer Status ? ✓ ✓

Invited Reviewers

	1	2	3
version 1	?	✓	✓
03 Dec 2020	report	report	report

1. **Mushfiq Hassan Shaikh** , Western University, London, Canada
2. **Marwa Abdul-Salam Hamied** , Sulaimani University, Sulaimani, Iraq
3. **Mahmoud Serag**, East Carolina University, Greenville, USA

Any reports and responses or comments on the article can be found at the end of the article.

Corresponding author: Mohamed Shamel (mohamed.shamel@bue.edu.eg)

Author roles: **Mansy M:** Conceptualization, Formal Analysis, Investigation, Methodology, Writing – Original Draft Preparation, Writing – Review & Editing; **Soliman M:** Supervision, Validation, Writing – Review & Editing; **Mubarak R:** Investigation, Methodology, Supervision, Validation, Visualization, Writing – Review & Editing; **Shamel M:** Methodology, Resources, Visualization, Writing – Review & Editing

Competing interests: No competing interests were disclosed.

Grant information: The author(s) declared that no grants were involved in supporting this work.

Copyright: © 2020 Mansy M *et al.* This is an open access article distributed under the terms of the [Creative Commons Attribution License](#), which permits unrestricted use, distribution, and reproduction in any medium, provided the original work is properly cited.

How to cite this article: Mansy M, Soliman M, Mubarak R and Shamel M. **The role of exogenous epidermal growth factor on Ki-67 proliferation marker expression in the submandibular salivary gland of albino rats receiving doxorubicin [version 1; peer review: 2 approved, 1 approved with reservations]** F1000Research 2020, 9:1393 <https://doi.org/10.12688/f1000research.27186.1>

First published: 03 Dec 2020, 9:1393 <https://doi.org/10.12688/f1000research.27186.1>

Introduction

Ki-67 is a heavy protein of 395 kDa weight. It is a proliferation marker which is highly expressed in various tumors, and has been used for investigations of many cancer types. Ki-67 is controlled by proteolytic pathways and has similar essential properties with other proteins known to regulate the cell cycle (Hofmann & Bucher, 1995). Furthermore, Ki-67 is an important protein for cell division as antisense nucleotides of Ki-67 will stop the division, and it is a vital factor in the formation of ribosomes (Schluter *et al.*, 1993). This is reinforced by the conclusion that Ki-67 immuno-expression associates with the rate of protein production and function of ribosomes (Plaat *et al.*, 1999).

Proliferation marker evaluation is of high value in pathological diagnosis and prognosis. It has been reported that Ki-67 has a prognostic character for many forms of malignant tumors, such as lymphomas, breast, prostate and colorectal cancers (Tretiakova *et al.*, 2016). Ki-67 is a protein formed during active phases of the cell mitotic cycle, but is not present in resting cells. Therefore, its expression is used as an assessment tool for tissue proliferation (Faur *et al.*, 2015).

The division activity measured by Ki-67 has been reported in previous studies, and has a great prognostic significance in different forms of malignancies (Yerushalmi *et al.*, 2010). Ki-67 is a protein linked with cell production and is noticeable in all active phases of the cell cycle cresting at G2 and persisting at low levels after cell cycle exit. It then becomes undetectable in senescent cells (Sobecki *et al.*, 2017).

Epidermal growth factor (EGF) could motivate the production and differentiation of epidermal cells and assist skin renewal and wound healing. The therapeutic effect of EGF in the treatment of thermal injuries is not only confined to rapid activation of the healing process and a decrease in tissue damage, but also decreases the size of the affected area and reduces hyperergic inflammation. EGF has demonstrated its efficacy in thermic injury by stimulating wound healing and decreasing the possibility of purulent septic complication and tissue damage. This process might also involve modulation of the immune system status (Osikov *et al.*, 2014; Parment *et al.*, 2007).

Doxorubicin (DXR) is an important drug for leukemia, Hodgkin's lymphoma and bladder, breast, stomach, lung and ovaries cancer, treatment during chemotherapy (Bielack *et al.*, 1996). Jensen *et al.* (2002) studied the consequence of chemotherapy on the salivary gland with different solid and hematological tumors. Apart from xerostomia, 50% of the salivary glands of the patients showed ductal dilatation, cyst formation, degenerated acini and inflammatory cell presence. These degenerated salivary glands were markedly detected less than 2 weeks after chemotherapy. DXR motivates reactive oxygen species (ROS) synthesis and depolarizes the membrane potential of the mitochondria. Both excessive ROS synthesis and mitochondrial membrane damage are very important causes of cellular injury (Ghosh *et al.*, 2011).

This study was conducted to evaluate the role of exogenous EGF injection on the Ki-67 immuno-expression in submandibular

salivary gland tissue of rats receiving DXR. Rats were used in this study because they have biology similar to humans and therefore can be a model for human carcinogenicity and recovery.

Methods

Animals

This study protocol and the animal care and experimental procedures were approved by the Ethics Committee, Faculty of Dentistry, Cairo University, Egypt (#415). All efforts were made to ameliorate any suffering of the animals by adopting the OECD 423 test guidelines, and all applicable international, national, and/or institutional guidelines for the care and use of animals were followed.

In total, 21 male adult albino rats, two months old, pathogen free, with an average weight of 200 gm were used. The animals were obtained from and housed in the Animal house, Faculty of Medicine, Cairo University. Sample size calculation was performed using G*Power version 3.1.9.2 (University Kiel, Germany) (Faul *et al.*, 2009). The effect size was 0.95 using α level of 0.05 and β level of 0.05, i.e., power = 95%; the estimated sample size (n) was a total of 21 samples for three groups.

The animals were housed in a controlled environment (temperature $25\pm 2^\circ\text{C}$, humidity 70–80% and 12hr dark/light cycle) and had free access to food and water. The animals were fed a natural diet and water *ad libitum* throughout the whole experiment. The rats were acclimatized to their cages for 1 week.

All 21 rats were given a number (1–21) using a marker pen, then randomized by putting the numbers in an envelope and dividing them into three groups according to the numbers which were taken from the envelope.

The three groups were as follows:

- control group, the rats were kept on a normal diet and did not receive DXR or EGF;
- DXR group, the rats received 20 mg/kg body weight DXR as a single intra-peritoneal injection (Ayla *et al.*, 2011);
- DXR+EGF group, the rats received the same intra-peritoneal dose of DXR (20 mg/kg body weight) and on the next day they were injected intraperitoneally with 10 μg /kg body weight of EGF daily for one week (Ohlsson *et al.*, 1997).

The rats were injected every morning at 9 am in the animal house laboratory of Faculty of Medicine, Cairo university.

Procedure

This study was performed to detect changes in the salivary glands after doxorubicin injection and the role of EGF, if any, in reversing any negative changes appearing in the glands. Therefore, histological sections as well as Ki67 immuno expression were used to detect these changes.

The rats were sacrificed by euthanization by CO₂ asphyxiation followed by cervical dislocation when the experiment finished after 1 week.

Submandibular salivary glands of both sides were dissected out and preparation of specimens for staining procedure was done as follows.

After the glands were excised, those of the right side were fixed immediately in 10% neutral buffered formalin. Then, the specimens were washed properly under running water, dehydrated through ascending concentrations of alcohol and transferred to xylene to clear the specimens from alcohol. Then, the glands were embedded in paraffin wax and mounted in the center of the paraffin wax blocks. Sections from paraffin embedded tissues blocks were cut into sections 5- μ m thick and mounted on glass slides for histological examination using Samples were processed for regular histopathological examination using H&E stain. Other sections were stained with immuno-peroxidase for immunohistochemical detection of Ki-67 in the glandular tissue using staining reaction containing anti-Ki-67 antibodies (Santa Cruz Biotechnology catalogue # sc-23900).

The selected sections were studied by ZEISS Primo Star light microscopy and images taken using Tucsen IS 1000 10.0MP Camera in the Oral Biology Lab, Faculty of Dentistry, Cairo University.

The scoring of the staining reaction of the immunohistochemical parameter (presence of Ki-67) of the different groups was as follows: (-) negative reactivity and (+) positive reactivity.

Image analysis

Image analysis was performed using a computer system software Leica Quin 500 (LEICA Imaging Systems Ltd, Cambridge, England) to assess the area percentage of the immunostaining within the tissues.

The image analyzer was first calibrated automatically to convert the measurement units (pixels) produced by the image analyzer program into actual micrometer units. Measurement of the area of percentage positive cells was done as previously described (Shi *et al.*, 2007). Briefly, the percentage of positive cells was recorded as an area and area percentage within a standard measuring frame of area 114,342.9 mm² per 10 fields from different slides. This was done at a magnification of 400X by the light microscope transmitted to the monitor. Areas containing the most uniformly stained tissues were chosen for evaluation. These areas were disguised by blue binary color which could be measured by the computer system. Images were manually corrected for brightness and contrast. Colour thresholding was then performed automatically after which pictures were converted to RGB stack type. Masking of the brown cyokeratin, immuno-stain was performed by blue colour where any brown stain of any intensity was considered positive whereas the background grey stain was considered negative. Area fraction was then calculated automatically representing the area percentage of immune positive cells to the total area of the microscopic field.

Data analysis

Image analysis data representing experimental values of Ki-67 immunostain were given as mean and standard deviation. ANOVA (ONEWAY ANOVA test, n=10, P <0.05) was used to compare the mean area percent of Ki-67 immuno-expression among the specimens of different groups. Tukey's Multiple Comparison Test (Post Hoc Tukey HSD) was performed to calculate a pair-wise comparison between each group. SPSS 25.0 for Windows (SPSS Inc., Chicago, IL, USA) was used for analysis.

Results

Histological examination

Histological examination of the submandibular salivary gland of rats of control group (group I) revealed its main structural components was composed of parenchymal tissue supported by connective tissue stroma (Figure 1A). Histopathological sections of DXR group (group II) showed several pathological changes. The secretory acini appeared with massive cytoplasmic vacuolization, and deformation in the acini and loss of normal cellular orientation were frequently encountered. A clear space separated the parenchymal elements, which might be an index of interstitial edema and extravasated red blood cells (RBCs) in between acini and ducts (Figure 1B).

Comparing with the histopathological results of DXR group, the DXR+EGF group (group III) sections showed great enhancement in the structural features of the glands. Little evidence of inflammatory condition was present. On the other hand, many blood vessels engorged with RBCs were found in close relation with the striated ducts. Moreover, a rich vascular network was found in association to the excretory ducts (Figure 1C).

Ki-67 immunoreactivity

The control group sections showed positive cytoplasmic immunoreactivity for Ki-67 protein in the parenchymal tissue of the glands, which appeared more distinctive in the duct system. Scattered nuclear reactivities were identified for the protein antigen. A few localized focal areas in the secretory acini as well as the endothelial cells of blood vessels expressed the proliferation antigen at higher intensity (Figure 2A). On the other hand, the immunohistochemical findings of the DXR group corroborated with the histological results; Ki-67 protein was localized in the DXR group sections differently to the control group. DXR was found to increase the immuno-expression of Ki-67 protein in the submandibular salivary glands of rats particularly the secretory terminal portions. Wider areas of the acini expressed the antigen and with greater intensity. The expression of the proliferation antigen appeared foamy, probably due to the vacuolar degeneration affecting the glandular tissue. Scattered nuclear and perinuclear reactivities were identified for the protein antigen in this group (Figure 2B).

The differences between the control and DXRs groups were statistically significant, as there was a significant increase in the mean area percent of Ki-67 immuno-expression found in DXR group in contrast with the control group (p<0.01; Figure 3).

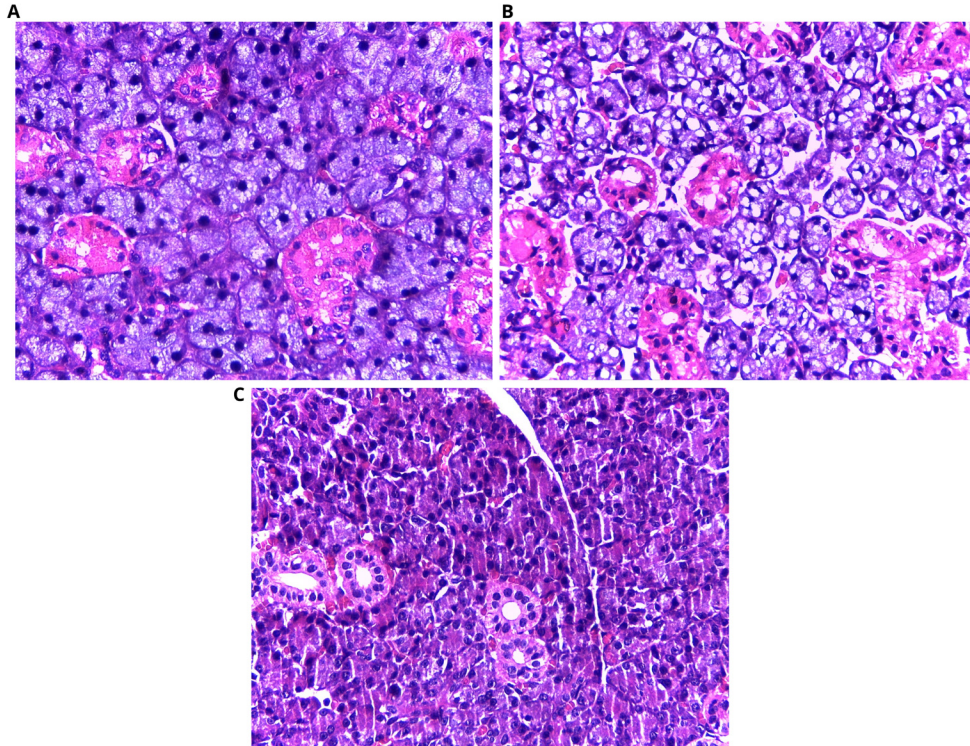


Figure 1. Photomicrographs showing histology of salivary glands. (A) Control group, regular gland architecture; (B) DXR group, degenerated acini with multiple vacuoles extravasated red blood cells (RBCs) in between acini and ducts; (C) DXR+EGF group, well aligned acini together with blood vessels engorged with RBCs in association with the striated ducts exhibiting good cell alignment and minute areas of small vesicles. H&E staining, orig. mag. X400.

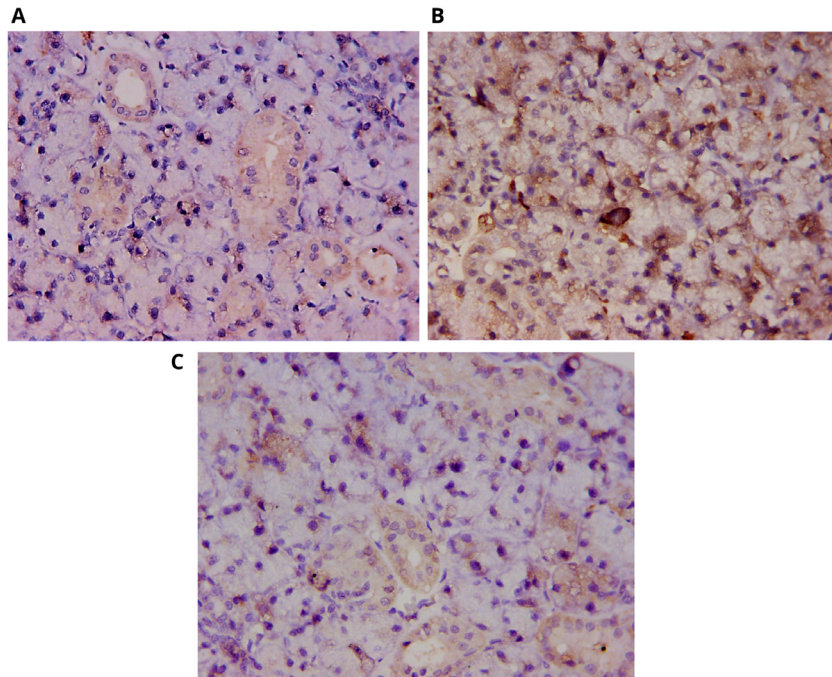


Figure 2. Photomicrographs showing Ki-67 immunoreactivity. (A) Control group, positive reaction to Ki-67 protein in the secretory acini and the wall of the blood vessels; (B) DXR group, increased reactivity of Ki-67 in the secretory acini together with the nuclear and perinuclear reactivities; (C) DXR+EGF group, decreased Ki-67 immunoreactivity in the acini. DAB, orig. mag. X400.

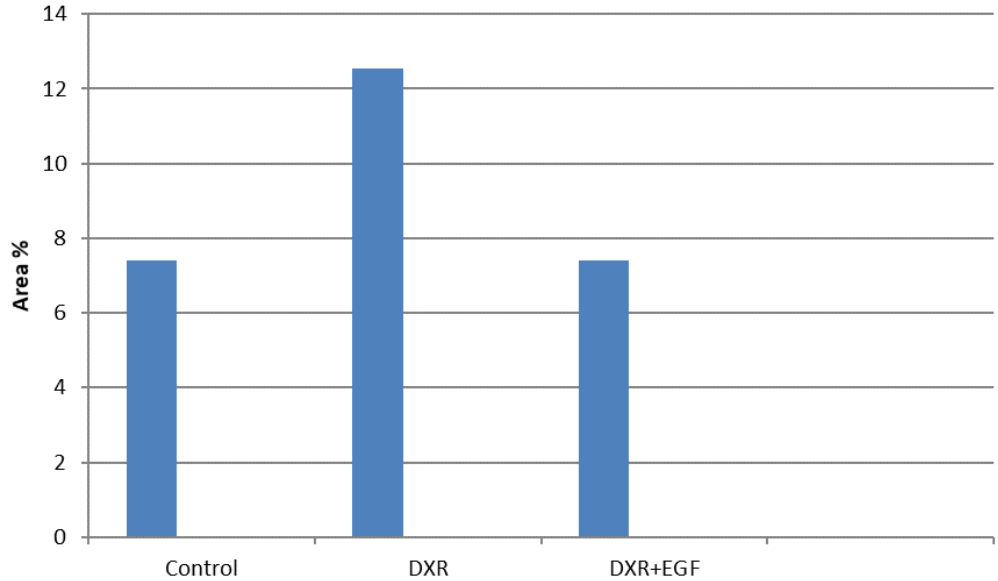


Figure 3. Area percent of Ki-67 reactivity in the submandibular salivary glands of all groups.

The tissue sections of the DXR+EGF group revealed a remarkable decrease in Ki-67 antigen expression in the acinar cells in comparison to the DXR group. Conversely a slight increase in immunoreactivity to the proliferation antigen appeared in the ductal profiles. Nevertheless, the immunoreactivity seemed to be very similar to that of the control group (Figure 2C).

Post Hoc Tukey HSD test comparing between the groups showed that the difference between the control group and DXR+EGF group was not significant ($p > 0.05$). However, a significant increase was recorded between the DXR and control groups, and a significant decrease was recorded between DXR+EGF and DXR groups ($p < 0.01$; Table 1 and Table 2).

Discussion

In this study, the systemic injection of DXR in rats resulted in pathological structural alterations within the submandibular salivary gland tissue. Atrophied and degenerated acini with multiple cytoplasmic vacuolization were detected. The chemical composition of DXR leads to creation of free radicals and the stimulation of oxidative stress, which is considered the main factor of cellular damage (Saad *et al.*, 2001). DXR also initiates an inequity between free oxygen radicals and antioxidants. This disturbs the oxidant-antioxidant system, leading to tissue damage that is manifested by lipid peroxidation and protein oxidation within the tissue (Karaman *et al.*, 2006).

Mitochondrial degeneration possibly is the primary cause of the intracytoplasmic vacuolizations shown repeatedly in parenchymal cells of both acini and ducts. Disturbance in cellular metabolism and sodium ions entering the cell have also been reported to cause this damage. This osmotic effect initiates degradation of large macromolecules within the injured cell and leads to the presence of cytoplasmic vacuoles. Furthermore, other cytoplasmic vacuolations might be due to degeneration of

Table 1. Area percentage of Ki-67 immuno-expression in different groups.

	Control	DXR	DXR+EGF	P- value
Minimum	5.486	9.958	4.42	0.001
Median	6.96	12.13	5.62	
Maximum	8.731	15.118	9.67	
Mean	7.399	12.538	6.277	
Standard Deviation	1.118	1.661	2.243	
Standard Error	0.5	0.743	0.916	

Table 2. Tukey's Post Hoc Test for Ki-67 immuno-expression in different groups.

Tukey's multiple comparison	Significance (P>0.05)	Summary
Control vs DXR	0.003	Significant
Control vs DXR+EGF	0.778	Not significant
DXR vs DXR+EGF	0.0001	Significant

other cell organelles such as Golgi apparatus which appear as empty spaces (Ankily *et al.*, 2020).

In our study, the submandibular salivary glands of rats injected with EGF after DXR presented great improvement in the gland architecture. Resolution of vacuolar degeneration was noted apart from minute areas of microvesicles detected in the

parenchymal tissue. The acini and ducts cells were more alike to those of the control group. The anti-inflammatory response of EGF was evident in this current work and has been confirmed in previously conducted studies. [Berlanga et al. \(2002\)](#) recorded a protective effect of EGF on the intestine from ischemia/reperfusion injury. They noticed the marked reduction of inflammatory infiltrates (mainly neutrophils) in the intestinal tissue after EGF injection. They also registered decreased level of TNF- α (a major pro-inflammatory cytokine), which may contribute to the cytoprotective effect.

The healing potential of EGF was documented in several studies. It was prevalent in epithelial cell re-epithelialization, proliferation, migration and renewal of gastric glands during renal epithelium regeneration ([Flaquer et al., 2010](#)), gastric ulcer healing ([Tarnawski & Ahluwalia, 2012](#)), corneal epithelium ([Jeon et al., 2018](#)) and salivary glands ([Al-Ankily et al., 2018](#); [Shamel et al., 2017](#)).

EGF binding to EGF receptor results in auto phosphorylation of receptor tyrosine kinase and activation of signal transduction pathways that are included in the modulation of cellular division, differentiation and persistence. EGF assists epithelial cell regeneration and plays a vital role in dermal wound healing through motivation of proliferation and migration of keratinocytes ([Zeng & Harris, 2014](#)).

Ki-67 is localized during active phases of the cell cycle and its expression is used as a sign of proliferation rate ([Faur et al., 2015](#)). It is found in all multiplying cells (normal and up-normal cells) and has been shown to be an admirable proliferation marker to detect the growth rate of certain cell populations. It is also used as the proliferation indicator to evaluate several categories of tumors ([Brown & Gatter, 2002](#); [Do Prado et al., 2011](#); [Tadbir et al., 2012](#)).

[Dayan et al. \(2002\)](#) examined time related alterations in the proliferative capacity of parenchymal cells of human labial salivary gland using Ki-67 as a proliferative marker. They reported positive immuno-expression of Ki-67 within the acini and ducts of the glands in all groups. These findings were in agreement with our results as mild cytoplasmic immunoreactivity for Ki-67 protein was registered in the submandibular salivary gland tissue of the control group. Furthermore, it has been considered that Ki-67 protein localization are not binary as it is continuously decreased during G0 and G1 and is continuously increased from the start of S phase till mitotic exit ([Miller et al., 2018](#)).

Nonetheless, [Birajdar et al. \(2014\)](#) found Ki-67 expression in all cases of normal oral epithelium to be mainly presented in the parabasal layer where the numbers of proliferating cells were limited in comparison with the basal cell layer. Furthermore, [Hagiwara et al. \(2013\)](#) detected Ki-67 mainly in the parabasal cells and infrequently in the basal cells in the normal squamous epithelium.

Ki-67 proliferation index was found prominently reduced following chemotherapy treatment, showing the anti-proliferative effect on tumors ([Miller et al., 2003](#) and [Miller et al., 2006](#);

[Lee et al., 2008](#)). An unexpected finding in the current study was the significant increase in the expression of Ki-67 in the submandibular salivary glands of rats, particularly the secretory terminal portions, secondary to DXR in comparison with control group ($p < 0.01$).

[Sasaki et al. \(1987\)](#) studied Ki-67 in HeLa S3 cells (human cell line derived from cervical cancer cells), and showed an increase in Ki-67 antigen after treatment with DXR, as well as its continuous expression throughout the cell cycle. They hypothesized that this is due to the maintaining response of Ki-67 antigen in the cell cycle; interference in DNA replication might cause a reactive enhancement of the Ki-67 protein.

[Kausch et al. \(2003\)](#) found that the expression of Ki-67 is increased at G2/M, which is exactly the period during which DXR induces apoptosis. They suggested that DXR could have an inhibitory effect on Ki-67 protein production, which may induce apoptosis. However, cancer cells, in an attempt to survive this effect, increase their mRNA to produce more protein. Ultimately, the production of protein by the cell and induction of apoptosis by DXR reaches an equilibrium, the result of which has been a lack of change in the protein after DXR treatment.

These results were also constant with findings in human hepatocellular carcinoma in which DXR treatment caused the acceleration of cell cycle transition; at an early time point allowing cell cycle continuance, but finally leading to cell cycle arrest ([Choi et al., 2012](#)).

According to [Etemad-Moghadam et al. \(2013\)](#) a significant increase occurred in Ki-67 mRNA following incubation of cancer cells with DXR, but there was no change in the expression of its protein. However, they failed to explain the exact function and role of Ki-67 in proliferation and cell cycle.

Chemotherapy targets rapidly proliferating cells that are closest to blood vessels but poorly penetrated tumor cells located distal to functional blood vessels (hypoxic regions). Hypoxic cells do not respond to treatment because of the cytotoxic effects generated by oxygen-dependent free radicals. Surviving hypoxic cells in intervals between treatments might re-oxygenate and proliferate from enhanced supply of nutrients released from digestion of dead cells close to the blood vessels. [Saggar & Tannok \(2015\)](#) noted that DXR resulted in the highest increase in Ki-67 cells in reoxygenated surviving hypoxic cells.

[Hultman et al. \(2018\)](#) found that post DXR treatment the BE (2)-C (neuroblastoma cell line derived from human bone marrow) tumor growth presented a remarkable increase in Ki-67-index (from 43% to 64%; $p < 0.01$), thus indicating a move towards cycling cells by application of DXR. [Tredan et al. \(2007\)](#) previously determined the same hypothesis and found *in vitro* that quiescent (G0) tumor cells enter cell cycle after DXR treatment.

Unexpectedly, we found that Ki-67 proliferation marker expression decreased significantly in the DXR+EGF group in comparison to the DXR group ($p < 0.001$). Weak to mild cytoplasmic immunoreactivity for Ki-67 protein was shown in the

parenchymal tissue of the glands of the EGF supplemented group in a manner matching its expression in the control group. Although the expression was a bit stronger than the control, the statistical correlation was not significant ($P > 0.05$). The immunohistochemical results might be correlated with the ultrastructure findings, as binucleation was frequently encountered in DXR group displaying high expression of the proliferation marker, while being unidentified with EGF treatment of low antigen expression (Mansy *et al.*, 2020).

Comparable findings were reported by Fatimah *et al.* (2012), as they found EGF significantly decreased the pluripotent genes expression of cultured human amnion epithelial cells. It is likely that the mitogenic EGF did not favor abnormal proliferation, as had been unexpectedly detected in the current investigation secondary to DXR. In a previous study, a disruption in normal expression of EGF was found correlated with improved proliferation and differentiation of medial cells in developing palate and resulted in cleft palate in rat embryo (Abbott & Bimbaum, 1990).

Conclusions

We conclude that EGF has a cytoprotective and reparative effect against DXR induced changes on salivary gland tissue in

rats. DXR injection significantly increased Ki-67 immunoeexpression in the glandular tissue. However, exogenous EGF preserved the immunohistochemical expression of Ki-67 in the glands or restored it to approximately to the normal level.

Data availability

Underlying data

Figshare: The Role of Exogenous EGF on Ki-67 proliferation marker expression on Submandibular Salivary Gland of Albino Rats Receiving Doxorubicin, <https://doi.org/10.6084/m9.figshare.13042625.v4> (Shamel, 2020).

This project contains the following underlying data:

- Original, unedited light microscopy images in TIFF format
- Original, unedited Ki67 immuno-expression images in TIFF format
- Area percentage of Ki-67 immuno-expression for all 21 rats in excel sheet

Data are available under the terms of the [Creative Commons Attribution 4.0 International license](#) (CC-BY 4.0).

References

- Abbott BD, Bimbaum LS: **TCDD-induced altered expression of growth factors may have a role in producing cleft palate and enhancing the incidence of clefts after coadministration of retinoic acid and TCDD.** *Toxicol Appl Pharmacol.* 1990; **106**(3): 418–432.
[PubMed Abstract](#) | [Publisher Full Text](#)
- Al-Ankily MM, Shamel M, Bakr M: **Epidermal growth factor restores cytokeratin expression in rats with diabetes.** *J Res Med Dent Sci.* 2018; **6**(1): 196–203.
[Reference Source](#)
- Ankily M, Shamel M, Bakr M: **Epidermal Growth Factor Improves the Ultrastructure of Submandibular Salivary Glands of Streptozotocin Induced Diabetic Rats - A Qualitative Study.** *International Journal of Medical and Dental Sciences.* 2020; **9**(1).
[Publisher Full Text](#)
- Ayla S, Seckin I, Tanriverdi G, *et al.*: **Doxorubicin Induced Nephrotoxicity: Protective Effect of Nicotinamide.** *Int J Cell Biol.* 2011; **2011**: 390238.
[PubMed Abstract](#) | [Publisher Full Text](#) | [Free Full Text](#)
- Berlanga J, Prats P, Ramirez D, *et al.*: **Prophylactic use of Epidermal Growth Factor Reduces Ischemia/reperfusion Intestinal Damage.** *Am J Pathol.* 2002; **161**(2): 373–9.
[PubMed Abstract](#) | [Publisher Full Text](#) | [Free Full Text](#)
- Bielack SS, Erttmann R, Kempf-Bielack B, *et al.*: **Impact of scheduling on toxicity and clinical efficacy of doxorubicin: What do we know in the minineties?** *Eur J Cancer.* 1996; **32A**(10): 1652–1660.
[PubMed Abstract](#) | [Publisher Full Text](#)
- Birajdar SS, Radhika MB, Paremala K, *et al.*: **Expression of Ki-67 in normal oral epithelium, leukoplakic oral epithelium and oral squamous cell carcinoma.** *J Oral Maxillofac Pathol.* 2014; **18**(2): 169–176.
[PubMed Abstract](#) | [Publisher Full Text](#) | [Free Full Text](#)
- Brown DC, Gatter KC: **Ki67 protein: the immaculate deception?** *Histopathology.* 2002; **40**(1): 2–11.
[PubMed Abstract](#) | [Publisher Full Text](#)
- Choi SY, Shen YN, Woo SR, *et al.*: **Mitomycin C and doxorubicin elicit conflicting signals by causing accumulation of cyclin E prior to p21WAF1/CIP1 elevation in human hepatocellular carcinoma cells.** *Int J Oncol.* 2012; **40**(1): 277–86.
[PubMed Abstract](#) | [Publisher Full Text](#)
- Dayan D, Vered M, Sivor S, *et al.*: **Age-related changes in proliferative markers in labial salivary glands: a study of argyrophilic nucleolar organizer regions (AgNORs) and Ki-67.** *Exp Gerontol.* 2002; **37**(6): 841–850.
[PubMed Abstract](#) | [Publisher Full Text](#)
- do Prado RF, da Silva Machado AL, Dias Colombo CE, *et al.*: **Immunohistochemical study of the expression of fatty acid synthase and Ki-67 in salivary gland tumors.** *J Oral Pathol Med.* 2011; **40**(6): 467–475.
[PubMed Abstract](#) | [Publisher Full Text](#)
- Etemad-Moghadam S, Fouladde S, Azizi E, *et al.*: **In vitro study on the effect of doxorubicin on the proliferation markers MCM3 and Ki-67.** *J BUON.* 2013; **18**(4): 1062–1068.
[PubMed Abstract](#)
- Fatimah SS, Tan GC, Chua KH, *et al.*: **Effects of epidermal growth factor on the proliferation and cell cycle regulation of cultured human amnion epithelial cells.** *J Biosci Bioeng.* 2012; **114**(2): 220–7.
[PubMed Abstract](#) | [Publisher Full Text](#)
- Faul F, Erdfelder E, Buchner A, *et al.*: **Statistical power analyses using G*Power 3.1: Tests for correlation and regression analyses.** *Behav Res Methods.* 2009; **41**(4): 1149–1160.
[PubMed Abstract](#) | [Publisher Full Text](#)
- Faur AC, Sas I, Motoc AGM, *et al.*: **Ki-67 and p53 immunostaining assessment of proliferative activity in salivary tumors.** *Rom J Morphol Embryol.* 2015; **56**(4): 1429–1439.
[PubMed Abstract](#)
- Flaquer M, Romagnant P, Cruzado JM: **Growth factors and renal regeneration.** *Nefrologia.* 2010; **30**(4): 385–93.
[PubMed Abstract](#) | [Publisher Full Text](#)
- Ghosh J, Das J, Manna P, *et al.*: **The protective role of arjunolic acid against doxorubicin induced intracellular ROS dependent JNK-p38 and p53-mediated cardiac apoptosis.** *Biomaterials.* 2011; **32**: 4857–4866.
[PubMed Abstract](#) | [Publisher Full Text](#)
- Hagiwara S, Yamamoto N, Furue H, *et al.*: **Pathological analysis of Ki-67 and CD109 expression in tongue squamous cell carcinoma.** *J Oral Maxillofac Surg*

Med Pathol. 2013; **25**(3): 276–281.

[Publisher Full Text](#)

Hofmann K, Bucher P: **The FHA domain: a putative nuclear signalling domain found in protein kinases and transcription factors.** *Trends Biochem Sci.* 1995; **20**(9): 347–349.

[PubMed Abstract](#) | [Publisher Full Text](#)

Hultman I, Haeggbloom L, Rognmo I, *et al.*: **Doxorubicin-provoked increase of mitotic activity and concomitant drain of G0-pool in therapy-resistant BE(2)-C neuroblastoma.** *PLoS One.* 2018; **13** (1): e0190970.

[PubMed Abstract](#) | [Publisher Full Text](#) | [Free Full Text](#)

Jensen SB, Pedersen AM, Reibel J, *et al.*: **Xerostomia and hypofunction of the salivary glands in cancer therapy.** *Support Care Cancer.* 2002; **11**(4): 207–225.

[PubMed Abstract](#) | [Publisher Full Text](#)

Jeon S, Choi SH, Wolosin JM, *et al.*: **Regeneration of the corneal epithelium with conjunctival epithelial equivalents generated in serum- and feeder-cell-free media.** *Tissue Eng Regen Med.* 2018; **15**(3): 321–332.

Karaman A, Fadillioglu E, Turkmen E, *et al.*: **Protective effects of leflunomide against ischemia-reperfusion injury of the rat liver.** *Pediatr Surg Int.* 2006; **22**(5): 428–434.

[PubMed Abstract](#) | [Publisher Full Text](#)

Kausch I, Lingnau A, Endl E: **Antisense treatment against Ki-67 mRNA inhibits proliferation and tumor growth *in vitro* and *in vivo*.** *Int J Cancer.* 2003; **105**(5): 710–716.

[PubMed Abstract](#) | [Publisher Full Text](#)

Lee J, Im YH, Lee SH, *et al.*: **Evaluation of ER and Ki-67 proliferation index as prognostic factors for survival following neoadjuvant chemotherapy with doxorubicin/docetaxel for locally advanced breast cancer.** *Cancer Chemother Pharmacol.* 2008; **61**(4): 569–77.

[PubMed Abstract](#) | [Publisher Full Text](#)

Mansy M, Malak S, Mubarak RT, *et al.*: **The Effect of EGF on the Ultrastructure of Submandibular Salivary Glands of Albino Rats Receiving Doxorubicin.** *Annals of Dental Specialty.* 2020; **8**(1): 26–33.

[Reference Source](#)

Miller I, Min M, Yang C, *et al.*: **Ki67 is a Graded Rather than a Binary Marker of Proliferation versus Quiescence.** *Cell Press.* 2018; **24**(5): 1105–1112.e5.

[PubMed Abstract](#) | [Publisher Full Text](#) | [Free Full Text](#)

Miller WR, Dixon JM, Macfarlane L, *et al.*: **Pathological features of breast cancer response following neoadjuvant treatment with either letrozole or tamoxifen.** *Eur J Cancer.* 2003; **39**(4): 462–468.

[PubMed Abstract](#) | [Publisher Full Text](#)

Miller WR, White S, Dixon JM, *et al.*: **Proliferation, steroid receptors and clinical/pathological response in breast cancer treated with letrozole.** *Br J Cancer.* 2006; **94**(7): 1051–1056.

[PubMed Abstract](#) | [Publisher Full Text](#) | [Free Full Text](#)

Ohlsson B, Jansen C, Ihse I, *et al.*: **Epidermal Growth factor Induces Cell Proliferation in Mouse Pancreas and Salivary glands.** *Pancreas.* Department of Surgery, University Hospital. Lund, Sweden. 1997; **14**(1): 94–98.

[PubMed Abstract](#) | [Publisher Full Text](#)

Osikov MV, Telesheva LF, Likhacheva AG: **Effect of Local Application of Epidermal Growth Factor on Innate Immunity and Cell Composition of Destruction Focus in Experimental Thermal Injury.** *Bull Exp Biol Med.* 2014; **157**(3): 307–10.

[PubMed Abstract](#) | [Publisher Full Text](#)

Parment K, Zetterberg A, Ernerudh J, *et al.*: **Long-term immunosuppression in burned patients assessed by *in vitro* neutrophil oxidative burst (PhagoburstW).** *Burns.* 2007; **33**(7): 865–871.

[PubMed Abstract](#) | [Publisher Full Text](#)

Plaatz B, Kole A, Mastik M, *et al.*: **Protein synthesis rate measured with**

L-[1- ¹⁴C] tyrosine positron emission tomography correlates with mitotic activity and MIB-1 antibody-detected proliferation in human soft tissue sarcomas. *Eur J Nucl Med.* 1999; **26**(4): 328–332.

[PubMed Abstract](#) | [Publisher Full Text](#)

Saad SY, Najjar TA, Al-Rikabi AC: **The preventive role of deferoxamine against acute doxorubicin-induced cardiac, renal and hepatic toxicity in rats.** *Pharmacol Res.* 2001; **43**(3): 211–218.

[PubMed Abstract](#) | [Publisher Full Text](#)

Saggari JK, Tannock IF: **Chemotherapy rescues hypoxic tumor cells and induces their reoxygenation and repopulation - an effect that is inhibited by the hypoxia-activated pro-drug TH-302.** *Cancer Sci.* 2015; **106**(10): 1438–47.

Sasaki K, Murakami T, Kawasaki M, *et al.*: **The cell cycle associated change of the Ki-67 reactive nuclear antigen expression.** *J Cell Physiol.* 1987; **133**(3): 579–584.

[PubMed Abstract](#) | [Publisher Full Text](#)

Schluter C, Duchrow M, Wohlenberg C, *et al.*: **The cell proliferation-associated antigen of antibody Ki-67: a very large, ubiquitous nuclear protein with numerous repeated elements, representing a new kind of cell cycle maintaining proteins.** *J Cell Biol.* 1993; **123**(3): 513–522.

[PubMed Abstract](#) | [Publisher Full Text](#) | [Free Full Text](#)

Shamel M: **The Role of Exogenous EGF on Ki-67 proliferation marker expression on Submandibular Salivary Gland of Albino Rats Receiving Doxorubicin.** *figshare.* Figure. 2020.

<http://www.doi.org/10.6084/m9.figshare.13042625.v4>

Shamel M, Ankily M, Bakr M: **Epidermal growth factor restores normal levels of myosin expression in submandibular salivary glands of rats treated with botulinum toxin.** *Journal of Advanced Medical and Dental Sciences Research.* 2017; **5**(1): 5–9.

[Reference Source](#)

Shi SR, Liu C, Young L: **Development of an optimal antigen retrieval protocol for immunohistochemistry of retinoblastoma protein (pRB) in formalin fixed, paraffin sections based on comparison of different methods.** *Biotech Histochem.* 2007; **82**(6): 301–309.

[PubMed Abstract](#) | [Publisher Full Text](#)

Sobecki M, Mrouj K, Colinge J, *et al.*: **Cell-Cycle Regulation Accounts for Variability in Ki-67 Expression Levels.** *Cancer Res.* 2017; **77**(10): 2722–34.

[PubMed Abstract](#) | [Publisher Full Text](#)

Tadbir AA, Pardis S, Ashkavandi ZJ, *et al.*: **Expression of Ki67 and CD105 as proliferation and angiogenesis markers in salivary gland tumors.** *Asian Pac J Cancer Prev.* 2012; **13**(10): 5155–5159.

[PubMed Abstract](#) | [Publisher Full Text](#)

Tarnawski AS, Ahluwalia A: **Molecular mechanisms of epithelial regeneration and neovascularization during healing of gastric and esophageal ulcers.** *Curr Med Chem.* 2012; **19**(1): 16–27.

[PubMed Abstract](#) | [Publisher Full Text](#)

Tredan O, Galmarini CM, Patel K, *et al.*: **Drug resistance and the solid tumor microenvironment.** *J Natl Cancer Inst.* 2007; **99**(19): 1441–54.

[PubMed Abstract](#) | [Publisher Full Text](#)

Tretiakova MS, Wei W, Boyer HD, *et al.*: **Prognostic value of Ki67 in localized prostate carcinoma: a multi-institutional study of >1000 prostatectomies.** *Prostate Cancer Prostatic Dis.* 2016; **19**(3): 264–270.

[PubMed Abstract](#) | [Publisher Full Text](#) | [Free Full Text](#)

Yerushalmi R, Woods R, Ravdin PM, *et al.*: **Ki67 in breast cancer: prognostic and predictive potential.** *Lancet Oncol.* 2010; **11**(2): 174–183.

[PubMed Abstract](#) | [Publisher Full Text](#)

Zeng F, Harris RC: **Epidermal growth factor, from gene organization to bedside.** *Semin Cell Dev Biol.* 2014; **28**: 2–11.

[PubMed Abstract](#) | [Publisher Full Text](#) | [Free Full Text](#)

Open Peer Review

Current Peer Review Status: ? ✓ ✓

Version 1

Reviewer Report 08 January 2021

<https://doi.org/10.5256/f1000research.30035.r76741>

© 2021 Serag M. This is an open access peer review report distributed under the terms of the [Creative Commons Attribution License](#), which permits unrestricted use, distribution, and reproduction in any medium, provided the original work is properly cited.



Mahmoud Serag

Division of Prosthodontics, Department of General Dentistry, School of Dental Medicine, East Carolina University, Greenville, NC, USA

The research by Mansy *et al.* is an interesting study which examined the effect of Epidermal growth factor on salivary gland of albino rats receiving doxorubicin detecting ki67 expression as a proliferation marker.

The title of the study is sufficient and reflects the purpose of the study. The methods sections was more than sufficient and I think there is more than enough details that it can be shortened and only referencing is enough. Histological and immunohistochemical results figures were clear. The manuscript is structurally organized and well written but needed minor modifications in some areas as in the discussion which needed some correlation between other studies and the current study.

Conclusions were drawn adequately and the overall manuscript is well constructed and meets the criteria for indexing.

Is the work clearly and accurately presented and does it cite the current literature?

Yes

Is the study design appropriate and is the work technically sound?

Yes

Are sufficient details of methods and analysis provided to allow replication by others?

Yes

If applicable, is the statistical analysis and its interpretation appropriate?

Yes

Are all the source data underlying the results available to ensure full reproducibility?

Yes

Are the conclusions drawn adequately supported by the results?

Yes

Competing Interests: No competing interests were disclosed.**Reviewer Expertise:** Dentistry, Oral Health, Prosthodontics**I confirm that I have read this submission and believe that I have an appropriate level of expertise to confirm that it is of an acceptable scientific standard.**

Reviewer Report 07 January 2021

<https://doi.org/10.5256/f1000research.30035.r76739>

© 2021 Abdul-Salam Hamied M. This is an open access peer review report distributed under the terms of the [Creative Commons Attribution License](#), which permits unrestricted use, distribution, and reproduction in any medium, provided the original work is properly cited.

**Marwa Abdul-Salam Hamied** 

Department of Oral Diagnosis, College of Dentistry, Sulaimani University, Sulaimani, Iraq

The paper by Mansy *et al.* is clearly and accurately presented. They analyzed whether epidermal growth factor effect on ki-67 proliferation marker or not in the submandibular gland parenchyma of albino rats receiving DXR. The submandibular salivary glands of rats injected with EGF after DXR showed great improvement in the glandular tissue. It could be considered a novel treatment for human carcinogenicity and recovery. The title and abstract are appropriate for the content of the text. The figures clearly showed histopathological features and ki-67 expression. Furthermore, the article is well constructed, the experiments were well conducted, and the analysis was well performed.

Is the work clearly and accurately presented and does it cite the current literature?

Yes

Is the study design appropriate and is the work technically sound?

Yes

Are sufficient details of methods and analysis provided to allow replication by others?

Yes

If applicable, is the statistical analysis and its interpretation appropriate?

I cannot comment. A qualified statistician is required.

Are all the source data underlying the results available to ensure full reproducibility?

No source data required

Are the conclusions drawn adequately supported by the results?

Yes

Competing Interests: No competing interests were disclosed.

Reviewer Expertise: Molecular basis of Head and Neck cancers

I confirm that I have read this submission and believe that I have an appropriate level of expertise to confirm that it is of an acceptable scientific standard.

Reviewer Report 05 January 2021

<https://doi.org/10.5256/f1000research.30035.r75760>

© 2021 Hassan Shaikh M. This is an open access peer review report distributed under the terms of the [Creative Commons Attribution License](#), which permits unrestricted use, distribution, and reproduction in any medium, provided the original work is properly cited.



Mushfiq Hassan Shaikh 

Department of Otolaryngology-Head and Neck Surgery, Schulich School of Medicine & Dentistry, Western University, London, ON, Canada

Is the study design appropriate and is the work technically sound?

Answer: The study design is okay and the work is technically sound. However, reviewer has a concern about the experiment length. The authors have performed the drug experiment on rats for 7 days. Can the authors provide reference of such study length is used in any other previous studies? If so, please add those references in the manuscript.

If applicable, is the statistical analysis and its interpretation appropriate?

Answer: The statistical analysis and its interpretation was appropriate, however, the reviewer feels that authors should re-plot figure 3 using statistical software.

Are the conclusions drawn adequately supported by the results?

Answer: The conclusion drawn adequately, however need some addition and modification. the reviewer has discussed this in the report.

Reviewer's Report: This is an interesting study. Authors in this manuscript presented their study about the role of exogenous epidermal growth factor (EGF) on Ki-67 proliferation marker expression in the submandibular salivary gland on albino rats receiving doxorubicin. To understand the role of EGF in submandibular salivary gland, authors have selected albino rats for this study. The expression pattern of Ki-67 proliferation marker was tested in albino rats treated with doxorubicin, using immunohistochemistry (IHC) technique. The manuscript is structurally organized, however, the writing appears to lack clarity in several places. In the manuscript, especially in the 'Discussion' section, the authors have discussed, and referred to different interesting topics, however, in several places failed to correlate those information with the current study. This makes those information irrelevant to mention unless authors make some effort to show the relevance. Therefore, the reviewer feels that rewriting and reorganising the 'discussion' section in succinct manner would be needed to enhance the quality of the manuscript. The

reviewer has provided some suggestions below for the modification of the 'discussion' section. Similar suggestion would apply for the 'Methods' section, as the section is unnecessarily too long and in some cases lack proper scientific language use. The authors should consider rewriting the 'methods' section in succinct form as well. As the authors have demonstrated changes in the rat tissue after the injection of EGF, which is encouraging, but what does it mean, that is, what is the significance of doing this study? The authors should consider adding few sentences about the significance of this study in the manuscript.

The authors have performed this study on rat's epithelium, but drawn comparisons with human epithelial cells, which are considered two different species. Have the authors performed investigation and observed similar findings in human tissue? If not, then the authors should carefully conclude the study with their findings and make relevance with the human. Furthermore, the authors have performed the drug experiment on rats for 7 days, the reviewer is concerned about the length of the experiment. Can the authors provide reference of such study length is used in any other previous studies? If so, please add those references in the manuscript. Although this manuscript might have met the criteria for publication on this journal should the following several concerns be addressed properly.

1. The title of the manuscript looks too long, authors should consider meaningful shortening of title.
2. The background of the abstract needs more clarity. Rather than just copying the title here, authors should add two sentences on the background and significance of the study.
3. Under the 'methods' section of the abstract, what did the authors mean by 'immunohistochemical expression of Ki67 sections'? What is this 'Ki67 section'? Please clarify.
4. Under the 'results' section of the abstract, 'However, Ki-67 expression in the glandular tissue was restored to normal levels'. What did the authors mean by 'normal levels'? Similar term 'normal level' was used in Conclusion. What is the normal level of Ki67 expression? Please, clarify.
5. In the first paragraph of the 'Introduction' section, authors mentioned, Ki67 is 'used for investigations of many cancer types', can the authors clarify for what sort of investigations? Furthermore, 'Ki-67 has similar essential properties with the other proteins known to regulate cell cycle', can the authors explain, what are those essential properties?
6. In the third paragraph of the 'Introduction' section, 'The division activity measured by Ki-67.....', the authors should explain, what this 'division activity' meant here?
7. In the fifth paragraph of the 'Introduction' section, the sentence, 'Apart from xerostomia, 50% of the salivary glands of the patients showed ductal dilation, cyst formation, degenerated acini and inflammatory cell presence.' Did authors mean those conditions were seen in normal healthy patient or in cancerous patients? It is confusing here, please clarify.
8. In the sixth paragraph of the 'Introduction' section, '..... the role of exogenous EGF injection on the Ki-67 immuno-expression in submandibular salivary gland....', authors should consider rewriting this sentence, as this sounds confusing, especially, it sounds like role of EGF injection on Ki-67 expression.

9. In the first paragraph of the 'Methods' section, authors mentioned that they have followed institutional guidelines for animal study. Can the authors mention in detail what guideline their institution follows, is it Declaration of Helsinki guidelines ? If so, please mention that.
10. In the fourth paragraph of the 'methods' section, did the authors kept all 21 rats in one case of separate cages ? Please, clarify.
11. The authors should consider rewriting the 'methods' section in succinct but mention all necessary details, as this section is unnecessarily too long and lacks proper scientific language use.
12. Many places across the manuscript, authors used the term 'Ki67-immuno expression'. Please use, just Ki-67 expression, which will be sufficient and sounds better. Furthermore, authors should use a consistent term throughout the manuscript not interchange between 'Ki-67 immuno expressions' and 'Ki-67 immuno reactivity', as it becomes confusing. For example, in the fourth paragraph of the 'results section', authors mentioned Ki-67 immuno-expression, but in Figure 3, it was Ki-67 immuno-reactivity.
13. In the 2nd paragraph of the 'Results' section, 'DXR+EGF' group (group III) sections showed great enhancement in the structural features of the gland', what did the authors mean by 'enhancement in the structural features of the gland' here ? Were there increment in the number of structures or enlargement of structures ? Please, clarify.
14. In the 4th paragraph of the 'Results' section, 'DXR was found to increase the immune-expression of Ki-67 protein in the submandibular salivary gland.....' What did the author mean in this sentence, is not clear? Did the authors mean DXR increased the expression of Ki-67 ? If so, how or by which mechanism?
15. The authors should consider to remake figure 3, as this, at current state, does not provide much of information and rather confusing. Is the control here indicate 100% ? If so, what is Area % less than 8 ? Y axis numbers or percentages are confusing. The reviewer suggest the authors could use statistical programs such as, Graph Pad Prism, SPSS or R programming to plot this figure properly. Typically, Microsoft Excel is not considered as an ideal stat platform for publication. Furthermore, please add figure legend after title of the figure for Figure 3.
16. In table 1, authors mentioned 'Area percentage' but inside the table no percentage sign. Please, add percentage sign where appropriate.
17. In the 5th paragraph of the 'Results' section, it reads, 'increase in immune-reactivity to the proliferation antigen....'. Can authors clarify which 'Proliferation antigen' they are referring here ?
18. Many places across the manuscript, authors used 'not significant ($p>0.05$)'. Use of this form is a bit confusing while reading, therefore, reviewer suggests the author should only use p-value across the text if anything is significant, such as, ($p<0.05$). Alternatively, mention the exact p-value, in case of non-significant cases.

19. Under the 'Discussion' section, 4th, 5th and 6th paragraphs do not fit well in discussion section, authors may consider moving them to introduction section but in more briefly manner.
20. The paragraph 8 of the discussion section, authors referred about the Ki-67 expression in normal oral epithelium. How the authors justify the relevance with the current study providing the above information in this paragraph?
21. The paragraph 9 and 10 in the discussion section should be merged as one paragraph.
22. In paragraph 12 of the discussion section, authors starts the paragraph with 'These results were also consistent....'. What did the authors mean by 'These results' here? Which results authors referring to? Please, clarify as the whole sentence is unclear.
23. In paragraph 13 of the discussion section, authors talked about Ki-67 miRNA expression in another study. How the authors justify the relevance with the current study providing the above information in this paragraph?
24. In paragraph 14 of the discussion section, 'Chemotherapy targets rapidly.....functional blood vessel' , this sentence needs reference. Please, add reference.
25. In paragraph 17 of the discussion section, authors highlights the EGF effects in pluripotent gene expression. Please, justify the relevance of the above mentioned topic with the current study.
26. In Conclusion, please write in few sentences about the justification and significance of this current study.

Is the work clearly and accurately presented and does it cite the current literature?

Yes

Is the study design appropriate and is the work technically sound?

Partly

Are sufficient details of methods and analysis provided to allow replication by others?

Yes

If applicable, is the statistical analysis and its interpretation appropriate?

Partly

Are all the source data underlying the results available to ensure full reproducibility?

Yes

Are the conclusions drawn adequately supported by the results?

Partly

Competing Interests: No competing interests were disclosed.

Reviewer Expertise: Head and Neck Cancer, Molecular Biology, Immunotherapy, Genome editing, Cancer genomics, Translational research.

I confirm that I have read this submission and believe that I have an appropriate level of expertise to confirm that it is of an acceptable scientific standard, however I have significant reservations, as outlined above.

The benefits of publishing with F1000Research:

- Your article is published within days, with no editorial bias
- You can publish traditional articles, null/negative results, case reports, data notes and more
- The peer review process is transparent and collaborative
- Your article is indexed in PubMed after passing peer review
- Dedicated customer support at every stage

For pre-submission enquiries, contact research@f1000.com

F1000Research