



Contents lists available at ScienceDirect

## International Journal of Surgery Case Reports

journal homepage: [www.casereports.com](http://www.casereports.com)

# Chest wall reconstruction following axillary breast augmentation and desmoid tumor resection using capsular flaps and a form-stable silicone implant: A case report, diagnosis and surgical technique



Alexandre Mendonça Munhoz<sup>a,\*</sup>, Ary de Azevedo Marques<sup>b</sup>, José Ribas Milanez<sup>c</sup>, Rolf Gemperli<sup>d</sup>

<sup>a</sup> Hospital Sírio Libanês and Instituto do Câncer do Estado de São Paulo, São Paulo, Brazil

<sup>b</sup> Hospital Sírio Libanês, São Paulo, Brazil

<sup>c</sup> Hospital Albert Einstein and Hospital das Clínicas University of São Paulo, Brazil

<sup>d</sup> University of São Paulo, São Paulo, Brazil

## ARTICLE INFO

## Article history:

Received 11 February 2017

Received in revised form 14 May 2017

Accepted 15 May 2017

Available online 21 May 2017

## Keywords:

Case report

Breast augmentation

Breast reconstruction

Chest reconstruction

Desmoid tumor

Myocutaneous flap

Form-stable silicone implants

Complication

## ABSTRACT

**INTRODUCTION:** Chest desmoid tumors (CDT) are rare lesions characterized by fibroblastic proliferation from the connective tissue. Although CDT have been studied previously, no cases following subfascial transaxillary breast augmentation (TBA) have been described.

**PRESENTATION OF CASE:** The authors describe a case of CDT in a 28-year-old woman one year after TBA, which presented as a painful and progressive mass in the lower-inner right breast quadrant. MRI showed a soft-tissue tumor (6 × 3 × 4 cm) that affected the region of the right anterior costal margin, without signs of structural costal invasion. Patient was treated surgically, exposing the right costal-sternal region through an inframammary approach and resecting the CDT. The remaining capsular flap was mobilized into the defect and a form-stable silicone implant was utilized to cover the chest wall defect and achieve an adequate breast contour. The patient is currently in 5th year after chest reconstruction, with satisfactory results. Neither the tumor or the symptoms recurred.

**DISCUSSION:** CDT is an uncommon evolution following TBA. Although it is a rare disease, thoracic and plastic surgeons must be alert to avoid misdiagnosis. Defect reconstruction is necessary, mobilizing the capsular flaps and replacing the implants in order to obtain a satisfactory outcome.

**CONCLUSION:** Knowledge of this rare post-operative evolution is crucial, and early surgical intervention is warranted in order to avoid more aggressive treatment. This case report provides general knowledge of CDT, and may be used as guidance for early diagnosis and treatment.

© 2017 The Author(s). Published by Elsevier Ltd on behalf of IJS Publishing Group Ltd. This is an open access article under the CC BY-NC-ND license (<http://creativecommons.org/licenses/by-nc-nd/4.0/>).

## 1. Introduction

Breast augmentation (BA) has become one of the most frequently performed aesthetic procedures [1]. The transaxillary approach used for augmentation (TBA) is a well-known technique, with its main benefits related to the absence of incisions on the breast [2–5].

Desmoid tumors (DT) are rare benign lesions that occur at a rate of approximately 3.7 new cases per one million persons per year [6–8]. These tumors are characterized by fibroblastic proliferation from the connective tissue of the muscle and its overlying fascia [7,8]. Desmoid tumors of the chest (CDT) are much less frequent

and represent 8–10% of all DT cases, and involve local invasion of surrounding structures [9].

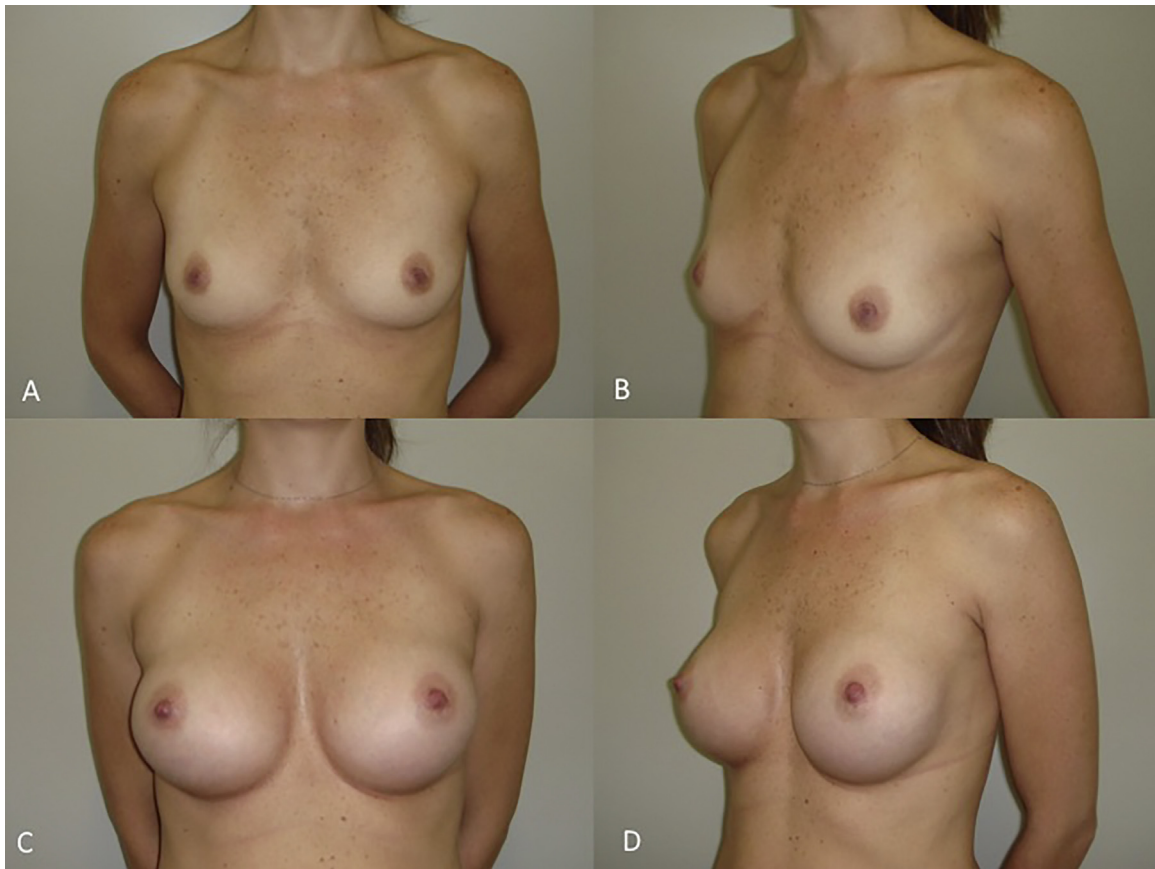
CDT following BA is a very rare disease and has been described in very few case reports [10,11]. Furthermore, all of these cases in the literature are related to the inframammary approach and located in the implant capsule. As of this writing no reports have been published on CDT following subfascial TBA and its surgical management and chest wall reconstruction. The case illustrates some aspects that may be useful for thoracic and plastic surgeons and may be used as guidance for surgical management.

## 2. Clinical case

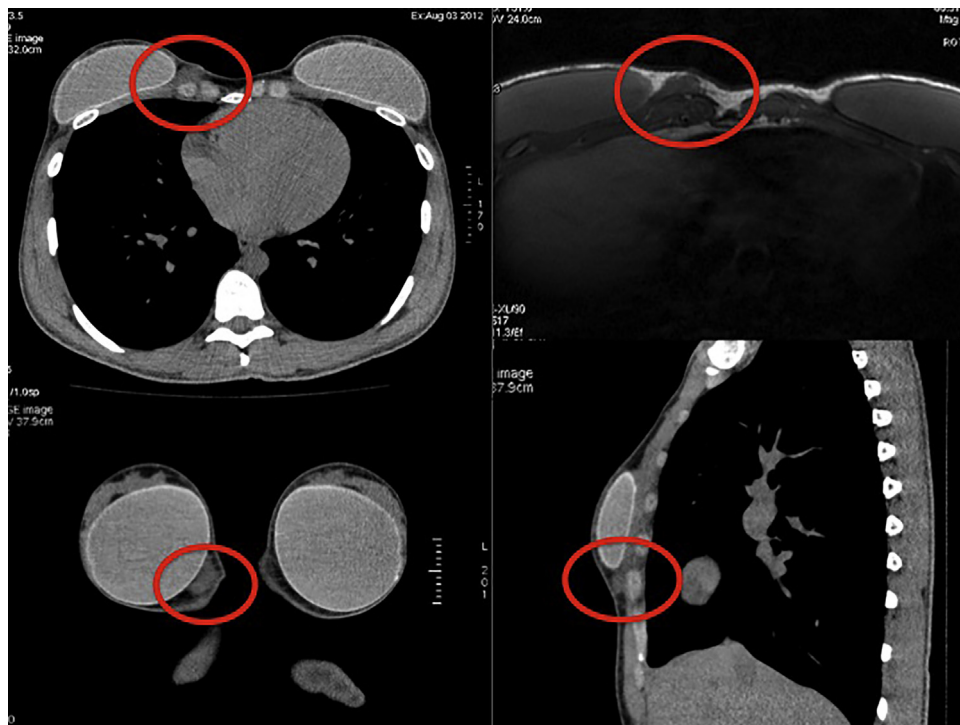
A 30-year-old woman with a bilateral hypomastia underwent subfascial TBA with texturized anatomic silicone implants (Natrele 410 MF style, 295cc) (Fig. 1a–d). One year after surgery, the patient noticed a painful mass in the medial lower part of her right breast. At that time a breast seroma or capsular contracture was sus-

\* Corresponding author at: Division of Plastic Surgery, Hospital Sírio-Libanês, Rua Mato Grosso, 306cj.1705-1706, 01239-040 Sao Paulo, SP, Brazil.

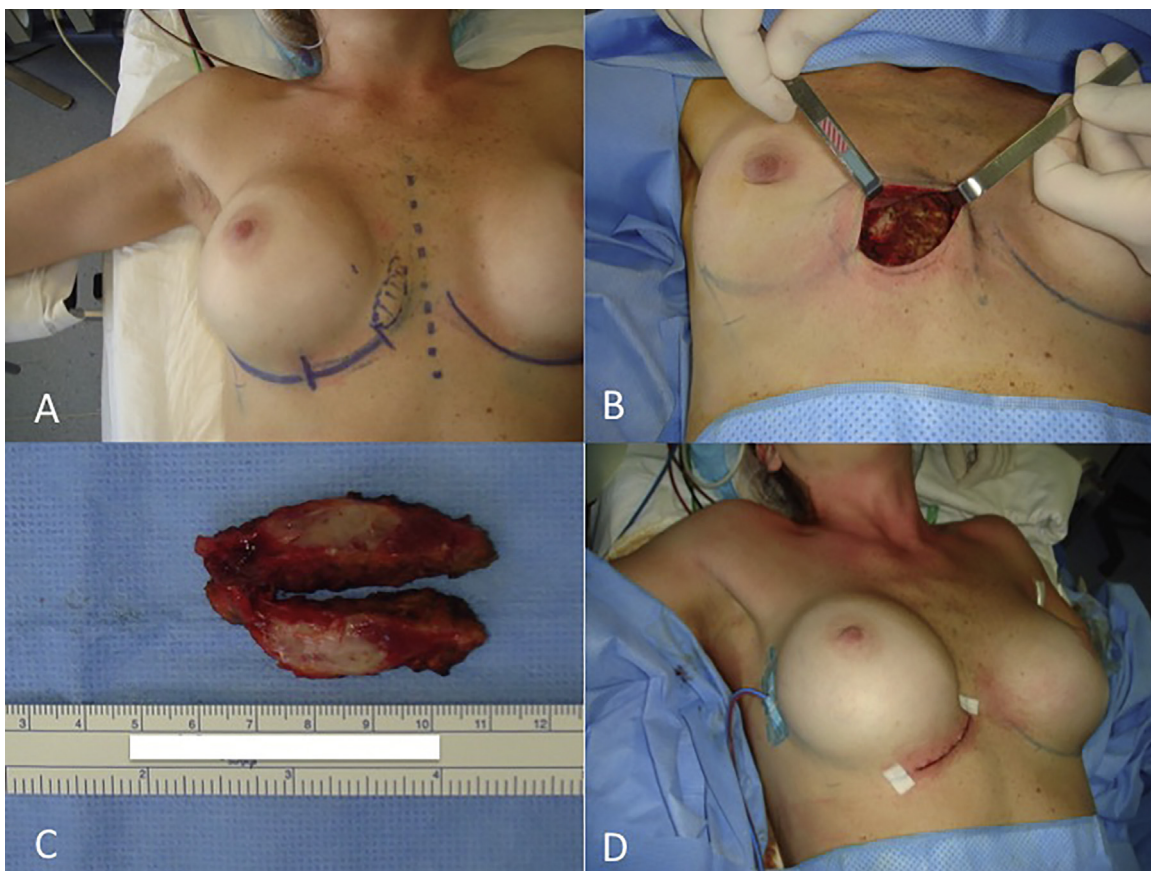
E-mail addresses: [munhozalex@uol.com.br](mailto:munhozalex@uol.com.br), [alexandremunhoz@hotmail.com](mailto:alexandremunhoz@hotmail.com) (A.M. Munhoz).



**Fig 1.** (A–D) Pre-operative frontal and left oblique views of a 28-year-old patient with hypoplastic breasts (A top left. B top right). Appearance six months after procedure, showing very good outcome. 255 cc Natrelle Style 410 MF implants were used bilaterally (C bottom left. D bottom right).



**Fig. 2.** Chest MRI showed a well-defined solid submuscular mass 6.1 cm × 2.4 cm × 5.1 cm in size with low to intermediate signal intensity in T1 imaging and high signal intensity in T2 imaging.



**Fig. 3.** (A–D) Intraoperative view of the right breast region. The inframammary approach was planned, near the parasternal region and approximately 0.5 cm above the anticipated new fold (a). Exposure of the right parasternal region was performed. The resection included the whole tumor and a peripheral margin of 1 cm of healthy tissue (b). Intraoperative view of the DT showing a firm tumor with white pattern (c). The chest wall defect was reconstructed with a larger form-stable texturized silicone implant associated with local advancement of capsular flaps (d).

pected. A breast ultrasound was performed and showed no sign of seroma. Magnetic resonance imaging (MRI) revealed a solid mass ( $6.1 \times 3.1 \times 4.1$  cm) with low/intermediate signal intensity in T1 and high signal intensity in T2. The mass exhibited high contrast medium enhancement without signs of infiltration of the fatty tissue or the costal cartilage (Fig. 2a and b). After discussing the case with thoracic surgeons and radiologists, the decision was made to plan a wide resection.

### 2.1. Surgical planning/reconstruction

Skin markings were planned with the patient in a sitting position: the current inframammary sulcus, the limits of the future pocket, and the new inframammary fold (IMF). Different options for larger implants were selected according to the location of the tumor. The inframammary approach was chosen and a 5 cm incision was planned near the parasternal region (Fig. 3a and b).

### 2.2. Surgical technique/reconstruction

Under general anesthesia, the right parasternal region was exposed and dissection continued down to the intercostal space and the previous subfascial implant pocket (Fig. 3b). The pectoralis major muscle was opened and the 5th and 6th costal cartilages were exposed on the right aspect of the sternal bone. A chest mass was seen which involved the 5th costal cartilage/sternal bone and extended 6 cm horizontally. The tumor ( $5 \times 3 \times 2$  cm) was fixed to the anterior chest wall. Based on frozen biopsy and perioperative findings, the thoracic surgeon decided to perform a wide excision

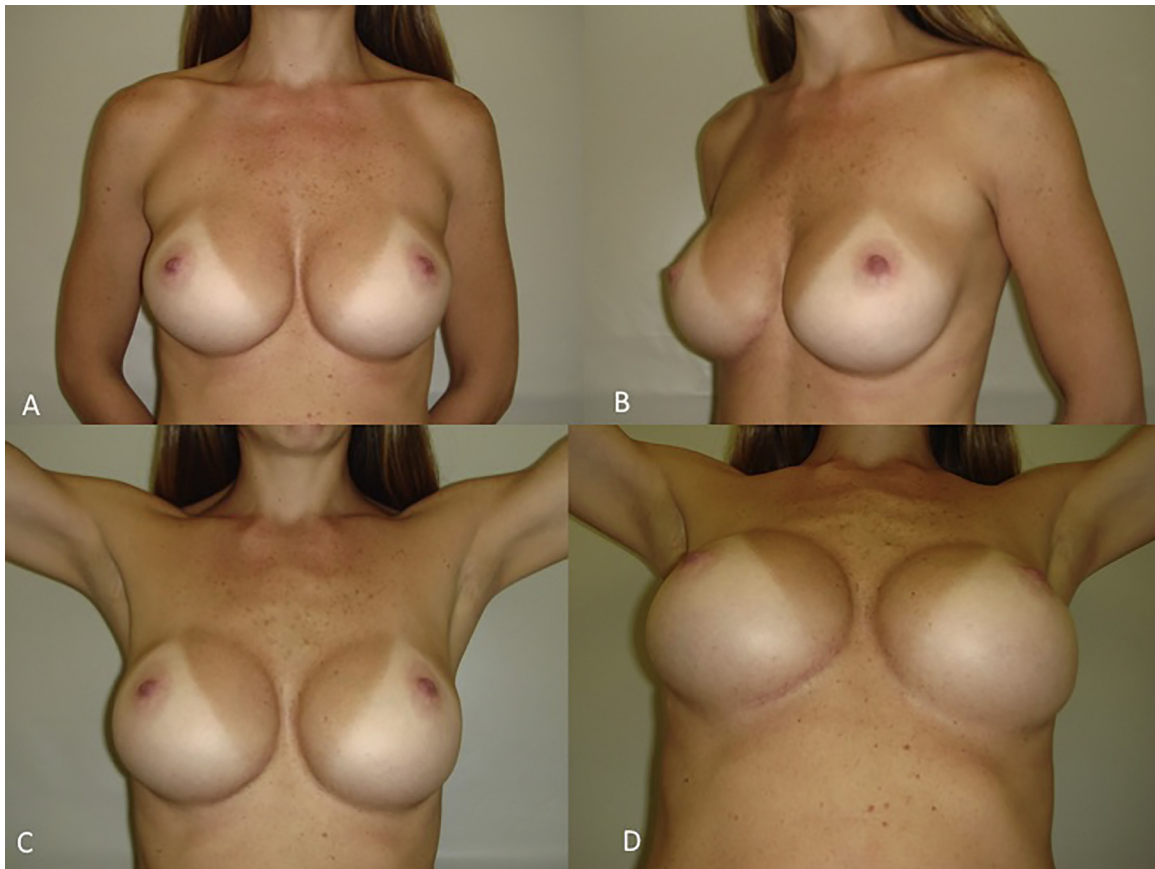
which included a peripheral margin of 1 cm of healthy tissue (anterior part of the costal cartilage, intercostal muscle, and the insertion of pectoralis major muscle) to achieve clear margins. (Fig. 3b)

The chest wall defect was reconstructed using a larger form-stable texturized silicone implant combined with local capsular flaps. To do so, a partial capsulotomy was performed in accordance with the size of the new implant. The lower pole of the implant was supported and covered by a capsular flap dissected from the posterior aspect of the capsule covering the pectoralis major muscle. The superior distal edge of the capsule was raised as an inferior-based flap from the chest wall up to the estimated level of the newly-created IMF. Sutures were placed to anchor the inferior skin flap to the deep fascia, securing the new position of the IMF. After the pocket was irrigated, a new implant (Natrelle 410 MF, 335cc) was selected considering factors such as height and weight of the thoracic wall, extension of resection, and patient preference. A three-layer closure was performed on the inframammary incision, with dermal and intradermal absorbable stitches (Fig. 3d). The pathological analysis confirmed the diagnosis of CDT. Macroscopically, the tumor was firm, white, and did not exhibit necrosis (Fig. 3c). Microscopically, the tumor was composed of spindle cells of variable cell density with few occurrences of mitosis and absence of atypical nucleus separations arranged in fascicles.

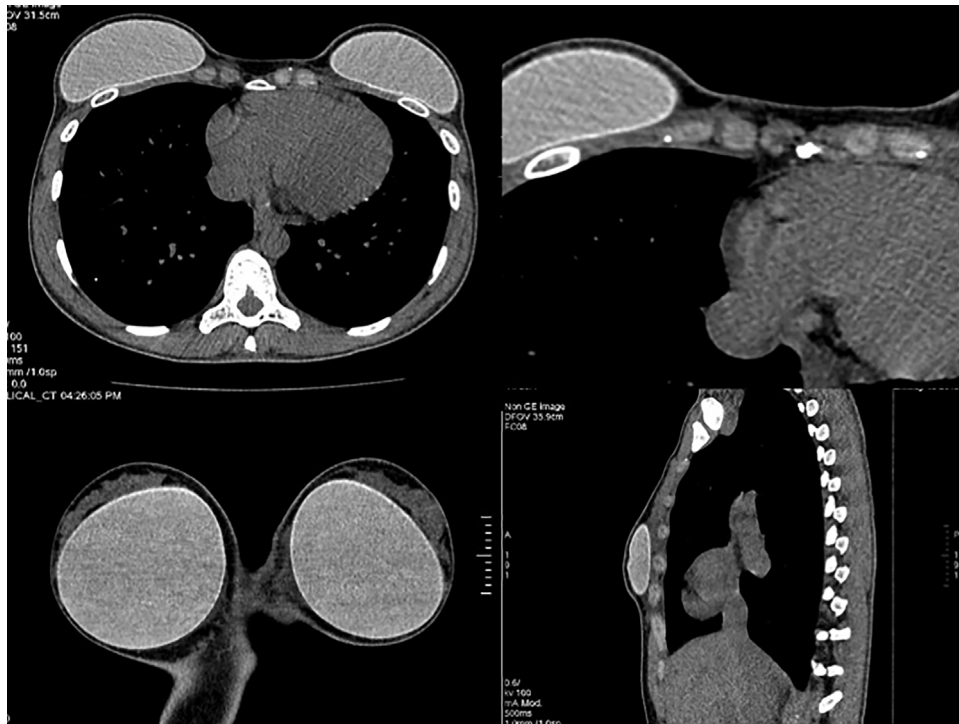
### 2.3. Postoperative period/outcome

The procedure achieved a satisfactory breast and chest wall contour (Fig. 4a–d). The patient is currently in her 5th post-operative year after CDT resection and chest/breast reconstruction. Neither





**Fig. 4.** (A–D) Appearance five years after procedure, showing very good outcome and satisfactory chest and breast contour. Bilateral 325-cc Natrelle Style 410 MF implants were used (a–d). Neither CDT nor symptoms recurred.



**Fig. 5.** (A–B) Chest MRI 58 months after resection, showing no local recurrence..

the CDT nor pain symptoms recurred. MRI 50 months after resection showed no local recurrence (Fig. 5a and b).

### 3. Discussion

First described in 1838 by Muller, DT are frequently associated with female sex, fertile age, familial adenomatous polyposis, and estrogen therapy [6–9]. In addition, some studies have stated that surgical trauma has been associated in 68–86% of abdominal and intra-abdominal DT [7].

DT most commonly occur in the abdominal wall, but these tumors may be classified as extra-abdominal or even intra-abdominal [6,7]. Extra-abdominal DT are less frequent and are usually confined to the connective tissue of the muscle, with a tendency to infiltrate [8,9]. In previous studies, chest DT present as firm masses with poorly-defined margins [9,12]. Abrão et al., in a series of 19 CDT, observed a mean age of 37 years at the time of resection, and most of the tumors in this series were located in the anterior chest wall and cervicothoracic transition [8]. In the present case, the patient was a young woman and had a history of surgical trauma due to previous TBA.

DT following BA are very rare, with fewer than 20 cases described in the literature [10,11]. In addition, there are no previous reports describing CDT following subfascial TBA. A significant majority of these cases were associated with silicone implants, and all utilized the inframammary approach [11]. According to Joeng et al., DT may develop after implantation of saline/silicone implants, and present as a breast/chest mass [10]. Additionally, when DT are diagnosed in association with breast implants, the fibrous capsule is implicated as a possible source. Matrai et al., in a review of CDT after BA, found that all cases arose in or around the capsule or were exclusively confined to the capsule [11].

Imaging exams such ultrasound or CT/MRI are effective tools for diagnosis as well as surgical planning. Usually DT appear as lesions with well-defined margins around the capsule, and demonstrate smooth variable echogenicity in ultrasound [9,12]. In MRI, they frequently exhibit low signal intensity relative to muscle in T1-weighted images, and variable signal intensity in T2-weighted images [12]. Although there are no specific imaging signals to differentiate DT from other solid tumors, this diagnosis should be considered in female patients with a chest mass and history of previous surgery or trauma. Despite these aspects, diagnosis can only be confirmed after histopathological analysis.

Wide local excision with surgical margins is the treatment of choice; incomplete resection is associated with high recurrence rates [8,9,13]. In a series of 23 patients, Matrai et al. observed that 19 patients underwent surgery, 15 with wide excisions and 3 with marginal excisions [11]. These authors also reported that 8 implants were removed, 5 were replaced, and 1 was left in place. Local recurrences occurred in 5 cases, and the median time for recurrence to occur was 34.2 months.

The objective of treatment is curative, especially for localized extra-abdominal small-volume tumors [8]. For DT with residual disease following resection, adjuvant radiotherapy yields benefits in terms of local control [9]. Abrão et al. observed 21% local recurrence in a series of CDT, all diagnosed through physical examination. In contrast, in a series of 146 patients Lev et al. concluded that there were no differences in long-term recurrence rates between patients with microscopically positive or negative margins [13].

Chest wall reconstruction may be achieved through primary repair, using synthetic materials or cutaneous and myocutaneous flaps [8,9]. In this present case, the chest wall defect was repaired with local capsular flaps associated with a larger silicone implant. To do so, an inframammary incision was planned to access the CDT

and to provide a better aesthetic outcome. This approach was chosen because of its well-known advantages such as simple access (ensuring accurate dissection and hemostasis over the tumor location), nondisruption of the breast parenchyma, and the ability to use any type/size of implant. In order to protect the implant and avoid post-operative implant visibility, we utilized a capsular flap from the previous implant.

The use of the capsule as a local flap has been described previously for implant coverage after breast reconstruction and to treat breast contour deformities [14,15]. This present case demonstrates clinical application of capsular flap coverage of the lower-medial part of the right breast implant. In cases with parasternal resection, replacement of larger silicone implants displaces the medial and inferior aspects of the peri-implant pocket. This makes it more difficult to achieve adequate soft-tissue coverage for the lower and medial poles of the implant, and leaves the skin as the only tissue available to support the implant [15]. Based on this experience, and as other authors have observed, the capsular flap provides simple and stable coverage for the implant and avoids its displacement [14,15].

Besides the benefits of the capsular flap, we utilized the most recent generation of form-stable silicone gel implants. These high-cohesive gel implants are form-stable, which means that if the implant ruptures, the gel remains inside the shell [16]. These implants are also available in a wide range of shapes, so the surgeon can select an implant which is best suited to each patient's anatomy and chest defect. Another important aspect is related to the low rate of wrinkling/rippling for these implants. It has been our experience (and other authors have observed) that form-stable implants maintain the shape and fill of the upper pole while resisting folding, especially in thin patients with insufficient soft-tissue coverage [16,17]. For this purpose, the pocket should be adjusted with capsular flaps to achieve an appropriate match between the implant and pocket volume. In this current study, the patient is currently in her 5th post-operative year after CDT resection and chest reconstruction and has a satisfactory chest wall and breast contour.

CDT is a very rare disease following TBA. Thoracic and plastic surgeons must be alert to avoid misdiagnosis, and early diagnosis and surgical management are crucial for a satisfactory outcome. Chest defect reconstruction should be individualized, and mobilization of the capsular flaps and implant replacement may be necessary to obtain a stable repair and a satisfactory result.

### SCARE guidelines

The present study has been reported in line with the SCARE criteria and is compliant with the SCARE Guidelines [18].

### Conflict of interest

Alexandre Mendonça Munhoz is consultant to Allergan Corporations and Establishment Labs and Rolf Gemperli is consultant to Ethicon, Johnson & Johnson Corporations.

### Funding source

We have no sources of funding and sponsor for the present research.

### Ethical approval

The present case report was approved by Plastic Surgery Department of the Hospital das Clínicas of the University of São Paulo.

## Consent

Written informed consent was obtained from the patient for publication of this case report and accompanying images.

## Authors contribution

Alexandre Mendonça Munhoz: study concept or design, data collection, data analysis or interpretation, writing the paper.

Ary Marques: data collection, data analysis.

José Ribas Milanez: data collection, data analysis.

Rolf Gemperli: data analysis, interpretation.

## Guarantor

Alexandre Mendonça Munhoz

## References

- [1] American Society of Plastic Surgeons, 2013 Cosmetic Plastic Surgery Statistics, 2013, Available at: <http://www.plasticsurgery.org/news/plastic-surgery-statistics/2013.html> (Accessed 8 May 2014).
- [2] F. Lista, J. Ahmad, Evidence-based medicine: augmentation mammoplasty, *Plast. Reconstr. Surg.* 132 (6) (2011) 1684–1696.
- [3] S.J. Pacella, M.A. Codner, The transaxillary approach to breast augmentation, *Clin. Plast. Surg.* 36 (1) (2009) 49–61.
- [4] A.M. Munhoz, K. Fells, E.G. Arruda, et al., Subfascial transaxillary breast augmentation without endoscopic assistance: technical aspects and outcome, *Aesthet. Plast. Surg.* 30 (2006) 503–512.
- [5] A.M. Munhoz, R. Gemperli, J.C. Sampaio Goes, Transaxillary subfascial augmentation mammoplasty with anatomic form-stable silicone implants, *Clin. Plast. Surg.* 42 (4) (2015) 565–584.
- [6] C.J. Shields, D.C. Winter, W.O. Kirwan, et al., Desmoid tumours, *Eur. J. Surg. Oncol.* 27 (2001) 701–6.
- [7] A.R. Kallam, B.V. Ramakrishna, G.K. Roy, K.R. Karthik, Desmoid tumours: our experience of six cases and review of literature, *J. Clin. Diagn. Res.* 8 (October (10)) (2014) 01–4.
- [8] F.C. Abrão, D.R. Waisberg, A. Fernandez, W.M. Bernardo, P.M. Pêgo-Fernandes, F.B. Jatene, Desmoid tumors of the chest wall: surgical challenges and possible risk factors, *Clinics* 66 (4) (2011) 705–708.
- [9] E. Bölke, H. Krasniqi, G. Lammering, R. Engers, C. Matuschek, S. Gripp, P.A. Gerber, G. Fischer, M. Peiper, S. Shaikh, W. Budach, K. Orth, Chest wall and intrathoracic desmoid tumors: surgical experience and review of the literature, *Eur. J. Med. Res.* 14 (June (6)) (2009) 240–243.
- [10] W.S. Jeong, T.S. Oh, H.B. Sim, J.S. Eom, Desmoid tumor following augmentation mammoplasty with silicone implants, *Arch. Plast. Surg.* 40 (July (4)) (2013) 470–472.
- [11] Z. Matrai, L. Toth, G. Gulyas, et al., A desmoid tumor associated with a ruptured silicone breast implant, *Plast. Reconstr. Surg.* 127 (2011) 1e–4e.
- [12] J. Cassilas, G.J. Sais, J.L. Greve, M.C. Iparraguirre, G. Morillo, Imaging of intra- and extraabdominal desmoid tumors, *Radiographics* 11 (1991) 959–968.
- [13] D. Lev, D. Kotilingan, C. Wei, M.T. Ballo, G.K. Zagars, P.W. Pisters, et al., Optimizing treatment of desmoids tumors, *J. Clin. Oncol.* 25 (2007) 1785–1791.
- [14] M. Brandstetter, T. Schoeller, P. Pulzl, et al., Capsular flap for coverage of an exposed implant after skin-sparing mastectomy and immediate breast reconstruction, *Plast. Reconstr. Aesthet. Surg.* 63 (2010) 1388–1390.
- [15] A.B. Berezovsky, E. Silberstein, Y. Shoham, Y. Krieger, Capsular flap: new applications, *Aesthet. Plast. Surg.* 37 (2013) 395–397.
- [16] G.P. Maxwell, M.H. Brown, P. Hedén, J. Luan, A.M. Munhoz, M. Carter, Delphi consensus recommendations: intraoperative technique and postoperative management of patients with natrelle 410 implants, *Plast. Reconstr. Surg. Glob. Open* 3 (11) (2015) e557.
- [17] P. Hedén, M.H. Brown, J. Luan, G.P. Maxwell, A.M. Munhoz, M. Carter, Delphi study consensus recommendations: patient selection and preoperative planning measurements for natrelle 410, *Plast. Reconstr. Surg. Glob. Open* 11 (2015) e556.
- [18] R.A. Agha, A.J. Fowler, A. Saetta, I. Barai, S. Rajmohan, D.P. Orgill, the SCARE group, The SCARE statement: consensus-based surgical case report guidelines, *Int. J. Surg.* 34 (2016) 180–186.

## Open Access

This article is published Open Access at [sciendo.com](http://sciendo.com). It is distributed under the [IJSCR Supplemental terms and conditions](#), which permits unrestricted non commercial use, distribution, and reproduction in any medium, provided the original authors and source are credited.