



A fatal case of severe systemic varicella zoster infection in a patient with chronic use of immunosuppressive agents for cutaneous vasculitis

Wei-Chen Lin^a, Ching Chang^a, Meng-Cheng Ko^b, Shu-Min Lin^{b,c,*}

^a Department of Internal Medicine, Chang Gung Memorial Hospital, Chang Gung University, School of Medicine, Taipei, Taiwan

^b Department of Thoracic Medicine, Chang Gung Memorial Hospital, Chang Gung University, School of Medicine, Taipei, Taiwan

^c Department of Respiratory Therapy, Chang Gung Memorial Hospital, Chang Gung University, School of Medicine, Taipei, Taiwan

ARTICLE INFO

Article history:

Received 15 July 2019

Received in revised form 20 September 2019

Accepted 5 November 2019

Keywords:

Varicella zoster

Systemic infection

Mortality

Vasculitis

Immunosuppressive agents

ABSTRACT

Acute varicella zoster virus (VZV) infection is a common condition in children, which is considered a mild, self-limited disease with diffuse skin vesicular rash. However, disseminated VZV infection with multiple organ involvement can occur in immunocompromised patients with impaired T cell immunity including solid or hematopoietic stem cell transplant recipients, receiving immunosuppressive therapy, leukemia, lymphoma, and HIV infection. Prompt antiviral therapy is mandatory in those immunocompromised persons. A 52 year-old man receiving chronic immunosuppressive drugs for his underlying leukocytoclastic vasculitis visited emergency department for diffuse skin vesicular rash that developed 4 days after contact with varicella zoster patients at his office. Despite prompt initiation of oral antiviral agents had been prescribed, rapid progression with septic shock, lactate acidosis, and disseminated intravascular coagulopathy occurred. The patient died within 24 h of intensive care unit admission. Varicella zoster infection commonly causes severe complications in adults receiving chronic immunosuppressive therapy. Post exposure prophylaxis varicella zoster immune globulin and early parenteral antiviral agents use after acute varicella virus infection may be mandatory in immunocompromised patients.

© 2019 Published by Elsevier Ltd. This is an open access article under the CC BY-NC-ND license (<http://creativecommons.org/licenses/by-nc-nd/4.0/>).

Background

Immunosuppressive drugs and disease modifying antirheumatic medicines are widely used in the treatment of connective tissue disease. However, usage of immunosuppressive medications is associated with increased risk of severe infection [1]. Varicella zoster infection can be caused by primary infection or reactivation. Risk of reactivation is related to age-related immune senescence or immunocompromised status. Complications include cutaneous dissemination and serious visceral organ involvement such as severe pneumonia, hepatitis and meningo-encephalitis. Post exposure varicella immune globulin and prompt antiviral therapy may contribute to decrease disease progression in immunocompromised patients [2,3]. In this case report, we described a fulminant clinical course of varicella zoster infection in a immunosuppressed host after contact with varicella zoster patients.

Case presentation

A 52-year-old man visit emergency department for diffuse vesicular skin rash over the trunk for one day (Fig. 1A) after contact with his co-workers diagnosed as varicella infection 4 days before. He also had headache, sore throat and nausea. He denied prior history of chicken pox. He took immunosuppressants including methotrexate (12.5 mg per week), azathioprine (100 mg per day) and prednisolone (10 mg per day) for his underlying cutaneous leukocytoclastic vasculitis since 5 years ago. Vesicle Tzank smear was performed. Multinucleated giant cells were found (Fig. 1B), which implied herpes virus infection. Serum laboratory examination showed: white blood cell count 4100/uL, hemoglobin 14.8 gm/dL, platelets 13,400/uL, serum creatinine 0.62 mg/dL, Aspartate transaminase (AST) 782 U/L (≤ 34), Alanine transaminase (ALT) 603 U/L (≤ 36), total bilirubin 0.4 mg/dL, prothrombin time 12.6 s (10–13) and C reactive protein 1.45 mg/L. Under the impression of varicella zoster complicated with hepatitis, oral famciclovir 500 mg three times per day was prescribed and his immunosuppressive drugs was discontinued by the doctor at emergency room. He was discharged home and outpatient clinics follow up was arranged. However, he visited emergency department again two days later for general malaise and nausea. Upon admission, his clinical status was acute ill looking and alert (E4V5M6). Vital sign

* Corresponding author at: Department of Thoracic Medicine, Chang Gung Memorial Hospital, 199 Tun-Hwa N. Rd., Taipei, Taiwan.
E-mail address: smlin100@gmail.com (S.-M. Lin).

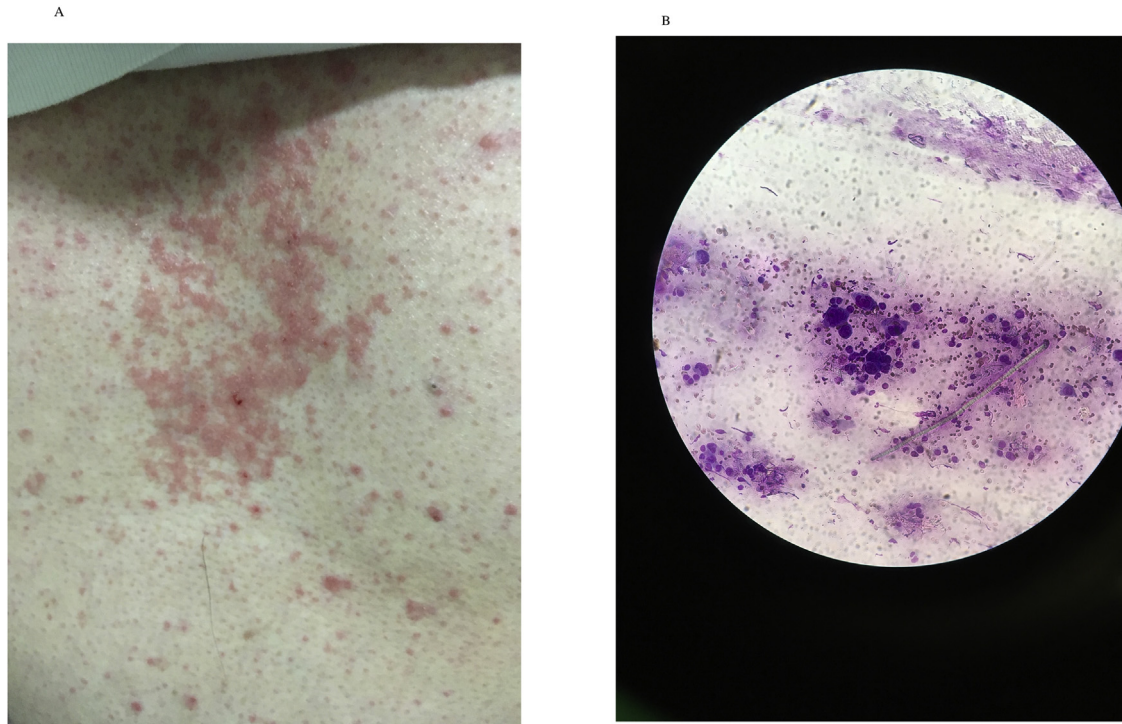


Fig. 1. A: Vesicular rash over trunk. B: Multinucleated giant cell on Tzank smear.

were: temperature 36.2 °C, blood pressure 54/46 mmHg, pulse rate 102 beats/minute, respiratory rate 20 cycles/min. Blood laboratory examination were: white blood cell 12700/uL, hemoglobin 15.4 g/dL, and platelets 61000/uL, prothrombin time 35.7 s, activated partial thrombin time 44.5 s (24–31), fibrinogen <50 mg/dL, AST 8989 U/L, ALT 6048 U/L, total bilirubine 2.0 mg/dL, indirect total bilirubin 1.5 mg/dL and serum creatinine 2.99 mg/dL. Blood arterial gas analysis showed PH 7.31 CO₂ 23 mmHg O₂ 83 mmHg HCO₃ 15.1 mm/L under nasal cannula oxgen flow 5 L/min. Serum tests for possible causes of acute hepatitis were all negative, including Hepatitis B surface antigen (HbsAg), antibodies against hepatitis C (anti-HCV), anti-hepatitis A immunoglobulin M (IgM) antibody, Epstein-Barr virus (EBV) viral capsid antigen IgM and immunoglobulin G (IgG), serum Cytomegalovirus (CMV) IgM and IgG, CMV pp65 antigen test, serum Herpes simplex virus IgM and IgG, and serum HSV DNA PCR. Only PCR test for VZV was positive during admission. Vesicular base and serum viral isolation also yielded the growth of VZV thereafter. In contrast, serum VZV IgM and IgG test were both negative. He was admitted to an intensive care unit due to septic shock, multiple organ failure, and disseminated intravascular coagulopathy. He received aggressive fluid resuscitation, broad-spectrum empirical antibiotics including glycopeptide and carbapenem, blood transfusion for correcting anemia and coagulopathy, and intravenous acyclovir for severe VZV infection. However, the clinical condition deteriorated rapidly. He was intubated 2 h after ICU admission because of comatose consciousness (E2M2V1), dyspnea, and profound shock. Brain CT was not done due to unstable hemodynamic status with high risk for transportation from the ICU to CT scan room. Lumbar puncture was not considered due to coagulopathy and absence of meningeal sign. However, lactate acidosis, disseminated intravascular coagulopathy and multiple organ failure were not reversed by aggressive treatment. He expired within 24 h after intensive care unit admission.

Discussion

Varicella zoster is a highly contagious virus, which is transmitted dominantly by air droplet. Fatal varicella zoster infection in

immunocompromised patients has been reported [4,5]. Early administration of intravenous antiviral therapy is associated with better disease resolution and may prevent VZV dissemination [6].

Post exposure live attenuated varicella vaccination is recommended for the healthy persons; in contrast, it is contraindicated in immunocompromised patient by current guideline because of risk of live vaccine related infection in immunocompromised hosts [7]. Varicella-zoster immune globulin with passive immunity is recommended as post exposure prophylaxis for immunocompromised patients.

Molecular diagnosis such as PCR test for VZV in blood sample may contribute to early diagnosis of disseminated infection of VZV before skin vesicular rash eruption in immunocompromised patients, which provides evidence for earlier use of parental antiviral therapy [8].

Although there is little reported data indicating the minimal inhibitory concentration of acyclovir treatment for disseminated varicella infection in immunocompromised patients, the drug plasma concentration after intravenous acyclovir (5 mg/kg every eight hours) is around ten times higher than oral acyclovir use (multiple doses of 400 mg) and is documented as the standard treatment of serious infection in immunocompromised hosts [9]. The administration of oral famciclovir treatment in immunocompromised patients with disseminated cutaneous and visceral involvement is not the standard of care.

In the present patient, he had chicken pox after recent contact with diseased patients and oral famciclovir was prescribed incorrectly for disseminated infection in immunocompromised host on his first visit of the emergency room. Rapid and fatal clinical course suggest the importance of early administration of intravenous antiviral therapy and close monitoring of organ function in immunocompromised patients with VZV infection.

Conclusion

This case report described a fulminant clinical course of severe VZV infection in an immunocompromised patient. Early diagnosis,

studies for possible visceral involvement, and prompt antiviral therapy are needed for management of VZV infection in immunocompromised patients.

Author statement

Manuscript: A Fatal Case of Severe Systemic Varicella Zoster Infection in a Patient with Chronic Use of Immunosuppressive Agents for Cutaneous Vasculitis.

Authorship Responsibility

All authors have seen and approved the content of the submitted manuscript. The paper presents original work not previously published in similar form and not currently under consideration by another Journal. If the paper contains material (data or information in any other form) that is the intellectual property and copyright of any person(s) other than the Author(s), then permission of the copyright owner(s) to publish that material has been obtained, and is clearly identified and acknowledged in the text of the paper. The authors followed ethics guidelines.

References

- [1] Hudson M, Bernatsky S, Suissa S. Anti-rheumatic drug use and risk of serious infections in rheumatoid arthritis. *Rheumatology* 2007;46(7):1157–60.
- [2] Tunbridge AJ, Breuer J, Jeffery KJ. Chickenpox in adults - clinical management. *J Infect* 2008;57(2):95–102.
- [3] Dworkin RH, et al. Recommendations for the management of herpes zoster. *Clin Infect Dis* 2007;44(Supplement_1):S1–S26.
- [4] Habuka M, et al. Fatal visceral disseminated varicella zoster infection during initial remission induction therapy in a patient with lupus nephritis and rheumatoid arthritis—possible association with mycophenolate mofetil and high-dose glucocorticoid therapy: a case report. *BMC Res Notes* 2018;11(1):165.
- [5] Fujisato S, et al. A fatal case of atypical disseminated herpes zoster in a patient with meningoencephalitis and seizures associated with steroid immunosuppression. *Am J Case Rep* 2018;19:1162–7.
- [6] Shepp DH, Dandliker PS, Meyers JD. Treatment of varicella–Zoster virus infection in severely immunocompromised patients. *N Engl J Med* 1986;314(4):208–12.
- [7] Marin M, et al. Prevention of varicella: recommendations of the Advisory Committee on Immunization Practices (ACIP). *MMWR Recomm Rep* 2007;56(RR-4):1–40.
- [8] de Jong MD, et al. Molecular diagnosis of visceral herpes zoster. *Lancet* 2001;357(9274):2101–2.
- [9] de Miranda P, Blum MR. Pharmacokinetics of acyclovir after intravenous and oral administration. *J Antimicrob Chemother* 1983;12(suppl_B):29–37.