



CASE REPORT

Testicular artery pseudoaneurysm: a case report [v1; ref status: indexed, <http://f1000r.es/2kw>]

William P Parker, Ajay K Nangia

Department of Urology, The University of Kansas Medical Center, Kansas City, KS, 66160, USA

v1 First published: 06 Jan 2014, 3:2 (doi: [10.12688/f1000research.3-2.v1](https://doi.org/10.12688/f1000research.3-2.v1))
 Latest published: 06 Jan 2014, 3:2 (doi: [10.12688/f1000research.3-2.v1](https://doi.org/10.12688/f1000research.3-2.v1))

Abstract

This is a case of an unusual cause of a testicular mass and the clinical features associated with its presentation and management. The patient presented with testicular pain and was found to have a testicular mass on ultrasound with a central 1cm anechoic region with arterial wave-form concerning for a pseudoaneurysm. The patient underwent orchiectomy with resolution of his symptoms. This case highlights the presentation of testicular artery pseudoaneurysm and outcome following orchiectomy.

Open Peer Review

Invited Referee Responses

	1	2	3
version 1 published 06 Jan 2014	report	report	report

- 1 **Nelson Bennett**, Lahey Clinic Medical Center USA
- 2 **Paul Turek**, The Turek Clinic USA
- 3 **Jay Sandlow**, Medical College of Wisconsin USA

Latest Comments

No Comments Yet

Corresponding author: William P Parker (wparker@kumc.edu)

How to cite this article: Parker WP and Nangia AK. **Testicular artery pseudoaneurysm: a case report [v1; ref status: indexed, <http://f1000r.es/2kw>]** *F1000Research* 2014, 3:2 (doi: [10.12688/f1000research.3-2.v1](https://doi.org/10.12688/f1000research.3-2.v1))

Copyright: © 2014 Parker WP and Nangia AK. This is an open access article distributed under the terms of the [Creative Commons Attribution Licence](#), which permits unrestricted use, distribution, and reproduction in any medium, provided the original work is properly cited. Data associated with the article are available under the terms of the [Creative Commons Zero "No rights reserved" data waiver](#) (CC0 1.0 Public domain dedication).

Grant information: The author(s) declared that no grants were involved in supporting this work.

Competing interests: No competing interests were disclosed.

First published: 06 Jan 2014, 3:2 (doi: [10.12688/f1000research.3-2.v1](https://doi.org/10.12688/f1000research.3-2.v1))

First indexed: 16 Jun 2014, 3:2 (doi: [10.12688/f1000research.3-2.v1](https://doi.org/10.12688/f1000research.3-2.v1))

Case history

A 34 year-old Caucasian man presented to the Emergency Department at the University of Kansas Medical Center (Kansas City, Kansas) with a 1 week history of right-sided orchalgia in December of 2012. The day prior to presentation the patient was admitted at an outside institution for presumed orchitis, where he was treated with intravenous levofloxacin 500mg. During that hospitalization a scrotal ultrasound was obtained which revealed hypervascularity of the right testicle but no masses or lesions within the testicle. He was discharged the next day, but due to persistent symptoms presented to our institution. He denied any constitutional symptoms and was voiding without difficulty or irritative symptoms. He additionally denied any prior genitourinary trauma or infections including any history of orchitis, prostatitis, urinary tract infection, or sexually transmitted infection. The patient was monogamous without any high-risk behavior. The patient had no past medical history and was on no prior medications. His examination revealed a swollen and indurated right testicle without involvement of the paratesticular structures. There was no discrete testicular mass palpable. Scrotal ultrasound revealed a region of hypoechoogenicity measuring 3.3cm x 2cm felt to represent an intratesticular hematoma (see [Figure 1](#)). Within this there was a 1cm central focus that demonstrated an arterial wave form with alternating reversal of flow, suggestive of a pseudoaneurysm (see [Figure 2](#)). Our differential diagnosis included abscess, testicular artery aneurysm/pseudoaneurysm, or testicular neoplasm. We counseled the patient on the ultrasonographic findings and our presumed diagnosis of testicular artery pseudoaneurysm. The patient was in a considerable amount of pain and was additionally concerned about the possibility of a testicular neoplasm and elected to undergo

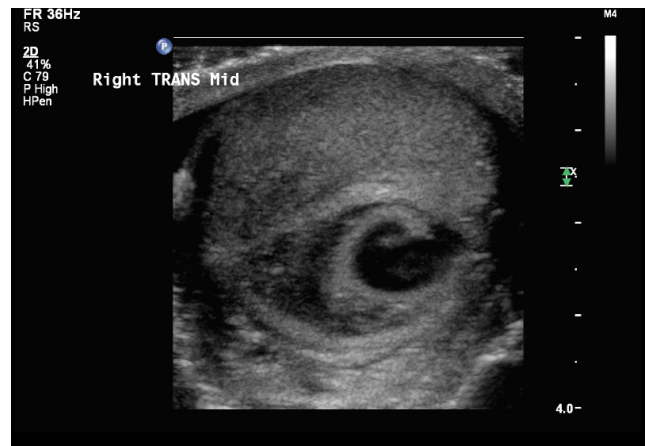

Figure 1. Scrotal ultrasound of the right testicle in transverse revealing a hypoechoic lesion within the central testicle with an anechoic central core.

radical orchiectomy. Tumor markers were obtained prior to orchiectomy and were within normal limits. He tolerated the procedure without any adverse event and was discharged to home with resolution of his pain on the first post-operative morning. Pathologic evaluation confirmed the presence of significant intraparenchymal hemorrhage within a background of chronic orchitis (see [Figure 3](#)). At the time of post-operative follow-up – 2 weeks after his orchiectomy – the patient was in excellent condition with complete resolution of his pain. His surgical incision was well healed and he had no evidence of intra-scrotal pathology.

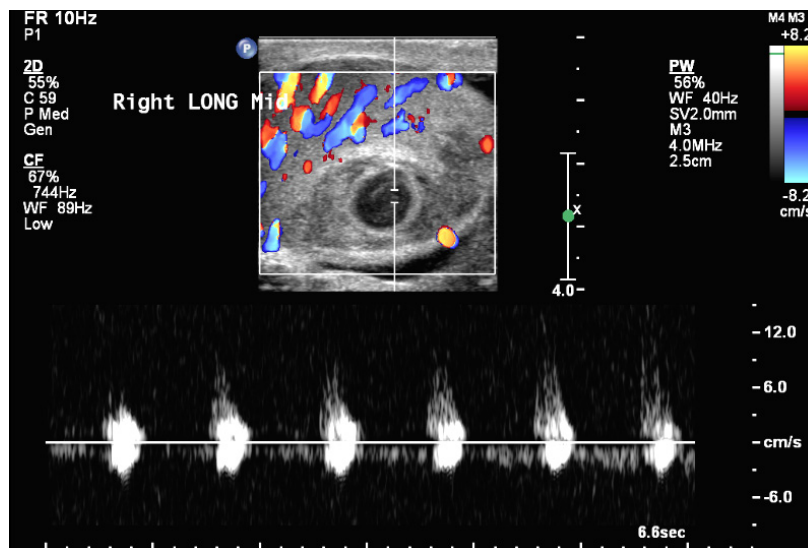


Figure 2. Doppler ultrasound of the right testicle in transverse reveals an arterial waveform within the center of the anechoic portion of the testicular mass.

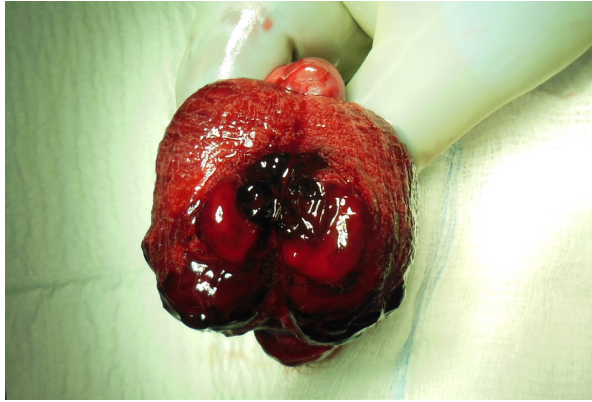


Figure 3. Gross section of the right testicle bi-valved with hematoma and surrounding intraparenchymal hemorrhage.

Discussion

Intratesticular hemorrhage is frequently associated with trauma. In the absence of trauma, testicular artery aneurysm and pseudoaneurysm have been described as an infrequent source of hematoma formation. To our knowledge there have been two cases of testicular artery aneurysm and two of pseudoaneurysm reported in the literature, with etiologies of trauma¹⁻³ and infection⁴.

As in previous cases of testicular artery aneurysm and pseudoaneurysm, the diagnosis was established on ultrasonography. Furthermore this case describes a second scenario in which sonographically diagnosed orchitis has progressed to this clinicopathologic entity⁴. Our management included radical orchiectomy - to rule out possible malignancy - and the patient recovered with complete resolution of his pain. This case supports orchitis as a risk factor for pseudoaneurysm

formation, the use of ultrasound for the diagnosis, and the use of orchiectomy as a potential treatment in patients with unremitting pain.

Certainly the management of this case is limited by the radical treatment offered – namely orchiectomy. We did consider and offer the patient a more conservative trial of observation for possible resolution. However in the absence of overwhelming evidence to rule out malignancy we felt that radical orchiectomy would not only establish our working diagnosis, but also rule out the possibility of testicular neoplasia. Regardless, at the time of final follow-up the patient was satisfied with his course of care and the outcome.

Consent

The patient was unable to be reached for consent and no next-of-kin information was available to contact the patient. The write-up does not contain sufficient information to identify the patient as this is a case based mainly on radiology and pathology findings. We have made numerous attempts to contact the patient and it appears that his contact information as provided at the time of treatment is no longer valid.

Author contributions

William Parker prepared the manuscript; Ajay Nangia edited the manuscript and participated in the clinical care of the patient.

Competing interests

No competing interests were disclosed.

Grant information

The author(s) declared that no grants were involved in supporting this work.

References

1. Dee KE, Deck AJ, Waitches GM: **Intratesticular pseudoaneurysm after blunt trauma.** *AJR.* 2000; **174**(4): 1136.
[PubMed Abstract](#) | [Publisher Full Text](#)
2. Zicheran JM, Mistry KD, Sarokhan CT, *et al.*: **CT angiography, sonography, and MRI of aneurysm of the testicular artery.** *AJR.* 2004; **182**(4): 1088–1089.
[PubMed Abstract](#) | [Publisher Full Text](#)
3. Reddy YP, Murphy JK, Sheridan WG: **Spontaneous aneurysm of the testicular artery.** *Br J Urol.* 1998; **82**(4): 599–600.
[PubMed Abstract](#) | [Publisher Full Text](#)
4. Mujoondar A, Maheshwari S, Zand KR, *et al.*: **Sonographic diagnosis of a ruptured intratesticular pseudoaneurysm secondary to orchitis.** *AJR.* 2007; **189**(1): W20–22.
[PubMed Abstract](#) | [Publisher Full Text](#)

Open Peer Review

Current Referee Status:



Referee Responses for Version 1



Jay Sandlow

Department of Urology, Medical College of Wisconsin, Milwaukee, WI , USA

Approved with reservations: 16 June 2014

Referee Report: 16 June 2014

doi:[10.5256/f1000research.3344.r5013](https://doi.org/10.5256/f1000research.3344.r5013)

The authors describe a fairly rare case of testicular artery pseudoaneurysm, presumably secondary to orchitis. The case history is complete and the figures are well-presented. Furthermore, based on the patient's history, age, and ultrasound findings, their management was not unreasonable. However, I would like them to describe in more detail the thought process that led to a radical orchiectomy, particularly since pseudoaneurysm was in their differential. Because the patient was of reproductive age, I wonder if it would have been possible to preserve some functioning testicular tissue. Based on the gross appearance of the specimen, it appears that at least a third of the testis was unaffected. How accurate is scrotal ultrasound in identifying a testicular artery pseudoaneurysm? Finally, looking back, is there something that the authors could have done to prevent a radical orchiectomy? This might be helpful for those of us facing this situation in the future. I think with some revisions of the Discussion, this case report should be acceptable.

I have read this submission. I believe that I have an appropriate level of expertise to confirm that it is of an acceptable scientific standard, however I have significant reservations, as outlined above.

Competing Interests: No competing interests were disclosed.



Paul Turek

The Turek Clinic, San Francisco, CA, USA

Approved with reservations: 24 January 2014

Referee Report: 24 January 2014

doi:[10.5256/f1000research.3344.r2990](https://doi.org/10.5256/f1000research.3344.r2990)

This case report is a classic "suspicious-looking-lesion-in-the-testicle" that is treated by removal and diagnosed definitively only after the fact, based on histology. The care provided was standard. However, besides learning about the existence of the lesion, there is no information in this case report that might help others PREVENT the extreme measure of radical orchiectomy for a benign lesion. What other diagnostic tests could have been done? Why wasn't partial orchiectomy considered in the treatment algorithm? The learning potential of this case is limited.

I have read this submission. I believe that I have an appropriate level of expertise to confirm that it is of an acceptable scientific standard, however I have significant reservations, as outlined above.

Competing Interests: No competing interests were disclosed.



Nelson Bennett

Institute of Urology, Lahey Clinic Medical Center, Burlington, MA, USA

Approved: 08 January 2014

Referee Report: 08 January 2014

doi:[10.5256/f1000research.3344.r2993](https://doi.org/10.5256/f1000research.3344.r2993)

This is a very nice presentation and description of a rare issue. The manuscript underscores that a complete scrotal/testicular ultrasound be carefully scrutinized. To further enhance the impact of the study, the authors may want to consider including the values of the testicular tumor markers.

Good Show.

I have read this submission. I believe that I have an appropriate level of expertise to confirm that it is of an acceptable scientific standard.

Competing Interests: No competing interests were disclosed.
