



Incidence and Risk Factors of the Complications Related to the Latarjet Surgery*

Incidência e fatores de risco das complicações da cirurgia de Latarjet

Marcio Cohen¹ Raphael Fonseca¹ Bernardo Gribel¹ Marcus Vinicius Galvão¹
Martim Monteiro¹ Geraldo Motta Filho¹

¹ Shoulder and Elbow Surgery Center, Instituto Nacional de Traumatologia e Ortopedia Jamil Haddad, Rio de Janeiro, RJ, Brazil

Address for correspondence Marcio Cohen, MD, Rua Almirante Guilhem, 127, Leblon, Rio de Janeiro, RJ, 22440-000, Brazil (e-mail: mcohen5@hotmail.com).

Rev Bras Ortop 2021;56(3):307–312.

Abstract

Objective The Latarjet procedure is a well-accepted treatment of shoulder instability. This technique is associated with a unique set of complications with overall rates of up to 30%. The purpose of the present study was to investigate the incidence and risk factors associated with complications after open Latarjet procedure.

Methods We retrospectively reviewed 102 patients submitted to open Latarjet procedure. Complications were divided into three types: clinical; graft-related; and screw-related. All of the patients were submitted to radiography and computed tomography (CT). The risk factors analyzed were gender, age, previous surgery, epilepsy, experience of the surgeon.

Results A total of 102 consecutive patients (108 cases) underwent the Latarjet procedure. The mean age was 33.7 years old (18 to 61 years old), with 88 males and 14 females. The overall complication rate was 21.2%, being 12% clinical-related, 7.4% graft-related, and 2.7% screw-related. The most frequent were anterior apprehension (eight cases) and lateral overhang of the graft in six patients. Computed tomography scan at a minimum of 6 months was performed in 79 cases (73%), and graft union occurred in 75 patients (94.9%). There were no cases of instability in the remaining four cases of nonunion. Ten patients (9.2%) required revision surgery. The risk factors associated with complications were epilepsy ($p = 0.0325$), experience of the surgeon ($p = 0.0499$) and patients ≥ 40 years old at the time of the surgery ($p = 0.0151$). There was no correlation with gender and previous surgery.

Keywords

- articular instability/ complications
- risk factors
- glenohumeral dislocation

* Study developed at the Shoulder and Elbow Surgery Center, Instituto Nacional de Traumatologia e Ortopedia Jamil Haddad, Rio de Janeiro, RJ, Brazil.

received
June 5, 2019
accepted
March 2, 2020
published online
September 30, 2020

DOI <https://doi.org/10.1055/s-0040-1712987>.
ISSN 0102-3616.

© 2020. Sociedade Brasileira de Ortopedia e Traumatologia. All rights reserved.

This is an open access article published by Thieme under the terms of the Creative Commons Attribution-NonDerivative-NonCommercial-License, permitting copying and reproduction so long as the original work is given appropriate credit. Contents may not be used for commercial purposes, or adapted, remixed, transformed or built upon. (<https://creativecommons.org/licenses/by-nc-nd/4.0/>)

Thieme Revinter Publicações Ltda., Rua do Matoso 170, Rio de Janeiro, RJ, CEP 20270-135, Brazil

Resumo

Palavras-chave

- instabilidade articular/complicações
- fatores de risco
- luxação glenoumeral

Conclusion The complication rate following the Latarjet procedure was 21.2%, with 9% requiring revision surgery. Epilepsy, age > 40 years old and experience of the surgeon were risk factors.

Objetivo A cirurgia de Latarjet é bem estabelecida para o tratamento da instabilidade anterior do ombro. Apresenta complicações específicas com taxas de até 30%. Nosso objetivo é avaliar a incidência e os fatores de risco associados às complicações após a cirurgia de Latarjet.

Métodos Analisamos retrospectivamente 102 pacientes submetidos ao procedimento. Dividimos as complicações em três tipos: clínicas, relacionadas ao enxerto e relacionadas aos implantes. Todos os pacientes foram submetidos a radiografias e tomografia computadorizada (TC). Os fatores de risco analisados foram gênero, idade, cirurgia prévia, epilepsia e experiência do cirurgião.

Resultados Um total de 102 pacientes consecutivos (108 casos) foram avaliados. A média de idade foi 33,7 anos (18 a 61 anos), com 88 homens e 14 mulheres. A taxa de complicações foi de 21,2%, sendo 12% clínicas, 7,4% relacionadas ao enxerto e 2,7% relacionadas ao implante. As mais frequentes foram apreensão anterior (oito casos) e posicionamento lateral do enxerto, em seis casos. A TC foi realizada com o mínimo de 6 meses em 79 casos (73%), evidenciando a consolidação do enxerto em 75 pacientes (94.9%). Nenhum caso de não união apresentou instabilidade. Dez pacientes (9.2%) precisaram de cirurgia de revisão. Os fatores de risco relacionados às complicações foram epilepsia ($p = 0.0325$), experiência do cirurgião ($p = 0.0499$) e pacientes ≥ 40 anos ($p = 0.0151$). Não houve correlação com gênero e cirurgia prévia.

Conclusão A taxa de complicações após a cirurgia de Latarjet foi de 21,2%, com 9% necessitando de revisão cirúrgica. Epilepsia, idade > 40 anos e experiência do cirurgião foram fatores de risco.

Introduction

Latarjet surgery has become an increasingly frequent option for the treatment of anterior glenohumeral instability.¹ Its main indications are glenoid bone injury, surgical revisions and in contact sports athletes. There are numerous described technical variations, but the basic principle of the procedure is the transfer of the coracoid process along conjoint tendon to the anterior glenoid border through an open or arthroscopic route.

Although the literature is clear in showing consistent joint stabilization results, few studies report the risk factors and incidence of Latarjet complications, which ranges from 0 to 30%.²⁻¹² The most frequently reported complications include neurological injury, infection, instability recurrence, fracture and graft pseudoarthrosis. In addition, the treatment of these complications often requires a surgical revision.

Shah et al.⁵ observed 10% of neurological complications; the most common complication was the involvement of the axillary and musculocutaneous nerves. Athwal et al.⁶ showed graft fracture in 7% of patients, with 2 cases requiring surgical revision.

In addition to the surgical technique knowledge, some authors have identified risk factors associated with a higher chance of complications. For Gartsman et al.,⁷ advanced age was a risk factor, while Dauzère et al.⁸ correlated the experience of the surgeon with the rate of complications.

The present study aimed to highlight the incidence of complications from Latarjet surgery and to correlate it with possible risk factors.

Methods

Patients undergoing Latarjet surgery for anterior glenohumeral instability treatment from January 2012 to June 2018 in a single institution were retrospectively evaluated to highlight any occurred complication. This technique was indicated in cases of glenoid or bipolar bone defect, failure of previous surgery and in contact sports athletes. The inclusion criteria for the present study were patients undergoing the classic Latarjet surgery with the graft positioned lying down and submitted to outpatient clinical and radiological postoperative follow-up for a minimum period of 6 months.

Complications were divided into three types: clinical, graft-related and implant-related complications. Clinical complications included hematoma, infection (both superficial or deep), neurological injury, subscapular tendon lesion and instability recurrence (anterior apprehension or dislocation). Graft-related complications included lateral or medial positioning, intra- or postoperative fracture and nonconsolidation, whereas implant-related complications included malposition or breaking of one or two screws.

Subscapularis tendon integrity was assessed through a physical examination using the Gerber and lift off tests.

Radiological examination consisted of simple x-rays in true anteroposterior (AP) view of the shoulder, scapular view and axillary lateral view, as well as computed tomography (CT) scans.

Positioning was considered a complication when CT showed that the graft was > 1 mm lateral to the joint surface; the graft > 1 mm medial to the surface was deemed a complication only in case of instability recurrence. Graft pseudoarthrosis was defined as the absence of a bone beam between the graft and the glenoid at CT examination.

Evaluated risk factors included gender, age younger or older than 40 years old, epilepsy, history of previous shoulder surgery, and experience of the surgeon. To assess the experience of the surgeon, patients were divided in two groups: the first group was operated on during the first half of the study, whereas the second group was operated on later.

Surgical Technique

All of the patients were placed in the beach chair position and submitted to general anesthesia with brachial plexus block. Antimicrobial prophylaxis was performed during anesthetic induction with intravenous administration of first-generation cephalosporin for 24 hours.

A deltopectoral approach with ~ 7 cm in length from the coracoid process towards the axillary fold was used. The coracoid process was exposed and individualized after releasing the pectoralis minor muscle and the coracoacromial ligament. Osteotomy was performed immediately distal to the coracoclavicular ligaments attachments using a curved osteotome to obtain a graft with at least 20 mm in size. The inferior face of the coracoid process was then decorticated and prepared with two holes at a 1-cm distance from each other. The joint was accessed by means of horizontal division of the subscapularis muscle, between its middle and lower thirds, followed by a vertical capsulotomy. The antero-inferior border of the glenoid was prepared with labral resection and decortication. The coracoid process was positioned lying down and fixed with two screws. In all cases, screw sizes ranged from 30 to 36 mm. There was no capsular repair in 59 cases. In 37 patients, the coracoacromial ligament was preserved and sutured in the joint capsule, resulting in an intra-articular graft; in 12 patients, the capsule was sutured with an anchor (Gryphon; DePuy Synthes, Warsaw, IN, USA), resulting in an extra-articular graft.

Postoperatively, patients were immobilized with a sling for 4 weeks. Passive mobilization began after 2 weeks. Formal physical therapy started 4 weeks after the procedure to gain range of motion. Strengthening exercises started after 2 months. Activities were totally resumed after 4 to 6 months.

Statistical Analysis

The chi-squared and Fisher tests were used for categorical variables, while paired and unpaired T tests were used for continuous variables. Statistical significance was defined as $p < 0.05$.

Results

During the analyzed period, Latarjet surgery was performed in 142 patients (148 shoulders). Of these, 19 patients who did not perform the required minimum follow-up and 21 who underwent the technique described as congruent arc were excluded.¹⁰ A total of 102 patients (108 shoulders) met the inclusion criteria.

The mean age was 33.7 years old (range, 18–61 years old), with 88 (86.3%) men (93 cases) and 14 (13.7%) women (15 cases). Latarjet surgery was the primary treatment for instability in 94 shoulders (87.1%). In 14 cases (12.9%), the procedure was performed as a revision due to previous surgery failure. A total of 11 patients (10.2%) had epilepsy. A total of 79 (73.1%) of the 108 cases underwent a CT scan after a minimum period of 6 months after surgery.

The mean follow-up period was 16.2 months (6–52 months). A total of 23 cases (21.2%) presented at least 1 complication, with 16 (14.8%) clinical, 8 (7.4%) graft-related, and 2 (1.8%) implant-related complications. Of this total, 10 revision procedures (9%) were required (► **Table 1**).

Clinical complications included 4 (3.7%) axillary neuropathies that resolved spontaneously in up to 6 months. There were 2 cases of infection; 1 was superficial (0.9%) and was treated with oral antibiotics, whereas the other was deep (0.9%) and was treated with surgical debridement and intravenous antibiotic therapy. Eight cases (7.4%) presented positive apprehension during the physical exam. One patient (0.9%), who had epilepsy, presented dislocation recurrence, and the deformity resulted in axial loss in both screws. A hematoma required drainage (0.9%), and 1 patient presented positive clinical tests indicating subscapularis injury (0.9%). One patient with positive apprehension had refractory pain and underwent an arthroscopic biopsy to diagnose infection, but no changes were found.

Graft-related complications included 6 cases (5.5%) of lateral positioning. Of these, one underwent lateral extremity regularization, one was repositioned, two were resolved with postconsolidation synthetic material removal and two required no surgical revision. There were three cases of medial positioning, but none of these patients presented instability, so they were not counted as complications. In addition, there were 2 cases (1.8%) of graft fracture detected at the first outpatient reassessment (► **Figures 1 and 2**); 1 was treated conservatively, whereas the other was submitted to resection of the fractured lateral fragment. Among the 79 cases submitted to CT, 75 (94.9%) presented graft consolidation and 4 (5.1%) had pseudoarthrosis. None of the patients with graft fractures or pseudoarthrosis developed instability recurrence.

Among implant-related complications, there were 2 cases (1.8%) of intraarticular screws; in the first one, the synthesis material was removed, but the other one evolved with early arthrosis and required a hemiarthroplasty.

Risk factors that significantly affected the complication rate were epilepsy, age > 40 years old and experience of the surgeon. Patients with epilepsy had 45.4% of complications compared with 18.5% in cases of traumatic instability ($p = 0.0325$). Patients > 40 years old presented 35.7% of complications

Table 1 Complications and respective surgical revisions

| Complications | n | % | Intervention |
|-------------------------------------|-----|-----|--|
| Clinical Complications | | | |
| Hematoma | 1 | 0.9 | Surgical drainage |
| Superficial Infection | 1 | 0.9 | Oral antibiotic treatment |
| Deep Infection | 1 | 0.9 | Debridement and intravenous antibiotic treatment |
| Anterior Apprehension | 8 | 7.4 | No intervention required |
| Anterior Dislocation | 1 | 0.9 | No intervention required |
| Axillary Neuropathy | 4 | 3.7 | No intervention required |
| Subscapularis Injury | 1 | 0.9 | No intervention required |
| Refractive Pain | 1 | 0.9 | Diagnostic arthroscopy |
| Implant-Related Complication | | | |
| Intraarticular screw | 2 | 1.8 | 1 RMS and 1 hemiarthroplasty |
| Graft-Related Complications | | | |
| Lateral Positioning | 6 | 5.5 | 2 RMS, 1 regularization and 1 repositioning |
| Medial Positioning* | 3 | 2.8 | No intervention required |
| Fracture | 2 | 1.8 | 1 lateral fragment resection |
| Pseudoarthrosis | 4** | 5.1 | No intervention required |

Abbreviations: n, absolute number of cases; RMS, synthetic material removal.

Source: hospital medical records.

*Not considered as complications since there was no development of anterior instability.

**from a total number of 79 patients undergoing computed tomography scans.

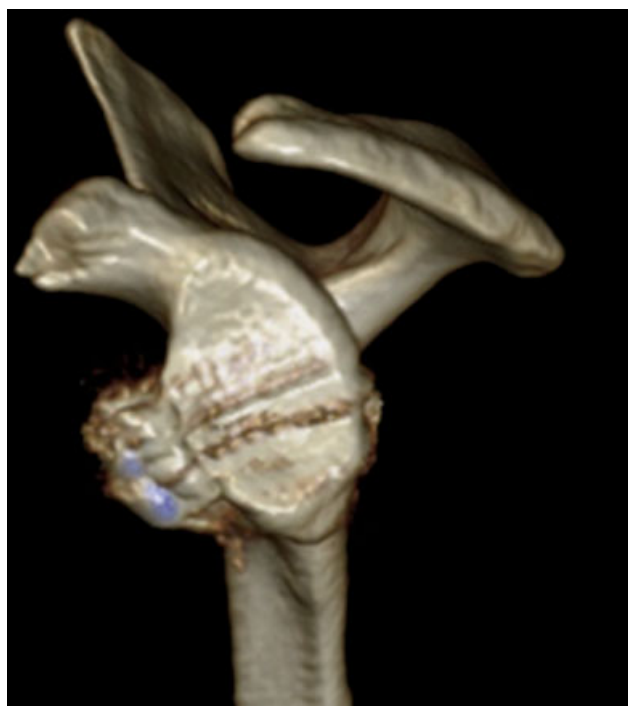


Fig. 1 Three-dimensional computed tomography scan in the immediate postoperative period showing a well-positioned graft.

compared with 19.4% of those < 40 years old ($p = 0.0151$). Likewise, the first half of the surgeries had a 27.7% complication rate versus 14.8% in the second half of the procedures ($p = 0.0499$). No statistical significance was observed regarding gender and history of previous surgeries (► **Table 2**).

Discussion

Latarjet surgery has become more and more indicated to treat anterior glenohumeral instability, resulting in an increase in reported complications. Unlike the arthroscopic surgery for capsulolabral repair, in which the main complication is dislocation recurrence, complications from Latarjet surgery are specific and their outcomes can be disastrous.¹³

Studies reporting Latarjet complications present some confusion regarding the definition of postoperative complications. Some authors differentiate problems from complications, while others divide complications as minor or major.^{5,11} We differentiate complications into three types: clinical, graft-related and implant-related complications. With a mean follow-up time of 16.2 months, we observed a complication rate of 21.2%, with only 9% of the cases requiring surgical revision. In a recent study, Domos et al.¹⁴ presented similar rates, with 21% of complications and 9% of surgical revision in patients > 40 years old submitted to the Latarjet technique.

Our series also presented results consistent with the literature regarding instability recurrence, with only 1 dislocation recurrence (0.9%) in a patient with epilepsy, and 8 (7.4%) subjects with positive apprehension at the physical examination.^{1,10,15–17} Unlike Griesser et al.,⁹ who identified the musculocutaneous nerve as the most frequently affected nerve in a systematic review, the most affected nerve in our series was the axillary nerve, with 4 cases (3.6%), as observed by Gartsman et al.⁷ All of the cases were neuropathies with complete recovery within 4 months.

There were 4 cases (5%) of pseudoarthrosis, one of which requiring removal of the screws. None of these cases evolved

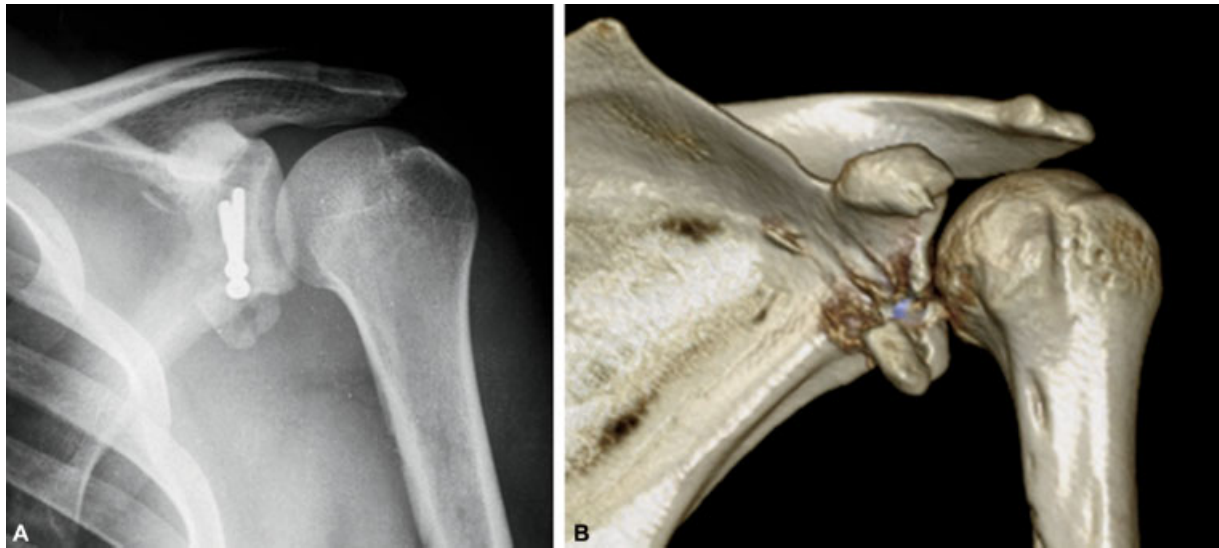


Fig. 2 Radiography (A) and three-dimensional computed tomography scan (B) 3 weeks after surgery showing graft fracture.

Table 2 Risk factors and *p*-value

| Risk Factor | Without complications | With complications | p-value |
|---------------------------|-----------------------|--------------------|---------|
| Etiology | | | |
| Epilepsy | 6 | 5 | 0.0325 |
| Trauma | 79 | 18 | |
| Previous Surgery | | | |
| Previous surgery | 10 | 4 | 0.2435 |
| First surgery | 75 | 19 | |
| Gender | | | |
| Female | 13 | 2 | 0.2271 |
| Male | 72 | 21 | |
| Experience of the surgeon | | | |
| First Half | 39 | 15 | 0.0499 |
| Second Half | 46 | 8 | |
| Age | | | |
| < 40 years old | 67 | 13 | 0.0151 |
| > 40 years old | 18 | 10 | |

Source: hospital medical records.

to instability. Shah et al.⁵ observed that some patients with nonunion of the graft were asymptomatic and did not consider them as complications.

Lateral graft positioning and poor positioning of the screws are risk factors for secondary arthrosis.^{18–20} There were 6 (5.5%) cases of laterally positioned graft, and 4 of them underwent surgical revision; in addition, there were 2 cases of intraarticular screws, with 1 rapidly evolving to secondary arthrosis with subsequent need for surgical revision and hemiarthroplasty.

Due to the technical complexity, the experience of the surgeon is associated with complications, as evidenced

by Dauzère et al.⁸ We found that patients operated on during the second half of the evaluated period had fewer complications. Other identified risk factors included epilepsy and age > 40 years old.^{14,21,22} Although some authors report an increased complication rate in patients with a history of previous surgeries, we did not observe such correlation.

The strengths of the present study include populational homogeneity and the relatively large sample. Since this is a retrospective study, its limitations are the complications inherent to this type of study and new complications may arise with a greater follow-up period.

Conclusion

The complication rate after Latarjet surgery was 21.2%, with only 9% of the patients requiring surgical revision. Epilepsy, age > 40 years old and the experience of the surgeon were risk factors for complications.

Conflict of Interests

The authors have no conflicts of interest to declare. There was no financial support from public, commercial, or non-profit sources.

References

- Allain J, Goutallier D, Glorion C. Long-term results of the Latarjet procedure for the treatment of anterior instability of the shoulder. *J Bone Joint Surg Am* 1998;80(06):841–852
- Silva J, Damas C, Sá M, Torres J. Análise morfológica da escápula e suas implicações no procedimento de Bristow-Latarjet. *Acta Ortop Bras* 2017;25(01):34–37
- Moura DL, Reis ARE, Ferreira J, Capelão M, Cardoso JB. Modified Bristow-Latarjet procedure for treatment of recurrent traumatic anterior glenohumeral dislocation. *Rev Bras Ortop* 2018;53(02):176–183
- Ikemoto R, Murachovsky J, Nascimento L, et al. Resultados da cirurgia de Latarjet no tratamento da instabilidade anterior

- traumática do ombro associada à erosão óssea da cavidade glenoidal - seguimento mínimo de um ano. *Rev Bras Ortop* 2011;46(05):553-560
- 5 Shah AA, Butler RB, Romanowski J, Goel D, Karadagli D, Warner JJ. Short-term complications of the Latarjet procedure. *J Bone Joint Surg Am* 2012;94(06):495-501
 - 6 Athwal GS, Meislin R, Getz C, Weinstein D, Favorito P. Short-term Complications of the Arthroscopic Latarjet Procedure: A North American Experience. *Arthroscopy* 2016;32(10):1965-1970
 - 7 Gartsman GM, Waggenspack WN Jr, O'Connor DP, Elkousy HA, Edwards TB. Immediate and early complications of the open Latarjet procedure: a retrospective review of a large consecutive case series. *J Shoulder Elbow Surg* 2017;26(01):68-72
 - 8 Dauzère F, Faraut A, Lebon J, Faruch M, Mansat P, Bonneville N. Is the Latarjet procedure risky? Analysis of complications and learning curve. *Knee Surg Sports Traumatol Arthrosc* 2016;24(02):557-563
 - 9 Griesser MJ, Harris JD, McCoy BW, et al. Complications and re-operations after Bristow-Latarjet shoulder stabilization: a systematic review. *J Shoulder Elbow Surg* 2013;22(02):286-292
 - 10 Burkhart SS, De Beer JF, Barth JR, Cresswell T, Roberts C, Richards DP. Results of modified Latarjet reconstruction in patients with anteroinferior instability and significant bone loss. *Arthroscopy* 2007;23(10):1033-1041
 - 11 Frank RM, Gregory B, O'Brien M, et al. Ninety-day complications following the Latarjet procedure. *J Shoulder Elbow Surg* 2019;28(01):88-94
 - 12 Da Silva LA, Lima AGC, Kautsky RM, Santos PD, Val Sella G, Checchia SL. Avaliação dos resultados e das complicações em pacientes com instabilidade anterior do ombro tratados pela técnica de Latarjet. *Rev Bras Ortop* 2015;50(06):652-659
 - 13 An VV, Sivakumar BS, Phan K, Trantalís J. A systematic review and meta-analysis of clinical and patient-reported outcomes following two procedures for recurrent traumatic anterior instability of the shoulder: Latarjet procedure vs. Bankart repair. *J Shoulder Elbow Surg* 2016;25(05):853-863
 - 14 Domos P, Lunini E, Ascione F, et al. Clinical and radiographic outcomes of open Latarjet procedure in patients aged 40 years or older. *J Shoulder Elbow Surg* 2019;28(09):e304-e312
 - 15 Hovelius L, Vikerfors O, Olofsson A, Svensson O, Rahme H. Bristow-Latarjet and Bankart: a comparative study of shoulder stabilization in 185 shoulders during a seventeen-year follow-up. *J Shoulder Elbow Surg* 2011;20(07):1095-1101
 - 16 Huguet D, Pietu G, Bresson C, Potaux F, Letenneur J. [Anterior instability of the shoulder in athletes: apropos of 51 cases of stabilization using the Latarjet-Patte intervention]. *Acta Orthop Belg* 1996;62(04):200-206
 - 17 Matton D, Van Looy F, Geens S. Recurrent anterior dislocations of the shoulder joint treated by the Bristow-Latarjet procedure. Historical review, operative technique and results. *Acta Orthop Belg* 1992;58(01):16-22
 - 18 Mizuno N, Denard PJ, Raiss P, Melis B, Walch G. Long-term results of the Latarjet procedure for anterior instability of the shoulder. *J Shoulder Elbow Surg* 2014;23(11):1691-1699
 - 19 Hovelius L, Sandström B, Saebö M. One hundred eighteen Bristow-Latarjet repairs for recurrent anterior dislocation of the shoulder prospectively followed for fifteen years: study II-the evolution of dislocation arthropathy. *J Shoulder Elbow Surg* 2006;15(03):279-289
 - 20 Lädermann A, Lubbeke A, Stern R, Cunningham G, Bellotti V, Gazielly DF. Risk factors for dislocation arthropathy after Latarjet procedure: a long-term study. *Int Orthop* 2013;37(06):1093-1098
 - 21 Raiss P, Lin A, Mizuno N, Melis B, Walch G. Results of the Latarjet procedure for recurrent anterior dislocation of the shoulder in patients with epilepsy. *J Bone Joint Surg Br* 2012;94(09):1260-1264
 - 22 Checchia SL, Doneux PS, Miyazaki AN, Leite AFM, Simmer Filho J, Menezes MVC. Tratamento cirúrgico da luxação recidivante anterior do ombro em pacientes convulsivos. *Rev Bras Ortop* 2000;35(09):340-346