

Received: 2021.08.02

Accepted: 2021.11.02

Available online: 2021.11.20

Published: 2021.12.29

# A Case of Native Joint Septic Arthritis Caused by *Bacteroides fragilis*

## Authors' Contribution:

Study Design A  
Data Collection B  
Statistical Analysis C  
Data Interpretation D  
Manuscript Preparation E  
Literature Search F  
Funds Collection G

ABCDEFG

Duong Tommy Hua CDE  
Jaclyn SpiegelBE  
Pei-Yu FuCDEF  
David Yuchno

Department of Internal Medicine, Harbor-University of California Los Angeles  
(UCLA) Medical Center, Torrance, CA, USA

**Corresponding Author:** Duong Tommy Hua, e-mail: [dhua@dhs.lacounty.gov](mailto:dhua@dhs.lacounty.gov)

**Financial support:** None declared

**Conflict of interest:** None declared

**Patient:** Male, 65-year-old  
**Final Diagnosis:** Sepsis  
**Symptoms:** Knee pain  
**Medication:** —  
**Clinical Procedure:** Arthrocentesis  
**Specialty:** Infectious Diseases

**Objective:** Rare disease

**Background:** *Bacteroides fragilis* (*B. fragilis*) is an uncommon cause of native joint septic arthritis (NJSA). It is an anaerobic gram-negative rod that is normally found in the oral cavity, gastrointestinal tract, genitourinary system, and skin, and thus is rarely isolated from the musculoskeletal system. Risk factors for *B. fragilis* NJSA include inflammatory arthritis, malignancy, sickle cell disease, and ischemic heart disease.

**Case Report:** We discuss a case of a 65-year-old man with coronary artery disease, heart failure, chronic kidney disease, and gout, who presented with 5 days of right knee pain, redness, swelling, and warmth. His history included a corticosteroid injection in the affected knee 2 months prior to presentation. The patient was febrile with a palpable right knee joint effusion on exam. Labs were significant for leukocytosis and elevated inflammatory markers. Synovial fluid was aspirated, which was diagnostic for septic arthritis, with cultures growing *B. fragilis*. Blood cultures were negative, so the infection was attributed to the prior joint injection. The patient was subsequently taken to the operating room for irrigation and debridement. He was started on metronidazole, but he unfortunately left against medical advice before treatment was complete and was lost to follow-up thereafter.

**Conclusions:** *B. fragilis* NJSA most often occurs in the setting of bacteremia or contiguous spread from a concomitant infection. Management involves antibiotics such as metronidazole and surgical drainage. Due to the paucity of data on an infection such as in the present case, the optimal duration of metronidazole is not well-established.

**Keywords:** Arthritis, Infectious • *Bacteroides fragilis* • Knee Joint

Full-text PDF: <https://www.amjcaserep.com/abstract/index/idArt/934266>




1670



—



1



17



## Background

Native joint septic arthritis (NJSa) is an uncommon condition, with an incidence rate of 12/100 000 person-years [1]. Mortality is variable depending on co-morbid conditions and causative organism, but a case series studying 109 patients with NJSa found a mortality rate of 5.6% [2]. The most common organisms isolated in septic arthritis are *Staphylococcus aureus*, *Streptococcus pyogenes*, and methicillin-resistant *Staphylococcus aureus*, accounting for 53%, 15%, and 13% of cases, respectively [3]. On the contrary, septic arthritis due to anaerobic bacteria, particularly *B. fragilis*, is exceedingly rare. For example, a review of 308 patients with native joint septic arthritis found only 2 patients who had *B. fragilis* as the causative organism [4]. *B. fragilis* NJSa is more often attributed to hematogenous spread, with detection of *B. fragilis* in the blood 65% of the time [4].

*B. fragilis* is an obligate anaerobe and gram-negative rod that is typically isolated from the oral cavity, gastrointestinal tract, genitourinary system, and skin [4]. Clinically significant infections caused by *B. fragilis* have been found in many areas throughout the body, including intra-abdominal, intestinal, hepatobiliary, skin and soft tissue, blood, lung, urinary, gynecologic organs, brain, cerebrospinal, oral, cardiac valve, and bone [5]. Risk factors for *B. fragilis* infection include inflammatory arthritis, malignancy, sickle cell disease, and ischemic heart disease [4].

We report a case of *B. fragilis* NJSa, which we attribute to direct inoculation from a prior knee injection in the setting of negative blood cultures, in a patient with multiple risk factors, including cardiac disease, kidney disease, and diabetes.

## Case Report

A 65-year-old man with a complex past medical history, including coronary artery disease with stent, heart failure, atrial fibrillation, sick sinus syndrome with a pacemaker, chronic kidney disease, diabetes mellitus, gout, asthma, hypertension, obstructive sleep apnea, anxiety, and prostate cancer status post prostatectomy, presented to the emergency room with a chief concern of 5 days of right knee pain associated with redness, swelling, and warmth. His symptoms had progressively worsened such that he was unable to bear weight on the affected leg. He denied any fevers or chills. Of note, 2 weeks prior to his presentation, he sought care for a gout flare of his right knee and was given colchicine and prednisone. He had undergone steroid injections in the right knee every 3 months, the last of which was 2 months prior to the current presentation. He denied intravenous drug use. His medication list included albuterol, fluticasone-vilanterol, linaclotide, losartan,

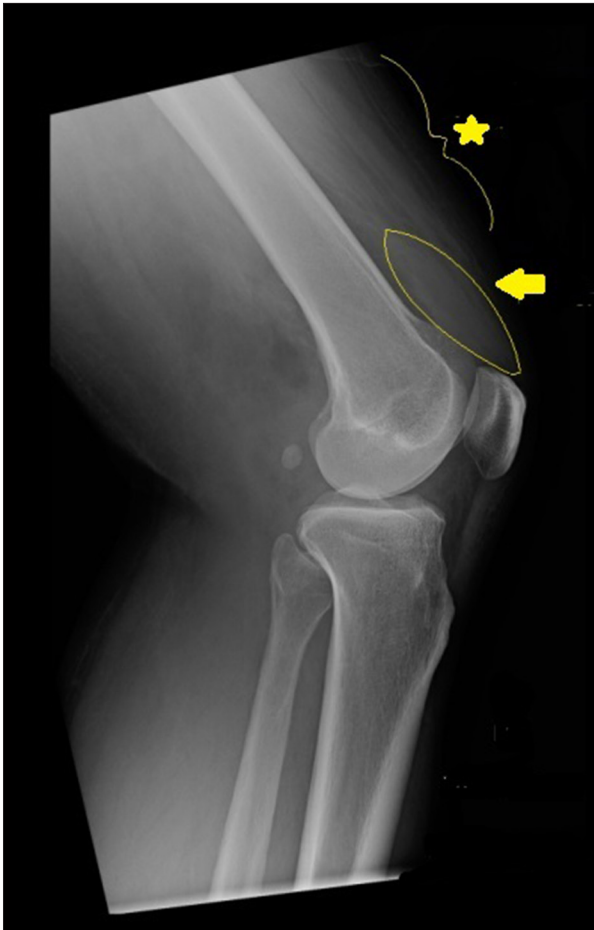amlodipine, famotidine, montelukast, furosemide, glipizide, clonazepam, pantoprazole, evolocumab, and febusostat.

His vital signs included a temperature of 38.5°C, heart rate of 80 beats per minute, blood pressure of 137/73 mmHg, respiratory rate of 16 breaths/minute, oxygen saturation of 98% on room air, and weight of 92.2 kilograms. His physical exam was remarkable for a right knee that was erythematous, warm, and swollen, and was exquisitely tender to palpation. The patient was unable to tolerate passive range of motion. The remainder of the joints assessed were unremarkable. Auscultation of his heart revealed an irregularly irregular rhythm but was otherwise negative for murmurs.

Notable lab results included a white blood cell count (WBC) of 16.7 K/cumm (reference range 4.5-10 K/cumm) with 78% neutrophils and 1% bands, hemoglobin 12.7 g/dL (reference range 13.5-16.5 g/dL), blood urea nitrogen (BUN) 48 mg/dL (reference range 8-20 mg/dL), creatinine 1.86 mg/dL (reference range 0.64-1.27 mg/dL), c-reactive protein (CRP) 9.15 mg/dL (reference range 0-0.74 mg/dL), and erythrocyte sedimentation rate (ESR) 49 mm/hr (reference range 0-20 mm/hr). Light brown, purulent synovial fluid from the right knee was obtained prior to antibiotic administration and was notable for a nucleated cell count of 218 325 K/cumm (reference range 13-180 K/cumm) with 87% neutrophils (reference range 0-25%), and a red blood cell count of

16 127 K/cumm (reference range 0-2000 K/cumm). Sterile specimens were sent to the microbiology lab for aerobic and anaerobic screening, revealing no organisms on original gram stain. Cultures plated per hospital protocol on multiple culture media including Blood, Chocolate, MacConkey, and Brucella with H&K (BRUHK) agar showed no growth at 24 h. A radiograph of the right knee demonstrated a small-to-moderate-size joint effusion (Figure 1).

The patient was started on empiric treatment with vancomycin and ceftriaxone for septic arthritis. Orthopedic Surgery was consulted for surgical management. The patient was taken to the operating room on hospital day 1 for irrigation and debridement of his right knee, without any complications. By hospital day 2, the synovial fluid culture obtained from admission revealed heavy growth of *B. fragilis* on BRUHK media (Hardy Diagnostics A30), and subsequent intraoperative cultures grew *B. fragilis* as well. As such, per Infectious Disease recommendations, the patient's antibiotic regimen was changed to intravenous metronidazole with an eventual plan for a 4-week treatment course on oral metronidazole. The source of infection was attributed to direct inoculation from his prior corticosteroid joint injection, given that he had multiple blood cultures that were negative and no other potential sites of infection were identified. Although the patient remained afebrile



**Figure 1.** Right knee radiograph with joint effusion (star) and soft tissue swelling (arrow).

and his leukocytosis resolved post-operatively, he continued to have pain and swelling with an associated rise in CRP to 25.4 mg/dL on hospital day 4. Orthopedic Surgery thus planned for repeat irrigation and debridement, but on hospital day 5, the patient left the hospital against medical advice and unfortunately was lost to follow-up thereafter.

## Discussion

No controlled trials or observational studies regarding the management of NJSAs due to *B. fragilis* could be found in the literature. As with cases of NJSAs due to other organisms, treatment of NJSAs due to *B. fragilis* is thought to require drainage of the affected joint in combination with antibiotic therapy.

The optimal means of achieving source control in NJSAs in general remain uncertain. Needle aspiration, arthroscopy, and arthrotomy have all been explored in the literature, but none of these modalities have demonstrated statistically significant superiority [6]. Arthrotomy and needle aspiration have both

been employed as modes of source control in cases of NJSAs due to *B. fragilis* [7-12]. However, this has been shown in some case reports to be insufficient, and 1 case report described the need for hemipelvectomy due to difficulty with achieving adequate source control [13].

In addition, antibiotic selection has varied widely in documented cases of NJSAs due to *B. fragilis* with agents including chloramphenicol, clindamycin, doxycycline, erythromycin, meropenem, metronidazole, piperacillin/tazobactam, and tobramycin prescribed, both individually and in combination, after synovial fluid culture speciation [7-12]. Metronidazole is currently the most commonly used antibiotic in this setting [4]. Metronidazole demonstrates excellent in vitro activity against *B. fragilis* and has been shown to penetrate well into synovial fluid, thus making it an extremely viable option for treatment [14,15]. In addition, metronidazole resistance is rare, with >99% of gram-negative anaerobes demonstrating susceptibility to this agent. This demonstrates superiority to alternatives with *B. fragilis* showing 10-42%, 1-22%, and 0-5% resistance to clindamycin, meropenem, and piperacillin/tazobactam, respectively [14]. Metronidazole is generally well-tolerated, with common adverse effects including nausea, diarrhea, and abdominal pain. However, extended courses of metronidazole (longer than 4 weeks) may result in peripheral neuropathy, which is reversible upon discontinuation [16].

The duration of antibiotic therapy in cases of NJSAs due to *B. fragilis* in the literature has ranged from 3 to 16 weeks, whereas 3 to 6 weeks of antibiotic therapy are traditionally recommended in the setting of NJSAs in general [4]. Of note, a recent unblinded randomized trial of NJSAs patients following surgical management compared a 2-week course of antibiotics with a 4-week course, finding the 2-week course to be non-inferior [17]. This approach has not yet been attempted in any documented case of NJSAs due to *B. fragilis*.

NJSAs due to *B. fragilis* typically responds well to the therapy outlined above. In the literature, we found documentation of only a single recorded death due to *B. fragilis* NJSAs and a single case of relapsed disease, both as outlined below.

The documented mortality occurred in a 71-year-old man with seropositive rheumatoid arthritis and NJSAs of his right knee and elbow. The patient had additional comorbidities including chronic obstructive pulmonary disease, coronary artery disease, and congestive heart failure, similar to our patient. Prior to his death, the patient had received surgical drainage of the affected joints and antibiotic therapy with ampicillin, chloramphenicol, clindamycin, and tobramycin. No autopsy was performed [8].

The case of relapsed disease occurred in a 44-year-old man with insulin-dependent diabetes mellitus and NJSAs of his right

knee. During his initial hospitalization, this patient received a right knee arthrotomy and a 5-week course of clindamycin following the isolation of *B. fragilis* in his synovial fluid. The patient was readmitted 3 weeks after discharge for management of purulent drainage from his right knee, and *B. fragilis* was again isolated from the patient's synovial fluid. The patient received surgical drainage of the affected joint and antibiotic therapy with a 19-day course of clindamycin followed by a 2-week course of doxycycline. The patient recovered and retained full range of motion in his right knee thereafter [8].

## Conclusions

NJSA due to *B. fragilis* is very rare. It is more common in the setting of *B. fragilis* bacteremia, occurring in about 65% of cases, or in the setting of contiguous spread from another concomitant infection, occurring in about 25% of patients [4]. In our case described above, the patient did not have *B. fragilis*

isolated from the bloodstream, nor was a local concomitant infection present, so the infection was attributed to direct inoculation from the prior corticosteroid injection.

Management requires both antibiotic therapy and source control with surgical drainage. However, the preferred modality of surgical drainage remains controversial [6]. The duration of antibiotic therapy after surgical drainage is dependent upon whether there is a concomitant primary infectious process, such as endocarditis or osteomyelitis, as these would require longer treatment courses. If none of these are present, then 2 weeks of targeted antibiotic therapy is now considered adequate [17].

## Declaration of Figures' Authenticity

All figures submitted have been created by the authors who confirm that the images are original with no duplication and have not been previously published in whole or in part.

## References:

1. Kennedy N, Chambers ST, Nolan I, et al. Native joint septic arthritis: Epidemiology, clinical features, and microbiological causes in a New Zealand population. *J Rheumatol*. 2015;42:2392-97
2. Ferrand J, El Samad Y, Brunschweiler B, et al. Morbimortality in adult patients with septic arthritis: A three-year hospital-based study. *BMC Infect Dis*. 2016;16:239
3. McBride S, Mowbray J, Caughey W, et al. Epidemiology, management, and outcomes of large and small native joint septic arthritis in adults. *Clin Infect Dis*. 2020;70:271-79
4. Nolla JM, Murillo O, Narvaez J, et al. Pyogenic arthritis of native joints due to *Bacteroides fragilis*: Case report and review of the literature. *Medicine (Baltimore)*. 2016;95:e3962
5. Wexler HM. Bacteroides: The good, the bad, and the nitty-gritty. *Clin Microbiol Rev*. 2007;20:593-621
6. Mathews CJ, Kingsley G, Field M, et al. Management of septic arthritis: A systematic review. *Ann Rheum Dis*. 2007;66:440-44
7. Ryeén AC, Schean A, Agell BO. A case of septic arthritis in multiple joints due to *Bacteroides fragilis* in a patient with rheumatoid arthritis. *Acta Orthop Scand*. 1978;49:98-101
8. Rosenkranz P, Lederman MM, Gopalakrishna KV, Ellner JJ. Septic arthritis caused by *Bacteroides fragilis*. *Rev Infect Dis*. 1990;12:20-30
9. Papanikolaou A, Tzavara V, Chini M, Papatheodorou A. Pyomyositis and septic hip arthritis due to *Bacteroides fragilis*: A case report. *Hip Int*. 2011;21:498-501
10. Martin T, Aziz H. *Bacteroides fragilis*: A case study of bacteremia and septic arthritis. *Clin Lab Sci*. 2009;22:131-35
11. Dodd MJ, Griffiths ID, Freeman R. Pyogenic arthritis due to bacteroides complicating rheumatoid arthritis. *Ann Rheum Dis*. 1982;41:248-49
12. Hart CA, Godfrey VM, Woodrow JC, Percival A. Septic arthritis due to *Bacteroides fragilis* in a wrist affected by rheumatoid arthritis. *Ann Rheum Dis*. 1982;41:623-24
13. Shalman A, Acker A, Shalman A, et al. Septic arthritis of the hip joint due to *Bacteroides fragilis* in a paraplegic patient. *Access Microbiol*. 2019;1:e000071
14. Brook I, Wexler HM, Goldstein EJ. Antianaerobic antimicrobials: Spectrum and susceptibility testing. *Clin Microbiol Rev*. 2013;26:526-46
15. Sattar MA, Sankey MG, Cawley MI, et al. The penetration of metronidazole into synovial fluid. *Postgrad Med J*. 1982;58:20-24
16. Hernández Ceruelos A, Romero-Quezada LC, Ruvalcaba Ledezma JC, López Contreras L. Therapeutic uses of metronidazole and its side effects: an update. *Eur Rev Med Pharmacol Sci*. 2019;23:397-401
17. Gjika E, Beaulieu JY, Vakalopoulos K, et al. Two weeks versus four weeks of antibiotic therapy after surgical drainage for native joint bacterial arthritis: A prospective, randomised, non-inferiority trial. *Ann Rheum Dis*. 2019;78:1114-21