

CASE REPORT

Successful Stenting of Iatrogenic Anterior Tibial Artery Pseudoaneurysm

A. Jones^{*}, S. Kumar

The John Hunter Hospital, Vascular Surgery Department, Newcastle, NSW, Australia

Introduction: The use of covered tibial stents extends beyond the treatment of atherosclerotic disease. Tibial artery pseudoaneurysms have traditionally been managed with open surgery; however, the endovascular option is an emerging treatment.

Report: This report describes endovascular management of an iatrogenic anterior tibial artery pseudoaneurysm using a covered stent.

Conclusion: This case highlights the use of a covered stent for pseudoaneurysm exclusion, vascular control, and to minimize dissection in a patient with multiple previous surgeries.

© 2016 The Authors. Published by Elsevier Ltd on behalf of European Society for Vascular Surgery. This is an open access article under the CC BY-NC-ND license (<http://creativecommons.org/licenses/by-nc-nd/4.0/>).

Article history: Received 6 July 2015, Revised 6 December 2015, Accepted 24 December 2015,

Keywords: Pseudoaneurysm, Tibial, Stent, Exclusion, Endovascular, Iatrogenic

INTRODUCTION

Tibial artery pseudoaneurysms have traditionally been managed with open surgery.¹ Case reports utilizing the endovascular strategy are reported in the literature; however, this approach in the setting of multiple interventions is ill defined (Table 1). As stent technology progresses, this minimally invasive strategy may become a durable option for pseudoaneurysm exclusion.

REPORT

A 52-year-old female, a smoker, presented with an acutely painful, pulsatile mass in the anterior compartment of the left lower leg. One week earlier, internal fixation hardware for a tibial plateau fracture had been electively removed without immediate complication. Examination revealed a tense, tender, pulsatile mass in the anterior compartment with threatened skin along the recent surgical incision (Fig. 1). There was no evidence of compartment syndrome or bleeding and the peripheral pulses were normal.

Blood chemistry including white cell count and C-reactive protein were normal. An arterial phase computed tomography angiography scan showed an $18 \times 2.5 \times 3.8$ cm pseudoaneurysm arising from the proximal anterior tibial artery (ATA). There were no radiological features of infection in the surrounding tissues (Fig. 2).

Because of the recent revision surgery and proximal location of the pseudoaneurysm arising from the ATA, an endovascular approach was favored. Retrograde arterial access via the contralateral common femoral artery was obtained with a 5F sheath and a stiff 0.035 glide wire (Terumo, Tokyo). This sheath was exchanged to a 55 cm, 6F, Check-flow ANL1 sheath (Cook, Bloomington, IL, USA) that was positioned over the aortic bifurcation into the superficial femoral artery. An angiogram demonstrated the ATA pseudoaneurysm and confirmed distal runoff via three vessels (Fig. 3A). The ATA was secured using a V14, 0.014 Control wire (Boston Scientific, Marlborough, MA, USA) and 65 cm Vanschie 1 catheter (Cook, Bloomington, IL, USA). An ePTFE 3.5×26 mm Graftmaster RX covered stent (Abbott Vascular Devices, Abbott Park, IL, USA) was deployed across the pseudoaneurysm neck. Angiogram confirmed both the absence of flow in the pseudoaneurysm and preserved flow distally (Fig. 3B). Following pseudoaneurysm exclusion, the resultant hematoma was then surgically evacuated with minimal dissection. The tissue microscopy and culture was negative for infection. Dual antiplatelet therapy was commenced post operatively. Because of geographical factors, normal perfusion has been reported by the local primary care physician at 12 months.

DISCUSSION

Tibial artery pseudoaneurysms are uncommon and have been reported following blunt and penetrating soft tissue trauma, following long bone fractures and also as a complication of fracture fixation.^{1,2} Open surgery with simple ligation or interposition vein grafting has been the standard of practice. Conservative management, coil embolization, and ultrasound-guided thrombin injection also have been reported.^{3,4} Case reports using covered

^{*} Corresponding author. The John Hunter Hospital, Vascular Department, Lookout Road, New Lambton Heights, NSW, 2305, Australia.

E-mail address: alister_jones@hotmail.com (A. Jones).

2405-6553/© 2016 The Authors. Published by Elsevier Ltd on behalf of European Society for Vascular Surgery. This is an open access article under the CC BY-NC-ND license (<http://creativecommons.org/licenses/by-nc-nd/4.0/>).

<http://dx.doi.org/10.1016/j.ejvssr.2015.12.003>

Table 1. Summary of published case reports using covered stents for tibial pseudoaneurysm.

Author	Etiology	Stent	Location	Size, mm
De Roo (2004) ¹⁰	Fibulectomy	PTFE Symbiot (Boston Scientific)	ATA	4 × 31
Spirito (2007) ⁵	Blunt trauma	ePTFE Graftmaster Jostent (Abbott Vascular)	ATA	4 × 26
Van Hensbroek (2007) ⁷	Tibial plate Insertion	PTFE Symbiot (Boston Scientific)	ATA	3 × 20
Joglar (2010) ⁸	Blunt trauma/fracture	ePTFE Graftmaster Jostent (Abbott Vascular)	PTA	3 × 19
Marks (2011) ⁹	Penetrating trauma	iCAST (Abbott Vascular)	TPT	5 × 16
De Troia (2014) ⁶	Penetrating trauma	ePTFE (InSitu Direct Stent Technologies)	PTA	3 × 19

ATA = anterior tibial artery; PTA = posterior tibial artery; TPT = tibioperoneal trunk.

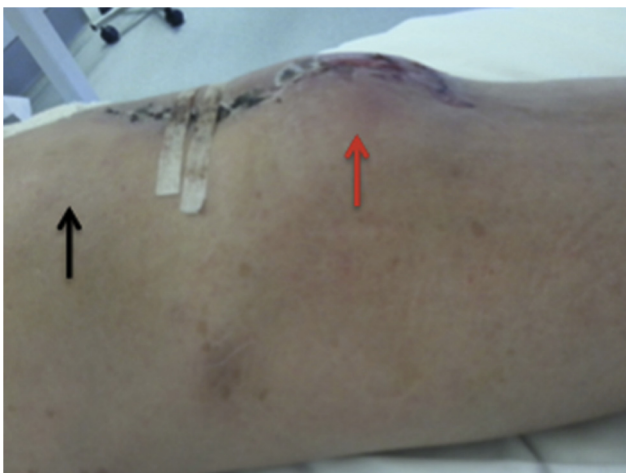

Figure 1. Left leg swelling (red arrow) below the knee (black arrow) viewed from the medial side.

stents have been described in the literature following trauma with immediate technical success; however, no reports have been published in the setting of multiple previous surgeries.^{5,6} In this situation with the open approach more challenging because of obliterated tissue planes, an alternative to open surgery has clear benefits. The use of a covered stent to gain intravascular control avoids multiple operative incisions to gain proximal and distal control while achieving the aim of preservation of distal flow. The avoidance of extensive dissection within an area of scar tissue and distorted tissue planes also facilitates a minimalist approach to hematoma evacuation following pseudoaneurysm exclusion. This technique allows rapid vascular control and can be performed using local anesthetic in the endovascular suite.

This case highlights the advantages of an endovascular strategy when managing tibial artery pseudoaneurysms in patients with multiple previous surgeries.

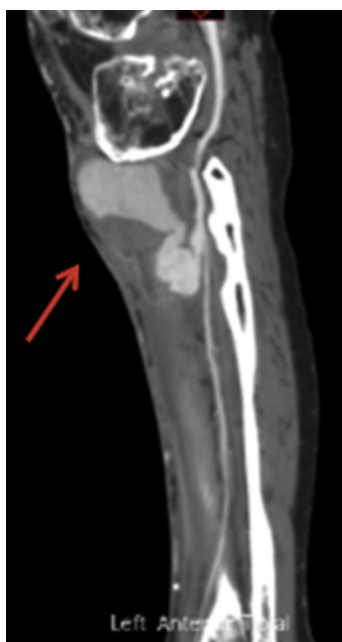

Figure 2. Sagittal computed tomography angiogram of the left leg demonstrating a pseudoaneurysm from the proximal anterior tibial artery (red arrow).

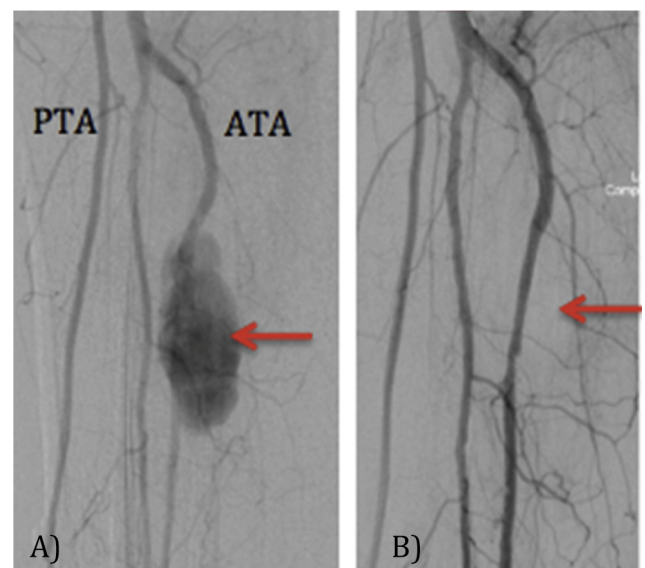


Figure 3. (A) Preintervention angiogram demonstrating the pseudoaneurysm of the anterior tibial artery (ATA- Red Arrow) below a high take-off posterior tibial artery (PTA). (B) Post intervention angiogram confirming adequate stent placement (red arrow) with exclusion of the ATA pseudoaneurysm using a covered stent.

CONFLICT OF INTEREST

None.

FUNDING

None.

REFERENCES

- 1 Poposelli F, Hamdan A. Lower extremity aneurysms. In: Cronenwett J, Johnston K, editors. *Rutherford's vascular surgery*. 7th ed. Philadelphia: Saunders; 2010. p. 2126–7.
- 2 Suri T, Dabas V, Sural S, Dhal A. Pseudoaneurysm of the anterior tibial artery: a rare complication of proximal tibial Steinman pin insertion. *Indian J Orthop* 2011;**45**(2):178–80.
- 3 Singh D, Ferero A. Traumatic pseudoaneurysm of the posterior tibial artery treated by endovascular coil embolization. *Foot Ankle Spec* 2013;**6**(1):54–8.
- 4 Kang S, Labropoulos N, Mansour M, Michelini M, Filliung D, Baubly M, et al. Expanded indications for ultrasound-guided thrombin injection of pseudoaneurysms. *J Vasc Surg* 2000;**31**: 289–98.
- 5 Spirito R, Trabattoni P, Pompilio G, Zoli S, Agrifoglio M, Biglioli P. Endovascular treatment of a post-traumatic tibial pseudoaneurysm and arteriovenous fistula: case report and review of the literature. *J Vasc Surg* 2007;**45**:1076–9.
- 6 De Troia A, Biasi L, Iazzolion L, Azzarone M, Tecchio T, Rossi C, et al. Endovascular stent grafting of posterior tibial artery pseudoaneurysm secondary to penetrating trauma: case report and review of the literature. *Ann Vasc Surg* 2014;**28**:1789.e13–7.
- 7 van Hensbroek PB, Ponsen KJ, Reekers JA, Goslings JC. Endovascular treatment of anterior tibial artery pseudoaneurysm following locking compression plating of the tibia. *J Orthop Trauma* 2007;**21**:279–82.
- 8 Joglar F, Kabutey NK, Maree A, Farber A. The role of stent grafts in the management of traumatic tibial artery pseudoaneurysms: case report and review of the literature. *Vasc Endovascular Surg* 2010;**44**:407–9.
- 9 Marks JA, Hager E, Henry D, Martin ND. Lower extremity vascular stenting for a post-traumatic pseudoaneurysm in a young trauma patient. *J Emerg Trauma Shock* 2011;**4**:302–5.
- 10 De Roo RA, Steenvoorde P, Schuttevaer HM, Den Outer AJ, Oskam J, Joosten PP. Exclusion of a crural pseudoaneurysm with a PTFE-covered stent-graft. *J Endovasc Ther* 2004;**11**(3): 344–7.