



## RESEARCH ARTICLE

# Computed Tomography-Based Determination of the Optimal Locations of Bone Tunnels for Coracoclavicular Ligament Reconstruction

Lei Zhang, PhD<sup>1,2,3,4</sup> , Lujing Xiong, MBBS<sup>5</sup>, Xin Zhou, MM<sup>1,2,3</sup>, Bingkun Li, MBBS<sup>1,2,3</sup>, Xiaogao Tang, MBBS<sup>1,2,3</sup>, Guo-you Wang, PhD<sup>1,2,3</sup> 

<sup>1</sup>Department of Orthopaedics and <sup>2</sup>Center for Orthopaedic Diseases Research, Affiliated Traditional Chinese Medicine Hospital of Southwest Medical University, <sup>3</sup>Expert Workstation in Luzhou, Sichuan, <sup>4</sup>Guangdong Province Medical 3D Printing Application Transformation Engineering Technology Research Center, Clinical Base of Affiliated Traditional Chinese Medicine Hospital of Southwest Medical University and <sup>5</sup>School of Clinical Medicine, Southwest Medical University, Luzhou, China

**Objective:** An agreement has not been reached on optimal locations of bone tunnels for coracoclavicular ligament (CCL) reconstruction for acromioclavicular joint dislocation (ACD). This study aims to identify the convergence point (cP) between the coracoid process and clavicle in the Chinese population to assist surgeons in reconstructing the CCL for ACD.

**Methods:** From 2014 to 2020, 483 CT scans of the shoulders of 270 male and 213 female patients (247 right and 236 left shoulders) were collected and studied retrospectively. By overlapping the images of the transverse plane of the coracoid process and the clavicle, points a and b, and the midpoint ab (cP) were determined. Then, a series of parameters through point cP in the transverse and sagittal planes were measured. In the transverse plane this included the distance from point cP to the tip of the coracoid process (cP-cor), the distance between the medial and lateral margins of the coracoid process through point cP (Med-lat cor), the distance from point cP to the acromioclavicular joint (cP-ac), and the distance between the anteroposterior margin of the clavicle through point cP (Ap-clav). In the sagittal plane, this included the craniocaudal segment of the coracoid process (Cc-cor), and the craniocaudal segment of the clavicle (Cc-clav). The sex and side differences of these measurements were also analyzed by two radiologists.

**Results:** Based on the following measurements, point cP was determined. For male patients, the cP-cor was  $28.02 \pm 3.43$  mm, Med-lat cor was  $22.78 \pm 2.80$  mm, Cc-cor was  $15.11 \pm 2.13$  mm, cP-ac was  $29.24 \pm 3.84$  mm, Ap-clav was  $18.27 \pm 2.46$  mm, and Cc-clav was  $10.09 \pm 1.56$  mm. For female patients, the cP-cor was  $25.20 \pm 3.26$  mm, Med-lat cor was  $20.21 \pm 2.97$  mm, Cc-cor was  $13.03 \pm 1.77$  mm, cP-ac was  $26.66 \pm 3.45$  mm, Ap-clav was  $16.10 \pm 2.30$  mm, and Cc-clav was  $8.91 \pm 1.40$  mm. All the measurements of female patients were lower than those of male patients ( $p < 0.01$ ). Between sides, only cP-ac of the left shoulders was significantly lower than those of the right shoulders ( $p < 0.05$ ), with no significant differences in other parameters between sides ( $p > 0.05$ ).

**Conclusion:** The results of this study identified the locations of bone tunnel-cP in the coracoid process and clavicle for the CCL reconstruction in ACD. Moreover, the findings indicated that surgeons should be more cautious in operating on female patients and that the cP-ac of left shoulders should be set lower than that of right shoulders.

**Key words:** acromioclavicular joint dislocation; bone tunnel; computed tomography; coracoclavicular ligament reconstruction; overlapping images

**Address for correspondence** Guo-You Wang, PhD, Department of Orthopaedics, Affiliated Traditional Chinese Medicine Hospital of Southwest Medical University, Luzhou, Sichuan province, China. Tel: 13989121399; Fax: 08302523352; Email: [wang\\_guoyou1981@163.com](mailto:wang_guoyou1981@163.com)  
Lei Zhang, Lujing Xiong, and Xin Zhou contributed equally to this work.

Received 23 April 2021; accepted 25 July 2022

## Introduction

Acromioclavicular joint dislocation (ACD) is a common shoulder girdle injury, accounting for approximately 8% of all joint dislocations and 12% of shoulder injuries.<sup>1</sup> In general, the treatments for ACD are non-operative for Rockwood types I and II and are operative for types IV–VI<sup>1,2</sup>. The treatment types remain controversial for type III acromioclavicular joint injuries. The literature supports non-operative management of type III injuries, with operative management only when non-operative management fails or according to patient preference.<sup>2–4</sup> Although more than 162 surgical techniques for ACD have been described, there remains no gold standard.<sup>5</sup>

In acute ACD, surgeons frequently resort to the use of hook plates, which provide good short-term effects but may lead to complications including acromioclavicular arthritis, stress fractures, and acromial osteolysis.<sup>6,7</sup> In contrast, the Weaver–Dunn procedure, which transfers the coracoacromial ligament (CCL) to the distal clavicle, is frequently used for the treatment of chronic ACD.<sup>8,9</sup> However, the biomechanical strength of the CCL is only 25% of that of the native CCL and the failure rate of the procedure is as high as 30%.<sup>9–11</sup> Over time, more and more minimally invasive surgical treatments for acute and chronic ACD with fewer complications have been described. For example, surgeons usually reconstruct the CCL under arthroscopy using double endobutton devices for acute ACD<sup>2,12,13</sup> and using autografts,<sup>2,8,14</sup> allografts,<sup>2,15</sup> or synthetic ligaments such as the ACLS and TightRope for chronic ACD.<sup>2</sup> In CCL reconstruction, drilling bone tunnels in the coracoid process and clavicle to restore the anatomical structure of the CCL has become a common surgical treatment. Although CCL reconstruction for ACD can provide favorable clinical and radiographic outcomes,<sup>12,13,16,17</sup> where and how to drill bone tunnels accurately in the coracoid process and clavicle for CCL reconstruction for ACD remains controversial.

In types IV–VI ACD, due to the instability of the acromioclavicular joint caused by CCL rupture, CCL reconstruction must interconnect the coracoid process and clavicle to prevent acromioclavicular joint superior dislocation. Therefore, just below the reduced clavicle, a bone tunnel at the base of the central region of the coracoid process, allows synthetic ligaments to pull down the clavicle to prevent this dislocation. Previous studies have proposed locations and methods for drilling bone tunnels through the coracoid process and clavicle.<sup>8,15,18–22</sup> These studies reported two 3.5/4.5/6/7 mm-diameter holes in the clavicle for conoid and trapezoid ligament reconstruction and zero, one, or two 3.5/4.5/6/7 mm-diameter holes in the base of the coracoid process. Coale *et al.*<sup>21</sup> prepared three bone tunnels using superior clavicular, inferior/superior coracoid landmarks, and central coracoid landmarks in a three-dimensional model for CCL reconstruction, concluding that the anatomical reconstruction of conoid and trapezoid ligaments may lead to a high risk of medial cortical breach and coracoid process fracture. However, no previous study described the

accurate placement of bone tunnels in the coracoid process and clavicle; thus, surgeons must drill bone tunnels empirically, which may lead to drilling at unsuitable sites, failure of acromioclavicular joint reduction, anterior subluxation of the acromioclavicular joint or coracoid process fracture and the clavicle after operation.<sup>21,23,24</sup>

In recent years, Sella *et al.*<sup>22</sup> described overlapping CT images to identify a convergence point (cP) between the coracoid process and clavicle for creating a bone tunnel for CCL reconstruction, as well as a series of parameters for accurate drilling. However, the authors did not analyze the differences between sex and side, the sample size was not large, and the study population included only Brazilians. Due to the differences according to sex and race, differences may exist when drilling bone tunnels in Chinese patients.

No previous study has described how to accurately establish a bone tunnel in the coracoid process and clavicle in a Chinese population. Thus, this study applied the previously described method of overlapping CT images of the coracoid process and clavicle to a Chinese population.<sup>22</sup> And based on previous literature,<sup>8,15,18–22</sup> we hypothesized that optimal bone tunnels located in the base of the central region of the coracoid process, and just above the coracoid process, were located in the central region of the clavicle. The purpose of this study was (i) to identify the point cP between the coracoid process and clavicle and measure a series of parameters through point cP, which contribute to reconstructing CCL; (ii) to analyze sex differences; and (iii) to study the side differences (left and right shoulders) in a Chinese population.

## Methods

### Inclusion and Exclusion Criteria

Inclusion criteria: (1) patients with normal scapula and clavicle; (2) patients who underwent CT scans of shoulders on different sides. Exclusion criteria: deformity and fracture of the scapula and clavicle. A total of 483 CT scans of patient shoulders scanned between 2014 and 2020 were provided by the Department of Radiology, Affiliated Hospital of Traditional Chinese Medicine, Southwest Medical University. Among the patients, 270 were male and 213 were female. Among the shoulders that were scanned, 247 of them were right and 236 were left shoulders.

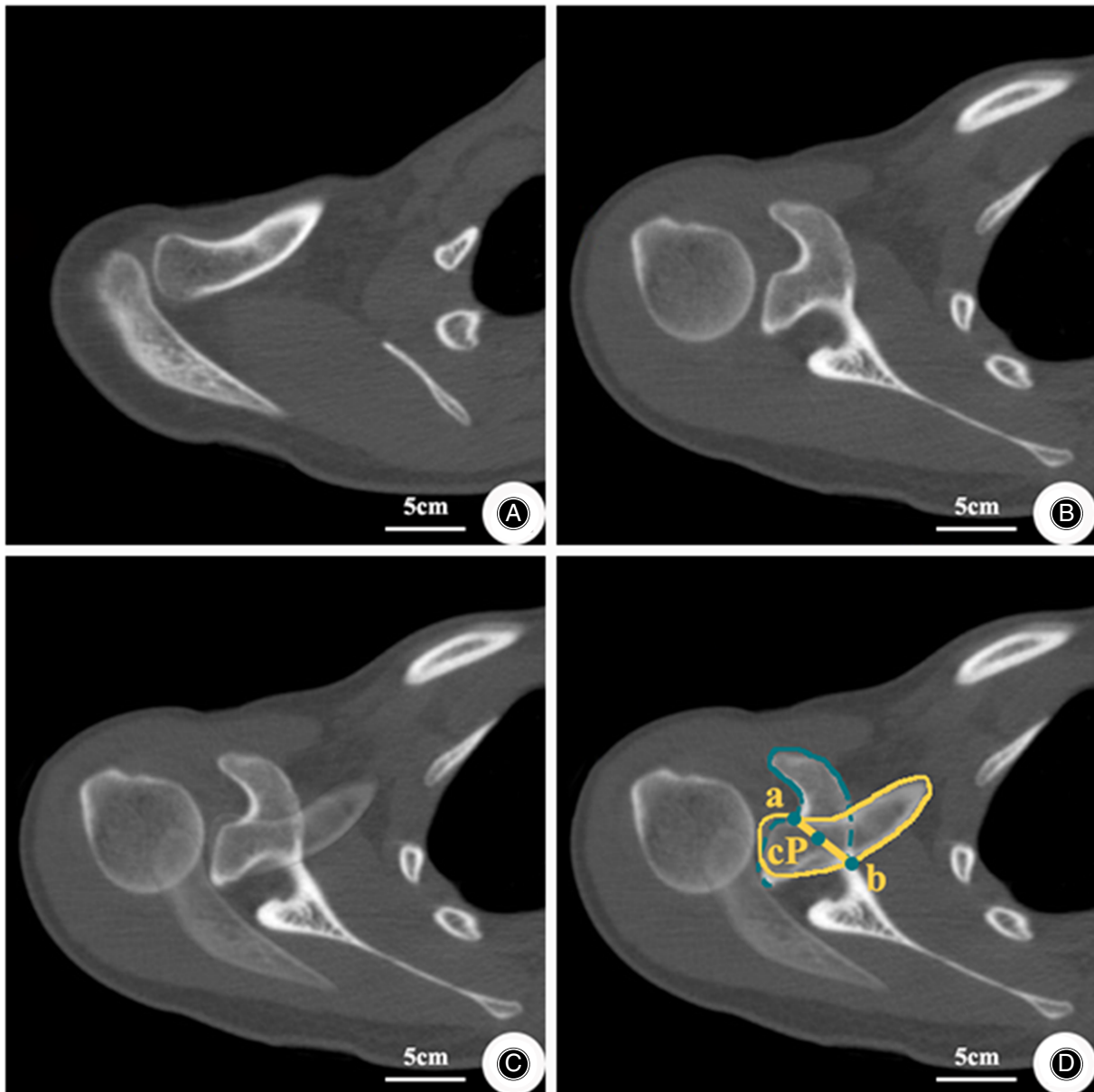
### Measurements

The shoulder joints including the scapula and the clavicle of 483 patients were scanned on a spiral CT scanner (Somatom Sensation 16) provided by SIEMENS (Munich, Germany). All measurements were performed by two radiologists who were familiar with musculoskeletal structure and who had worked in the radiology department for >5 years. The measurements described by Sella *et al.* were carried out as follows.<sup>22</sup> The images of the clavicle and the coracoid process were collected and processed on a picture archiving and communication system (PACS) (UniPeport V 2.0 m) provided by KONICA

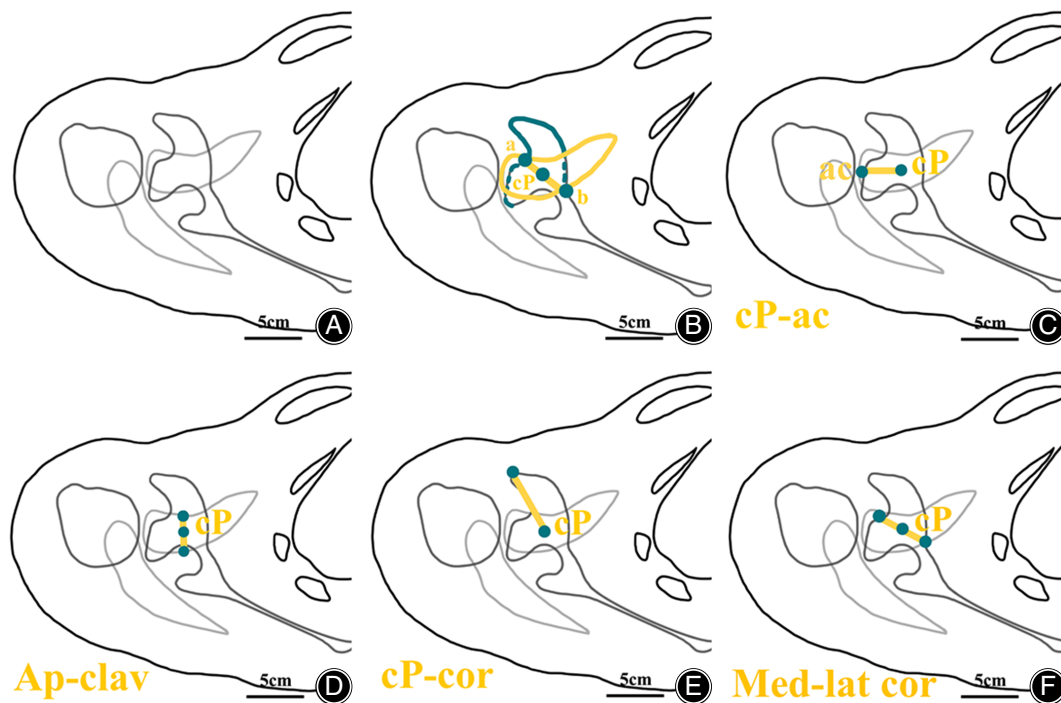
MINOLTA (Shanghai, China). The images of the transverse plane of the clavicle with the largest distance between the anteroposterior margins and the transverse plane of the coracoid process with the largest distance between the medial and lateral margins were obtained respectively (Figure 1A,B). The processed images of the clavicle and coracoid process were overlapped (Figures 1C and 2A). Points, a, b, and cP were marked in the overlapped images, in which point a was the

intersection of the anterior margin of the clavicle and the lateral margin of the coracoid process, point b was the intersection of the posterior margin of the clavicle and the medial margin of the coracoid process, and point cP was the midpoint of ab, which was the optimal location for drilling bone tunnels for CCL reconstruction (Figures 1D and 2B).

Next, in the overlapped images, using point cP as the reference point, four specific parameters of the coracoid



**FIGURE 1** Method for locating the convergence point (cP) in CT shoulder scans. (A), Images of the transverse plane of the clavicle with the largest distance of the anteroposterior margins. (B), Images of the transverse plane of the coracoid process with the largest distance between the medial and lateral margins. (C), Overlapped images from (A) and (B). (D), The location of point cP; a, the intersection of the anterior margin of the clavicle and the lateral margin of the coracoid process; b, the intersection of the posterior margin of the clavicle and the medial margin of the coracoid process. Point cP is defined as the midpoint of ab



**FIGURE 2** Illustration of the overlapped images and measurements. (A), Overlapped images from Figure 1A,B. (B), The location of point convergence point (cP); a, the intersection of the anterior margin of the clavicle and the lateral margin of the coracoid process; b, the intersection of the posterior margin of the clavicle and the medial margin of the coracoid process. Point cP is defined as the midpoint of ab. (C), cP-ac, distance from point cP to the acromioclavicular joint. (D), Ap-clav, distance between the anteroposterior margin of the clavicle through point cP. (E), cP-cor, distance from point cP to the tip of the coracoid process. (F), Med-lat cor, distance between the medial and lateral margins of the coracoid process through point cP

process and clavicle were described to accurately locate the bone tunnels (Figures 2 and 3), including:

1. cP-ac, distance from point cP to the acromioclavicular joint (Figures 2C and 3A)
2. Ap-clav, distance between the anteroposterior margin of the clavicle through point cP (Figures 2D and 3B)
3. cP-cor, distance from point cP to the tip of the coracoid process (Figures 2E and 3C)
4. Med-lat cor, distance between the medial and lateral margins of the coracoid process through point cP (Figures 2F and 3D)

Further, line  $\alpha$  (the axis of the coracoid process through point cP) was also determined (Figures 4A and 5A). On the sagittal plane, the image through line  $\alpha$  was selected (Figure 4B), from which two parameters of the clavicle and coracoid process were described to evaluate the depth of bone tunnels, including:

1. Cc-clav, craniocaudal segment of the clavicle (Figures 5B and 6A)
2. Cc-cor, craniocaudal segment of the coracoid process (Figure 5C and Figure 6B)

### Statistical Analyses

All measurements performed by the radiologists were averaged. Data were analyzed by using IBM SPSS Statistics for Windows, version 25.0 (IBM Corp.). The measurements were expressed as means  $\pm$  standard deviation ( $\bar{x} \pm s$ ).

Kolmogorov–Smirnov (K–S) tests were used to assess the normality of the distributions of each measurement of parameters. Independent sample *t*-tests were used to compare the differences between sides and sex. Fisher *F*-tests were used to determine whether the variances of each measurement of parameters were equal. Intraclass correlation coefficients (ICCs) were used to measure inter-observer reliability.  $p < 0.05$  was considered statistically significant.

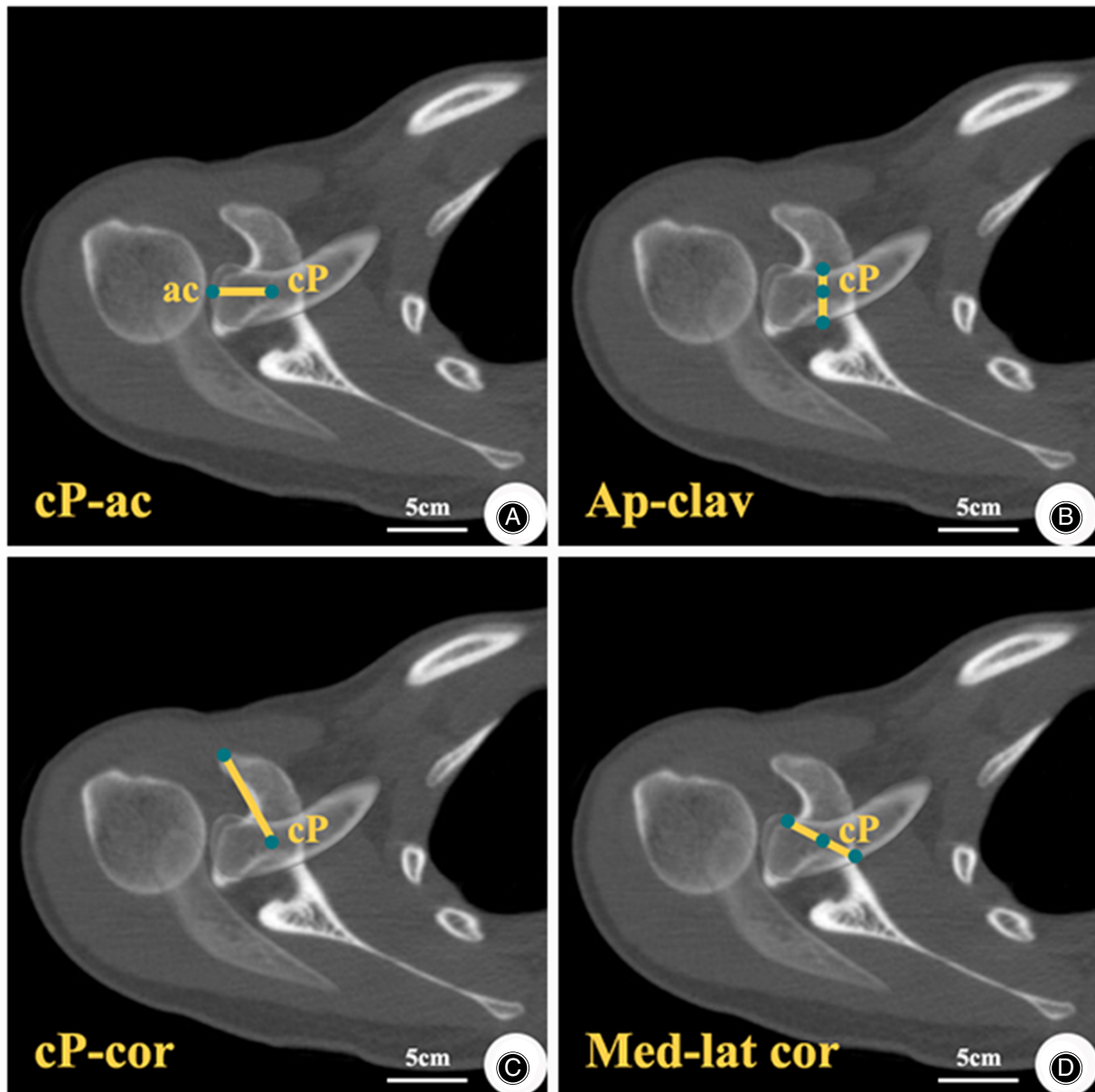
### Results

#### Measurement Results in Chinese Population

The measurement results for the coracoid process and clavicle in Chinese population are shown in Tables 1 and 2, including cP-ac ( $28.10 \pm 3.89$  mm), Ap-clav ( $17.31 \pm 2.62$  mm), cP-cor ( $26.78 \pm 3.63$  mm), Med-lat cor ( $21.65 \pm 3.14$  mm), CC-clav ( $9.57 \pm 1.60$  mm), and CC-cor ( $14.19 \pm 2.23$  mm).

#### Differences in Sex

The measurement results in men were as follows: cP-ac,  $29.24 \pm 3.84$  mm; Ap-clav,  $18.27 \pm 2.46$  mm; cP-cor,  $28.02 \pm 3.43$  mm; Med-lat cor,  $22.78 \pm 2.80$  mm; CC-clav,  $10.09 \pm 1.56$  mm; and CC-cor,  $15.11 \pm 2.13$  mm. The measurement results in women were cP-ac,  $26.66 \pm 3.45$  mm; Ap-clav,  $16.10 \pm 2.30$  mm; cP-cor,  $25.20 \pm 3.26$  mm; Med-lat cor,  $20.21 \pm 2.97$  mm; CC-clav,  $8.91 \pm 1.40$  mm; and CC-cor,  $13.03 \pm 1.77$  mm. All measurements in male



**FIGURE 3** Measurements in overlapping images, with point convergence point (cP) as a reference. (A), cP-ac, distance from point cP to the acromioclavicular joint. (B) Ap-clav, distance between the anteroposterior margin of the clavicle through point cP. (C) cP-cor, distance from point cP to the tip of the coracoid process. (D) Med-lat cor, distance between the medial and lateral margins of the coracoid process through point cP

patients were significantly higher than those in female patients ( $p < 0.05$ ) (Table 2).

#### Differences in Sides

The cP-ac locations differed significantly according to side, at  $28.56 \pm 4.06$  mm for the right and  $27.60 \pm 3.65$  mm for the left ( $p < 0.05$ ). No other measures differed significantly between the right and left sides (Ap-clav:  $17.41 \pm 2.74$  mm vs  $17.20 \pm 2.50$  mm; cP-cor:  $26.67 \pm 3.66$  mm vs  $25.20 \pm 3.26$  mm; Med-lat cor:  $21.67 \pm 3.18$  mm vs  $21.62 \pm 3.11$  mm;

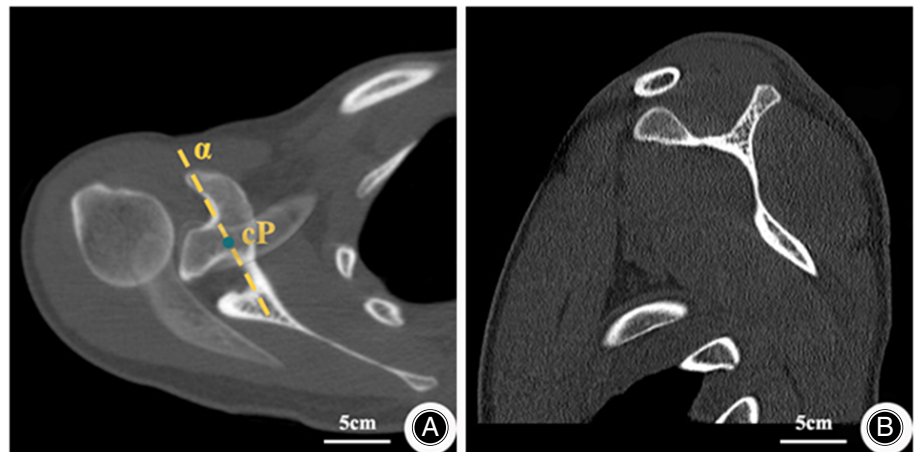
CC-clav:  $9.53 \pm 1.65$  mm vs  $9.62 \pm 1.55$  mm; CC-cor:  $14.02 \pm 2.31$  mm vs  $14.38 \pm 2.14$  mm; all  $p > 0.05$ ) (Table 2).

#### Inter-observer Reliability

The inter-observer agreement for all measurements was good (ICC = 0.900 [0.796–0.953],  $p < 0.001$ ).

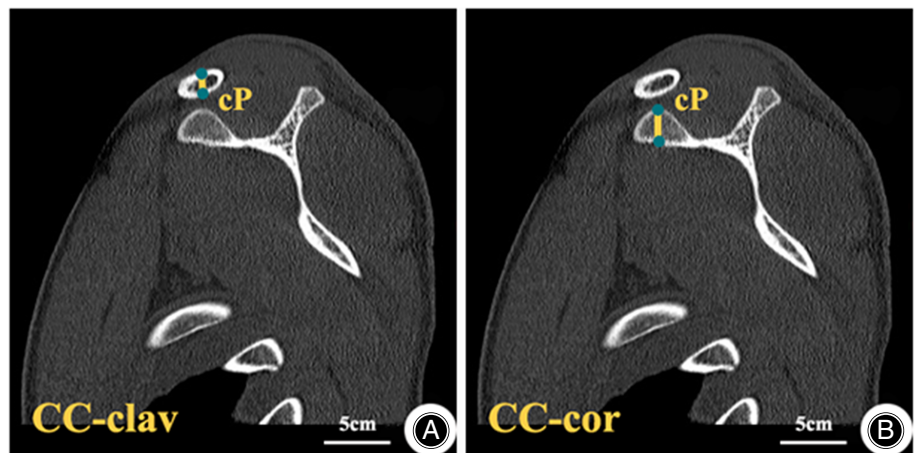
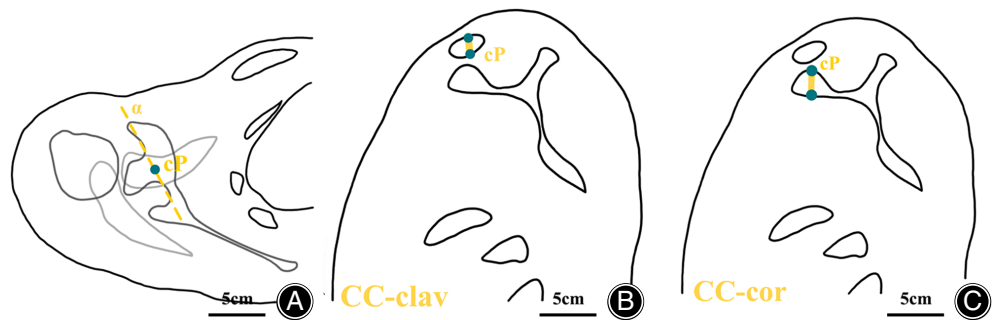
#### Discussion

By overlapping CT shoulder scans, we identified point cP between the coracoid process and clavicle, measured a



**FIGURE 4** Image of the sagittal plane through line  $\alpha$ . (A) Overlapping images from Figure 1A, B. Line  $\alpha$  is the axis of the coracoid process through point convergence point (cP). (B) Image of the sagittal plane through line  $\alpha$

**FIGURE 5** Illustration of the images of the sagittal plane through line  $\alpha$  and measurements. (A) Overlapping images from Figure 1A, B. Line  $\alpha$  is the axis of the coracoid process through point convergence point (cP). (B) Cc-clav, craniocaudal segment of the clavicle. (C) Cc-cor, craniocaudal segment of the coracoid process



**FIGURE 6** Measurements in the image of the sagittal plane through line  $\alpha$ . (A) Cc-clav, craniocaudal segment of the clavicle. (B) Cc-cor, craniocaudal segment of the coracoid process

series of parameters through point cP, and studied the differences between sides and sexes in Chinese population. Our results showed cP-cor locations of  $28.02 \pm 3.43$  mm in men and  $25.20 \pm 3.26$  mm in women and cP-ac locations of  $29.24 \pm 3.84$  mm in men and  $26.66 \pm 3.45$  mm in women. Our results are comparable to those reported by Sella *et al.*<sup>22</sup> (cP-cor: 29.3 mm and 24.9 mm; cP-ac: 29.3 mm in men and 25.6 mm in women, respectively). Moreover, as illustrated in Tables 1 and 2, all measurements in female patients were

lower than those in male patients, while the ac-cP of the left shoulders was lower than those of the right shoulders.

#### **Significance of the Optimal Location of the Bone Tunnel**

Selecting the optimal position to drill bone tunnels on the narrow clavicle and coracoid process is key but challenging in the reconstruction of the CCL for ACD. Based on cadaver specimens and CT scans, the anatomical characteristics of the coracoid process, clavicle, and CCL have been described.

**TABLE 1 Sex differences in measurements of the coracoid process and clavicle ( $\bar{x} \pm s$ )**

Parameters	Male	Female	Total	t	p
N	270	213	483	/	/
cP-ac (mm)	29.24 ± 3.84	26.66 ± 3.45 <sup>a</sup>	28.10 ± 3.89	7.730	<0.001
Ap-clav (mm)	18.27 ± 2.46	16.10 ± 2.30 <sup>a</sup>	17.31 ± 2.62	9.884	<0.001
cP-cor (mm)	28.02 ± 3.43	25.20 ± 3.26 <sup>a</sup>	26.78 ± 3.63	9.154	<0.001
Med-lat cor (mm)	22.78 ± 2.80	20.21 ± 2.97 <sup>a</sup>	21.65 ± 3.14	9.734	<0.001
Cc-clav (mm)	10.09 ± 1.56	8.91 ± 1.40 <sup>a</sup>	9.57 ± 1.60	8.649	<0.001
Cc-cor (mm)	15.11 ± 2.13	13.03 ± 1.77 <sup>a</sup>	14.19 ± 2.23	11.692	<0.001

Abbreviation: Ap-clav, distance between the anteroposterior margin of the clavicle through point cP; Cc-clav, craniocaudal segment of the clavicle; Cc-cor, craniocaudal segment of the coracoid process; cP-ac, distance from point cP to the acromioclavicular joint; cP-cor, distance from point cP to the tip of the coracoid process; Med-lat cor, distance between the medial and lateral margins of the coracoid process through point cP.; <sup>a</sup> p < 0.05 versus male.

**TABLE 2 Sides differences in measurements of the coracoid process and clavicle ( $\bar{x} \pm s$ )**

Parameters	Right	Left	Total	t	p
N	247	236	483	/	/
cP-ac (mm)	28.56 ± 4.06	27.60 ± 3.65 <sup>a</sup>	28.10 ± 3.89	2.729	0.007
Ap-clav (mm)	17.41 ± 2.74	17.20 ± 2.50	17.31 ± 2.62	0.882	0.378
cP-cor (mm)	26.67 ± 3.66	25.20 ± 3.26	26.78 ± 3.63	0.724	0.469
Med-lat cor (mm)	21.67 ± 3.18	21.62 ± 3.11	21.65 ± 3.14	0.161	0.873
Cc-clav (mm)	9.53 ± 1.65	9.62 ± 1.55	9.57 ± 1.60	0.625	0.532
Cc-cor (mm)	14.02 ± 2.31	14.38 ± 2.14	14.19 ± 2.23	1.750	0.081

Abbreviations: Ap-clav, distance between the anteroposterior margin of the clavicle through point cP; Cc-clav, craniocaudal segment of the clavicle; Cc-cor, craniocaudal segment of the coracoid process; cP-ac, distance from point cP to the acromioclavicular joint; cP-cor, distance from point cP to the tip of the coracoid process; Med-lat cor, distance between the medial and lateral margins of the coracoid process through point cP.; <sup>a</sup> p < 0.05 versus right.

Furthermore, relevant anatomical parameters have provided a reference for surgeons to establish bone tunnels.<sup>2,25–27</sup> However, due to different results among studies, there remains controversy regarding the selection of the optimal position to drill bone tunnels in clinical practice. Inaccurate bone tunnel location or inappropriate diameter may lead to failure of the reduction and fixation of the acromioclavicular joint and may also increase the risk of coracoid process and clavicle fractures.<sup>27</sup>

#### **Optimal Locations of Bone Tunnels in the Coracoid Process According to Sex and Side**

Xue *et al.*<sup>26</sup> studied the attachment regions of the CCL in Chinese population. The lengths of the coracoid process were 43.3 ± 3.1 mm and 38.0 ± 3.0 mm in men and women, respectively. Therefore, based on our results of point cP locations of 28.02 ± 3.43 mm in men and 25.20 ± 3.26 mm in women, far from the tip of the coracoid process, point cP was located approximately at the intersection of the middle and posterior thirds of the coracoid process, at the base of the coracoid process. Studies on the location of bone tunnels in the coracoid process suggested that tunnels in the base of the coracoid process were safer and more forgiving.<sup>21,28</sup> Coale *et al.*<sup>21</sup> drilled a bone tunnel at the midpoint between the center of the conoid and trapezoid ligament footprints on the superior coracoid process for CCL reconstruction, reporting a high risk of medial cortical breach and coracoid fracture. Many studies have also

proposed the diameter of the bone tunnel in the coracoid process,<sup>8,15,18–20,28,29</sup> with values ranging from 3.5 to 7 mm. Among them, Campbell *et al.*<sup>28</sup> reported that a 4.5-mm tunnel in the base of the coracoid process provided greater reduction and fixation compared to a 6.0-mm tunnel. In our results, the Med-lat cor locations were 22.78 ± 2.80 mm in men and 20.21 ± 2.97 mm in women. These findings suggest that surgeons should drill bone tunnels 4.5 mm in diameter at the base of the coracoid process, at 9.14 and 7.86 mm medial to the lateral margin in men and women, respectively. Moreover, due to the shorter distance between the lateral margin and the bone tunnel, surgeons should be more cautious in drilling the bone tunnel in female patients. Regarding tunnel orientation, Ferreira *et al.*<sup>29</sup> suggested that when drilling a bone tunnel in the coracoid process, center–center or medial–center tunnel orientations may provide fewer risks of coracoid fracture. Hence, 4.5-mm bone tunnels in the coracoid process should be located 28.02 ± 3.43 and 25.20 ± 3.26 mm from the tip of the coracoid process with center–center or medial–center tunnel orientations in men and women, respectively, with additional caution in female patients in performing the procedure.

#### **Optimal Locations of Bone Tunnels in the Clavicle According to Patient Sex and Sides**

Previous studies have proposed different methods for drilling bone tunnels in the clavicle,<sup>8,11,15,18–21,30,31</sup> including drilling

two<sup>8,15,18,19</sup> or one hole.<sup>11,20,21,30,31</sup> In procedures involving two holes, these are frequently drilled at the insertion of the conoid and trapezoid ligaments. Mazzocca *et al.*<sup>8</sup> created bone tunnels 45 mm medial to the acromioclavicular joint for the conoid ligament and 15 mm lateral to the first hole for the trapezoid ligament. Many procedures involving one hole frequently drilled a hole at the midpoint between the center of the insertion of the conoid and trapezoid ligaments. Coale *et al.*<sup>21</sup> defined bone tunnels at 36.3 mm in men and 32.9 mm in women medial to the acromioclavicular joint. Regarding the differences between single and double tunnels for CCL reconstruction, Banffy *et al.*<sup>31</sup> demonstrated equivalent biochemical properties of single tunnels, with a theoretically lower risk of clavicle fracture to those of double tunnels. Therefore, it is reasonable for surgeons to reconstruct CCL with a single tunnel. Xue *et al.*<sup>26</sup> measured a series of clavicle parameters in a Chinese population, reporting that the conoid ligament was  $37.7 \pm 2.7$  mm and  $33.7 \pm 3.0$  mm medial to the acromioclavicular joint and  $11.8 \pm 3.5$  mm and  $13.3 \pm 1.3$  mm posterior to anterior margin of the clavicle in men and women, respectively. They also reported that the trapezoid ligament was  $23.0 \pm 1.3$  mm and  $20.8 \pm 3.2$  mm medial to the acromioclavicular joint and was  $9.8 \pm 1.6$  mm and  $9.0 \pm 0.7$  mm posterior to the anterior margin of the clavicle, respectively. These measurements corresponded to midpoints between the center of insertion of the conoid and trapezoid ligaments of 30.35 mm in men and 27.25 mm in women medial to the lateral edge of the clavicle and 10.8 mm in men and 11.15 mm in women posterior to the anterior margin of the clavicle. In the present study, the cP was located 29.24 and 26.66 mm medial to the lateral edge of the clavicle in men and women, respectively, similar to the results reported by Xue *et al.* Therefore, a 4.5-mm bone tunnel located at 29.24 and 26.66 mm medial to the lateral edge of the clavicle and 10.8 and 11.15 mm posterior to the anterior margin of the clavicle are recommended in men and women, respectively.

### Strengths and Limitations

The study's strengths is that we applied the method of overlapping CT images of the coracoid process and clavicle to a Chinese population to guide the clinical selection of accurate location of coracoclavicular ligament repair. The limitations of our study include (i) the need for additional biomechanical tests to assess the applicability of point cP in clinical practice and (ii) the need to assess the generalizability of these findings beyond the Chinese population in this study.

### Conclusion

The results of this study demonstrated the use of CT scans to identify point cP for the insertion of bone tunnels for CCL reconstruction. In clinical practice, surgeons can drill holes at  $28.02 \pm 3.43$  and  $25.20 \pm 3.26$  mm from the tip of the coracoid process in men and women, respectively. The medial-lateral widths through the holes in the coracoid process were  $22.78 \pm 2.80$  mm in men and  $20.21 \pm 2.97$  mm in women, with thicknesses of  $15.11 \pm 2.13$  and  $13.03 \pm 1.77$  mm,

respectively. Holes should also be drilled at  $29.24 \pm 3.84$  mm and  $26.66 \pm 3.45$  mm from the holes in the clavicle to the acromioclavicular joint in men and women, respectively. The anteroposterior widths through the holes were  $18.27 \pm 2.46$  mm in men and  $16.10 \pm 2.30$  mm in women, with thicknesses of  $10.09 \pm 1.56$  mm and  $8.91 \pm 1.40$  mm, respectively. The small measurements in female patients compared to those in male patients indicate the need for additional caution in performing the procedure in women.

### Acknowledgments

The authors extend their appreciation to all patients who agreed to participate in this study and the Affiliated Traditional Chinese Medicine Hospital of Southwest Medical University for providing all the equipment.

### Author Contributions

Guoyou Wang contributed to conception and design of study. Lei Zhang, Lujing Xiong, and Xin Zhou contributed to writing and editing this manuscript. Bingkun Li contributed to data collection and literature search. Xiaogao Tang contributed to protocol and project development of study. All authors read and approved the final manuscript. Lei Zhang, Lujing Xiong, and Xin Zhou equally contributed to writing and editing this manuscript. Bingkun Li and Xiaogao Tang contributed to collecting data and pictures and searching the literature. Guoyou Wang contributed to conception and design of the study.

### Conflict of Interest

No conflict of interest exists in the submission of this manuscript, and the manuscript is approved by all authors for publication.

### Ethics Statement

All the procedures were approved by the Ethics Inspection Committee at Affiliated Traditional Chinese Medicine Hospital of Southwest Medical University (No. KY2018032). All patients signed a General Consent of the Ethical Committee of Affiliated Traditional Chinese Medicine Hospital of Southwest Medical University for using and publishing their data for scientific use.

### Funding Information

This work was supported by National Natural Science Foundation of China (Youth Science Foundation Project) (82004458), Traditional Chinese Medicine Research Project of Sichuan Traditional Chinese Medicine Administration (2020JC0138), and Southwest Medical University Research Project (2020ZRQNA045).

### Data Availability Statement

The datasets generated and analyzed during the current study are available from the corresponding author on reasonable request



## References

1. Tauber M. Management of acute acromioclavicular joint dislocations: current concepts. *Arch Orthop Trauma Surg.* 2013;133:985–95.
2. Nolte PC, Lacheta L, Dekker TJ, Elrick BP, Millett PJ. Optimal management of acromioclavicular dislocation: current perspectives. *Orthop Res Rev.* 2020;12:27–44.
3. Longo UG, Ciuffreda M, Rizzello G, Mannering N, Maffulli N, Denaro V. Surgical versus conservative management of type III acromioclavicular dislocation: a systematic review. *Br Med Bull.* 2017;122:31–49.
4. Beitzel K, Mazzocca A, Bak K, Itoi E, Kibler W, Mirzayan R, et al. ISAKOS upper extremity committee consensus statement on the need for diversification of the rockwood classification for acromioclavicular joint injuries. *Arthroscopy.* 2014;30:271–8.
5. Beitzel K, Cote M, Apostolakis J, Solovyova O, Judson CH, Ziegler CG, et al. Current concepts in the treatment of acromioclavicular joint dislocations. *Arthroscopy.* 2013;29:387–97.
6. Meda PV, Machani B, Sinopidis C, Braithwaite I, Brownson P, Frostick SP. Clavicular hook plate for lateral end fractures: a prospective study. *Injury.* 2006;37:277–83.
7. Chen CH, Dong QR, Zhou RK, Zhen HQ, Jiao YJ. Effects of hook plate on shoulder function after treatment of acromioclavicular joint dislocation. *Int J Clin Exp Med.* 2014;7:2564–70.
8. Mazzocca AD, Santangelo SA, Johnson ST, Rios CG, Dumonski ML, Arciero RA. A biomechanical evaluation of an anatomical coracoclavicular ligament reconstruction. *Am J Sports Med.* 2006;34:236–46.
9. Weaver J, Dunn H. Treatment of acromioclavicular injuries, especially complete acromioclavicular separation. *J Bone Joint Surg Am.* 1972;54:1187–94.
10. Jari R, Costic RS, Rodosky MW, Debski RE. Biomechanical function of surgical procedures for acromioclavicular joint dislocations. *Arthroscopy.* 2004;20:237–45.
11. Lee SJ, Nicholas SJ, Akizuki KH, McHugh MP, Kremenic JJ, Ben-Avi S. Reconstruction of the coracoclavicular ligaments with tendon grafts: a comparative biomechanical study. *Am J Sports Med.* 2003;31:648–55.
12. Xue C, Song LJ, Zhang H, Tang GL, Li X, Fang JH. Truly anatomic coracoclavicular ligament reconstruction with 2 endobutton devices for acute rockwood type V acromioclavicular joint dislocations. *J Shoulder Elb Surg.* 2018;27:e196–202.
13. Struhl S, Wolfson TS. Continuous loop double endobutton reconstruction for acromioclavicular joint dislocation. *Am J Sports Med.* 2015;43:2437–44.
14. Garofalo R, Ceccarelli E, Castagna A, Calvisi V, Flanagan B, Conti M, et al. Open capsular and ligament reconstruction with semitendinosus hamstring autograft successfully controls superior and posterior translation for type V acromioclavicular joint dislocation. *Knee Surg Sports Traumatol Arthrosc.* 2017;25:1989–94.
15. Grutter P, Petersen S. Anatomical acromioclavicular ligament reconstruction: a biomechanical comparison of reconstructive techniques of the acromioclavicular joint. *Am J Sports Med.* 2005;33:1723–8.
16. Koh KH, Shon MS, Choi NH, Lim TK. Anatomic tunnel placement is not feasible by transclavicular-transcoracoid drilling technique for coracoclavicular reconstruction: a cadaveric study. *Arthroscopy.* 2018;34:2012–7.
17. Park I, Itami Y, Hedayati B, Bitner B, McGarry MH, Lee TQ, et al. Biomechanical analysis of single-, double-, and triple-bundle configurations for coracoclavicular ligament reconstruction using cortical fixation buttons with suture tapes: a cadaveric study. *Arthroscopy.* 2018;34:2983–91.
18. Costic RS, Labriola JE, Rodosky MW, Debski RE. Biomechanical rationale for development of anatomical reconstructions of coracoclavicular ligaments after complete acromioclavicular joint dislocations. *Am J Sports Med.* 2004;32:1929–36.
19. Walz L, Salzmann GM, Fabbro T, Eichhorn S, Imhoff AB. The anatomic reconstruction of acromioclavicular joint dislocations using 2 TightRope devices: a biomechanical study. *Am J Sports Med.* 2008;36:2398–406.
20. Thomas K, Litsky A, Jones G, Bishop JY. Biomechanical comparison of coracoclavicular reconstructive techniques. *Am J Sports Med.* 2011;39:804–10.
21. Coale RM, Hollister SJ, Dines JS, Allen AA, Bedi A. Anatomic considerations of transclavicular-transcoracoid drilling for coracoclavicular ligament reconstruction. *J Shoulder Elb Surg.* 2013;22:137–44.
22. Sella GDV, Miyazaki AN, Nico MAC, Filho GH, Silva LA, Checchia SL. Study on the anatomic relationship between the clavicle and the coracoid process using computed tomography scans of the shoulder. *J Shoulder Elb Surg.* 2017;26:1740–7.
23. Izadpanah K, Weitzel E, Honal M, Winterer J, Vicari M, Maier D, et al. In vivo analysis of coracoclavicular ligament kinematics during shoulder abduction. *Am J Sports Med.* 2012;40:185–92.
24. Banffy MB, van Eck CV, Elattrache N. Clinical outcomes of a single-tunnel technique for coracoclavicular and acromioclavicular ligament reconstruction. *J Shoulder Elb Surg.* 2018;27:S70–5.
25. Salzmann GM, Paul J, Sandmann GH, Imhoff AB, Schöttle PB. The coracoid insertion of the coracoclavicular ligaments: an anatomic study. *Am J Sports Med.* 2008;36:2392–7.
26. Xue C, Song LJ, Zhang M, Zheng TS, Fang JH, Li X. Coracoclavicular ligament attachment regions of the Chinese population: a quantitative anatomic study. *Anat Sci Int.* 2013;88:189–94.
27. Zhang J, Zhang P, Wu L, Su J, Shen J, Fan H, et al. Application of an individualized and reassemblable 3D printing navigation template for accurate puncture during sacral neuromodulation. *NeuroUrol Urodyn.* 2018;37:2776–81.
28. Campbell S, Heckmann N, Shin S, Wang LC, Tamboli M, Murachovsky J, et al. Biomechanical evaluation of coracoid tunnel size and location for coracoclavicular ligament reconstruction. *Arthroscopy.* 2015;31:825–30.
29. Ferreira JV, Chowaniec D, Obopilwe E, Nowak MD, Arciero RA, Mazzocca AD. Biomechanical evaluation of effect of coracoid tunnel placement on load to failure of fixation during repair of acromioclavicular joint dislocations. *Arthroscopy.* 2012;28:1230–6.
30. Beitzel K, Obopilwe E, Chowaniec D, Nowak M, Niver G, Hanypsiak B, et al. Biomechanical comparison of arthroscopic repairs for acromioclavicular joint instability: suture button systems without biological augmentation. *Am J Sports Med.* 2011;39:2218–25.
31. Banffy MB, Uquillas C, Neumann JA, ElAttrache NS. Biomechanical evaluation of a single-versus double-tunnel coracoclavicular ligament reconstruction with acromioclavicular stabilization for acromioclavicular joint injuries. *Am J Sports Med.* 2018;46:1070–6.