

Unusual Orange-Colored Choroidal Metastases

Hatem Krema, MD, FRCSEd; Hugh McGowan, MD, FRCSC; Herbert Tanzer, MD, FRCSC
Rand Simpson, MD, FRCSC; Normand Laperriere, MD, FRCPC

Departments of Ocular & Radiation Oncology, Princess Margaret Cancer Center, University of Toronto, Toronto, ON, Canada

Purpose: To report the clinical and paraclinical features of two patients with orange-colored choroidal metastases in whom the primary cancers have not previously been associated with such lesions.

Case Report: Orange-colored choroidal lesions were detected on the fundus examination of one patient with metastatic small cell neuroendocrine tumor of the larynx and oropharynx, and in another subject with metastatic alveolar soft part sarcoma of the leg. Although ultrasonographic characteristics of the choroidal masses were comparable to those of choroidal hemangiomas, fluorescein angiography revealed delayed initial fluorescence along with minimal fluorescence in subsequent phases of the angiogram which were in clear distinction from the earlier appearing and progressively intense fluorescence observed with circumscribed choroidal hemangiomas.

Conclusion: Small cell neuroendocrine tumors and alveolar soft part sarcomas should be considered among the differential diagnoses for orange-colored choroidal metastases. Identifying these choroidal lesions could facilitate localizing the occult primary tumor. Fluorescein angiography may differentiate a unifocal orange choroidal metastasis from a circumscribed choroidal hemangioma.

Keywords: Eye; Metastasis; Color; Orange; Neuroendocrine; Sarcoma

J Ophthalmic Vis Res 2013; 8 (1): 53-57.

Correspondence to: Hatem Krema, MD. Assistant Professor of Ophthalmology, Ocular Oncology Service, Princess Margaret Cancer Center, University of Toronto, 610 University Avenue, Toronto M5G 2M9, ON, Canada; Tel: +1 416 946 2000 ext 5524, Fax: +1 416 9462773; e-mail: htmkrm19@yahoo.com

Received: October 23, 2012

Accepted: December 19, 2012

INTRODUCTION

Choroidal metastases constitute the most frequent intraocular malignancy among adults, yet in practice, they are less frequently encountered than choroidal melanomas since the majority of cases have far advanced systemic metastases drawing attention away from ophthalmic screening.^{1,2} Nearly one-third of patients with choroidal metastases have no history of cancer and the ophthalmologist may be the first physician to detect the primary tumor.^{1,3}

The color of these lesions may help localize the primary tumor; breast and lung cancers which constitute more than two-thirds of choroidal metastases, are typically yellowish-

white in color whereas metastatic cutaneous melanoma is usually brown.^{2,3} Orange-colored choroidal metastases have previously been reported to occur secondary to carcinoid tumors, thyroid cancer and renal cell carcinoma.⁴⁻⁸ It is of importance to distinguish unifocal orange-colored metastases from a choroidal hemangioma or a highly vascular amelanotic melanoma to avoid misdiagnosis.

The objective of the current report is to describe two patients with metastatic choroidal lesions whose primary cancers were not previously reported to be associated with orange-colored choroidal metastases, and to add them to the differential diagnoses of such lesions.

CASE REPORTS**Case 1**

A 49-year-old Caucasian man was referred for deterioration of vision of 2 months' duration. He had been diagnosed with high-grade small cell neuroendocrine carcinoma involving the larynx and oropharynx one year earlier; multiple massive regional lymph nodes and visceral metastases had failed to respond to cisplatin and etoposide combination chemotherapy. The patient had been a heavy smoker for over 25 years.

Visual acuity was 20/30 in the right eye and counting fingers in the left one. The significant finding on ophthalmic examination was the presence of bilateral multiple orange-colored

solid choroidal masses. There were four lesions on the right side, one partially involving the fovea and two larger masses in the left eye, one involving the macular area associated with exudative retinal detachment (Fig. 1A).

Ultrasonography demonstrated dome-shaped choroidal lesions of various thickness which appeared acoustically echogenic on B-scan without choroidal excavation (Fig. 1B), and with moderate to high internal reflectivity on A-scan.

Fluorescein angiography of the left macular tumor showed very faint fluorescence 22 seconds after dye injection. Fluorescence of these masses however did not show a significant increase during subsequent phases of the angiogram, reaching maximum fluorescence at 5 minutes

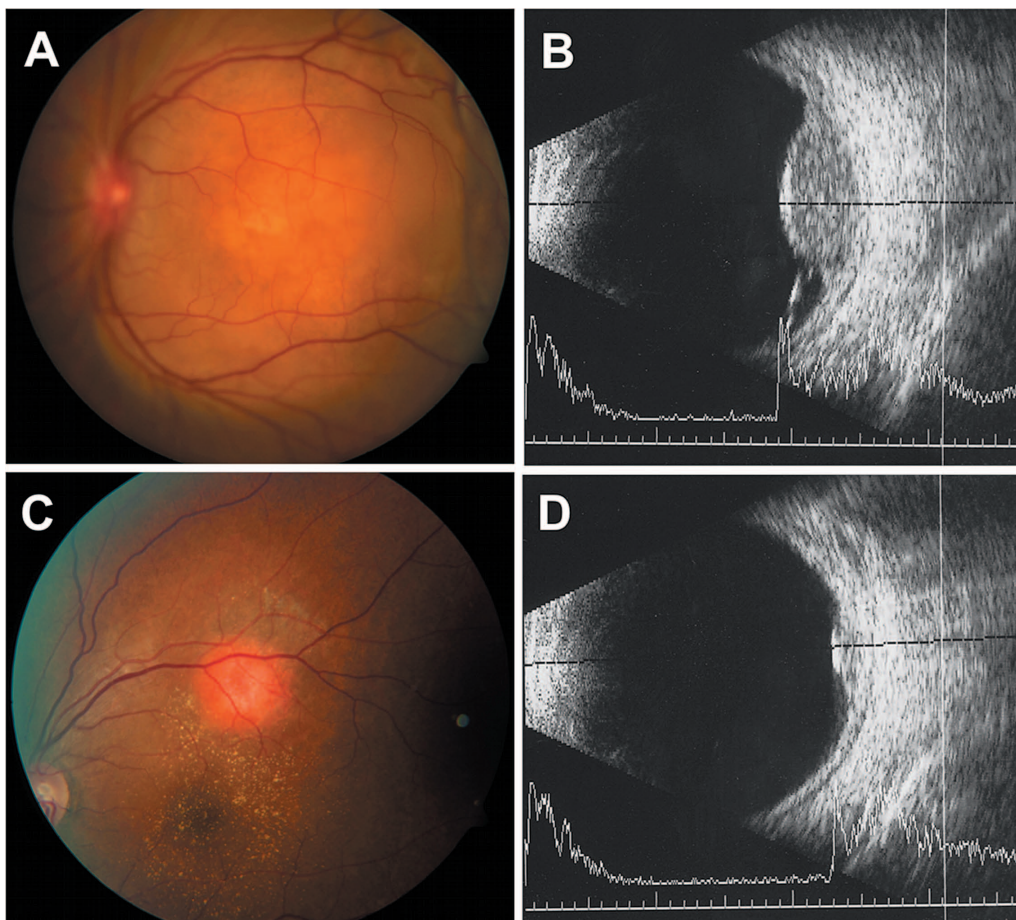


Figure 1 A, Fundus photograph of the left eye in case 1 demonstrates multifocal orange-colored choroidal metastases involving the macula; B, B-scan ultrasound of the lesion in 1A appears acoustically echogenic and associated with retinal detachment, and medium to high internal reflectivity on A-scan; C, Fundus photograph of case 2 illustrates a unifocal orange-colored choroidal metastasis; D, B-scan ultrasound of the lesion in 1C appears as a small acoustically echogenic mass with medium to high internal reflectivity on A-scan.

(Figures 2A, B, and C). The patient passed away two weeks after the ocular examination from advanced metastatic brain disease.

Case 2

A 38-year-old African female was referred for blurred vision of 2 weeks' duration. With a diagnosis of alveolar soft part sarcoma of the right leg five years earlier, she had initially received chemotherapy followed by below-knee amputation of her right leg. Multiple pulmonary metastases, appearing the following year, were surgically resected from five lung lobes. Three years later, she developed brain metastases that were treated with whole brain irradiation sparing the eyes, with total dose of 3000 centiGray (cGy) in 10 fractions.

On ocular examination, visual acuity was

20/20 and 20/50 in the right and left eyes, respectively. Funduscopy revealed a single bright orange-colored choroidal mass, 3.2 mm in diameter, superotemporal to the foveola, with exudation at its base extending into the fovea (Fig. 1C).

Ultrasonography displayed a small dome-shaped choroidal mass that appeared acoustically echogenic on B-scan (Fig. 1D), with moderate to high internal reflectivity on A-scan, similar to that observed with choroidal hemangiomas.

Fluorescein angiography showed very faint, mottled fluorescence of the lesion 21 seconds after dye injection, no significant increase in later phases of the angiogram and reaching maximum fluorescence at 5 minutes and (Figures 2 D, E, and F).

These findings indicated limited vascularity of the lesion as an explanation for its bright orange

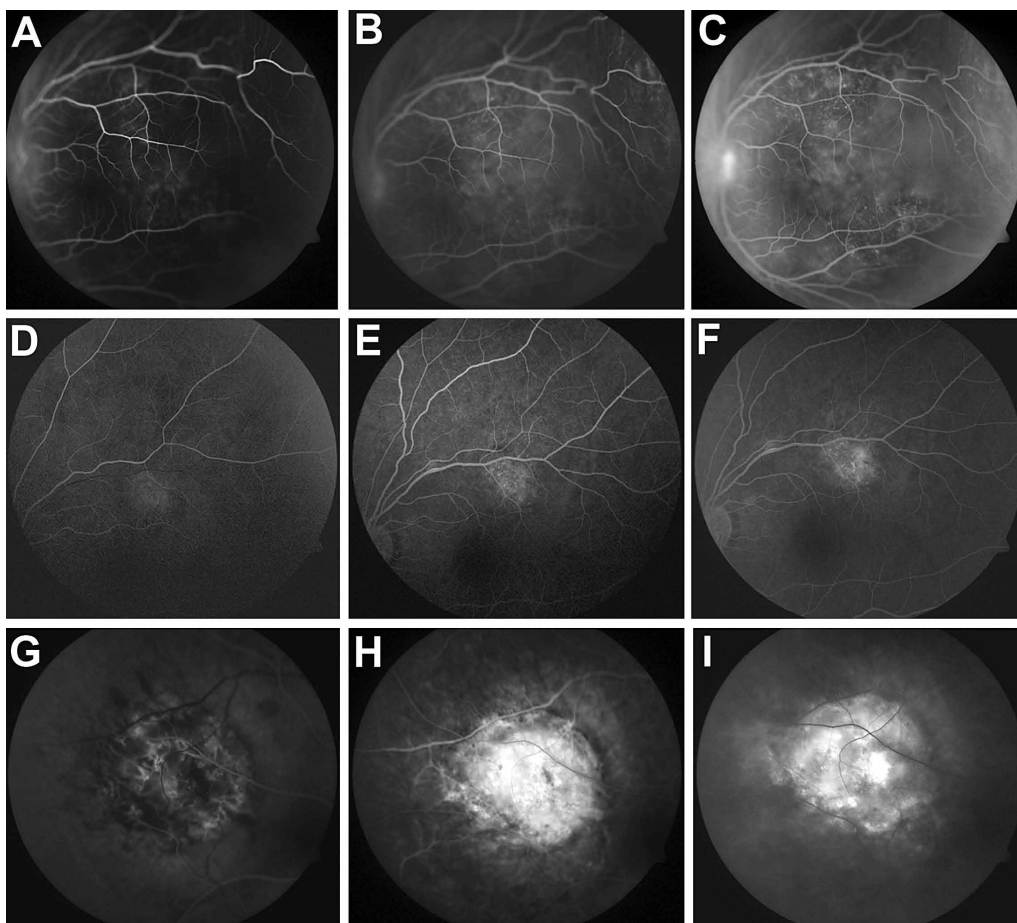


Figure 2. Fluorescein angiography of the choroidal metastasis in case 1 at 20 seconds (A), 60 seconds (B), and 5 minutes (C). Fluorescein angiography of choroidal metastasis in case 2 at 21 seconds (D), 63 seconds (E), and 5 minutes (F). Fluorescein angiography of a typical circumscribed choroidal hemangioma at 17 seconds (G), 60 seconds (H), 5 minutes (I).

color, as compared to the typical fluorescein angiography features of a circumscribed choroidal hemangioma (Figures 2 G, H, and I).

The choroidal mass was treated with 2000 cGy stereotactic irradiation delivered in 5 fractions which caused eventual shrinkage of the lesion into a gray-white gliotic scar.

DISCUSSION

Although infrequently encountered in clinical practice, uveal metastases represent the most common intraocular malignancy among adults based on autopsy studies of fatal cancer cases and reports of cancer patients screened for asymptomatic uveal metastases.^{1,2} Up to one third of the cases report no history of cancer.^{2,3} Hence, the ophthalmologist may lead the exploration to find the primary occult origin in this fraction of patients by recognizing the clinical features of their ocular metastases.

Choroidal metastases constitute 88% of uveal metastases and typically involve the post-equatorial region of the fundus. Unilateral involvement is more frequent than bilaterality, and unifocal presentation is more common than multifocal lesions.³ The color of these choroidal metastases is a valuable clinical clue in the search for their primary origin. Metastases from the breast or lung are gray to yellowish in color and a unifocal metastasis may simulate an amelanotic choroidal melanoma. Metastatic melanotic melanoma from the skin or the opposite choroid is often pigmented and a unifocal tumor can simulate a melanotic choroidal melanoma.¹⁻³ Orange-colored choroidal metastases are rare and a unifocal metastasis may appear like a circumscribed choroidal hemangioma. Orange metastases were previously reported to be secondary to carcinoid tumors, follicular and papillary thyroid carcinoma and renal cell carcinoma.⁴⁻⁸

Carcinoid tumors are identified as well-differentiated tumors of neuroendocrine cells, with an overall 5-year survival rate of 70%. Although cells with neuroendocrine differentiation are ubiquitous, 65% of carcinoid tumors develop from the gastrointestinal tract and 25% from the bronchopulmonary tree.⁹

Carcinoid tumors can be associated with over-secretion of bioactive peptides, mainly serotonin, producing the carcinoid syndrome, characterized by variable manifestations including diarrhea, flushing, hypotension or bronchospasm. Carcinoid syndrome may be the initial manifestation of an occult carcinoid tumor.^{9,10}

In contrast, small cell neuroendocrine carcinoma of the larynx (case 1), which similar to carcinoid tumors develops from neuroendocrine-differentiated cells, is a poorly differentiated cancer with an overall 5-year survival of almost 5%.¹¹ In contrast to carcinoid tumors, this carcinoma has a strong established link with cigarette smoking and may be associated with paraneoplastic syndromes such as the syndromes of inappropriate antidiuretic hormone secretion, ectopic adrenocorticotrophic hormone (ACTH) secretion and Eaton-Lambert syndrome.^{9,11} None of these conditions, however, were present in our patient. In a case report describing a patient with small cell carcinoma of the lung with neuroendocrine histological features, a unifocal orange choroidal metastasis was detected.¹² In another report, multiple bilateral choroidal metastases proven to be poorly differentiated small cell neuroendocrine carcinoma of unknown primary origin were described as whitish-red.¹³ Our first case suggests that orange-colored choroidal metastases could be secondary to small cell neuroendocrine tumors, which are biologically different from carcinoids. Accordingly, the search for an occult primary source of orange-colored choroidal metastases should also include the laryngopharyngeal region.

Alveolar soft part sarcoma (ASPS) accounts for 10% of sarcomas and commonly affects young women. The tumor is typically located in deep soft tissues, most often in the buttock and thigh, and less often in the arm, chest and retroperitoneal tissues. It runs an extended course along with late metastases, mainly to the lungs, brain and bone, and has an overall 5-year survival of 60%.¹⁴ A single case of ASPS choroidal metastasis was reported, in which the choroidal metastasis was described as white; it was incidentally discovered during post-mortem

autopsy of the eye of a patient who died from widespread metastases.¹⁵

The origin of the orange color of these choroidal metastases is not clear. Fluorescein angiography demonstrated less internal vascularity of these metastases as compared to hemangiomas. In a series of circumscribed choroidal hemangiomas, 80% showed the onset of fluorescence to occur during arterial and pre-arterial phases of the angiogram at a mean of 24 seconds, and 88% achieved maximum fluorescence by the full venous phase at a mean of 76.3 seconds.¹⁶ The two cases described herein had similar appearance to choroidal hemangiomas in terms of the onset of fluorescence, probably because the dye can reach the entire choroidal lesions at the same time. Nevertheless, due to limited vascularity, there was considerable delay in reaching maximum fluorescence with noticeably less intensity of fluorescence when compared with hemangiomas.

In summary, small cell neuroendocrine carcinoma and alveolar soft part sarcoma should be regarded among the differential diagnoses of orange-colored choroidal metastases. Fluorescein angiography can be a useful, noninvasive method for differentiating a single orange-colored choroidal metastasis from a circumscribed hemangioma. Identifying these choroidal metastases could facilitate localizing their primaries, if still undiagnosed at the time of ocular metastasis.

Conflicts of Interest

None.

REFERENCES

1. Singh AD. Clinical ophthalmic oncology. WB Saunders Co; 2007.
2. Shields JA, Shields CL. Atlas of intraocular tumors. Lippincott Williams & Wilkins; 1999.
3. Shields CL, Shields JA, Gross NE, Schwartz GP, Lally SE. Survey of 520 uveal metastases. *Ophthalmology* 1997;104:1265-1276.
4. Harbour W, De Potter P, Shields CL, Shields JA. Uveal metastasis from carcinoid tumor. Clinical observation in nine cases. *Ophthalmology* 1994;101:1084-1090.
5. Fajnkuchen F, Gatinel D, Le TL, Chaine G. Choroidal metastases of a bronchial carcinoid tumor. Review of cases in the literature. A case report. *J Fr Ophtalmol* 1998;21:214-219.
6. Ritland JS, Eide N, Walaas L, Høie J. Fine-needle aspiration biopsy diagnosis of a uveal metastasis from a follicular thyroid carcinoma. *Acta Ophthalmol Scand* 1999;77:594-596.
7. Singh U, Kaushik S, Pandav SS, Dogra MR, Powari M, Das A, et al. Papillary carcinoma thyroid presenting as a choroidal metastasis. Report of a case and brief review of literature. *Indian J Ophthalmol* 2003;51:81-83.
8. Haimovici R, Gragoudas ES, Gregor Z, Pesavento RD, Mieler WF, Duker JS. Choroidal metastases from renal cell carcinoma. *Ophthalmology* 1997;104:1152-1158.
9. Zuetenhorst JM, Taal BG. Metastatic carcinoid tumors: a clinical review. *Oncologist* 2005;10:123-131.
10. Schnirer II, Yao JC, Ajani JA. Carcinoid-a comprehensive review. *Acta Oncol* 2003;42:672-692.
11. Ferlito A, Barnes L, Rinaldo A, Gnepp DR, Milroy CM. A review of neuroendocrine neoplasms of the larynx: update on diagnosis and treatment. *J Laryngol Otol* 1998;112:827-834.
12. Trichopoulos N, Augsburger JJ. Neuroendocrine tumours metastatic to the uvea: diagnosis by fine needle aspiration biopsy. *Graefes Arch Clin Exp Ophthalmol* 2006;244:524-528.
13. Nicolò M, Piccolino FC, Ghiglione D, Nicolò G, Calabria G. Multiple bilateral choroidal metastatic tumors from a small-cell neuroendocrine carcinoma of unknown primary site. *Eur J Ophthalmol* 2005;15:148-152.
14. Folpe AL, Deyrup AT. Alveolar soft-part sarcoma: a review and update. *J Clin Pathol* 2006;59:1127-1132.
15. Pak W, Glasgow BJ, Brown HH, Foos RY. Intraocular metastasis of alveolar soft part sarcoma. Case report. *Arch Ophthalmol* 1987;105:894-895.
16. Arevalo JF, Shields CL, Shields JA, Hykin PG, De Potter P. Circumscribed choroidal hemangioma: characteristic features with indocyanine green videoangiography. *Ophthalmology* 2000;107:344-350.