

Congenital Insensitivity to Pain with Anhidrosis: A Rare Entity

Sir,

Congenital insensitivity to pain with anhidrosis (CIPA), also known as hereditary sensory and autonomic neuropathy type IV (HSAN IV), is an autosomal recessive disorder. It is characterized by the absence of sensitivity to pain (and temperature) since birth, anhidrosis, intellectual disability, unintentional self-injury (and delayed wound healing), and recurrent episodes of hyperpyrexia (because of anhidrosis). Repeated injuries may result in multiple fractures, joint dislocation, joint deformity (Charcot joint) and osteomyelitis. It occurs because of a mutation in neurotrophic tyrosine receptor kinase 1 gene (*NTRK1*) that encodes the protein TrKA, a receptor tyrosine kinase for a nerve growth factor (NGF). CIPA lacks all the NGF-dependent neurons, which is responsible for the absence of pain sensation and anhidrosis.^[1] It is a rare disorder, with only a few reports from the Indian subcontinent.

A 4-year-old boy born to second-degree consanguineous parentage, presented with complaints of hyperpyrexia and recurrent ulcerations over fingertips because of biting and auto-amputation of the left little toe with an ulcer on the right little toe. He was born with an uneventful antenatal period by normal vaginal delivery, but the child did not cry after birth. The other two siblings were absolutely normal. The child was apparently normal until he started crawling, after which he started developing trauma-induced ulcers. There was a history of self-injury after the eruption of primary teeth, by biting fingertips, lips, and tongue. His parents noticed that he did not respond to painful and thermal stimuli (burn because of hot utensils, vaccination, and after fall). Delay in developmental milestones was also noted. The parents also noticed that the child did not sweat even on sun exposure and had recurrent episodes of elevated body temperature. There was no history of involuntary movements suggestive of tremor, chorea, athetosis, dystonia, and others. Family history was non-contributory.

On examination, the child appeared irritable and hyperactive. Cutaneous examination showed generalized xerosis; lichenified skin over hands, feet, and the joints of the lower limbs; and atrophic scars from previous injuries. Other notable findings were ulcers over the lower limbs and tips of fingers and auto-amputation of the left little toe [Figures 1-3]. The front-row teeth were missing [Figure 4]. Sensory examination revealed complete insensitivity to pain (pin prick) and temperature, but the sensations of vibration and fine touch were intact. Deep tendon reflexes were normal and superficial tendon reflexes were sluggish. Cold pressure test was negative. Complete hemogram and biochemical tests, including serum uric acid, were within normal parameters. X-ray of both hands showed broken phalanges [Figure 5]. Histopathology

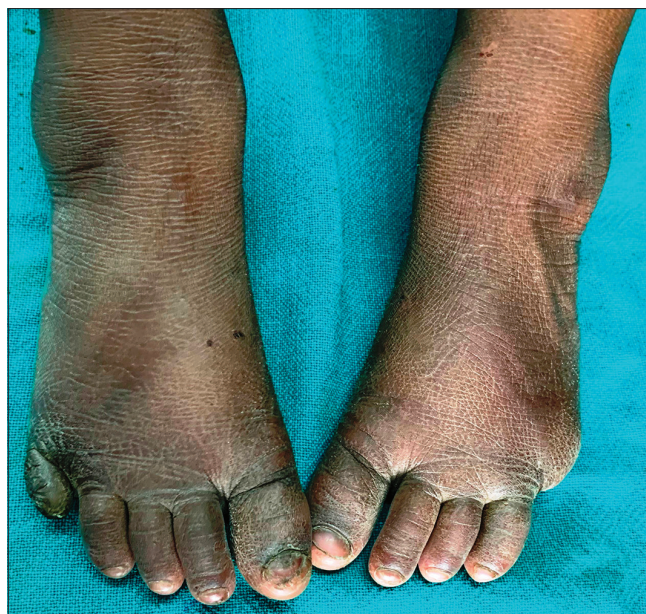

Figure 1: Ichthyosis and lichenification of the skin of lower limbs. Note the autoamputation of the left little toe

from the palmar skin showed unremarkable epidermis and dermal structures with the presence of normal-appearing sweat glands [Figure 6]. Nerve conduction velocity (NCV) study of both upper and lower extremities showed severe sensorimotor neuropathy. Based on clinical and histopathological findings, a diagnosis of CIPA was done. *NTRK1* molecular genetic testing could not be done because of logistic reasons. The patient was treated with appropriate antibiotics and emollients. Parents were explained about the disorder and they were counseled regarding preventive measures to be taken.

Half of the reported cases of CIPA/HSAN IV were seen in consanguineous parentage. Mutation in *NTRK1* results in the failure of differentiation and migration of neural crest cells, which causes a complete absence of small myelinated and unmyelinated nerve fibers, resulting in loss of pain and temperature sensation. The normally formed sweat glands lack the nerve supply, leading to anhidrosis.^[2]

The common findings in CIPA include recurrent episodes of fever, congenital insensitivity to pain and temperature, self-mutilation, intellectual disability, and anhidrosis, as seen in our patient. Uncommon features include joint deformity, multiple fractures, septic arthritis, neurotrophic keratitis, hyperkeratosis, and hypotonia, which were absent in the index case. Angular cheilitis (AC) and ulcers are present over the lips and on the ventral surface of the tongue, which are attributed to repeated biting. Anhidrosis leads to xerosis and lichenification. In addition, anhidrosis results in poor temperature control in summers, and early

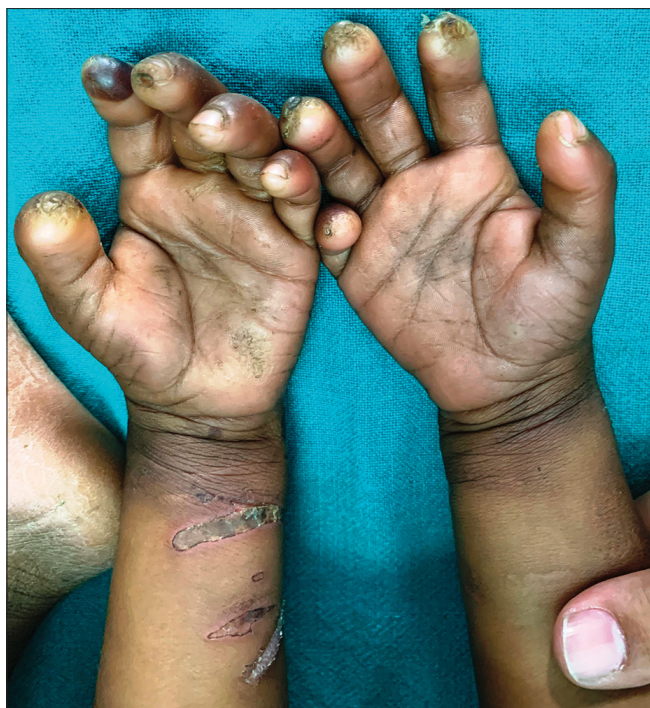

Figure 2: Ulcerations on the tips of the fingers. Note the ulcers and scarring on the forearms

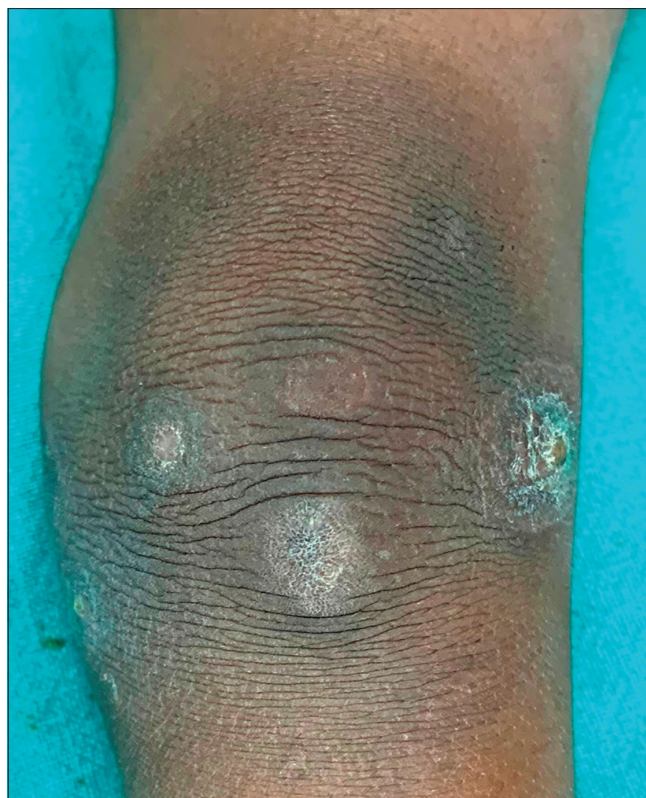

Figure 3: Atrophic scars (from previous injuries) on the knee joint

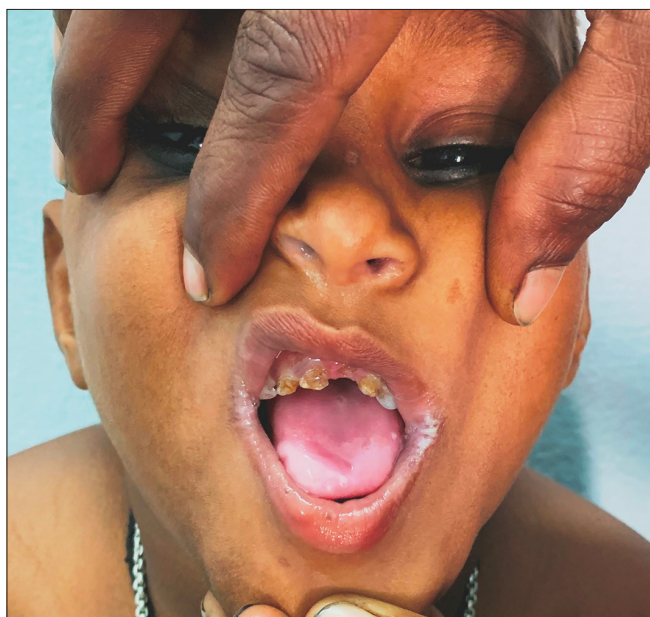


Figure 4: Absence of primary teeth in the front row

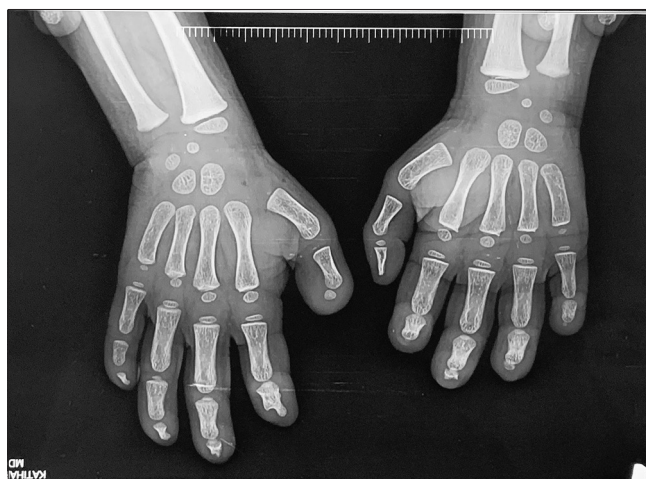


Figure 5: X-ray of both hands showing broken phalanges

deaths (within 3 years of life) because of hyperpyrexia have been reported.^[3,4] Various types of HSAN have been tabulated in Table 1. CIPA (HSAN IV) is unique among HSANs because it is associated with widespread anhidrosis.

The differential diagnoses for CIPA include other HSANs (discussed in Table 1); hypohidrotic ectodermal dysplasia (no evidence of generalized loss of pain sensation); Lesch–Nyhan syndrome (hyperuricemia, self-induced trauma, mental retardation, chorea, and athetosis); and

Hansen's disease (presence of hypopigmented hypoesthetic patches and enlargement of nerves). The battered baby syndrome should be considered in clinical differentials and needs to be ruled out. The diagnosis of CIPA is made by characteristic clinical features and pharmacological and histopathological findings. However, the confirmation is done by identification of biallelic pathogenic variants in *NTRK1*. The histamine test shows wheal but not flare in CIPA patients. Sweating in response to pilocarpine test is minimal or absent. Skin biopsy shows normal adnexal structures, including sweat glands, but dermal nerves and

Table 1: Types of Hereditary sensory and autonomic neuropathy

Type of HSAN	Clinical Features
Type I	Mild manifestation Present in 2 nd to 4 th decade of life Mainly affects the lower limb
Type II (Morvan's syndrome)	Hyporeflexia and hypotonia Acral anhidrosis and episodic hyperhidrosis Hearing impairment
Type III (Familial dysautonomia or Riley-Day syndrome)	Temperature and control of blood pressure are normal Multisystemic involvement Hyporeflexia, hypotonia, and ataxia Kyphoscoliosis Less impaired pain and temperature sensation with acral anhidrosis Abnormal gastro-esophageal mobility resulting in feeding difficulty and aspiration pneumonia
Type IV (Congenital insensitivity to pain and anhidrosis), consistent with our case	Episodes of hyperthermia Anhidrosis Insensitivity to pain Palmar skin is thickened Charcot joints are commonly present
Type V	It is similar to HSAN IV with relatively milder intellectual disability and anhidrosis
Type VI	Selectively affects nociception
Type VII	Similar to HSAN III Diarrhea, constipation, hyperhidrosis, pruritus, and muscular weakness

HSAN=Hereditary sensory and autonomic neuropathy

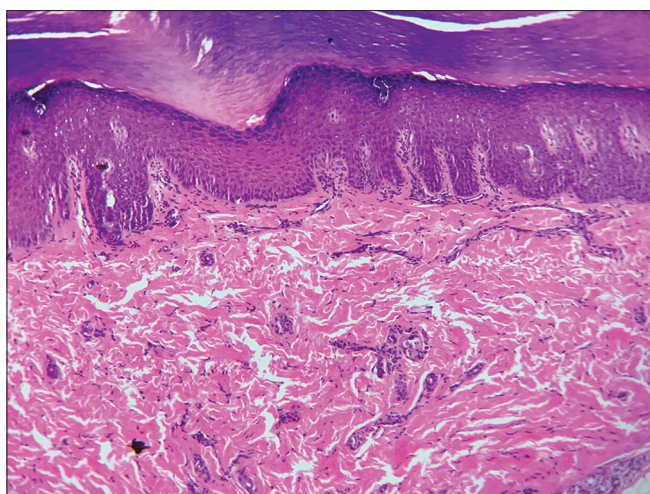


Figure 6: Photomicrograph showing unremarkable epidermis and dermal structures with the presence of normal-appearing sweat glands (H and E, 100×)

innervations to sweat glands are absent (confirmed by special stains for nerves). Sural nerve biopsy shows a reduction in the small unmyelinated and myelinated nerve fibers. However, the large fibers are normal.^[5]

Although there is no specific treatment modality for CIPA, it requires a multidisciplinary approach according to its

manifestations.^[6] The skin lesions and traumatic ulcers should be treated with antibiotics and emollients. Parents need to be educated about the condition and preventive measures that can be taken like avoiding excessive wrapping; frequent sponging to reduce hyperpyrexia and prevention of dehydration. Parents should also be asked to keep close attention of their kids to prevent injuries, burns, and self-mutilation. The treating pediatrician should be aware of diagnosis while giving treatment for hyperpyrexia to avoid unnecessary use of drugs. Due to frequent fractures, operative interventions are required in these children, and postoperative hypertension and tachycardia should raise the suspicion of inadequate analgesia. This occurs because of the unconscious physiologic response to pain though the patient is unaware of pain because of the decreased number of peripheral pain fibers.

As it is an autosomal recessive disorder, the importance of genetic counseling cannot be overemphasized. Parents should be explained about its genetic inheritance and consanguineous marriage should be discouraged. The identification of *NTRK1* mutation is the only tool for its prenatal diagnosis and it becomes necessary when there is a positive family history of CIPA. The limitation of our documentation is that we could not perform molecular genetic testing and sural nerve biopsy because of logistic difficulties.

Declaration of patient consent

The authors certify that they have obtained all appropriate patient consent forms. In the form the patient(s) has/have given his/her/their consent for his/her/their images and other clinical information to be reported in the journal. The patients understand that their names and initials will not be published and due efforts will be made to conceal their identity, but anonymity cannot be guaranteed.

Financial support and sponsorship

Nil.

Conflicts of interest

There are no conflicts of interest.

Priya Rajbansh, Mamta Yadav, Piyush Kumar, Anupam Das¹

*Department of Dermatology, Katihar Medical College, Bihar,
¹Department of Dermatology, KPC Medical College and Hospital,
 Kolkata, West Bengal, India*


Address for correspondence:

*Dr. Anupam Das,
 Department of Dermatology, KPC Medical College and Hospital,
 Kolkata, West Bengal, India.
 E-mail: anupamdasdr@gmail.com*

References

1. Udayashankar C, Oudeacoumar P, Nath AK. Congenital insensitivity to pain and anhidrosis: A case report from South India. *Indian J Dermatol* 2012;57:503.
2. Dahiya S, Vijayalakshmi KR, Khan M. Congenital insensitivity to pain: Case report of a rare entity. *Indian J Paediatr Dermatol* 2018;19:48-50.
3. Eregowda NI, Yadav S, Parameshwarappa P, Basavraj RK. A girl with no pain: Congenital insensitivity to pain and anhidrosis (HSAN) type IV - A case report. *J Clin Diagn Res* 2016;10:ZL01-2.
4. Sasnur AH, Sasnur PA, Ghaus-UI RS. Congenital insensitivity to pain and anhidrosis. *Indian J Orthop* 2011;45:269-71.
5. Pérez-López LM, Cabrera-González M, Gutiérrez-de la Iglesia D, Ricart S, Knörr-Giménez G. Update review and clinical presentation in congenital insensitivity to pain and anhidrosis. *Case Rep Pediatr* 2015;2015:589852.
6. Nabiye V, Kara A, Aksoy MC. Multidisciplinary assessment of congenital insensitivity to pain syndrome. *Childs Nerv Syst* 2016;32:1741-4.

This is an open access journal, and articles are distributed under the terms of the Creative Commons Attribution-NonCommercial-ShareAlike 4.0 License, which allows others to remix, tweak, and build upon the work non-commercially, as long as appropriate credit is given and the new creations are licensed under the identical terms.

Access this article online	
Website: www.idoj.in	Quick Response Code 
DOI: 10.4103/idoj.IDOJ_180_19	

How to cite this article: Rajbansh P, Yadav M, Kumar P, Das A. Congenital insensitivity to pain with anhidrosis: A rare entity. *Indian Dermatol Online J* 2020;11:274-7.

Received: April, 2019. **Accepted:** July, 2019. **Published:** March, 2020.

© 2020 Indian Dermatology Online Journal | Published by Wolters Kluwer- Medknow