

Percutaneous retrieval of an intracardiac central venous port fragment using snare with triple loops

Mehdi Ghaderian, Mohammad Reza Sabri, Ali Reza Ahmadi

Isfahan University of Medical Sciences, Child Growth and Development Research Center, Isfahan, Iran

Peripherally inserted venous ports fracture with embolization in patients who received chemotherapy is a serious and rare complication, and few cases have been reported in children. We report a successful endovascular technique using a snare for retrieving broken peripherally inserted venous ports in a child for chemotherapy. Catheter fragments may cause complications such as cardiac perforation, arrhythmias, sepsis, and pulmonary embolism. A 12-year-old female received chemotherapy for acute lymphocytic leukemia through a central venous port implanted into her right subclavian area. The patient completed chemotherapy without complications 6 months ago. Venous port was accidentally fractured during its removal. Chest radiographs of the patient revealed intracardiac catheter fragment extending from the right subclavian to the right atrium (RA) and looping in the RA. The procedure was performed under ketamine and midazolam anesthesia and fluoroscopic guidance using a percutaneous femoral vein approach. A snare with triple loops (10 mm in diameter) was used to successfully retrieve the catheter fragments without any complication. Percutaneous transcatheter retrieval of catheter fragments is occasionally extremely useful and should be considered by interventional cardiologists for retrieving migrated catheters and can be chosen before resorting to surgery, which has potential risks related to thoracotomy, cardiopulmonary bypass, and general anesthesia.

Key words: Percutaneous retrieval, port catheter, triple loops snare

How to cite this article: Ghaderian M, Sabri MR, Ahmadi AR. Percutaneous retrieval of an intracardiac central venous port fragment using snare with triple loops. *J Res Med Sci* 2015;20:97-9.

INTRODUCTION

Chemotherapy drug administration, total parenteral nutrition, transfusion of blood products, and blood sampling through a peripherally inserted central venous port have been widely used because of several advantages like improved patient satisfaction.^[1] Major complications include arrhythmia, bloodstream infection, vein thrombosis, and embolization may be seen among these patients. Catheter fracture with or without embolization is a serious and rare complication in children, and few cases have been reported.^[2-6] Management of fractured catheters includes open thoracotomy or midsternotomy retrieval or percutaneous transcatheter retrieval. Percutaneous transcatheter retrieval is an easy, safe, and efficient method among these techniques.

We report the successful percutaneous transcatheter retrieval of fractured catheter using snare with triple loops in one child.

CASE REPORT

A 12-year-old female was admitted with complaints of anemia and pallor at 8 years of age, and was

diagnosed as acute lymphoblastic leukemia by bone marrow aspiration and biopsy. After 3 years of systemic chemotherapy and remission of her disease, a peripherally inserted central venous port used for chemotherapy was accidentally fractured during its removal from the skin. The patient was asymptomatic; however, serial chest radiographs demonstrated of a long radiopaque venous port fragment from the end of right subclavian vein just at the junction to the superior vena cava (SVC) and lodged in this site. The distal tip was at the right atrium (RA) [Figure 1]. She referred to our clinic 5 months later for retrieval of the catheter.

Echocardiography showed the distal tip of the catheter fragment was in the RA without significant clot.

The patient and her parents were discussed, and percutaneous transcatheter retrieval technique via right femoral vein was chosen. Informed consents were obtained from the parents. The procedure was performed under mild anesthesia and fluoroscopic guidance. Ketamine (1-2 mg/kg/dose and midazolam 50-100 mcg/kg/dose, intravenous [i.v.]) were used for sedation and repeated if further sedation was necessary. Antibiotic (cefazolin, 50 mg/kg, i.v.) was administered

Address for correspondence: Dr. Mehdi Ghaderian, Isfahan University of Medical Sciences, Child Growth and Development Research Center, Imam Khomeini St., Isfahan, Iran. E-mail: ghader_45@yahoo.co.uk

Received: 11-02-2014; **Revised:** 02-07-2014; **Accepted:** 02-01-2015

during the procedure and first 24 h. 6F femoral sheath were placed in the right and left femoral veins. Injection in right subclavian, jugular and SVC revealed that the catheter was lodged at the junction of subclavian and SVC [Figure 2].

Looping of catheter was resolved using a pigtail catheter, and distal of catheter was brought to inferior vena cava (IVC). Then a 10 mm in diameter snare with triple loops was advanced from snare catheter to the IVC and snare advanced to proximal of catheter near to lodged site. At the beginning of the procedure, mild forces could not release the catheter from the site but by increasing force the catheter was released. The catheter fragment and snare were carefully pulled back until reaching the distal end of the femoral sheath [Figure 3].

The retrieved catheter fragment and snare introduced together into the femoral sheath in patient but in the middle of sheath because of sizing of sheath the catheter was divided into two parts by pulling back of snare and all of them were extracted gently from skin [Figure 4].

Injection in right subclavian and SVC from left femoral vein revealed no extravasation of contrast from veins. The total procedure times were 35 min, and fluoroscopy time was 6 min. After the procedure, patient was monitored, and chest radiographs at 4 and 24 h after procedure and echocardiographic examinations were normal. No major or minor complications such as arrhythmia, bleeding, vascular/

cardiac perforation or local hematoma were observed during or after the procedure.

DISCUSSION

We encountered a patient with a broken peripherally inserted central venous port in the right subclavian vein was successfully retrieved using a snare with triple loops.

The main complications of venous port are bloodstream infection and venous thrombosis.^[7,8] Catheter fracture with or without embolization is a serious and rare complication in adult patients.^[9] In children, the exact incidence is unknown and few cases have been reported.^[2-6] In general, broken catheter management includes percutaneous transcatheter retrieval, open thoracotomy or sternotomy, and long-term anticoagulation therapy. Percutaneous transcatheter retrieval is usually performed as the first choice for treatment of these complications. However, cases of cardiac tamponade following of a broken catheter have been discussed.^[7] Although, cardiac tamponade and RA perforation seldom occur, a fractured catheter may cause an increased incidence of thrombosis in the RA, which may cause clinical symptoms or may act as a source of infection. After discussing to patient and her parents, we considered the patient's requests and the possibility of complications, we chose percutaneous transcatheter retrieval of fractured catheter. Techniques for

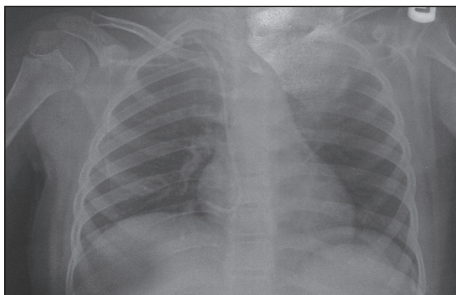


Figure 1: The proximal tip of the central venous port fragment lodged at the end of the right subclavian vein just at the junction to the superior vena cava and the distal tip was at the right atrium

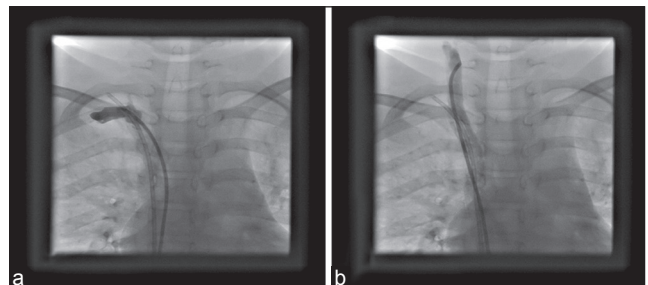


Figure 2: Injection in right subclavian (a) and jugular vein (b)

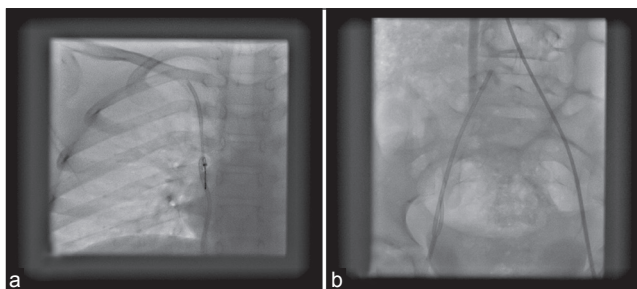


Figure 3: Angiographic views during percutaneous transcatheter retrieval. (a) The proximal tip of the catheter was captured with the snare. (b) The catheter fragment and snare were pulled back until reaching the distal end of the femoral sheath




Figure 4: The retrieved catheter fragments

nonsurgical retrieval of foreign materials include using a snare, basket catheter, pigtail catheter, ablation catheter or snare and suture.^[10-13] Baskets and forceps as the required sheath size is large are use in larger patients. Forceps have rigid construction, and traumatic property and baskets cannot be guided. Because of their simplicity of use, safety, flexibility, and availability, snares have been the most commonly preferred and widely used devices. The loop-snare technique has high success (98%) and low complication rates among adult cancer patients that reported by Cheng *et al.* (3.3%).^[9]

Improper procedure handling is the most common cause of catheter fracture. Compression of the catheter between the first rib and clavicle has been responsible for the deformed, fractured catheter resulting from repeated compress of the surrounding musculoskeletal system.

With early designs of loop-snare devices, as the snares had a loop oriented in the same axis of the introducer catheter, the retrieval procedure was difficult for operators. Hiroki Teragawa *et al.* in their report described that at first time their tries were unsuccessful because the catheter was lodged in the pulmonary artery wall, finally, a string was tied to the top of the snare, allowing them to curve the snare toward the pulmonary artery by pulling the string and the catheter body was grasped and retrieved. In our case, at first, we resolved looping of catheter using a pigtail catheter and distal of catheter was brought to IVC then we used three loop-snare for capture of the catheter. These snares facilitated easy capturing of foreign bodies when deployed. No complications were observed during our procedure. Our patient had no underlying problems (anemia, neutropenia, thrombocytopenia, immunodeficiency). Use of the femoral sheath with a larger size than catheter french size may facilitate our procedure and reduce our complications.

CONCLUSION

Catheter fracture with or without embolization may cause fatal complications, and they should be removed in most instances. Because of safe and successful, percutaneous transcatheter retrieval using loop-snare should be the technique of choice. Many children with malignancies and broken or embolized port catheters have underlying problems that make them poor candidates for surgical retrieval. Thoracotomy or sternotomy and cardiopulmonary bypass increase morbidity and mortality in these conditions. We suggest percutaneous transcatheter technique for retrieval of embolized or broken catheter fragments before resorting to surgery.

ACKNOWLEDGMENT

The article was supported by Isfahan University of Medical Sciences.

AUTHOR'S CONTRIBUTION

All authors have contributed in designing and conducting the study. All authors have assisted in preparation of the first draft of the manuscript or revising it critically for important intellectual content. All authors have read and approved the content of the manuscript and confirmed the accuracy or integrity of any part of the work.

REFERENCES

1. Chopra V, Anand S, Krein SL, Chenoweth C, Saint S. Bloodstream infection, venous thrombosis, and peripherally inserted central catheters: Reappraising the evidence. *Am J Med* 2012;125:733-41.
2. Fuenfer MM, Georgeson KE, Cain WS, Colvin EV, Johnson WH Jr, Pearce FB, *et al.* Etiology and retrieval of retained central venous catheter fragments within the heart and great vessels of infants and children. *J Pediatr Surg* 1998;33:454-6.
3. Andrews RE, Tulloh RM, Rigby ML. Percutaneous retrieval of central venous catheter fragments. *Arch Dis Child* 2002;87:149-50.
4. Bessoud B, de Baere T, Kuoch V, Desruennes E, Cosset MF, Lassau N, *et al.* Experience at a single institution with endovascular treatment of mechanical complications caused by implanted central venous access devices in pediatric and adult patients. *AJR Am J Roentgenol* 2003;180:527-32.
5. Yen HJ, Hwang B, Lee PC, Meng CC. Transcatheter retrieval of different types of central venous catheter fragment: Experience in 13 cases. *Angiology* 2006;57:347-53.
6. Uçar B, Kiliç Z, Ayata M, Tokar B, İlhan H. Percutaneous retrieval of an intracardiac catheter fragment using a snare-loop catheter. *Anadolu Kardiyol Derg* 2005;5:257.
7. Amerasekera SS, Jones CM, Patel R, Cleasby MJ. Imaging of the complications of peripherally inserted central venous catheters. *Clin Radiol* 2009;64:832-40.
8. Kock HJ, Pietsch M, Krause U, Wilke H, Eigler FW. Implantable vascular access systems: Experience in 1500 patients with totally implanted central venous port systems. *World J Surg* 1998;22:12-6.
9. Cheng CC, Tsai TN, Yang CC, Han CL. Percutaneous retrieval of dislodged totally implantable central venous access system in 92 cases: Experience in a single hospital. *Eur J Radiol* 2009;69:346-50.
10. Motta Leal Filho JM, Carnevale FC, Nasser F, Santos AC, Sousa Junior Wde O, Zurstrassen CE, *et al.* Endovascular techniques and procedures, methods for removal of intravascular foreign bodies. *Rev Bras Cir Cardiovasc* 2010;25:202-8.
11. Kawata M, Ozawa K, Matsuura T, Kuroda M, Hirayama Y, Adachi K, *et al.* Percutaneous interventional techniques to remove embolized silicone port catheters from heart and great vessels. *Cardiovasc Interv Ther* 2012;27:196-200.
12. Liem TK, Yanit KE, Moseley SE, Landry GJ, Deloughery TG, Rumwell CA, *et al.* Peripherally inserted central catheter usage patterns and associated symptomatic upper extremity venous thrombosis. *J Vasc Surg* 2012;55:761-7.
13. Teragawa H, Sueda T, Fujii Y, Takemoto H, Toyota Y, Nomura S, *et al.* Endovascular technique using a snare and suture for retrieving a migrated peripherally inserted central catheter in the left pulmonary artery. *World J Cardiol* 2013;5:369-72.

Source of Support: Nil. Conflict of Interest: None declared.