

Medial Patellofemoral Ligament Reconstruction: An Uncommon Solution for a Common Problem

Abstract

Patellofemoral dislocations are commonly encountered knee ailment. Although majority of the patients are managed conservatively, depending on the patients' demands and predisposing factors, patients with recurrent dislocations often require surgical intervention. The main aim of any surgical procedure should be to restore the anatomy of the soft tissue as well as the bony elements. We here describe a technique which combines transverse patella double tunnel technique with tibial tuberosity distalization and medicalization to reconstruct the medial patellofemoral ligament using a free autologous semitendinosus graft.

Keywords: Knee joint, recurrent patellar instability, medial patellofemoral ligament, tibial tuberosity

**Pinaki Das,
Arnab Karmakar**

*Department of Orthopaedics,
Institute of Post Graduate
Medical Education and
Research and Seth Sukhlal
Karni Memorial Hospital,
Kolkata, West Bengal, India*

Background

Patellofemoral joint instability is a commonly encountered orthopedic problem that has a combination of genetic predispositions and anatomic variations. Medial patellofemoral ligament (MPFL) has been identified as the major contributor to medial soft tissue restraint that prevents the lateral displacement of patella, contributing as much as 53% of the total force.^[1] Biomechanical studies have shown that recurrent patellar dislocation is associated with variations in the position of the tibial tuberosity (TT). Increased TT to trochlear groove (TT: TG) distance leads to the persistence of patellofemoral instability even if MPFL reconstruction is performed.^[2,3]

In this case report, a new method of MPFL reconstruction with transverse patellar double tunnel technique combined with TT transfer has been described.

Case Report

A 32-year-old female presented to our institution with complaints of left side recurrent patellar dislocation of five episodes over the past 3 years. The patient was clinically evaluated and found to have a positive apprehension test with a critical angle of dislocation at 50°. Routine

radiological investigations were done such as X-rays of the knee in Anteroposterior (AP), oblique, and merchant view. Computed tomography (CT) scan and magnetic resonance imaging of the left knee gave an impression of patellar translation with TT: TG distance measuring 21 mm [Figure 1a] and Insall–Salvati ratio of 1.1. The lateral trochlear inclination was 24° [Figure 1b] and trochlear depth was 4.6 mm. Tear of MPFL was confirmed with patchy subcutaneous edema and altered hyperintense signal on T2-weighted images.

Semitendinosus tendon was harvested using the standard graft harvesting technique. Preliminary diagnostic arthroscopy was performed to examine the undersurface of the patella and to evaluate the integrity of medial patellofemoral ligament [Figure 2a]. The graft incision that was applied medial to the TT was extended proximally and distally for TT transfer [Figure 2b]. After superficial subcutaneous dissection, the patellar ligament and TT were identified. A horizontal downward curvilinear cut of around 1-cm depth and parallel to the joint line was applied, followed by a vertical cut from lateral to medial which helped in obliquely elevating the tibial tuberosity. The distal 0.5 cm of the TT was excised with the help of a narrow oscillating saw blade. The remnant portion of the tuberosity was then pulled down in total as a sleeve to

Submitted: 07-Jul-2021
Revised: 02-Mar-2022
Accepted: 17-Mar-2022
Published: 10-May-2022

Address for correspondence:

*Dr. Pinaki Das,
B 1512, Sector 6, CDA,
Cuttack - 753 014, Odisha,
India.
E-mail: docpinakidas@outlook.
com*

Access this article online

Website:
www.ijabmr.org

DOI:
10.4103/ijabmr.ijabmr_445_21

Quick Response Code:



How to cite this article: Das P, Karmakar A. Medial patellofemoral ligament reconstruction: An uncommon solution for a common problem. *Int J App Basic Med Res* 2022;12:144-7.

This is an open access journal, and articles are distributed under the terms of the Creative Commons Attribution-NonCommercial-ShareAlike 4.0 License, which allows others to remix, tweak, and build upon the work non-commercially, as long as appropriate credit is given and the new creations are licensed under the identical terms.

For reprints contact: WKHLRPMedknow_reprints@wolterskluwer.com

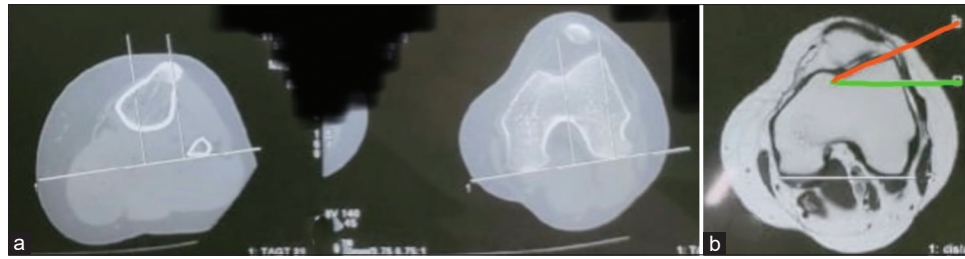


Figure 1: (a) Preoperative CT scan. TT: TG distance measuring 21 mm. (b) Preoperative MRI scan. Lateral trochlear inclination angle is 24° in this case. CT: Computed tomography, TT: TG: Tibial tuberosity to trochlear groove, MRI: Magnetic resonance imaging

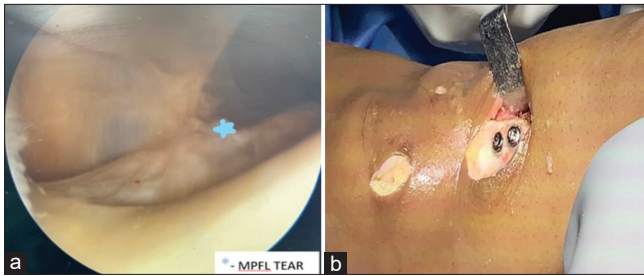


Figure 2: (a) Intraoperative images: Diagnostic arthroscopy done showing MPFL tear. (b) Intraoperative images: Tibial tuberosity after medial transfer and fixation with cortical screw. MPFL: Medial patellofemoral ligament

make the patellar ligament taut. It was then fixed with two 4.5-mm cortical lag screws at a more medial position than its native location with distance between the two screws being 1 cm [Figure 3a]. The patella was approached through a 3-cm medial parapatellar incision; the medial wall of the patella was exposed after dissection of the prepatellar fascia. Two guide pins were inserted in the patella in a horizontal orientation in the upper half. Half-length of the tunnels was drilled with a 4-mm cortical drill bit (Depuy®) with a space of 1.5 cm between them [Figure 3b]. The prepared graft was then inserted through the two transverse tunnels from medial to lateral, forming a loop, and the Ethibond sutures were taken out from the lateral side and secured with multiple knots.

The isometric point on the distal femur was evaluated with the help of lateral fluoroscopy using a variation of Schottle's technique [Figure 3c].^[4] A tissue plane was formed in between the joint capsule and subcutaneous tissue in the medial aspect of the knee by blunt dissection using curved artery forceps for the passage of the remnant graft [Figure 3d].

Subsequently, the medial epicondyle was palpated and was exposed using a small 1.5 cm incision. A guide pin was inserted from medial to lateral under fluoroscopy guidance through the isometric point, over which a 6-mm cortical drill bit was used to create a tunnel.

The U loop portion of the graft was then inserted into the medial tunnel with the help of a suture loop and a Beath pin. A bioabsorbable interference screw (Depuy Mitek®) of size 8 mm × 30 mm was inserted over the medial tunnel with the graft *in situ* at 30° of knee flexion [Figure 3e].

Sterile compression dressing was applied and the knee was immobilized in a long knee brace.

The patient was put on knee range of motion (ROM) exercise after the pain subsided, i.e., around 4–5 days following the intervention. Weight bearing was allowed 2 weeks after surgery with gradual resumption of normal activities over 12 weeks. Full flexion was achieved in 4 weeks.

The patient was followed up at 2 weeks, 6 weeks, 3 months, 6 months, one and half years, and 2 years after surgery with serial radiographs. The radiographs and functional ROM of the patient at 1-year and 2-year postintervention were documented [Figure 4a-c]. There were no complications noted, except mild anterior knee pain. There were no further episodes of patellar dislocation. Three months after the procedure, the patient was able to ambulate freely without complaint.

Discussion

MPFL disruption has a major contribution in predisposition to patellar dislocation.^[1] Recurrence is more in patients managed conservatively and in females with anatomical predisposition.^[5]

Mountney *et al.* have compared different tunnel positions and graft anchorage in cadavers and concluded that through tunnel tendon graft would have the most analogous strength to the native MPFL.^[6] Muneta *et al.* performed MPFL reconstruction in addition to the medial transfer of tibial tubercle on six patients with recurrent dislocation of the patella. The hamstring graft was passed through the second layer of the knee through a drill hole from the middle of the patella to its center, subsequently fixing it on the superficial surface of the bone, with an Endobutton.^[7]

Carmont and Maffulli described a transverse patellar double tunnel technique using a free autologous gracilis or semitendinosus graft. They concluded that their technique allowed a wider ligament base comprising a double thickness of hamstring and minimized graft impingement without increasing the risk of patellar fracture as compared to a single-tunnel technique.^[8]

In our case report, as half of the tunnel was drilled, we anticipated that there would be a cohesive graft–bone interface

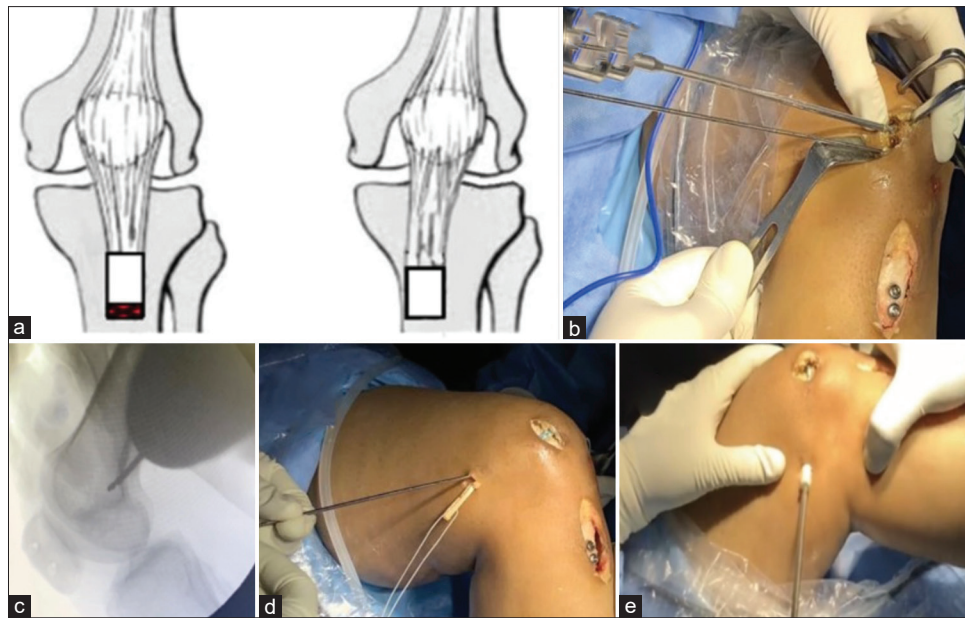


Figure 3: (a) Schematic illustration demonstrating the tibial tuberosity transfer. (b) Intraoperative images: Transverse double tunneling of patella being done (medial to lateral). (c) Intraoperative images: Isometric point identification by Schottle's technique under fluoroscopic guidance. (d) Intraoperative images: Insertion of graft through the second layer of the knee. (e) Intraoperative images: Interference screw fixation at 30° knee flexion

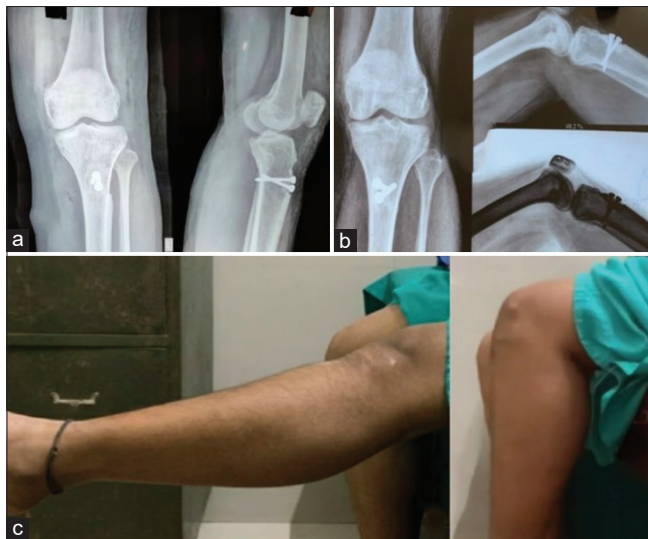

Figure 4: (a) Postoperative: radiograph at 1 year demonstrating uniting tibial tuberosity and no radiographic complication. (b) Postoperative: radiograph at 2 years demonstrating full tibial tuberosity union. (c) Postoperative: Excellent functional range of motion at 2 years after intervention

aiding the process of the graft union. The double graft would also impart less stress on the femur in flexion because of the fanned-out area of contact, substantially decreasing the incidence of impingement. Potential complications of a larger single tunnel in patella such as fracture or impingement are also avoided with this technique. We performed an additional bony procedure of TT distalization and medicalization to decrease the TT: TG distance and the Q-angle.

Conclusion

MPFL reconstruction is the need of the hour to address acute or chronic patellofemoral instability. Although an

isolated MPFL reconstruction is the preferred treatment option and is widely accepted, the inclusion of additional procedures should be individualized depending on the various anatomical predispositions such as TT: TG distance, trochlear dysplasia, and patellar tilt.

Consent to participate

Written informed consent was obtained from the patient for this procedure.

Consent for publication

Written informed consent was obtained from the patient for publication and accompanying images.

Declaration of patient consent

The authors certify that they have obtained all appropriate patient consent forms. In the form, the patient has given her consent for her images and other clinical information to be reported in the journal. The patient understands that her name and initials will not be published and due efforts will be made to conceal her identity, but anonymity cannot be guaranteed.

References

1. Conlan T, Garth WP Jr, Lemons JE. Evaluation of the medial soft-tissue restraints of the extensor mechanism of the knee. *J Bone Joint Surg Am* 1993;75:682-93.
2. Steensen RN, Bentley JC, Trinh TQ, Backes JR, Wiltfong RE. The prevalence and combined prevalences of anatomic factors associated with recurrent patellar dislocation: A magnetic resonance imaging study. *Am J Sports Med* 2015;43:921-7.
3. Balcarek P, Ammon J, Frosch S, Walde TA, Schüttrumpf JP, Ferlemann KG, *et al*. Magnetic resonance imaging characteristics of the medial patellofemoral ligament lesion in acute lateral

- patellar dislocations considering trochlear dysplasia, patella alta, and tibial tuberosity-trochlear groove distance. *Arthroscopy* 2010;26:926-35.
4. Schöttle PB, Schmeling A, Rosenstiel N, Weiler A. Radiographic landmarks for femoral tunnel placement in medial patellofemoral ligament reconstruction. *Am J Sports Med* 2007;35:801-4.
 5. Cash JD, Hughston JC. Treatment of acute patellar dislocation. *Am J Sports Med* 1988;16:244-9.
 6. Mountney J, Senavongse W, Amis AA, Thomas NP. Tensile strength of the medial patellofemoral ligament before and after repair or reconstruction. *J Bone Joint Surg Br* 2005;87:36-40.
 7. Muneta T, Sekiya I, Tsuchiya M, Shinomiya K. A technique for reconstruction of the medial patellofemoral ligament. *Clin Orthop Relat Res* 1999;(359):151-5. doi: 10.1097/00003086-199902000-00016. PMID:10078138.
 8. Carmont MR, Maffulli N. Medial patellofemoral ligament reconstruction: A new technique. *BMC Musculoskelet Disord* 2007;8:22.