

Case report

Transformation of double-hit follicular lymphoma to plasmablastic lymphoma: a partial role of *MYC* gene rearrangement

Mikiko Ise,^{1,2)} Hajime Kageyama,³⁾ Dai Ikebe,^{3,4)} Akinobu Araki,³⁾ Kyoya Kumagai,¹⁾
Makiko Itami³⁾

Follicular lymphoma (FL) is genetically characterized by *BCL2/IGH* translocation. Some FL cases histologically transform to high-grade lymphoma, and the majority of cases transform to diffuse large B-cell lymphoma. We report herein an unusual FL case that transformed to plasmablastic lymphoma (PBL) with *MYC* gene rearrangement as early as 12 months after FL diagnosis. *IGH/MYC* translocation, the most common cytogenetic abnormality seen in *de novo* PBL, was also detected in the transformed tumor (double-hit lymphoma). The patient became resistant to chemotherapy and died 4 months after transformation. We speculate that the “second hit” of *MYC* rearrangement played a crucial role in PBL transformation (PBL-T) in this case. Highly specific three-color FISH analysis demonstrated the presence of *BCL2/IGH/MYC* triple fusion signals on a single chromosome as we expected, but *BCL2/IGH* and *IGH/MYC* fusion signals also coexisted in a single nucleus. The PBL-T tumor was genetically heterogeneous, despite being histologically quite homogeneous PBL. Surprisingly, three-color FISH analysis revealed that the preceding FL tumor was also genetically heterogeneous, simultaneously harboring *BCL2/IGH*, *IGH/MYC* and *BCL2/IGH/MYC* fusion signals (i.e. double-hit lymphoma), despite being histologically quite homogeneous FL. This suggests that *MYC* rearrangement played a partial role in PBL-T. Genetic instability including *MYC* rearrangement in the preceding FL tumor would contribute to PBL-T and poor outcome in this case. This study will broaden our understanding of the pathogenesis of high-grade transformation of FL and help improve patient outcome.

Keywords: Follicular lymphoma, Histological transformation, Plasmablastic lymphoma, Double-hit lymphoma, Three-color FISH

INTRODUCTION

Follicular lymphoma (FL) is genetically characterized in most cases by the presence of the reciprocal chromosomal translocation t(14;18)(q32;q21), which results in the deregulated expression of the anti-apoptotic *BCL2* oncogene under the control of the *IGH* enhancer region. Histological transformation of FL to high-grade lymphoma occurs in 2% of cases each year in the rituximab era.¹ The majority of FLs transform to diffuse large B-cell lymphoma (DLBCL).

Herein we describe an unusual FL case that transformed to plasmablastic lymphoma (PBL) with *MYC* gene rearrangement. To investigate the pathogenesis of PBL transformation (PBL-T) in this case, especially the role of additional *MYC* rearrangement, we performed three-color FISH analysis.

We revealed the genetic heterogeneity of the transformed PBL tumor and, surprisingly, of the preceding FL tumor.

CASE REPORT


A 59-year-old man with no history of immunodeficiency developed a fever and night sweats in January 2013. A computed tomography (CT) scan revealed an abdominal-pelvic mass and a submandibular lymphadenopathy. Laboratory evaluation showed levels of hemoglobin at 9.3 g/dl (normal range 14-18 g/dl), serum lactate dehydrogenase (LDH) at 562 IU/ml (normal range 80-200 IU/ml) and soluble interleukin-2 receptor (sIL-2R) at 12200 U/ml (normal range 145-519 U/ml). The tumors showed abnormal uptake of fluorodeoxyglucose (FDG) on positron emission tomography

Received: January 31, 2018. Revised: June 8, 2018. Accepted: June 19, 2018. J-STAGE Advance Published: July 14, 2018
DOI:10.3960/jslrt.18003

¹⁾Department of Hematology-Oncology, Chiba Cancer Center, Chiba, Japan, ²⁾Department of Internal Medicine, Kamagaya General Hospital, Chiba, Japan, ³⁾Department of Surgical Pathology, Chiba Cancer Center, Chiba, Japan, ⁴⁾Department of Pathology, Matsudo City General Hospital, Chiba, Japan

Corresponding author: Mikiko Ise, MD, PhD, Department of Internal Medicine, Kamagaya General Hospital 929-6 Hatsutomi, Kamagaya City, Chiba 273-0121, Japan.
E-mail: spak7hd9@star.ocn.ne.jp

Copyright © 2018 The Japanese Society for Lymphoreticular Tissue Research

 This work is licensed under a Creative Commons Attribution-NonCommercial-ShareAlike 4.0 International License.

(PET) scan [standard uptake value (SUV) max: 9.54] (Fig. 1A). An abdominal mass needle biopsy showed a partial infiltration of medium-sized lymphoid cells within necrotic tissue. The cells were positive for CD20, CD79a, CD10 and BCL2, suggesting B-cell lymphoma of follicular center origin. A submandibular lymph node excision biopsy performed under general anesthesia demonstrated architectural

effacement by abnormal lymphoid cells predominantly composed of centrocytes and a few centroblasts displaying a nodular pattern (Fig. 2A, B). The tumor cells were positive for CD20, CD79a, CD10 and BCL2 (Fig. 2C–F), and negative for CD3 and CD5 (data not shown). Cytogenetic analysis of the lymph node showed 47, XY, del(6)(q?), t(14;18)(q32;q21), +der(18)t(14;18)(q32;q21). Interphase fluorescence *in situ*

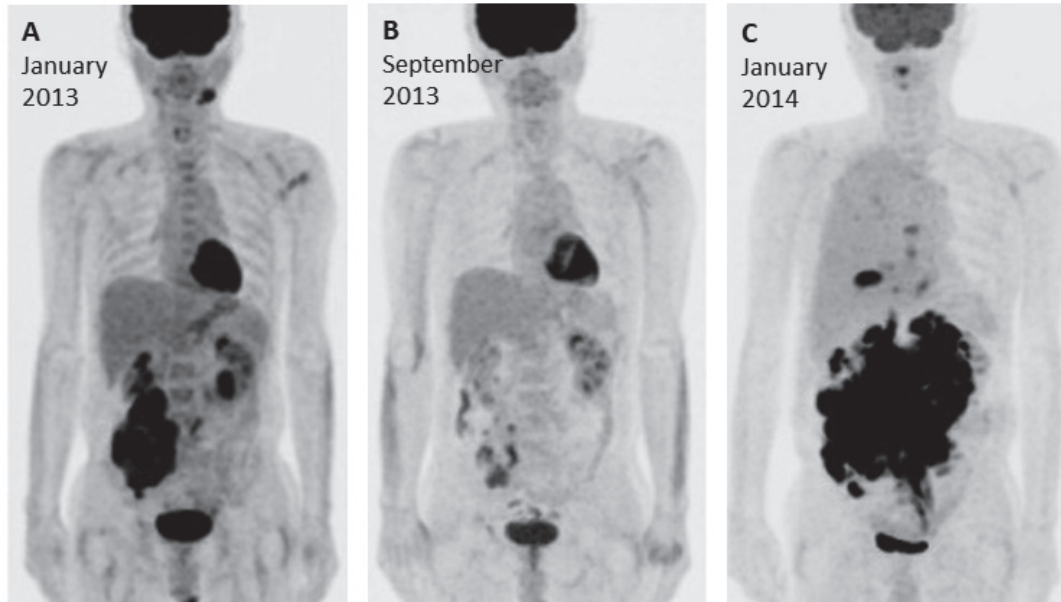


Fig. 1. Whole body PET/CT imaging. **A.** In January 2013, abdominal FDG uptakes (SUV max: 9.54) were detected in the right abdominal-pelvic mass and left submandibular lymph node. **B.** In September 2013, after completion of R-CHOP therapy, the abdominal-pelvic mass was significantly decreased in size and FDG uptake was markedly reduced. **C.** In January 2014, the abdominal-pelvic bulky tumor regrew and a right pleural lesion appeared. FDG uptake was increased (SUV max: 23.26).

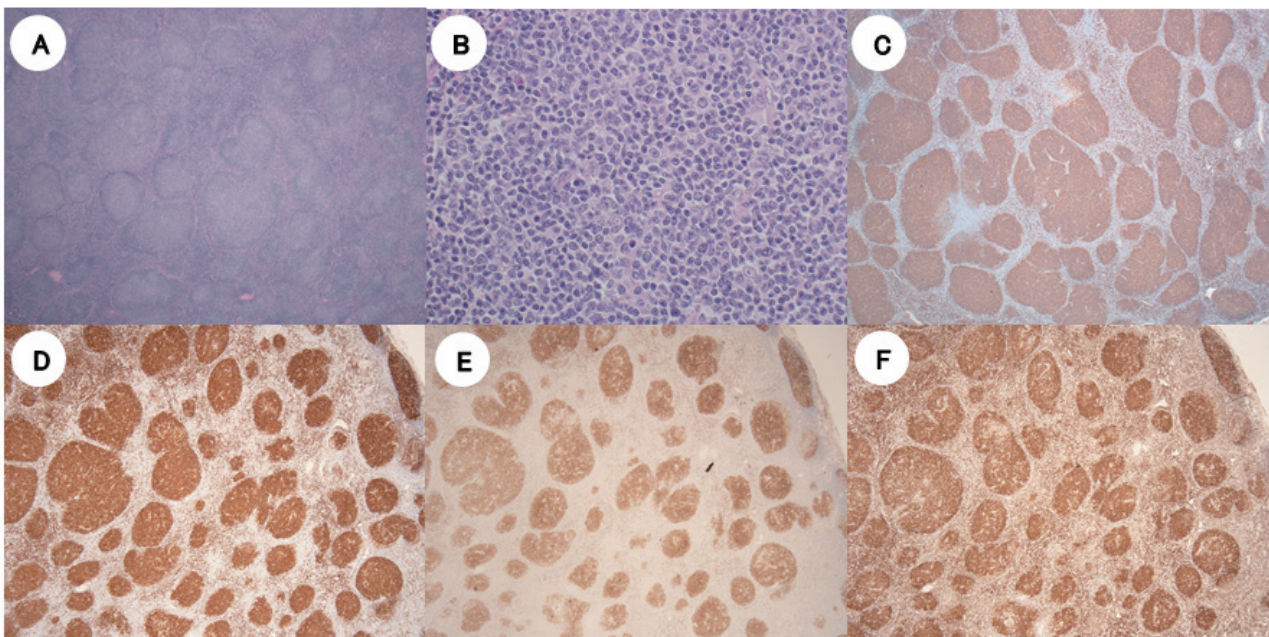


Fig. 2. Histological and immunophenotypic findings of follicular lymphoma. Sections of submandibular lymph node in February 2013 showed neoplastic follicles with attenuated mantle zones (**A**, hematoxylin and eosin, $\times 40$). Neoplastic follicles were composed of centrocytes and centroblasts (**B**, hematoxylin and eosin, $\times 400$). The tumor cells expressed CD20 (**C**, $\times 40$), CD79a (**D**, $\times 40$), CD10 (**E**, $\times 40$) and BCL2 (**F**, $\times 40$).

hybridization (FISH) analysis demonstrated *BCL2/IGH* fusion signals in 54.0% of analyzed cells (Table 1). A diagnosis of FL grade 2 was made. Bone marrow involvement was also demonstrated (stage IVB, FLIPI: high). The FL was with high tumor burden meeting the GELF criteria: a diameter of abdominal tumor mass was over 7cm, and the patient presented B symptoms (a fever and night sweats). In

September 2013, after eight cycles of R-CHOP (rituximab, cyclophosphamide, doxorubicin, vincristine, prednisolone), the tumor was significantly decreased (partial remission) (Fig. 1B). Serum sIL-2R levels were decreased to 500 U/ml. Rituximab maintenance was not performed because it was not covered by health insurance.

In January 2014, at 12 months after the initial FL diagnosis,

Table 1. Cytogenetic studies: G-banding and interphase FISH analysis

	January 2013, Lymph node	January 2014, Pleural effusion	May 2014, Bone marrow
Histological diagnosis	Follicular lymphoma, Grade 2	Plasmablastic lymphoma	Plasmablastic lymphoma
Cytogenetic studies	47,XY,del(6)(q?),t(14;18)(q32;q21),+der(18)t(14;18)(q32;q21)[1]/47,idem,-Y,+mar[2]/46,XY[16]	48,X,-Y,+add(1)(p11),ins(1;?)(q21;?),add(4)(q31),add(6)(p23),+7,+9,+12,+add(14)(q32),del(17)(p?),-18,der(18)t(14;18)(q32;q21),-21,+add(22)(q11.2)[8]	50,XY,+add(1)(p11),add(6)(p23),+7,-8,+9,-10,+add(10)(q22),+12,+add(14)(q32),del(17)(p?),+18,der(18)t(14;18)(q32;q21)x2,-21,+add(22)(q11.2),+der(?)t(?;1)(?q21)[1]/51,idem,+add(4)(p11),+7[1]/46,XY[6]
FISH analysis	<i>BCL2/IGH</i> : 54.0% <i>IGH/MYC</i> : not examined	<i>BCL2/IGH</i> : 98.0% <i>IGH/MYC</i> : not examined	<i>BCL2/IGH</i> : 10.0% <i>IGH/MYC</i> : 12.0%

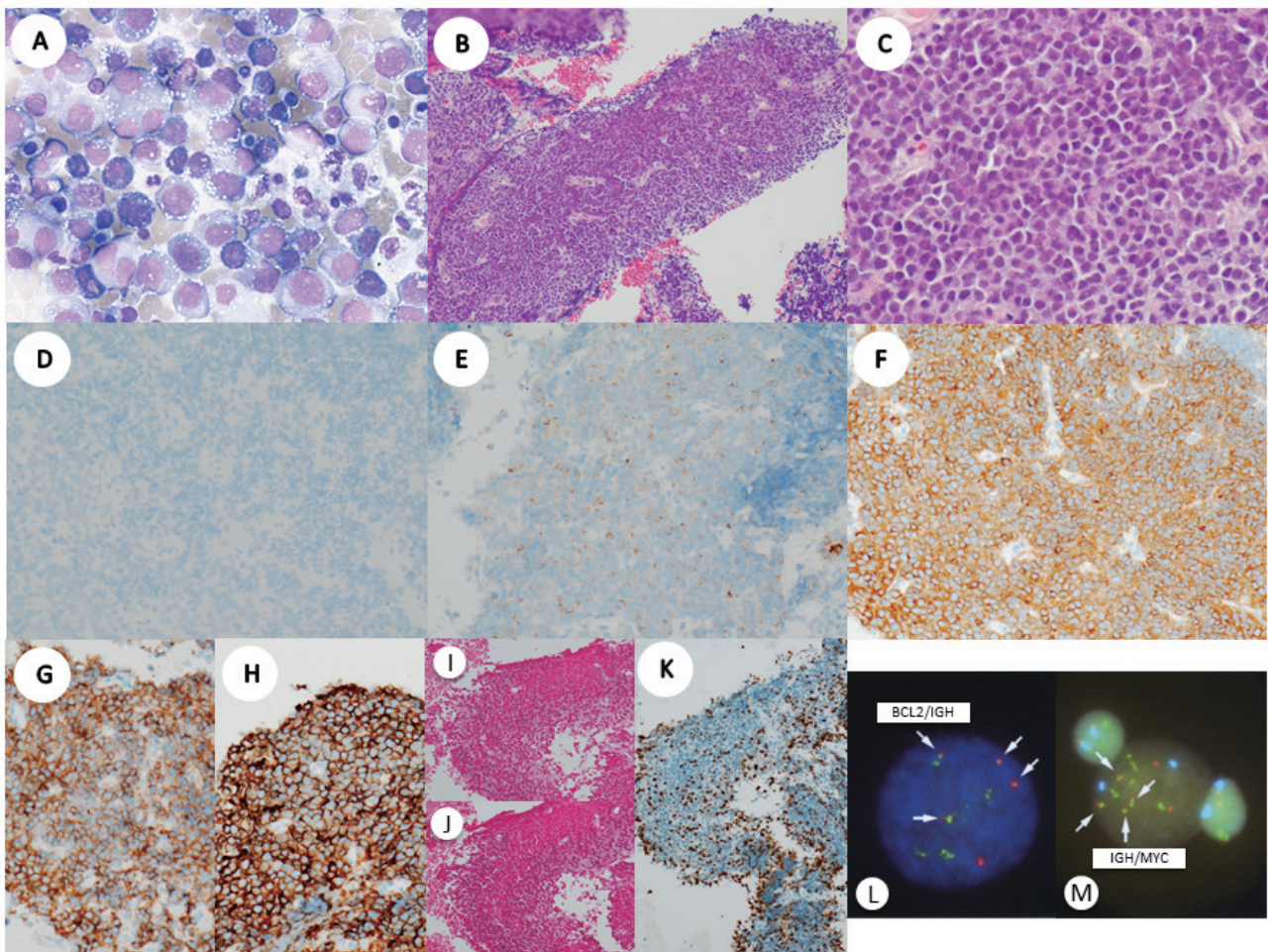


Fig. 3. *A.* Cytology of pleural effusion in January 2014 showed large neoplastic plasmacytoid cells with abundant cytoplasm and eccentrically located round nuclei with prominent nucleoli (Wright-Giemsa, $\times 600$). *B–J.* Histological and immunophenotypic findings of plasmablastic lymphoma. Sections of abdominal lymph node in January 2014 showed a diffuse proliferation of immunoblastic and plasmablastic cells (hematoxylin and eosin) (*B*, $\times 40$ and *C*, $\times 400$). The tumor cells lacked CD20 (*D*, $\times 400$) and CD10 (*E*, $\times 400$), and expressed BCL2 (*F*, $\times 400$), CD38 (*G*, $\times 400$) and CD138 (*H*, $\times 400$). The tumor cells lacked kappa (*I*, $\times 400$) and lambda (*J*, $\times 400$). The Ki-67 proliferation index was 90% (*K*, $\times 400$). *L&M.* Conventional FISH analysis of bone marrow cells in May 2014 showed *BCL2/IGH* fusion signals in 10.0% (*L*) and *IGH/MYC* fusion signals in 12.0% (*M*) of analyzed cells (i.e. double-hit lymphoma).

the patient again developed night sweats, abdominal distention and lower back pain. A CT scan revealed an abdominal-pelvic bulky mass, pleural effusion and ascites. Laboratory evaluation showed levels of serum LDH at 867 IU/ml and sIL-2R at 2830 U/ml. Tumors showed increased abnormal uptake of FDG on PET scan [SUV max: 23.26] (Fig. 1C). Pleural effusion cytology showed large abnormal lymphoid cells with plasmablastic features: round eccentric nuclei, prominent nucleoli and abundant basophilic cytoplasm (Fig. 3A). An abdominal mass needle biopsy also revealed a diffuse proliferation of immunoblastic and plasmablastic cells (Fig. 3B, C). The tumor cells were negative for CD20 (Fig. 3D), CD79a, PAX5 and TdT (data not shown), weakly positive for CD10 (Fig. 3E) and positive for BCL-2 (Fig. 3F), CD38 (Fig. 3G) and CD138 (Fig. 3H). Monoclonal immunoglobulin was not detected by serum and urine electrophoresis. Cytogenetic analysis of the pleural effusion cells showed a complex karyotype: 48, X, -Y, +add(1)(p11), ins(1;?)(q21;?), add(4)(q31), add(6)(p23), +7, +9, +12, add(14)(q32), del(17)(p?), der(18)t(14;18)(q32;q21), -21, add(22)(q11.2). FISH analysis demonstrated *BCL2/IGH* fusion signals in 98.0% of analyzed cells (Table 1). Based on these profiles, a diagnosis of PBL transformed from FL was made (stage IVB, IPI: high). Tumor cells were negative for kappa (Fig. 3I), lambda (Fig. 3J) and EBER *in situ* hybridization. The Ki-67 proliferation index was 90% (Fig. 3K). The patient was started with CHASE (cyclophosphamide, cytarabine, etoposide, prednisolone). Although he initially responded to treatment, the lymphoma soon became resistant. Other multiple intensive chemotherapy regimens were tried without success. Bone marrow aspiration in May 2014 demonstrated 8.4% abnormal plasmablastic cells. Cytogenetic analysis showed 50, XY, +add(1)(p11), add(6)(p23), +7, -8, +9, -10, add(10)(q22), +12, add(14)(q32), del(17)(p?), +18, der(18)t(14;18)(q32;q21)x2, -21, add(22)(q11.2), +der(?)t(?;1)(?;q21). FISH analysis demonstrated *BCL2/IGH* fusion signals in 10.0% of analyzed cells (Fig. 3L). *IGH/MYC* fusion signals, the most common translocation detected in *de novo* PBL,² was also demonstrated in 12.0% of the cells (i.e. double-hit lymphoma) (Fig. 3M) (Table 1). The patient died of disease 16 months after FL diagnosis and 4 months after PBL-T. In autopsy, the PBL tumor replaced mesentery, retroperitoneal and pelvic space and involved the pancreas, adrenal glands, right kidney and duodenum. Histological and immunophenotypic findings were the same as that of abdominal mass in January 2014. No residual FL population was identified.

POLYMERASE CHAIN REACTION, SEQUENCING, AND FISH ANALYSIS

Molecular studies and interphase FISH analysis were performed on FL and PBL specimens. For FL, the submandibular lymph node biopsy specimen from February 2013 was used. For PBL, because only few numbers of cells were available in the abdominal mass needle biopsy and pleural effusion cell block specimens from January 2014, the abdom-

inal mass specimen from May 2014 autopsy was used.

Polymerase chain reaction analysis for *BCL/IGH* was performed on DNA extracted from frozen sections using established BIOMED-2 consensus primers.³ The result yielded clonal rearrangements at the major breakpoint region with identical migration patterns in the FL and PBL, suggesting that these two neoplasms were clonally related (Fig. 4A). Sequencing of the amplicons showed an identical junction sequence consisting of the *BCL2* sequence from the 3' untranslated region in exon 3 and the JH6 sequence (Fig. 4B), confirming that the two tumors are the identical neoplastic clone.

To investigate the pathogenesis of PBL-T in this case, especially the role of additional *MYC* gene rearrangement, we performed three-color FISH analysis on the PBL stamp preparations. A cocktail of chemically synthesized single-color dual-fusion FISH probes (SureFISH; Agilent Technologies, TX, USA) were used: red-labeled *BCL2*, green-labeled *IGH* and aqua-labeled *MYC*. We identified the presence of *BCL2/IGH/MYC* triple fusion signals on a single chromosome (Fig. 5A; white arrows), but *BCL2/IGH* (Fig. 5A, B; orange arrows) and *IGH/MYC* (Fig. 5A, C; blue arrows) fusion signals also coexisted in a single nucleus. Therefore, we retrospectively performed FISH analysis on the FL stamp preparations. Surprisingly, aberrant *BCL2/IGH/MYC* (26% of the interphase nuclei evaluated) (Fig. 6A; white arrow) and *IGH/MYC* fusion signals (45%) (Fig. 6A, C; blue arrows) were detected, concurrent with typical *BCL2/IGH* fusion signals (94%) (Fig. 6A, B; orange arrows) (i.e. double-hit lymphoma).

DISCUSSION

Although FL is a clinically indolent disease, transformed FL is usually characterized by an aggressive course, poor response to chemotherapy and short survival.^{1,4} The median overall survival following transformation in patients with transformation within 18 months of FL diagnosis was inferior compared with patients with a later transformation.¹ The present case transformed to PBL as early as 12 months after FL diagnosis and died of the disease 4 months after transformation.

FL transformation to high-grade lymphoma occurs by divergent rather than direct clonal evolution. Most genetic alterations typical of transformed FL can be found at a lower prevalence in indolent FL, suggesting that a single alteration may not be sufficient to drive transformation.⁴ Detailed genetic analyses have revealed several discrete mechanisms driving transformation.⁵ Alteration of genes deregulating cell cycle progression and the DNA damage response (*CDKN2A/B*, *MYC* and *TP53*) have been frequently observed in transformed FL, suggesting that the loss of genetic stability and deregulated proliferation are critical steps in transformation.⁵ *MYC* deregulation is implicated in 20% of all human malignancies and is often associated with poor prognosis.⁶

Double-hit lymphoma (DHL) is a high-grade B-cell

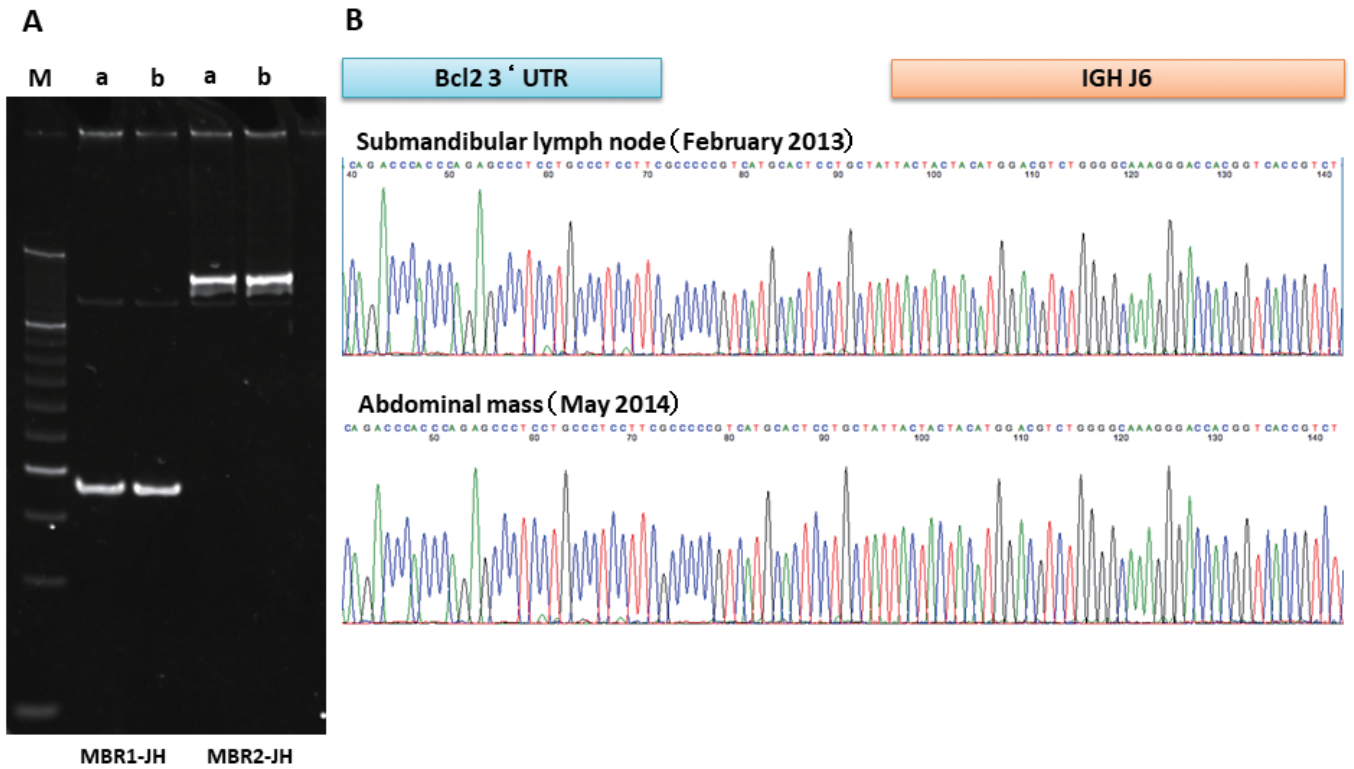


Fig. 4. *A.* Polymerase chain reaction analysis for *BCL2/IGH* rearrangements showed similar rearranged bands between the FL and the PBL. M, size markers; a, submandibular lymph node in February 2013; b, abdominal mass in the May 2014 autopsy; MBR, major breakpoint region.³ *B.* Sequencing of the *BCL2/IGH* rearrangement from the FL and the PBL demonstrated identical junction sequences, confirming that the two tumors are clonally related.

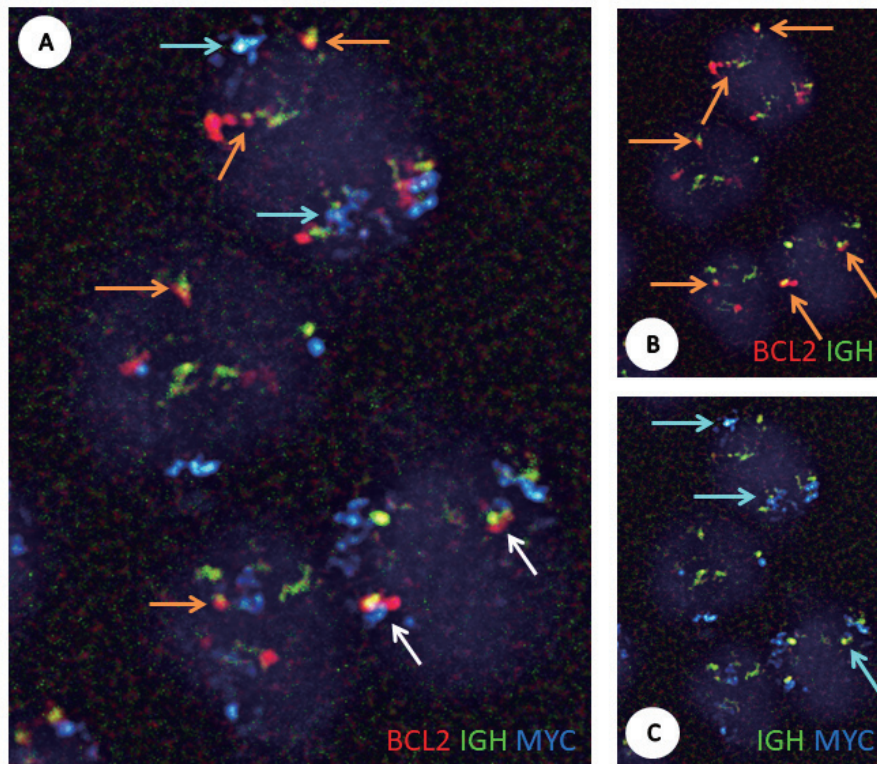


Fig. 5. Triple fusion FISH analysis on stamp preparations of abdominal PBL mass from May 2014 autopsy. A cocktail of chemically synthesized oligonucleotide-based dual-fusion probes was used: red-labeled *BCL2*, green-labeled *IGH* and aqua-labeled *MYC*. Fluorescence microphotographs of the same visual field were taken through each of four color filters (DAPI, FITC, Texas-red and aqua) and overlaid in each combination with imaging software. *A.* *BCL2/IGH/MYC* triple fusion (white arrows) signals were demonstrated. *B.* *BCL2/IGH* fusion (orange arrows) and *C.* *IGH/MYC* fusion (blue arrows) signals were also found in a single nucleus.

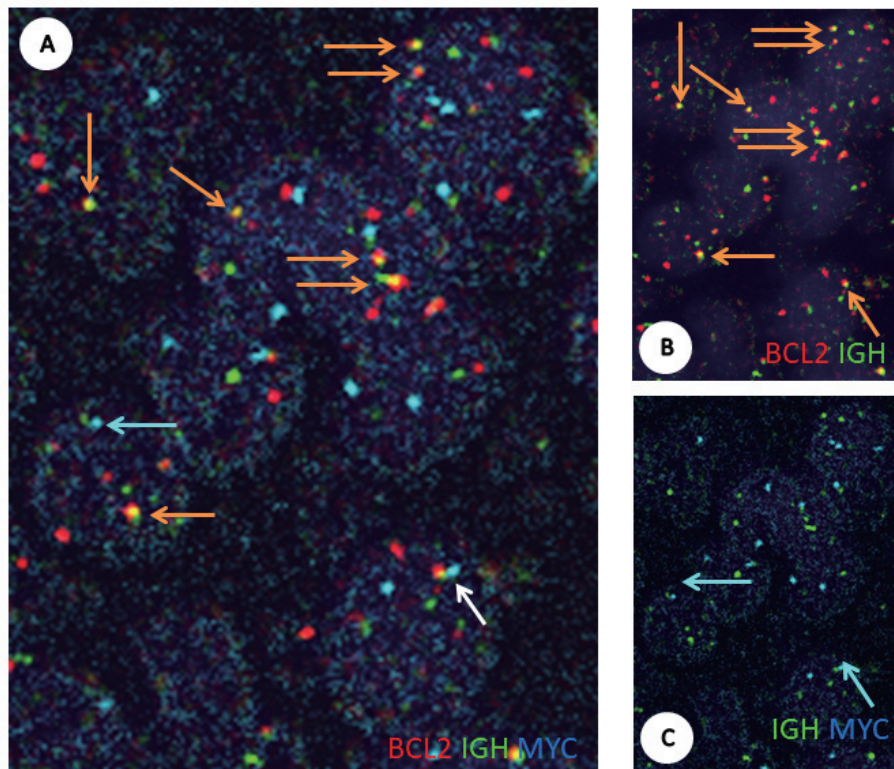


Fig. 6. Triple fusion FISH analysis on stamp preparations of submandibular lymph node FL from the February 2013 biopsy. *A.* *BCL2/IGH/MYC* triple fusion (white arrows, 26% of the interphase nuclei evaluated) signals were identified. *B.* *BCL2/IGH* fusion (orange arrows, 94%) and *C.* *IGH/MYC* fusion (blue arrows, 45%) signals were also found in a single nucleus.

Table 2. Clinical features of cases that transformed from FL to PBL

Case	Age at FL diagnosis/Sex	Time from FL diagnosis to PBL transformation	Site of PBL at diagnosis	Treatment for PBL	Outcome	<i>MYC</i> gene rearrangement
1 ¹⁰⁾	69/Male	10 months	Bladder, LNs, testis	R-CHOP, DeVIC	DwD/6 months after PBL diagnosis	Yes
2 ¹¹⁾	67/Male	Simultaneously	LNs, bone	R-CHOP, ESHAP, ASCT	DwoD/20 months after FL diagnosis	No
3 ¹¹⁾	70/Male	Simultaneously	Jejunum, LNs	R-CHOP	AwoD/24 months from FL diagnosis	No
4 ¹¹⁾	72/Male	34 months	LNs, spleen	R-CHOP, GEMOX, radiotherapy	AwoD/10 months from PBL diagnosis	No
Present case	59/Male	12 months	Pleural effusion, LNs	CHASE, DeVIC, GDP, CPT-11 and DXR	DwD/5 months after PBL diagnosis	Yes

FL, follicular lymphoma; PBL, plasmablastic lymphoma; LN, lymph node; DeVIC, dexamethasone, carboplatin, etoposide, and ifosfamide; ESHAP, etoposide, methylprednisolone, cytarabine, and cisplatin; ASCT, autologous stem cell transplantation; GEMOX, gemcitabine and oxaliplatin; GDP, gemcitabine, dexamethasone, and cisplatin; CPT-11, irinotecan; DXR, doxorubicin; DwD, died with disease; DwoD, dead without disease; AwoD, alive without disease.

lymphoma with *MYC* and *BCL2* and/or *BCL6* rearrangements and was recently categorized as a distinct entity in the 2016 revision of the World Health Organization classification for lymphoid malignancies.⁷ DHL is characterized by a rapidly progressing clinical course that is refractory to aggressive treatment and has a short survival time.⁸ In addition to *de novo* disease, DHL occurs in the setting of transformation of indolent lymphoma, particularly FL, when the *BCL2/IGH* lymphoma acquires *MYC* translocation,⁹ as is the present case.

PBL is an uncommon subtype of DLBCL that shows diffuse proliferation of large neoplastic cells resembling immunoblasts and plasmablasts. PBL is clinically characterized by an aggressive course and high rates of relapse. The most common cytogenetic abnormality seen in PBL is *IGH/MYC* translocation.² Most PBL cases are EBV-associated, with a high proliferation index. Our PBL-T case carried *IGH/MYC* translocation and a high Ki-67 proliferation index but was negative for EBV.

PBL-T of FL is extremely rare, and only four cases have been reported (Table 2).^{10,11} Only one case displayed *MYC* gene rearrangement.¹⁰ The other three cases without *MYC* rearrangement (cases 2, 3 and 4) achieved complete remission with R-CHOP and remained disease free for 10 to 24 months.¹¹ One case with *MYC* rearrangement (case 1) was chemotherapy-resistant and died of disease less than 6 months after PBL-T.¹⁰ In that case, Ouansafi *et al.* identified *MYC* gene rearrangement in almost all nuclei of the PBL-T tumor using FISH analysis, although the partner gene was not shown. The authors also demonstrated that the PBL-T tumor exhibited a much lower intra-clonal diversity compared with the preceding FL tumor by somatic hypermutation analysis. No *MYC* rearrangement was detected in the preceding FL tumor.¹⁰

The present case is the second case of PBL-T of FL with *MYC* gene rearrangement. We provide definitive evidence of histological transformation by demonstrating identical *BCL2/IGH* gene breakpoints in both PBL and FL. Conventional FISH analysis detected *IGH/MYC* fusion signals in addition to *BCL2/IGH* in the PBL-T tumor (Fig. 3L, M) (i.e. DHL). Taking the case of Ouansafi into consideration, we speculated that the “second hit” of *MYC* rearrangement played a crucial role in PBL-T in the current case. However, in contrast with previous case, the chromosome copy number increased in the current case and the karyotype became complex. Three-color FISH analysis demonstrated the presence of *BCL2/IGH/MYC* triple fusion signals on a single chromosome, as we expected (Fig. 5A; white arrows), but *BCL2/IGH* (Fig. 5A, B; orange arrows) and *IGH/MYC* (Fig. 5A, C; blue arrows) fusion signals coexisted in a single nucleus. Remarkably, the PBL-T tumor was genetically heterogeneous, despite being histologically quite homogeneous PBL. We also retrospectively performed triple fusion FISH analysis on the FL specimen. Surprisingly, the FL tumor was also genetically heterogeneous harboring aberrant *BCL2/IGH/MYC* (Fig. 6A; white arrow) and *IGH/MYC* fusion signals (Fig. 6A,C; blue arrows) in addition to typical *BCL2/IGH*

fusion signals (Fig. 6A, B; orange arrows) (i.e. DHL), despite being histologically quite homogeneous FL. This indicates that the preceding FL tumor was already genetically heterogeneous and genomically unstable. This would contribute to such an early transformation to high-grade lymphoma, PBL. This also suggests that the role of *MYC* rearrangement was partial in PBL-T in this case; *MYC* dysregulation might be a necessary condition for PBL-T but not sufficient to allow PBL-T. Other mechanisms such as multiple chemotherapeutic agents and other genetic alterations will contribute to PBL-T and poor outcome. In future studies, we will isolate genetically heterogeneous FLs at diagnosis using this simple three-color FISH technique and consider applying aggressive induction regimens to improve patient outcomes.

In summary, we reported an unusual case of FL transformed to PBL with *MYC* gene rearrangement. Using a highly specific three-color FISH technique, we demonstrated that the PBL-T tumor was genetically heterogeneous harboring *BCL2/IGH*, *IGH/MYC* and *BCL2/IGH/MYC* translocations simultaneously. Moreover, we revealed that the preceding FL tumor was also genetically heterogeneous, despite being histologically quite homogeneous FL. This suggests that the role of *MYC* dysregulation was partial in PBL-T. Genetic instability including *MYC* dysregulation in the preceding FL tumor would contribute to PBL-T and poor outcome in this case. This study will broaden our understanding the pathogenesis of high-grade transformation of FL and help to improve patient outcome.

ACKNOWLEDGEMENT

This research was conducted using the Chiba Cancer Center Biobank Resource. We thank Edanz Group (www.edanzediting.com/ac) for editing a draft of this manuscript.

CONFLICT OF INTEREST

The authors declare that they have no conflict of interest.

REFERENCES

- Link BK, Maurer MJ, Nowakowski GS, *et al.* Rates and outcomes of follicular lymphoma transformation in the immunochemotherapy era: A report from the University of Iowa/Mayo Clinic specialized program of research excellence molecular epidemiology resource. *J Clin Oncol.* 2013; 31 : 3272-3278.
- Valera A, Balague O, Colomo L, Martinez A, *et al.* *IG/MYC* rearrangements are the main cytogenetic alteration in plasmablastic lymphomas. *Am J Surg Pathol.* 2010; 34 : 1686-1694.
- van Dongen JJ, Langerak AW, Bruggemann M, *et al.* Design and standardization of PCR primers and protocols for detection of clonal immunoglobulin and T-cell receptor gene recombinations in suspect lymphoproliferations: Report of the BIOMED-2 Concerted Action BMH4-CT98-3936. *Leukemia.* 2003; 17 : 2257-2317.
- Kridel R, Sehn LH, Gascoyne RD. Can histologic transformation of follicular lymphoma can be predicted and prevented?

- Blood. 2017; 130 : 258-266.
- 5 Pasqualucci L, Khiabani H, Fangazio N, Vasishtha M, *et al.* Genetics of follicular lymphoma transformation. *Cell Rep.* 2014; 6 : 130-140.
 - 6 Sarkozy C, Traverse-Glehen A, Coiffier B. Double-hit and double-expression lymphomas: aggressive and refractory lymphomas. *Lancet Oncol.* 2015; 16 : e555-567.
 - 7 Swerdlow SH, Campo E, Pileri SA, Harris NL, Stein H, *et al.* The 2016 revision of the World Health Organization classification of lymphoid neoplasms. *Blood.* 2016; 127 : 2375-2390.
 - 8 Nabhan C, Mato A. Emerging strategies in treating double hit lymphoma. *Clin Lymphoma Myeloma Leuk.* 2017; 17 : 563-568.
 - 9 Friedberg JW. How I treat double-hit lymphoma. *Blood.* 2017; 130 : 590-596.
 - 10 Ouansafi I, He B, Fraser C, *et al.* Transformation of follicular lymphoma to plasmablastic lymphoma with *c-myc* gene rearrangement. *Am J Clin Pathol.* 2010; 34 : 972-981.
 - 11 Martinez D, Valera A, Perez NS, Sua Villegas LF, Gonzalez-Farre B, *et al.* Plasmablastic transformation of low-grade B-cell lymphomas. *Am J Surg Pathol.* 2013; 37 : 272-281.