

Vagal denervation in atrial fibrillation ablation: A comprehensive review

Tolga Aksu, Tümer Erdem Güler, Ferit Onur Mutluer¹, Mehmet Ali Oto²

Department of Cardiology, Kocaeli Derince Education and Research Hospital; Kocaeli-Turkey

¹Department of Cardiology, Koç University Hospital; İstanbul-Turkey

²Department of Cardiology, Memorial Ankara Hospital; Ankara-Turkey

ABSTRACT

Although pulmonary vein isolation is accepted as an established interventional treatment in paroxysmal atrial fibrillation (AF), alternative modalities are being investigated because of the high recurrence rates of nonparoxysmal forms. One of the alternative ablation approaches is ablation or modification of vagal ganglionated plexi (VGP). The technique has not only been used in vagally mediated AF but also investigated in paroxysmal and nonparoxysmal AF. Clinical studies demonstrate significant discrepancy related with detection of VGP sites or ablation targets and definition of procedural end-points, so far. In this review, we aimed to discuss the current data on the role of VGP in the pathogenesis of AF and potential therapeutic implications of ablation of these ganglia. (*Anatol J Cardiol* 2017; 18: 142-8)

Keywords: parasympathetic, vagal ganglia, cardioneuroablation, tachycardia, autonomic

Introduction

Atrial fibrillation (AF) is an important public health problem in our country as it is in the world (1, 2). Several studies have reported that the majority of the paroxysmal AF cases are caused by rapid firings originating from pulmonary veins (PVs) and non-PV sites (3, 4). PV isolation (PVI) has been a cornerstone therapeutic modality and suggested as a potential first-line catheter ablation procedure in patients with paroxysmal AF (5). Although maintenance of sinus rhythm with only PVI is satisfactory in paroxysmal AF, the long-term outcome of PVI-alone strategy for persistent or long-standing persistent AF is still far from acceptable when compared with that of paroxysmal AF (6–8). To overcome this dilemma, continued efforts are underway to identify additive substrate modification strategies to improve the long-term outcome in this population. Linear ablation and ablation of complex fractionated atrial electrograms (CFAEs) are the most studied methods to modify atrial substrate (9, 10). We recently discussed questionable role of CFAE ablation in this patient population on the basis of STAR AF II trial (11). Ablation of vagal ganglionated plexi (VGP) has emerged as an alternative technique to improve outcomes in patients with AF. Although the technique was firstly investigated for vagally mediated AF, it has been investigated in all AF forms (12–14). In this review article, we aimed to discuss the current data on the role of the VGP in the pathogenesis of AF and potential therapeutic implications.

Anatomical localization of VGP

In the autonomic nervous system, fibers from the ganglion to the effector organ are called postganglionic fibers. Unlike the sympathetic nervous system in which postganglionic neurons are located in paravertebral ganglia, parasympathetic postganglionic neurons are located epicardially in VGP (15, 16). As a result, axons of these neurons are short in length and this fact might enable permanent ablation of these ganglia from the endocardial surface. Another difference between sympathetic and parasympathetic innervation of the heart is that ventricles are predominantly innervated by the sympathetic nervous system whereas atria are predominantly innervated by both systems. In a human autopsy study, atrial VGP were identified on five distinct localizations (Fig. 1): (1) the superior surface of the right atrium (superior right atrial VGP), (2) the superior surface of the left atrium (superior left atrial VGP), (3) the posterior surface of the right atrium (posterior right atrial VGP), (4) the posterior medial surface of the left atrium (posteromedial left atrial VGP), and (5) the inferolateral aspect of the posterior left atrium (posterolateral left atrial VGP) (15). Chiou et al. (16) investigated both anatomical localization and functional properties of atrial VGP in an animal study and defined three different VGP, which were found in fat pads (Fig. 1). They were named according to their location. The first one is superior vena cava-aorta fat pad, and it is located between the medial superior vena cava and aortic root

Address for correspondence: Dr. Tolga Aksu, Derince Eğitim ve Araştırma Hastanesi, Kardiyoloji Bölümü, Derince, Kocaeli-Türkiye
Fax: +90 262 317 80 00 E-mail: aksutolga@gmail.com

Accepted Date: 02.06.2017

©Copyright 2017 by Turkish Society of Cardiology - Available online at www.anatoljcardiol.com
DOI:10.14744/AnatolJCardiol.2017.7788



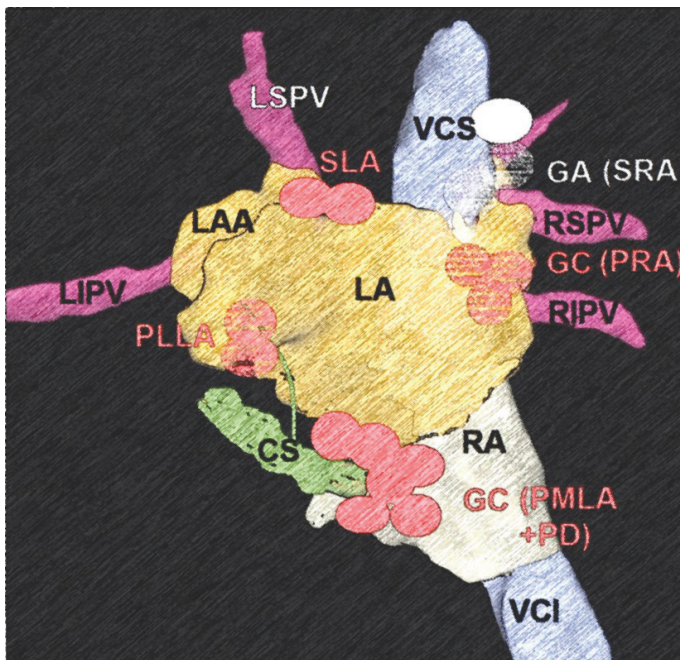


Figure 1. Schematic view of vagal ganglionated plexi. Pachon et al. (Ref. 51) re-named three fat pads in their study. According to this naming, ganglion A, B, and C correspond to superior vena cava-aorta fat pad, right pulmonary vein fat pad, and inferior vena cava-left atrium fat pad, respectively. Please pay attention similar anatomical localization of superior vena cava-aorta fat pad and superior right atrial vagal ganglionated plexus, right pulmonary vein fat pad and posterior right atrial vagal ganglionated plexus, and inferior vena cava-left atrium fat pad and posteromedial left atrial vagal ganglionated plexus

CS - coronary sinus; GA - ganglion A; GB - ganglion B; GC - ganglion C; LA - left atrium; LAA - left atrial appendage; LIPV - left inferior pulmonary vein; LSPV - left superior pulmonary vein; PMLA, VGP - posteromedial left atrial vagal ganglionated plexus; PLLA - posterolateral left atrial; PRA VGP - posterior right atrial vagal ganglionated plexus; RA - right atrium; RIPV - right inferior pulmonary vein; RSPV - right superior pulmonary vein; SLA - superior left atrial vagal ganglionated plexus; SRA VGP - superior right atrial vagal ganglionated plexus; VCI - vena cava inferior; VCS - vena cava superior

superior to the right pulmonary artery. It is accepted as a head station for atrial vagal innervations. The second one is named as inferior vena cava-left atrium fat pad and located around the coronary sinus. It mainly provides vagal innervations of the atrioventricular node. The last one is right PV fat pad and provides vagal innervations of the sinus node. Although, these schemes seem to be different anatomical localization of the VGP, there is considerable overlap. For example, superior vena cava-aorta fat pad and superior right atrial VGP, right PV fat pad and posterior right atrial VGP and inferior vena cava-left atrium fat pad and posteromedial left atrial VGP seem to refer to the same anatomical regions (Fig. 1).

Identification of VGP during electrophysiological study

So far, three different approaches have been used for identification of VGP in atria. In an animal study, Schauerte et al. (17) used high-frequency stimulation (HFS) to define the parasympathetic innervation sites. For cervical vagal nerve stimulation (VNS), rectangular electrical stimuli were delivered at a frequency of 20 Hz and a pulse duration of 2 ms. The voltage chosen for

right VNS was 5 V above the voltage at which sinus arrest lasting >2 s or complete atrioventricular block was observed. For stimulation of cardiac parasympathetic nerves in the right pulmonary artery, bipolar electrical stimulation was administered between adjacent arms of a basket catheter (stimulation frequency 20 Hz, pulse duration 0.1 ms). Similarly, Scanavacca et al. (18) used HFS with a frequency of 20 Hz, amplitude up to 100 V, and pulse duration of 4 ms (Grass Stimulator S-48, Astro Med Inc., Grass Instruments Division, West Warwick, RI) to identify atrial ablation target sites in 10 patients with paroxysmal AF. The places demonstrating positive vagal response which was defined as atrioventricular block >2.0 s that occurred after HFS ablated.

Pachon et al. (19) defined a new modality with no need for a positive vagal response to predict VGP. They used spectral analysis through fast Fourier transform (FFT) analysis, thus going beyond the time domain to the frequency domain of the atrial potentials. They developed a software and found two distinct types of atrial myocardium with different atrial potentials: compact and fibrillar atrial myocardium. Compact atrial myocardium was accepted as the normal atrial myocardium and demonstrated a well-defined homogeneous shape with one high-power fundamental frequency and fast, uniformly decreasing harmonics like an atrial action potential, whereas fibrillar atrial myocardium showed low-power fragmented and heterogeneous profile because of the incursion of the nervous fibers into the myocardium.

As the last method, Katritsis et al. (20) used an anatomical approach for VGP ablation in patients with paroxysmal AF. Nineteen patients underwent anatomically guided radiofrequency (RF) ablation at the location of the four main left atrial VGP. Recently, Pokushalov et al. (21) compared HFS-guided VGP ablation and anatomical ablation in a similar patient population. Eighty patients with paroxysmal AF were randomized to undergo selective VGP ablation or regional left atrial ablation at the anatomical sites of VGP. For selective VGP ablation, ablation targets were the sites where vagal reflexes (prolongation of the R-R interval by >50% and a concomitant decrease in blood pressure by >20 mm Hg) were evoked by HFS. The end point of the procedure was failure to reproduce vagal reflexes with repeated HFS. For anatomical ablation, lesions were delivered at the sites of VGP clustering. Surprisingly, vagal denervation was more prominent in patients with anatomical VGP ablation than selective VGP ablation.

There are some significant restrictions for all these modalities: (1) HFS may cause the sensations of discomfort and inadvertent vagal affects because of concomitant afferent autonomic nerve stimulation. Therefore, conscious patients may not tolerate >15 V and general anesthesia may be needed.; (2) SA required an additional equipment to convert time-amplitude curves to frequency-amplitude curves. The main restriction of anatomical approach is that ablation is performed at empirically identified sites. Although there is no comparison study in AF population, we have recently compared three VGP identification methods ablation in patients with reflex syncope and demonstrated that the methodologies incorporating HFS into VGP abla-

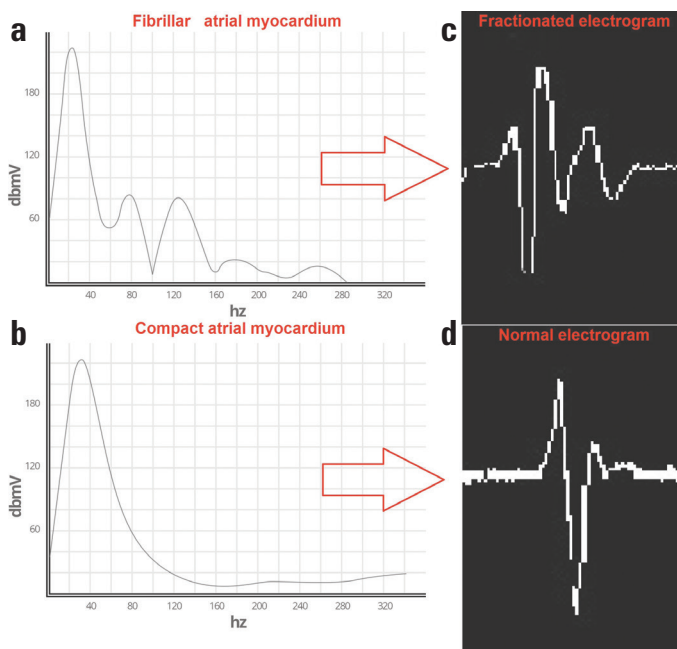


Figure 2. Spectral mapping and intracardiac recordings of fibrillar and compact atrial myocardium. (a) The fibrillar atrial myocardium presents a fractionated pattern with frequency >100 Hz on spectral analysis. (b) The compact atrial myocardium demonstrates homogenous spectrum with frequency <40 Hz on spectral analysis. (c) Areas that are compatible with fibrillar atrial myocardium demonstrates a complex fractionated pattern with ≥ 4 deflections at filter settings of 300–500 Hz on intracardiac recordings. (d) Areas that are compatible with compact atrial myocardium demonstrates monophasic or biphasic pattern on intracardiac recordings

tion may be associated with lower syncope recurrence rates than only anatomical approach (22).

In our previous work, we used a combination of all these modalities with a great success in bradyarrhythmia patients (23). By using FFT analysis, fibrillar atrial myocardium sites detected and tagged as ablation targets (Fig. 2). HFS was then delivered to these sites to evaluate parasympathetic response. Only sites demonstrating positive response ablated. Ablation lesions were extended if the sites suitable with ganglion A-C, anatomically. It seems reasonable that such a combined approach may decrease unnecessary ablation lesions.

VGP and AF

To uncover the mechanism of AF initiation, different hypotheses have been put forward in the last five decades. In 1998, Haissaguerre et al. (3) demonstrated the myocardial sleeves of the PVs as main triggering and maintaining foci for paroxysmal AF. Since then, PVI with the use of RF energy or cryoballoon has been accepted as the mainstay ablation modality for paroxysmal AF. However, this hypothesis cannot explain initiation of AF in all cases. Despite similar PV and myocardial sleeve anatomical properties, why does AF occur in some patients but not in the others is the main question. To define the mechanism how a single PV depolarization is converted to AF, Scherlag et al. (24) investigated the effects of VGP stimulation at voltages ranging

from 0.6 to 4.0 V in 14 anesthetized dogs. They demonstrated that stimuli applied to PVs would not induce AF unless there was simultaneous stimulation of the adjacent VGP (20 Hz, 0.1-ms pulse width) that excites the atrial myocardium. Same group showed that injection of acetylcholine into VGP induced focal firing originating from the adjacent PV and sustained AF.

Patterson et al. (25) investigated electrophysiological effects of the parasympathetic system. Autonomic nerve stimulation decreased PV sleeve action potential duration and initiated rapid firing from early after depolarizations in 22 of 28 PV preparations. Muscarinic receptor blockade prevented action potential duration shortening in eight of eight preparations and suppressed firing in six of eight preparations. Suppression of the calcium transient with ryanodine or sodium–calcium exchange blockade suppressed firing in the majority of preparations. All these electrophysiological effects (shortening of action potential duration, early afterdepolarization formation, and triggered firing) differ from the adjacent left atrial myocardium and demonstrate that the PV myocardium is more sensitive to autonomic stimulation than left atrial myocardium, which may explain why AF usually start with an extra beat arising from PVs.

Therefore, experimental studies demonstrated that increased parasympathetic tone may facilitate triggering of local AF foci. However, when we consider the multifactorial nature of AF, the parasympathetic system should not be accepted as main culprit in etiopathogenesis of AF except for a small number of vagally induced AF.

Ablation of VGP

As it has been shown that the autonomic nervous system plays a central role in initiating AF and in atrial autonomic remodeling, partial or complete vagal denervation through VGP ablation, either alone or in combination with PVI, has been investigated. The main limitation of these studies is the marked variation in the ablation methods.

In the first human study, Pappone et al. (26) assessed the incremental benefit of vagal denervation by RF in preventing recurrent AF in patients undergoing circumferential PV ablation for paroxysmal AF. During RF ablation, the sites demonstrating positive vagal response were identified and ablated until either these reflexes were abolished or for ≤ 30 s. The abolition of all vagal reflexes was defined as complete vagal denervation and obtained in 34.3% of the 297 paroxysmal AF patients. Late AF recurrences were less frequent in patients with complete vagal denervation. The main limitation of this study was that VGP was not specifically targeted in any patient.

Pachon et al. (19) investigated the potential role of VGP ablation without PVI by using FFT analysis in patients with paroxysmal and persistent AF. After 9.9 ± 5 months, 94.1% paroxysmal or persistent AF patients were in sinus rhythm with no documented episode of AF. Only two patients had AF relapse (5.9%) that was responsive to previously ineffective medication. When the results of this study were evaluated, it should be kept in mind that

ablation sites were very close to PVs. In the left atrium, 91.1% and 67.6% ganglionic areas were near left superior and inferior PVs, respectively. A similar relationship existed for right superior and inferior PVs (88.2% and 52.9%, respectively). Furthermore, nonintentional electrical isolation of 35 PVs was observed during the ablation of VGP in 34 patients. Thus, we cannot attribute the success of the procedure to VGP ablation entirely.

In 2006, Scanavacca et al. (18) conducted a similar research investigating effectiveness of VGP-ablation-alone strategy by using in 10 patients with vagal-induced paroxysmal AF. Two of the seven patients who underwent denervation remained asymptomatic without antiarrhythmic medication at a mean follow-up of 8.3 ± 2.8 months; four had frequent recurrences and were referred for circumferential PV ablation; and one had few AF episodes without antiarrhythmic medication. One patient had acute delayed gastric emptying after atrial vagal denervation.

In 2008, Katritris et al. (20) compared anatomically guided VGP ablation with conventional circumferential PV ablation. Arrhythmia recurred in seven patients (37%) with circumferential ablation and 14 patients (74%) with VGP ablation, during 1-year follow-up. In two patients with VGP ablation, left atrial flutter episodes in addition to AF episodes were documented during follow-up. Patients who underwent VGP ablation had almost 2.5 times higher risk of AF recurrence than those who underwent circumferential ablation.

Pokushalov et al. (21) compared selective VGP ablation identified by HFS with extensive regional ablation targeting the anatomical areas of VGP in patients with paroxysmal AF. Eighty patients were randomized to undergo selective VGP ablation by HFS or regional left atrial ablation at the anatomical sites of VGP without performing PVI. They showed that anatomical VGP ablation produces a better outcome (At 13.1 ± 1.9 months, 42.5% patients with selective VGP and 77.5% patients with anatomical ablation were free of symptomatic AF). The dilemma related with HFS is that HFS with low voltage may be not enough to cause parasympathetic response, whereas HFS with high voltage may be uncomfortable because of chest pain and require general anesthesia.

So, in the next randomized trial of same group, they used HFS in only selected patients and compared three ablation strategies: (1) circumferential PV isolation, (2) anatomical VGP ablation, and (3) circumferential PVI + anatomical VGP ablation (27). The number of included patients was higher than that in the previous study (a total of 242 patients with symptomatic paroxysmal AF). This well-designed trial demonstrated that addition of VGP ablation to PVI confers a significantly higher freedom from AF or atrial tachycardia rate compared with either PVI or VGP ablation alone in patients with paroxysmal AF (74%, 56%, and 48%, respectively).

In our opinion, VGP ablation should not be considered as alternative to PVI at this time. This emphasis is not only for paroxysmal AF but also for nonparoxysmal form. Although there is some discrepancy between the results of studies, addition of VGP ablation to PVI may increase success of ablation if it is performed by

experienced operators.

As emphasized the above, pooling of results from different studies on VGP ablation is quite difficult. First, characteristics of selected AF populations vary significantly between studies (paroxysmal, persistent, and even long-standing persistent). Second, a variety of different methods were used to detect vagal innervations sites in the relevant studies. As a result, it is not very easy to say which method is the best to locate VGP. In addition, only left atrial ablation modalities were used in AF trials. However, taking into account the anatomical location of VGP, adjunctive right atrial approach might also be needed to achieve complete vagal denervation. Although this issue was not studied in AF populations, vagal denervation studies on the treatment of bradycardia demonstrated that right atrial ablation may cause significant electrophysiological effects beyond left atrial ablation (23). Furthermore, isolated right atrial ablation may be used as a single strategy in highly selected patients (28).

The efficacy of adjunctive VGP ablation strategies evaluated by three meta-analyses (29–31). These meta-analyses had several limitations. In the first analysis, nonparoxysmal AF ratio was only 12% (29). VGP ablation in addition to PVI or the maze procedure significantly improved freedom from AF or other sustained arrhythmia at 12 months compared with patients who underwent either PVI or maze alone (29). In the other two analyses, adjunctive VGP and CFAE ablation were concomitantly reviewed. Zhang et al. (30) collected an analysis of controlled trials comparing the effect of PVI + CFAE/VGP ablation with PVI, as well as CFAE/VGP ablation with PVI. Subgroup analysis showed that additional VGP ablation increased the ratio of sinus rhythm maintenance in both paroxysmal and nonparoxysmal AF patients. Similarly, addition of VGP ablation to PVI significantly increased freedom from atrial tachyarrhythmias in short-term and long-term follow-up, whereas adjunctive CFAE ablation did not offer any further benefits following the initial and the repeat procedure (31). Therefore, isolated VGP ablation seems to be inferior or at least not superior to PVI when all result are considered.

Fractionated atrial electrograms and VGP

After demonstration of close relationship between CFAEs and positive autonomic response by Lemery et al. (32), anatomical and physiological background of this association was studied by different groups. In an animal model, Lin et al. (33) applied acetylcholine to the atria in varying concentrations during AF. They found that the incidence of inducing local CFAE was correlated with the concentration of acetylcholine applied. Furthermore, they showed that CFAE could be attenuated or eliminated by ablation of these plexi. Therefore, the occurrence of CFAE did not solely result from a change in local electrophysiological properties, but it also involved the activation of the neural network within the intrinsic cardiac autonomic nervous system. Lellouche et al. (34) took fractionated electrogram and vagal response association further. They defined three different left atrial endocardial electrograms during sinus rhythm in

patients with paroxysmal AF: normal, low-amplitude fragmented electrograms, and high-amplitude fragmented electrograms and found that the high-amplitude fragmented electrogram pattern was associated with greater parasympathetic response during RF ablation. A similar relationship was confirmed by our group in different patient populations (23) (Fig. 2).

Knecht et al. (35) investigated CFAE VGP association in detail. They evaluated the impact of pharmacological autonomic blockade on CFAE characteristics. The impact of autonomic blockade on fractionation was assessed by blinded investigators in this study. Following autonomic blockade, the ratio of CFAE sites significantly decreased in patients with paroxysmal AF but not in patients with persistent AF. Furthermore, only in patients with significant prolongation of the AF cycle length after autonomic blockade was a significant reduction in the CFAE proportion.

Pokushalov's group carried this research further and assessed the safety and efficacy of VGP ablation directed by HFS and additional ablation of CFAE around the areas with a positive reaction to HFS, in patients with paroxysmal AF (36). Ablation targets were the sites where vagal reflexes were evoked by HFS the surrounding CFAE areas. Although 71% patients were free of symptomatic AF at 12 months, this was not a comparison or superiority study.

VGP and ligament of Marshall

Ligament of Marshall (LOM) is a vestigial fold of the pericardium that was discovered in 1850. Potential importance of this embryonic formation is that it consists of axonal extensions of the intrinsic cardiac autonomic nervous system (37). The proximal portion of LOM connects to the muscle sleeve of the coronary sinus. This relationship is similar to PV and left atrium connection. The middle and distal portion connects to the left PVs and extends beyond these PVs, respectively. LOM contains Marshall bundles and have multiple reinsertions into the coronary sinus and the left atrial wall (38).

In the beginning, LOM was thought to be associated only with the sympathetic nervous system and the genesis and maintenance of adrenergic AF (39). However, ongoing histological and functional studies demonstrated that both sympathetic and parasympathetic elements are present along LOM and parasympathetic activity originating in LOM may help promote AF (40–42). In an animal study, Ulphani et al. (42) showed that cholinergic nerves originating in LOM were found to innervate surrounding left atrial structures, including the PVs, left atrial appendage, coronary sinus, and posterior left atrial fat pad. Surgical dissection of LOM significantly attenuated effective refractory period shortening at distant sites, such as the PVs and left atrial appendage, in response to vagal stimulation. In another animal study, Liu et al. (43) investigated the impact of LOM ablation on atrial vulnerability to AF induced by inferior left atrial VGP stimulation. Ablation of LOM significantly attenuated AF inducibility and prolonged atrial effective refractory periods of the structures in contiguity with LOM in the ablation group. In

contrast, there was no significant change in atrial effective refractory periods and AF inducibility in non-LOM ablation group. Furthermore, acetylcholinesterase staining, which demonstrates parasympathetic innervation sites, revealed a close relationship between LOM and inferior left atrial VGP.

In a human study, Han et al. (44) investigated the electrophysiological characteristics of LOM and the anatomical connections between LOM and the left atrium in patients with persistent AF. Endocardial and epicardial recordings showed distinct Marshall bundle potentials with a proximal-to-distal activation pattern and organized passive activations and dissociated slow Marshall bundle ectopic activities during sinus rhythm and AF, respectively. As an important point, the activation patterns were irregular and variable in each patient. In 2012, Santini et al. (45) evaluated feasibility and efficacy of PV isolation, VGP ablation, LOM resection, and left atrial appendage exclusion through beating heart minimally invasive bilateral thoracotomies in patients with paroxysmal and persistent AF. Freedom from AF recurrences independently from antiarrhythmic therapy status was 91% at 12 months. A similar higher success rates with the addition of surgical LOM ablation was demonstrated by other groups in especially long-standing persistent AF (46).

Endocardial ablation of LOM was firstly studied by Hwang et al. (47). After anatomical demonstration of LOM by balloon-occlusion coronary sinus angiograms, they advanced a 1.5-French electrophysiological catheter into LOM via the coronary sinus orifice and demonstrated characteristic Marshall bundle potentials. LOM was visualized by coronary sinus angiography and successfully cannulated with the recording catheter in 19 and in 17 of the 28 paroxysmal AF patients. In eight of these 17 patients, double potentials associated with Marshall bundle were detected both inside the left superior PV and inside LOM. LOM was found as primary trigger site in six of eight patients and successfully ablated via endocardial approach in four of six patients.

Although LOM can be ablated from the endocardial aspect of the left atrium inferior to the ostium of the left inferior PV, it may occasionally require direct catheterization from within the coronary sinus (48). Recently, as an alternative method of LOM ablation, ethanol infusion was demonstrated to achieve effective ablation of LOM throughout its course between the mitral annulus and the left superior PV (49, 50). One of these studies is fascinating due demonstration of the parasympathetic effects of LOM ablation (50). In patients undergoing catheter AF ablation, adjunctive ethanol injection in LOM abolished parasympathetic responses in all patients. Furthermore, ethanol infusion in LOM abolished AF induction upon repeated HFS in all patients in whom AF-initiating atrial premature contractions were recorded first in LOM.

Conclusion

VGP may play an important role in generation and perpetuation of AF. VGP ablation in addition to PVI in AF ablation may be more effective than either one alone. Despite the encouraging

result of the repeated studies, there are quite difficult questions that should be answered, such as how to detect VGP precisely, achieve complete VGP ablation, and prevent reinnervation. Future studies are needed to improve current VGP-ablation techniques in patients with AF.

Conflict of interest: None declared.

Peer-review: Externally peer-reviewed.

Authorship contributions: Concept – T.A., T.E.G.; Design – T.A., F.O.M.; Supervision – A.O., F.O.M.; Analysis &/or interpretation – A.O., F.O.M.; Literature search – T.A., T.E.G.; Writing – T.A., F.O.M.; Critical review – A.O.

References

1. Ertaş F, Kaya H, Yüksel M, Soyduñç MS, Alan S, Ülgen MS. Atrial fibrillation in Turkey: Epidemiologic Registry (AFTER) study design. *Anadolu Kardiyol Derg* 2013; 13: 339-43.
2. Ertaş F, Eren NK, Kaya H, Arıbaş A, Acar G, Kanadaşı M, et al. The atrial fibrillation in Turkey: Epidemiologic Registry (AFTER). *Cardiol J* 2013; 20: 447-52.
3. Haissaguerre M, Jais P, Shah DC, Takahashi A, Hocini M, Quiniou G, et al. Spontaneous initiation of atrial fibrillation by ectopic beats originating in the pulmonary veins. *N Engl Med* 1998; 339: 659-66.
4. Lin WS, Tai CT, Hsieh MH, Tsai CF, Lin YK, Tsao HM, et al. Catheter ablation of paroxysmal atrial fibrillation initiated by non-pulmonary vein ectopy. *Circulation* 2003; 107: 3176-83.
5. Kirchhof P, Benussi S, Kotecha D, Ahlsson A, Atar D, Casadei B, et al. 2016 ESC Guidelines for the management of atrial fibrillation developed in collaboration with EACTS. *Europace* 2016; 18: 1609-78.
6. Aksu T, Gölcük SE, Güler TE, Yalın K, Erden I. Prediction of mid-term outcome after cryo-balloon ablation of atrial fibrillation using post-procedure high-sensitivity troponin level. *Cardiovasc J Afr* 2015; 26: 165-70.
7. Aksu T, Baysal E, Güler TE, Gölcük SE, Erden İ, Özcan KS. Predictors of atrial fibrillation recurrence after cryoballoon ablation. *J Blood Med* 2015; 6: 211-7.
8. Boveda S, Providência R, Defaye P, Pavin D, Cebon JP, Anselme F, et al. Outcomes after cryoballoon or radiofrequency ablation for persistent atrial fibrillation: a multicentric propensity-score matched study. *J Interv Card Electrophysiol* 2016; 47: 133-42.
9. Knecht S, Hocini M, Wright M, Lellouche N, O'Neill MD, Matsuo S, et al. Left atrial linear lesions are required for successful treatment of persistent atrial fibrillation. *Eur Heart J* 2008; 29: 2359-66.
10. Nademanee K, McKenzie J, Kosar E, Schwab M, Sunsaneewitayakul B, Vasavakul T, et al. A new approach for catheter ablation of atrial fibrillation: mapping of the electrophysiologic substrate. *J Am Coll Cardiol* 2004; 43: 2044-53.
11. Aksu T, Güler TE, Yalın K, Oto A. Unanswered questions in complex fractionated atrial electrogram ablation. *Pacing Clin Electrophysiol* 2016; 39: 1269-78.
12. Lemola K, Chartier D, Yeh YH, Dubuc M, Cartier R, Armour A, et al. Pulmonary vein region ablation in experimental vagal atrial fibrillation: role of pulmonary veins versus autonomic ganglia. *Circulation* 2008; 117: 470-7.
13. Mikhaylov E, Kanidieva A, Sviridova N, Abramov M, Gureev S, Szilitorok T, et al. Outcome of anatomic ganglionated plexi ablation to treat paroxysmal atrial fibrillation: a 3-year follow-up study. *Europace* 2011; 13: 362-70.
14. Katritsis DG, Giazitzoglou E, Zografos T, Pokushalov E, Po SS, Camm AJ. Rapid pulmonary vein isolation combined with autonomic ganglia modification: a randomized study. *Heart Rhythm* 2011; 8: 672-8.
15. Armour JA, Murphy DA, Yuan BX, Macdonald S, Hopkins DA. Gross and microscopic anatomy of the human intrinsic cardiac nervous system. *Anat Rec* 1997; 247: 289-98.
16. Chiou CW, Eble JN, Zipes DP. Efferent vagal innervation of the canine atria and sinus and atrioventricular nodes. The third fat pad. *Circulation* 1997; 95: 2573-84.
17. Schauerte P, Scherlag BJ, Pitha J, Scherlag MA, Reynolds D, Lazzara R, et al. Catheter ablation of cardiac autonomic nerves for prevention of vagal atrial fibrillation. *Circulation* 2000; 102: 2774-80.
18. Scanavacca M, Pisani CF, Hachul D, Lara S, Hardy C, Darrieux F, et al. Selective atrial vagal denervation guided by evoked vagal reflex to treat patients with paroxysmal atrial fibrillation. *Circulation* 2006; 114: 876-85.
19. Pachon M JC, Pachon M EI, Pachon M JC, Lobo TJ, Pachon MZ, Vargas RN, et al. A new treatment for atrial fibrillation based on spectral analysis to guide the catheter RF-ablation. *Europace* 2004; 6: 590-601.
20. Katritsis D, Giazitzoglou E, Sougiannis D, Goumas N, Paxinos G, Camm AJ. Anatomic approach for ganglionic plexi ablation in patients with paroxysmal atrial fibrillation. *Am J Cardiol* 2008; 102: 330-4.
21. Pokushalov E, Romanov A, Shugayev P, Artyomenko S, Shirokova N, Turov A, et al. Selective ganglionated plexi ablation for paroxysmal atrial fibrillation. *Heart Rhythm* 2009; 6: 1257-64.
22. Aksu T, Güler TE, Bozyel S, Özcan KS, Yalın K, Mutluer FO. Cardioneuroablation in the treatment of neurally mediated reflex syncope: a review of the current literature. *Turk Kardiyol Dern Ars* 2017; 45: 33-41.
23. Aksu T, Gölcük E, Yalın K, Güler TE, Erden I. Simplified cardioneuroablation in the treatment of reflex syncope, functional AV block, and sinus node dysfunction. *Pacing Clin Electrophysiol* 2016; 39: 42-53.
24. Scherlag BJ, Yamanashi W, Patel U, Lazzara R, Jackman WM. Autonomically induced conversion of pulmonary vein focal firing into atrial fibrillation. *J Am Coll Cardiol* 2005; 45: 1878-86.
25. Patterson E, Po SS, Scherlag BJ, Lazzara R. Triggered firing in pulmonary veins initiated by in vitro autonomic nerve stimulation. *Heart Rhythm* 2005; 2: 624-31.
26. Pappone C, Santinelli V, Manguso F, Vicedomini G, Gugliotta F, Augello G, et al. Pulmonary vein denervation enhances long-term benefit after circumferential ablation for paroxysmal atrial fibrillation. *Circulation* 2004; 109: 327-34.
27. Katritsis DG, Pokushalov E, Romanov A, Giazitzoglou E, Siontis GC, Po SS, et al. Autonomic denervation added to pulmonary vein isolation for paroxysmal atrial fibrillation: a randomized clinical trial. *J Am Coll Cardiol* 2013; 62: 2318-25.
28. Aksu T, Gölcük SE, Erdem Güler T, Yalın K, Erden I. Functional permanent 2:1 atrioventricular block treated with cardioneuroablation: Case report. *HeartRhythm Case Rep* 2015; 1: 58-61.
29. Zhou Q, Hou Y, Yang S. A meta-analysis of the comparative efficacy of ablation for atrial fibrillation with and without ablation of the ganglionated plexi. *Pacing Clin Electrophysiol* 2011; 34: 1687-94.
30. Zhang Y, Wang Z, Zhang Y, Wang W, Wang J, Gao M, et al. Efficacy of cardiac autonomic denervation for atrial fibrillation: a meta-analysis. *J Cardiovasc Electrophysiol* 2012; 23: 592-600.

31. Qin M, Liu X, Wu SH, Zhang XD. Atrial substrate modification in atrial fibrillation: Targeting GP or CFAE? Evidence from meta-analysis of clinical trials. *PLoS One* 2016; 11: e0164989.
32. Lemery R, Birnie D, Tang AS, Green M, Gollob M. Feasibility study of endocardial mapping of ganglionated plexuses during catheter ablation of atrial fibrillation. *Heart Rhythm* 2006; 3: 387-96.
33. Lin J, Scherlag BJ, Zhou J, Lu Z, Patterson E, Jackman WM, et al. Autonomic mechanism to explain complex fractionated atrial electrograms (CFAE). *J Cardiovasc Electrophysiol* 2007; 18: 1197-205.
34. Lellouche N, Buch E, Celigoj A, Siegerman C, Cesario D, De Diego C, et al. Functional characterization of atrial electrograms in sinus rhythm delineates sites of parasympathetic innervation in patients with paroxysmal atrial fibrillation. *J Am Coll Cardiol* 2007; 50: 1324-31.
35. Knecht S, Wright M, Matsuo S, Nault I, Lellouche N, Sacher F, et al. Impact of pharmacological autonomic blockade on complex fractionated atrial electrograms. *J Cardiovasc Electrophysiol* 2010; 21: 766-72.
36. Pokushalov E, Romanov A, Artyomenko S, Shirokova N, Turov A, Karaskov A, et al. Ganglionated plexi ablation directed by high-frequency stimulation and complex fractionated atrial electrograms for paroxysmal atrial fibrillation. *Pacing Clin Electrophysiol* 2012; 35: 776-84.
37. Pauza DH, Skripka V, Pauziene N. Morphology of the intrinsic cardiac nervous system in the dog: a whole-mount study employing histochemical staining with acetylcholinesterase. *Cells Tissues Organs* 2002; 172: 297-320.
38. Kim DT, Lai AC, Hwang C, Fan LT, Karagueuzian HS, Chen PS, et al. The ligament of Marshall: a structural analysis in human hearts with implications for atrial arrhythmias. *J Am Coll Cardiol* 2000; 36: 1324-7.
39. Wu TJ, Ong JJ, Chang CM, Doshi RN, Yashima M, Huang HL, et al. Pulmonary veins and ligament of Marshall as sources of rapid activations in a canine model of sustained atrial fibrillation. *Circulation* 2001; 103: 1157-63.
40. Makino M, Inoue S, Matsuyama TA, Ogawa G, Sakai T, Kobayashi Y, et al. Diverse myocardial extension and autonomic innervations on ligament of Marshall in humans. *J Cardiovasc Electrophysiol* 2006; 17: 594-9.
41. Lin J, Scherlag BJ, Lu Z, Zhang Y, Liu S, Patterson E, et al. Inducibility of atrial and ventricular arrhythmias along the ligament of marshall: role of autonomic factors. *J Cardiovasc Electrophysiol* 2008; 19: 955-62.
42. Ulphani JS, Arora R, Cain JH, Villuendas R, Shen S, Gordon D, et al. The ligament of Marshall as a parasympathetic conduit. *Am J Physiol Heart Circ Physiol* 2007; 293: H1629-35.
43. Liu X, Yan Q, Li H, Tian Y, Su J, Tang R, et al. Ablation of ligament of Marshall attenuates atrial vulnerability to fibrillation induced by inferior left atrial fat pad stimulation in dogs. *J Cardiovasc Electrophysiol* 2010; 21: 1024-30.
44. Han S, Joung B, Scanavacca M, Sosa E, Chen PS, Hwang C. Electrophysiological characteristics of the Marshall bundle in humans. *Heart Rhythm* 2010; 7: 786-93.
45. Santini M, Loiaconi V, Tocco MP, Mele F, Pandozi C. Feasibility and efficacy of minimally invasive stand-alone surgical ablation of atrial fibrillation. A single-center experience. *J Interv Card Electrophysiol* 2012; 34: 79-87.
46. Kurfirst V, Mokraček A, Bulava A, Čanadyova J, Haniš J, Pešl L. Two-staged hybrid treatment of persistent atrial fibrillation: short-term single-centre results. *Interact Cardiovasc Thorac Surg* 2014; 18: 451-6.
47. Hwang C, Wu TJ, Doshi RN, Peter CT, Chen PS. Vein of marshall cannulation for the analysis of electrical activity in patients with focal atrial fibrillation. *Circulation* 2000; 101: 1503-5.
48. Choi JI, Pak HN, Park JH, Choi EJ, Kim SK, Kwak JJ, et al. Clinical significance of complete conduction block of the left lateral isthmus and its relationship with anatomical variation of the vein of Marshall in patients with nonparoxysmal atrial fibrillation. *J Cardiovasc Electrophysiol* 2009; 20: 616-22.
49. Valderrábano M, Liu X, Sasaridis C, Sidhu J, Little S, Khoury DS. Ethanol infusion in the vein of Marshall: Adjunctive effects during ablation of atrial fibrillation. *Heart Rhythm* 2009; 6: 1552-8.
50. Báez-Escudero JL, Keida T, Dave AS, Okishige K, Valderrábano M. Ethanol infusion in the vein of Marshall leads to parasympathetic denervation of the human left atrium: implications for atrial fibrillation. *J Am Coll Cardiol* 2014; 63: 1892-901.
51. Pachon JC, Pachon EI, Pachon JC, Lobo TJ, Pachon MZ, Vargas RN, et al. "Cardioneuroablation"--new treatment for neurocardiogenic syncope, functional AV block and sinus dysfunction using catheter RF-ablation. *Europace* 2005; 7: 1-13.