

## CASE REPORT

# Congenital cutaneous candidiasis in a premature neonate: A case report

Jose Ricardo Ruiz-Cabrera<sup>1</sup>  | Daniela Meléndrez-Vásquez<sup>2</sup>  |  
Diana Melissa Moreno<sup>2</sup>  | Reinaldo Prieto-Jure<sup>3</sup> 

<sup>1</sup>Department of Dermatology, Hospital Universitario Mayor Méderi-Universidad del Rosario, Bogotá, Colombia

<sup>2</sup>School of Medicine and Health Sciences, Hospital Universitario Mayor Méderi-Universidad del Rosario, Bogotá, Colombia

<sup>3</sup>Department of Neonatology, Hospital Universitario Mayor Méderi-Universidad del Rosario, Bogotá, Colombia

## Correspondence

Daniela Meléndrez-Vásquez, School of Medicine and Health Sciences, Hospital Universitario Mayor Méderi-Universidad del Rosario, Calle 24 # 29-45, Bogotá, Colombia.  
Email: [daniela.melendrez@urosario.edu.co](mailto:daniela.melendrez@urosario.edu.co)

## Funding information

None

## Abstract

Congenital cutaneous candidiasis (CCC) is a rare and usually benign disorder that develops within the first week of life. It predominantly presents with diffuse maculopapular and papulopustular erythematous desquamating patches. We report a preterm neonate with respiratory distress syndrome and skin diffuse maculopapular lesions at birth. *Candida albicans* was isolated from skin and gastrointestinal fluid culture; she underwent medical treatment with topical and systemic antifungal with clinical improvement and skin lesions resolution.

## KEYWORDS

*Candida albicans*, case report, congenital cutaneous candidiasis, congenital infection

## 1 | INTRODUCTION

Congenital cutaneous candidiasis (CCC) is a rare fungal infection caused by ascending intrauterine infection from *Candida* spp. The clinical presentation takes place within the first 24 h to the first week of life.<sup>1,2</sup> It is secondary to membrane rupture, chorioamnionitis, or on account of vertical transmission during labor in mothers with *Candida* spp. infection.<sup>3</sup> Literature around this condition is limited, with only a few case reports. Currently, there are no studies registered in Colombia regarding CCC; therefore, this is a pioneering case report in the country.

## 2 | CASE DESCRIPTION

A 36 week gestational age preterm female neonate, adequate weight for gestational age (2730 g), with an unremarkable past prenatal history and vaginal delivery. Her mother was a 26-year old, gravida 1, para 0, with a medical history of recurrent urinary tract infections and fungal vaginosis treated during pregnancy. She did not have a vaginal leak, blood, or premature rupture of the membrane before the onset of labor. Spontaneous neonatal adaptation with APGAR scores 7 and 8 at 1 and 5 min. Silverman's scoring system was 3–4. She had low oxygen

This is an open access article under the terms of the [Creative Commons Attribution-NonCommercial](https://creativecommons.org/licenses/by-nc/4.0/) License, which permits use, distribution and reproduction in any medium, provided the original work is properly cited and is not used for commercial purposes.

© 2022 The Authors. *Clinical Case Reports* published by John Wiley & Sons Ltd.

saturation levels impending respiratory distress; therefore, she received non-invasive respiratory support for 24 h with an adequate response.

During delivery, there was no umbilical cord compromise. Immediately at birth, on examination, multiple erythematous desquamative plaques along with papules and vesicles localized in the back, abdomen, lower and upper extremities, neck, axillary region, retro auricular region, and groin area were observed. Skin lesions had a burning-like dermatitis appearance. There was no palmar or plantar compromise nor mucous and skin appendages involvement (Figure 1).

Cerebral, abdominal, and cardiac ultrasound were unremarkable. Chest radiography and lumbar puncture were within normal limits. The patient had no ophthalmological compromise. Bloodwork showed a total leukocyte count of  $50,130/\text{mm}^3$ , a neutrophil count of  $32,720/\text{m}^3$ , and blood cultures were negative after 72 h. Skin swab and gastric aspirate were obtained for direct microscopy and culture. Potassium hydroxide preparation (KOH) revealed pseudohyphae and budding yeast cells. Culture on Sabouraud's dextrose agar and CHROMagar *Candida* Medium showed creamy-gray colonies and green colonies, respectively. *Candida albicans* species was confirmed with the BD Phoenix system. The isolate exhibited susceptibility to amphotericin B, echinocandins, and azole antifungals.

Further evaluation ruled out immunodeficiency virus, syphilis, and hepatitis B and C infection. The study of lymphocyte subpopulations showed normal immunoglobulin, T lymphocyte, and B lymphocyte levels.

At the neonatal intensive care unit (NICU), the patient received topical Nystatin 100,000 units/g cream four times per day and an intravenous fluconazole loading dose of 25 mg/kg, followed by 12 mg/day IV for seven days. Subsequently, oral fluconazole 12 mg/day and topical

Clotrimazole 1% were continued for 7 days with an adequate response (Figures 2–4).

### 3 | DISCUSSION

CCC is a rare invasive fungal infection of the epidermis and dermis caused by ascending intrauterine infection from *Candida* spp. CCC is estimated to occur in 0.1% of NICU admissions.<sup>1–3</sup> Common risk factors include pre-term neonates, gestational age less than 27 weeks, and weight <1000 g.<sup>4</sup> In addition, further risk factors are the presence of intrauterine devices, maternal history of cervical cerclage, and invasive maneuvers during delivery.<sup>5</sup> Other risk factors that may participate CCC are premature membrane rupture and the mother's diagnosis of fungal vaginosis previously.<sup>4–6</sup> In this case, the mother had recurrent vaginal infections treated during pregnancy. Before the onset of labor, the mother did not have a vaginal leak, blood, or premature membrane rupture. However, *Candida* spp., particularly *Candida albicans*, may penetrate the amniotic sac without evident membrane rupture, and it can develop in the absence of symptomatic vaginal candidiasis.<sup>5</sup> Furthermore, this condition may occur either from vaginal or abdominal delivery.<sup>4–6</sup> Regarding mucocutaneous compromise, manifestations are the result of the aspiration of infected amniotic fluid.<sup>6</sup>

Clinically, CCC develops within the first week of life, usually within a few hours of birth. It has a heterogeneous presentation that varies according to the following factors: host immune response, number of microorganisms, and time of exposure.<sup>1–6</sup> It typically initiates with diffuse maculopapular exanthema, with scaly patches localized in the face, scalp, extensor surfaces of extremities, and umbilical region.<sup>2</sup> Diaper area, palms, and soles are usually spared.<sup>5</sup> Primarily, it begins with erythematous patches that evolve to generalized diffuse papules and pustules, which resolve with desquamation.<sup>8</sup> Other clinical manifestations are paronychia, onychia, and funisitis. In addition, in the context of chorioamnionitis, yellow-white plaques in the proximal umbilical cord could be present.<sup>10</sup> Also, some cases present with skin compromise resembling burning-like dermatitis.<sup>6</sup> Additional clinical features may include pustules in the palmar and plantar region.<sup>5</sup>

Every CCC approach should begin with clinical suspicion. However, a definite diagnosis, including microscopic evaluation, and the culture of Sabouraud dextrose agar from the mucocutaneous lesions, placenta, or umbilical cord, should be assessed.<sup>5–8</sup> The clinical course is benign and auto-limited. Generally, skin lesions resolve within 5–20 days. However, this condition might lead to systemic involvement, the former embrace *Candida* septicemia, meningitis, bronchopneumonia, arthritis,

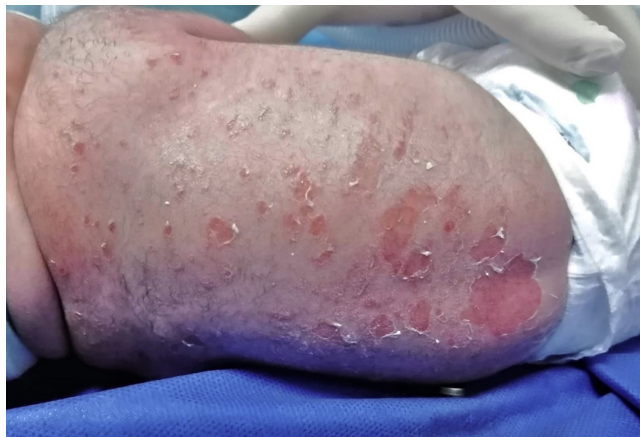

FIGURE 1 One-day neonate with diffuse erythema macular papular rash desquamation

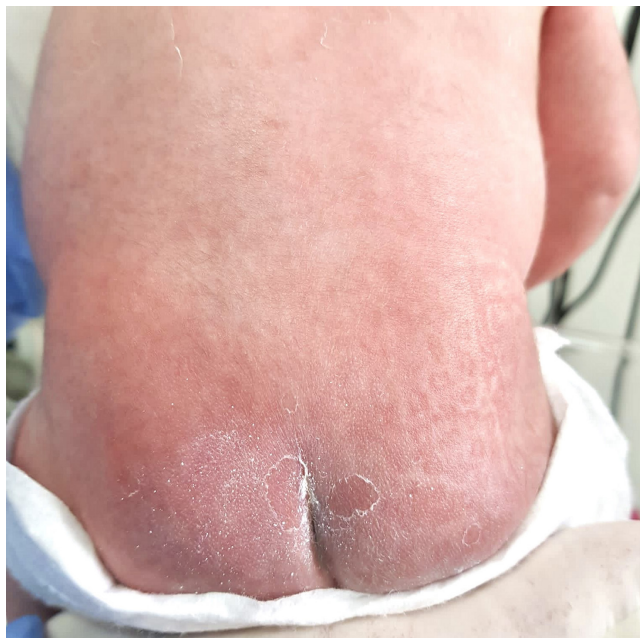

FIGURE 2 Ten days of life. Skin involvement resolution

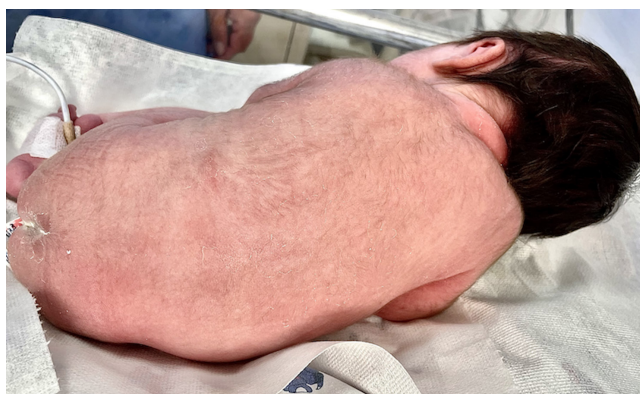

FIGURE 3 Fourteen days of life. Back skin involvement resolution

and endocarditis, associated with high mortality rates.<sup>5</sup> Therefore, it is essential to evaluate complications.<sup>8</sup> However, extensive evaluation should be warranted when respiratory distress, positive cultures from blood, urine, and cerebrospinal fluid, leukocytosis with left shift, and burning-like dermatitis.<sup>9,10</sup>

Regarding the treatment for CCC, topical Nystatin is the most common treatment, followed by topical Clotrimazole.<sup>1</sup> On the contrary, systemic antifungal therapy has efficacy in neonatal sepsis, weight <1500 g, broad-spectrum antibiotics previous treatment, respiratory distress, positive cultures, and immunodeficiency.<sup>5-9</sup> Management includes non-azole antifungal Amphotericin B, 1mg/kg for Amphotericin B deoxycholate, 5 mg/kg for lipid-associated Amphotericin B preparations, and 6–12 mg/kg fluconazole.<sup>3-10</sup> In addition, Caspofungin

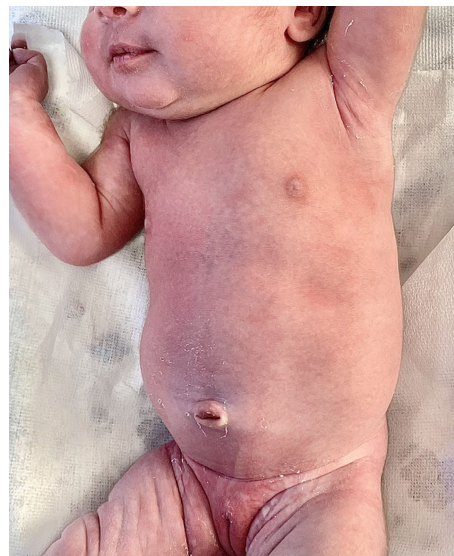

FIGURE 4 Fourteen days of life. Skin involvement resolution

should be an option in cases of refractory Candidemia or invasive candidiasis, although data in neonates are limited.<sup>4-6</sup>

In this case, clinical examination revealed multiple erythematous diffuse maculopapular and scaly patches resembling a burn. CCC was confirmed with KOH, direct microscopy, culture of the skin, and gastrointestinal fluid culture. Although risk factors for a systemic compromise like respiratory distress, leukocytosis with left shift, and burning-like dermatitis appearance, the patient had an excellent response to treatment with topical and systemic therapy within the first week.

## 4 | CONCLUSION

CCC is a rare invasive infection with few reports in the literature; it can occur in preterm or term neonates with heterogeneous clinical manifestations. Generally, the clinical course is benign and auto-limited. Early recognition and prompt diagnosis are essential to initiate treatment to avoid systemic compromise.

## ACKNOWLEDGEMENT

Hospital Universitario Mayor Méderi

## CONFLICT OF INTERESTS

The funding organization played no role in the report's writing or the decision to submit the report for publication.

## AUTHOR CONTRIBUTIONS

Ruiz Cabrera Jose Ricardo involved in approval of the final version of the manuscript, conception and planning of the study, drafting and editing of the manuscript;



intellectual participation in propaedeutic and/or therapeutic conduct; critical review of the literature; critical review of the manuscript. Meléndrez Vásquez Daniela and Moreno Diana Melissa involved in approval of the final version of the manuscript, conception and planning of the study, drafting and editing of the manuscript, critical review of the literature; critical review of the manuscript. Prieto Jure Reinaldo involved in approval of the final version of the manuscript, conception and planning of the study, drafting and editing of the manuscript; intellectual participation in propaedeutic and/or therapeutic conduct; critical review of the literature; critical review of the manuscript.

### ETHICAL APPROVAL

Ethical approval for this study was obtained from Universidad del Rosario Ethics Committee DVO005 1821-CV1515.

### CONSENT


Informed consent was obtained from the patient mother with written permission for publication of this case report and associated images.

### DATA AVAILABILITY STATEMENT

The data used to support the findings of this study are included within the article.

### ORCID

Jose Ricardo Ruiz-Cabrera  <https://orcid.org/0000-0002-1892-8435>

Daniela Meléndrez-Vásquez  <https://orcid.org/0000-0003-0018-3196>

Diana Melissa Moreno  <https://orcid.org/0000-0002-2295-5508>

Reinaldo Prieto-Jure  <https://orcid.org/0000-0002-7385-3448>

### REFERENCES

- Colantonio S, Hedin E, Li HO, Gavigan G. Management of congenital cutaneous candidiasis in a healthy term baby: a case report. *SAGE Open Med Case Rep.* 2019;7:2050313X1987670. doi:[10.1177/2050313X19876707](https://doi.org/10.1177/2050313X19876707)
- Joy Way Bueno SM, Santos Muñoz A, Maldonado I, Larralde M. Onychodystrophy as the only sign of congenital candidiasis. *Pediatr Dermatol.* 2020;37(1):159-161. doi:[10.1111/pde.14021](https://doi.org/10.1111/pde.14021)
- Nijamin Romina T, Yarza ML, Grees SA. Candidiasis congénita comunicación de un caso. *Dermatol Argent.* 2012;18(3):225-227.
- Georgescu TA, Lisievici A-C, Munteanu O, et al. Congenital systemic candidiasis: a comprehensive literature review and meta-analysis of 44 cases. *Rom J Morphol Embryol.* 2020;61(3):673-680. doi:[10.47162/RJME.61.3.05](https://doi.org/10.47162/RJME.61.3.05)
- Jagtap SA, Saple PP, Dhaliat SB. Congenital cutaneous candidiasis: a rare and unpredictable disease. *Indian J Dermatol.* 2011;56(1):92-93. doi:[10.4103/0019-5154.77564](https://doi.org/10.4103/0019-5154.77564)
- Miras I, Vierge E, García M, et al. Congenital cutaneous candidiasis with systemic dissemination in a preterm infant. *Pediatr Infect Dis J.* 2021;40(6):e230-e233. doi:[10.1097/INF.0000000000003080](https://doi.org/10.1097/INF.0000000000003080)
- Wang SM, Hsu CH, Chang JH. Congenital candidiasis. *Pediatr Neonatol.* 2008;49(3):94-96. doi:[10.1016/S1875-9572\(08\)60020-0](https://doi.org/10.1016/S1875-9572(08)60020-0)
- Tieu KD, Satter EK, Zaleski L, Koehler M. Congenital cutaneous candidiasis in two full-term infants. *Pediatr Dermatol.* 2012;29(4):507-510. doi:[10.1111/j.1525-1470.2011.01468.x](https://doi.org/10.1111/j.1525-1470.2011.01468.x)
- Aruna C, Seetharam K. Congenital candidiasis. *Indian Dermatol Online J.* 2014;5(Suppl 1):S44-S47. doi:[10.4103/2229-5178.144531](https://doi.org/10.4103/2229-5178.144531)
- Fernández-Ruiz M, Mosqueda-Peña R, Pérez-Ayala A, Blázquez-Gamero D. Congenital cutaneous candidiasis associated with maternal peripartum candidemia. *Rev Iberoam Micol.* 2020;37(2):68-71.

**How to cite this article:** Ruiz-Cabrera JR, Meléndrez-Vásquez D, Moreno DM, Prieto-Jure R. Congenital cutaneous candidiasis in a premature neonate: A case report. *Clin Case Rep.* 2022;10:e05773. doi:[10.1002/ccr3.5773](https://doi.org/10.1002/ccr3.5773)