

Eldecalcitol, an active vitamin D analog, effectively prevents cyclophosphamide-induced osteoporosis in rats

WEI WANG^{1*}, YUAN GAO^{1*}, HONGRUI LIU¹, WEI FENG², XIAOYAN LI¹, JIE GUO¹ and MINQI LI¹

¹Department of Bone Metabolism, School of Stomatology, Shandong University, Shandong Provincial Key Laboratory of Oral Tissue Regeneration, Jinan, Shandong 250012;
²Department of Endodontics, Jinan Stomatological Hospital, Jinan, Shandong 250001, P.R. China

Received December 8, 2018; Accepted May 9, 2019

DOI: 10.3892/etm.2019.7759

Abstract. Cyclophosphamide (CTX) as an alkylating agent is used for treating a range of tumor types and allergic diseases. However, high-dose application may induce rapid bone loss and increase the risk of osteoporotic fractures. Eldecalcitol (ED-71), a clinically approved active vitamin D analog, has been approved for osteoporosis treatment. It potently inhibited bone resorption while maintaining osteoblastic function in estrogen-deficient and high-turnover osteoporosis in model rats. The aim of the present study was to clarify the treatment effect of ED-71 on bone loss in a well-established rat model of osteoporosis with CTX administration. After 15 days of CTX treatment, ED-71 was administered, while estradiol valerate (E2V) was used as a positive control. At 2 and 4 weeks after ED-71 or E2V administration, rats were sacrificed and fixed. The tibiae were extracted for histochemical analysis using hematoxylin and eosin staining and immunohistochemistry. When compared with the untreated control group, the CTX group displayed clear osteoporotic features, including a decreased number of bone trabeculae and increased trabecular separation. ED-71 and E2V successfully rescued CTX-induced bone loss. The ED-71 group displayed denser and increasingly mature trabecular bone than the E2V group. Furthermore, ED-71 administration led to significant suppression of tartrate-resistant acid phosphatase (TRAP), cathepsin K (CK), matrix metalloproteinase 9 (MMP9), alkaline phosphatase (ALP) and Osteopontin (OPN), which was less pronounced than in E2V administration but was similar to the values exhibited in the normal control group. These results indicated

that ED-71 had a moderate and increased effect on bone turnover compared with E2V. Therefore, the present study suggests that ED-71 is a potential inhibitor of CTX-induced osteoporosis, successfully rescuing bone loss without excessively suppressing bone turnover, and may be a suitable treatment for preventing bone loss in patients receiving CTX.

Introduction

Cyclophosphamide (CTX) is a drug commonly used for the treatment of neoplastic diseases as well as preparation for bone marrow transplantation. It is applied as a chemotherapeutic and an immune suppressor. As the former, it is used to treat leukemia, breast cancers, ovarian cancers, small cell lung cancer and sarcoma (1-3), and as the latter, has applications in conditions including granulomatosis with polyangiitis and nephrotic syndrome, as well as following organ transplant (4). It is mostly administered by oral or vein injection. Loss of appetite, hair loss, vomiting, bleeding from the bladder and low white blood cell counts are common side effects. In addition, other severe side effects may also occur: Allergic reactions, infertility, pulmonary fibrosis and increased future risk of cancer. CTX is an alkylating agent from the class of nitrogen mustards. It acts through interfering with the stages of DNA duplication and transcription (4).

Of note, long-term administration of CTX results in osteoporosis (5,6). Previous studies have suggested that CTX may induce bone loss by inhibiting the differentiation of pre-osteoblasts and by reducing bone formation (7-9). Furthermore, certain studies reported that CTX increases the number of osteoclasts by altering the ratio of receptor activator for NF- κ B ligand (RANKL)/osteoprotegerin (10-12). Certain clinical studies suggested that adjuvant therapies of CTX may induce amenorrhea and an early onset of menopause, which may result in a significant loss of cortical and trabecular bone (13,14). This rapid bone loss is thought to be induced by ovarian failure (15). In most tumor patients, this form of osteoporosis has become a serious clinical problem, which may lead to bone fractures and affect the quality of life (16). This side effect exacerbates economic and psychological burdens and reduce the curative effect of chemotherapy. At present, bone-modifying agents, including bisphosphonates, are good at preventing and delaying cancer-associated bone

Correspondence to: Professor Minqi Li, Department of Bone Metabolism, School of Stomatology, Shandong University, Shandong Provincial Key Laboratory of Oral Tissue Regeneration, 44-1 Wenhua West Road, Jinan, Shandong 250012, P.R. China
 E-mail: liminqi@sdu.edu.cn

*Contributed equally

Key words: eldecalcitol, cyclophosphamide, osteoporosis, estradiol valerate

disease (17). However, during the past few years, several studies have indicated that jaw osteonecrosis is associated with bisphosphonate therapy (18).

Eldecalcitol (ED-71), a 2 β -hydroxypropyloxy derivative of 1 α ,25-dihydroxyvitamin D₃ (1 α ,25(OH)₂D₃), is an active vitamin-D analog that has been approved for osteoporosis treatment (19,20). It potently inhibited bone resorption while maintaining osteoblastic function in an estrogen-deficient and high-turnover osteoporosis rat model (21). ED-71 has demonstrated promising potential in the treatment of osteoporosis through a wide range of therapeutic mechanisms (22-24). ED-71 has been indicated to prevent post-menopausal osteoporosis by suppressing hypoxia-inducible factor 1 α protein, which accumulates in osteoclasts following estrogen deficiency due to menopause (25). Furthermore, a combination of ibandronate and ED-71 was beneficial in the treatment of osteoporosis in aged ovariectomy rats, and displayed a synergistic inhibitory effect on bone resorption and bone formation (26). In addition, a recent study also suggested that the increase of bone mass in ED-71-treated mice was mediated by suppressing bone resorption through vitamin D receptor in osteoblast-lineage cells (27). A prior study by our group also revealed that ED-71 prevented bone loss following ovariectomy in rats, mainly by suppressing the number of osteoclasts and triggering bone formation by 'mini-modeling' (28).

Most of the currently available drugs are aimed at post-menopausal osteoporosis and senile osteoporosis. Estrogen replacement, which predominantly reduces bone turnover and inhibits osteoclast activity, may prevent bone loss during menopause (29). Long-term zoledronic acid treatment has been reported to increase bone mineral density and mechanical strength of long bones in ovariectomized adult rats (30). Pharmacologic action of active vitamin D *in vivo* decreases the pool of osteoclast progenitors in the bone marrow, thereby inhibiting bone resorption in post-menopausal osteoporosis (31). However, there is currently no specific clinical treatment aimed at chemotherapy-associated osteoporosis. To identify one effective drug with the ability to restore the CTX-induced bone metabolic imbalance, a side effect of chemotherapy, the present study was designed. The ability of ED-71 to reverse CTX-induced osteoporosis was examined in a rat model. In light of the fact that chemotherapy-induced osteoporosis is mainly due to early onset of menopause and estrogen deficiency, an estrogen derivative, E2V, which has a longer pharmacological action than estrogen (32), was used as a positive control to observe a symptomatic treatment effect in the present study, instead of bisphosphonate, which is commonly used in the clinical treatment of osteoporosis.

To evaluate the treatment effect, markers of bone metabolism were detected. Bone turnover comprises two continuous processes: The removal of old bone and the formation of new bone. Serum markers, including bone-specific alkaline phosphatase (BALP), N-terminal propeptide of type I procollagen (PINP), and TRAP-5b, may accurately reflect the bone metabolic status. It may be used to predict the bone loss rate and bone fracture risk. ALP represents the osteoblast activity, while TRAP, CK and MMP9 represent the osteoclast activity. OPN regulates the formation and remodeling of mineralized tissue, and also serves as a coupling protein

for osteoclastic resorption. Furthermore, the trabecular area (Tb.Ar), total bone area (T.Ar) and trabecular perimeter (Tb.Pm) were measured. Specifically, the ratio of trabecular area (%Tb.Ar) was calculated using the formula $Tb.Ar/T.Ar \times 100\%$. Trabecular separation [Tb.Sp (μ m)] was calculated by the formula $(2,000/1.199) \times (Tb.Ar - T.Ar)/Tb.Pm$. These two parameters may be used to accurately estimate histological alterations of bone tissue. The effect of drugs on osteoporosis may also be evaluated through these histological indexes.

Materials and methods

Animal and tissue preparation. Female Wistar rats (body weight, 242-258 g; age, 12 weeks n=80) were obtained from the Animal Center of Shandong University (Jinan, China). All rats were kept in standard laboratory conditions with a 12 h dark and light cycle and a constant temperature of 20°C and humidity of 48%. Rats were fed a standard rodent diet *ad libitum*. All rats were randomly assigned to four groups, each group had 20 rats in total and 10 rats were sacrificed from each of the four groups at 2 and 4 weeks: The control groups, where rats received PBS by oral administration (p.o.) for 15 days and were only given vehicle [medium chain triglyceride (MCT), p.o.] for 2 or 4 weeks; the CTX groups, where rats received CTX (4.5 mg/kg/day, p.o.) for 15 days and were only orally given MCT for 2 or 4 weeks p.o.; the E2V groups, where rats received CTX (4.5 mg/kg/day p.o.) for 15 days and were given E2V (0.1 mg/kg/day, p.o.) (33) for 2 or 4 weeks; and the ED-71 groups, where rats received CTX (4.5 mg/kg/day, p.o.) for 15 days and were given ED-71 (25 ng/kg/day, p.o.) (34) for 2 or 4 weeks. Drugs were mixed with MCT using a vortex mixer. The oral dose of CTX for adults is 50 mg per day. The weight of an adult is about 60-70 kg. According to the formula for dose translation based on body surface area (BSA) (35), animal dose (mg/kg)=human equivalent dose (HED) (mg/kg) \times (human K_m /animal K_m). Therefore, rat dose (mg/kg)=HED (mg/kg) \times (human K_m /rat K_m)=50 mg/(60-70 kg) \times 37/6=4.4-5.1 mg/kg. So 4.5 mg/kg/day was used as an appropriate dose. After 15 days of CTX (4.5 mg/kg/day) administration, the trabecular bones of all rats had decreased by nearly 60%, while the body weight remained the same. Thus, this method fully satisfied the experimental requirements. At the end of the treatment, the rats were anesthetized with an intraperitoneal injection of 2% pentobarbital (40 mg/kg) and were fixed with 4% paraformaldehyde diluted in 0.1 M phosphate buffer (57.4 g Na₂HPO₄·12H₂O; 6.6 g Na₂H₂PO₄·2H₂O; 1,000 ml ddH₂O; pH 7.4) by transcardial perfusion. After fixation, tibiae were dissected and immersed in the same fixative for an additional 24 h. Subsequently, samples were demineralized with 10% EDTA 2 Na solution (100 g EDTA; 10 g NaOH; 1,000 ml ddH₂O, pH 7.4) for one month at 4°C. The specimens were then dehydrated through an ascending ethanol series and embedded in paraffin using standard procedures. Serial longitudinal 5- μ m sections were prepared for subsequent histological analysis.

Serum biochemical analysis. Blood samples were collected prior to sacrifice of the rats. Specifically, the rats were anesthetized with an intraperitoneal injection of 2% pentobarbital (40 mg/kg) at the end of the drug treatment. Blood

samples were collected from the left ventricle (1 ml blood was extracted from each rat). Subsequently, the rats were fixed as specified above. Serum samples were separated by centrifugation at 2,500 x g for 10 min at 4°C and stored at -80°C. Serum markers for bone metabolism, including BALP, PINP and TRAP-5b, were detected by using ELISA kit (cat. no. F4717, F5731 and F16977; Westang Biological Technology Co., Ltd.) according to the protocols provided by the manufacturers.

Histological examination. Hematoxylin and eosin staining was performed to evaluate histological alterations. After dewaxing and rehydration, the prepared sections were immersed in hematoxylin for 15 min and washed with distilled water. Subsequently, the sections were differentiated in 1% HCl in 70% ethanol for 1 min and washed again for 2 min. Subsequently, the sections were stained with 1% eosin for 10 min and were washed again. Finally, the stained sections were observed and digital images were captured with a light microscope (BX-53; Olympus Corp.).

Immunohistochemical analysis of CK, MMP9 and OPN, and double staining for ALP and TRAP. After xylene treatment, dewaxed paraffin sections were pretreated for endogenous peroxidase inhibition with 0.3% hydrogen peroxide in PBS for 30 min and blocking of non-specific staining with 1% bovine serum albumin (BSA; Seologicals Proteins Inc.) in PBS (1% BSA-PBS) for 20 min at room temperature. The treated sections were immersed in the respective primary antibodies, rabbit anti-ALP (1:150; cat. no. ab194297; Abcam), rabbit anti-CK (1:200; cat. no. ab19027; Abcam), goat anti-MMP9 (1:100; cat. no. AF909; R&D Systems, Inc.) and rabbit anti-OPN (1:300; cat. no. ab8448; Abcam), with 1% BSA-PBS for 2 h at room temperature. After rinsing with PBS, samples were incubated with horseradish peroxidase-conjugated swine anti-rabbit IgG for ALP, CK and OPN (cat. no. P0399; Dako Cytomation) and rabbit anti-goat IgG for MMP9 (cat. no. 93894; Jackson ImmunoResearch Laboratories, Inc.) at a dilution of 1:100 for 1 h at room temperature. The immunoreaction was visualized using diaminobenzidine (Sigma-Aldrich; Merck KGaA). After immunostaining, TRAP staining was performed on the sections treated with ALP antibody as previously described (36). In brief, dewaxed paraffin sections were submerged in a mixture of 3.0 mg naphthol AS-BI phosphate, 18 mg red violet LB salt and 100 mM L(+) tartaric acid (0.36 g) diluted in 30 ml 0.1 M sodium acetate buffer (pH 5.0) for 15 min at 37°C. All sections were faintly counterstained with methyl green and observed under a light microscope (BX53; Olympus Corp.). Specimens were scored on the basis of the number of positive cells and the intensity of the dye color as previously described (37). The percentage of positive cells was graded as 0 (<5%), 1 (5-25%), 2 (25-50%), 3 (51-75%) or 4 (>75%) and the intensity of the staining was graded as 0 (no color), 1 (light yellow), 2 (light brown) or 3 (brown). The two grades were added together and the specimens were assigned to one of the 4 levels: Score 0-1 (negative), score 1-2 (weak), scores 3-4 (moderate) and score >5 (intense). The positive expression rate for each group was expressed as the percentage of samples with weak, moderate and intense staining among all samples (37).

Image measurement and statistical analysis. Image Pro Plus 6.2 software (Media Cybernetics Inc.) was applied for determining the Tb.Ar, T.Ar and Tb.Pm of H&E staining images. The %Tb.Ar was calculated using the formula $Tb.Ar/T.Ar \times 100\%$. Tb.Sp was calculated using the formula $(2,000/1.199) \times (Tb.Ar - T.Ar)/Tb.Pm$. The mean optical density of the images was determined using light microscopy (x400, magnification) and Image Pro Plus 6.2 software. Positive staining areas of ALP, CK, MMP9 and OPN were manually selected in a color cube-based manner. At least 10 sections from each sample were analyzed. All values are expressed as the mean \pm standard deviation. All data were subjected to the normality test. For data groups that conformed to the normal distribution, one-way analysis of variance was performed to assess the differences among multiple groups. Subsequently, Tukey's test was used for post-hoc pairwise comparisons. For data groups that did not conform to the normal distribution, the Kruskal-Wallis test was performed, followed by Dunn's test as a post-hoc. $P < 0.05$ was considered to indicate statistical significance.

Results

ED-71 restores serum markers of bone resorption and bone formation after osteoporosis induction with CTX. As indicated in Fig. 1, CTX markedly increased the levels of serum markers of bone resorption and bone formation, namely TRAP-5b, BALP and PINP. However, the E2V and ED-71 groups displayed a clear suppressive effect on all the bone serum markers in comparison with the CTX groups. E2V had an intense inhibitory effect and ED-71 had a lower suppressive effect compared with that of E2V. This suppressive effect reflected a normalization of bone resorption and bone formation. Of note, the levels of TRAP-5b, BALP and PINP in the ED-71 group were significantly higher than those in the E2V group, and they were closest to those in the control group. Compared with the observations at 2 weeks, this effect was similar when the treatment was extended for an additional 2 weeks. Of note, the body weight exhibited no significant differences among all groups over the entire treatment period. This means that the body weight was not influenced by E2V or ED-71 in combination with CTX.

Histological alterations after 2 and 4 weeks of administration of E2V or ED-71. After 2 weeks of anti-osteoporotic drug administration, the E2V and ED-71 groups displayed a marked improvement in histological properties compared with those in the CTX group, including increased trabecular bone number, thicker metaphyseal trabeculae and reduced Tb.Sp. The ED-71 group exhibited denser and more mature trabecular bone than the E2V group, which was similar to that in the control group. When the treatment was extended for a further 2 weeks, E2V and ED-71 successfully rescued bone loss relative to that in the CTX group (Fig. 2). %Tb.Ar and Tb.Sp in the ED-71 group exhibited a significant increase in %Tb.Ar and a significant decrease in Tb.Sp when compared with the CTX group and the E2V group. However, no significant differences were exhibited between the ED-71 group and the control group (Fig. 2I and J).

Table I. ED-71 had a better biological effect than E2V.

Group	%Tb.Ar	MOD of ALP	TRAP + No. OC	MOD of CK	MOD of MMP9	MOD of OPN	Bone turnover
Control	++	-	-	-	-	-	-
E2V	+	--	--	--	--	--	--
ED-71	++	-	-	-	-	-	-

+, higher than CTX; ++, much higher than CTX; -, lower than CTX; --, much lower than CTX. CTX, cyclophosphamide; ED-71, eldecalcitol; E2V, estradiol valerate; CK, cathepsin K; TRAP, tartrate-resistant acid phosphatase; %Tb.Ar, trabecular area ratio; ALP, alkaline phosphatase; OPN, osteopontin; MMP, matrix metalloproteinase; MOD, mean optical density; No. OC, number of osteoclasts.

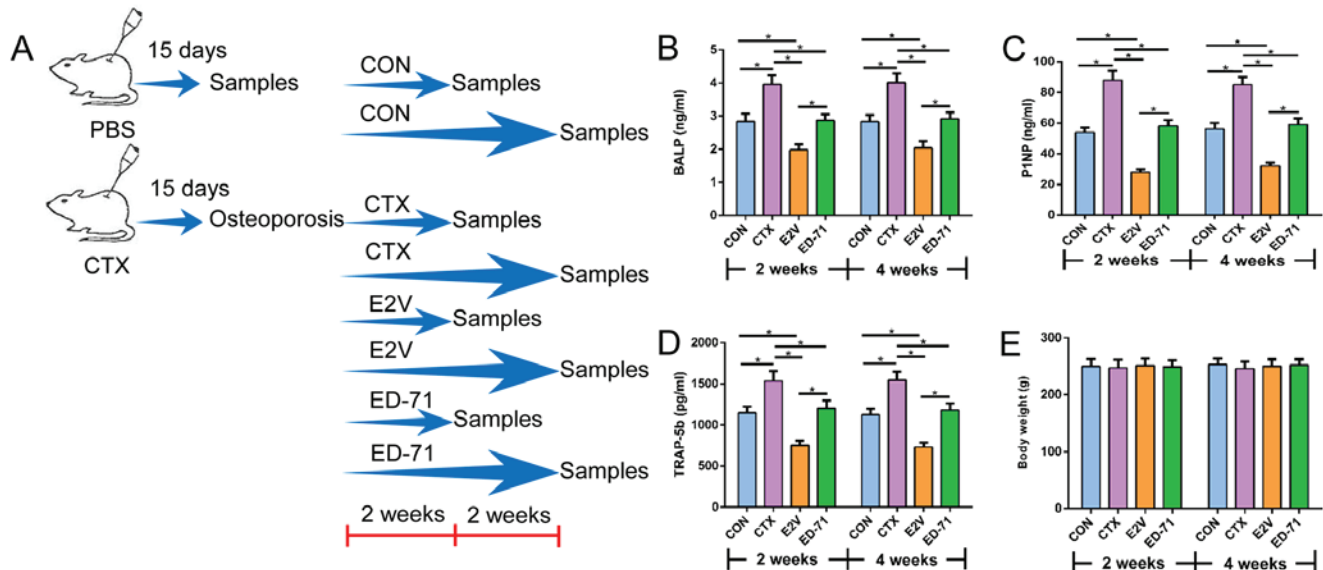


Figure 1. Serum bone turnover markers after ED-71 administration. (A) Illustration of treatment schedules for each group. (A-D) Effect of E2V and ED-71 on serum bone turnover markers. The levels of (B) BALP, (C) PINP, (D) TRAP-5b were assessed for the groups at different time-points. After ED-71 treatment, bone formation and bone resorption turnover markers were decreased compared with BALP, PINP and TRAP-5b in the CTX group. (E) Body weight during the treatment period. Values are expressed as the mean \pm standard deviation (n=10). *P<0.05. BALP, bone-specific alkaline phosphatase; PINP, N-terminal propeptide of type I procollagen; TRAP-5b, tartrate-resistant acid phosphatase 5b; CTX, cyclophosphamide; ED-71, eldecalcitol; E2V, estradiol valerate; CON, control.

TRAP staining and immunohistochemistry after 2 and 4 weeks of E2V or ED-71 administration. As expected, administration of either anti-osteoporosis agent for 2 weeks considerably decreased the number of TRAP-positive osteoclasts (Fig. 3) as well as the immunoreactivity for CK (Fig. 4) and MMP9 (Fig. 5) compared with those in the CTX group. E2V appeared to exert a greater inhibitory effect on osteoclasts than ED-71, as indicated by less TRAP-positive osteoclasts and lower intensity of immunostaining for CK and MMP9. However, ED-71 appeared to have a greater potency to maintain osteoblast function than E2V, as it suppressed the immunoreactivity of ALP (Fig. 3) and OPN (Fig. 6), representing osteoblast formation and osteoclast resorption, only to approximate those in the control group and not beyond. After extending the treatment with E2V or ED-71 for a further 2 weeks, the immunoreactivity remained relatively constant in terms of osteoclast and osteoblast suppression. Several significant differences were identified among the groups with regard to values after 2 and 4 weeks. Specifically, TRAP-, CK- and MMP9-positive osteoclasts from the ED-71 group presented significant differences to the CTX group

and the E2V group. However, no significant differences were exhibited between the ED-71 group and the control group. The mean optical density of staining for ALP, CK, MMP9 and OPN from the ED-71 group presented significant differences compared with the CTX and the E2V group. However, no significant differences were exhibited between the ED-71 group and the control group (Figs. 3I and J; 4I and J; 5I and J and 6I). Therefore, ED-71 exhibited a decreased inhibitory effect on bone formation and bone resorption, with increased bone turnover when compared with the E2V group (Table I). ED-71 indicated a relative higher expression of ALP, TRAP, CK, MMP9 and OPN than expression in the E2V group. These therapeutic indexes in the ED-71 group were close to the control group. The result of histological index %Tb.Ar from the ED-71 group revealed a higher value compared with the E2V group.

Discussion

CTX, as an alkylating agent, is used in a range of tumors and allergic diseases. High-dose and/or long-term application may

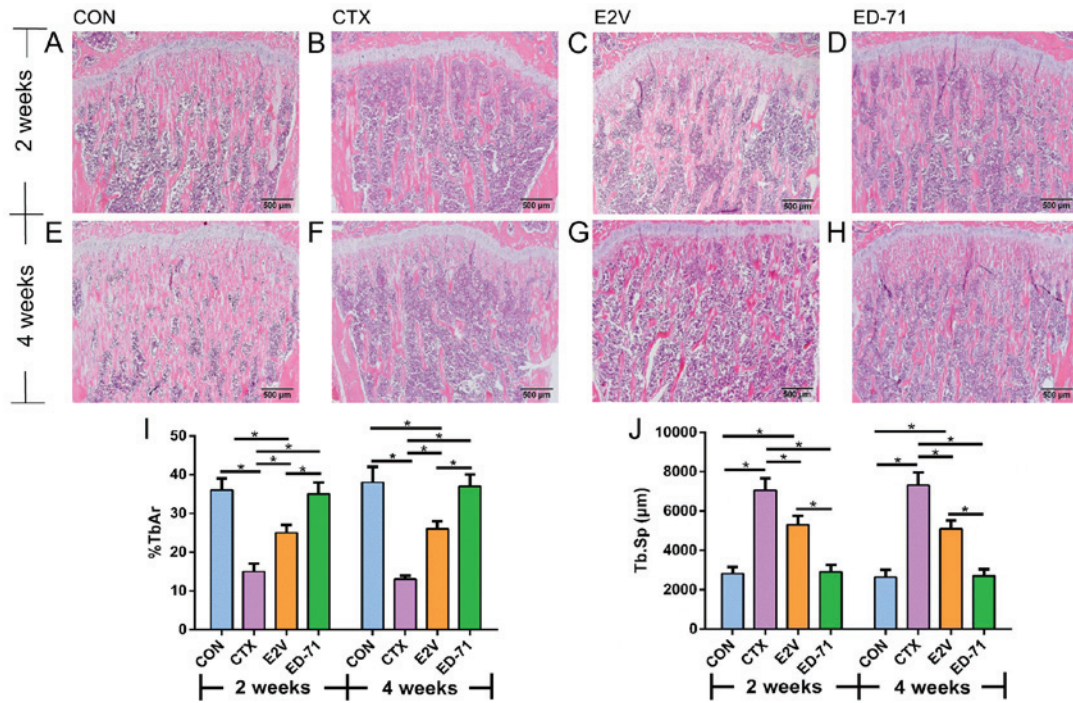


Figure 2. Histological analysis revealed that ED-71 administration increased the trabecular bone volume. (A-H) Hematoxylin-eosin staining of proximal tibiae metaphysis indicated differences between the two drugs. (A-D) 2 weeks; (E-H) 4 weeks (magnification, x40; scale bar, 500 µm). (D and H) At 2 and 4 weeks after ED-71 administration, tibiae exhibited an obvious histological manifestation of increased trabecular bone volume compared with (C and G) the group with E2V administration. (I and J) The mean values of (I) %Tb.Ar and (J) Tb.Sp (µm) were compared between the groups. The trabecular bone volume was increased after ED-71 treatment. Values are expressed as the mean ± standard deviation (n=10). *P<0.05. CTX, cyclophosphamide; ED-71, eldcalcitol; E2V, estradiol valerate; CON, control; %Tb.Ar, trabecular area ratio; Tb.Sp, trabecular separation.

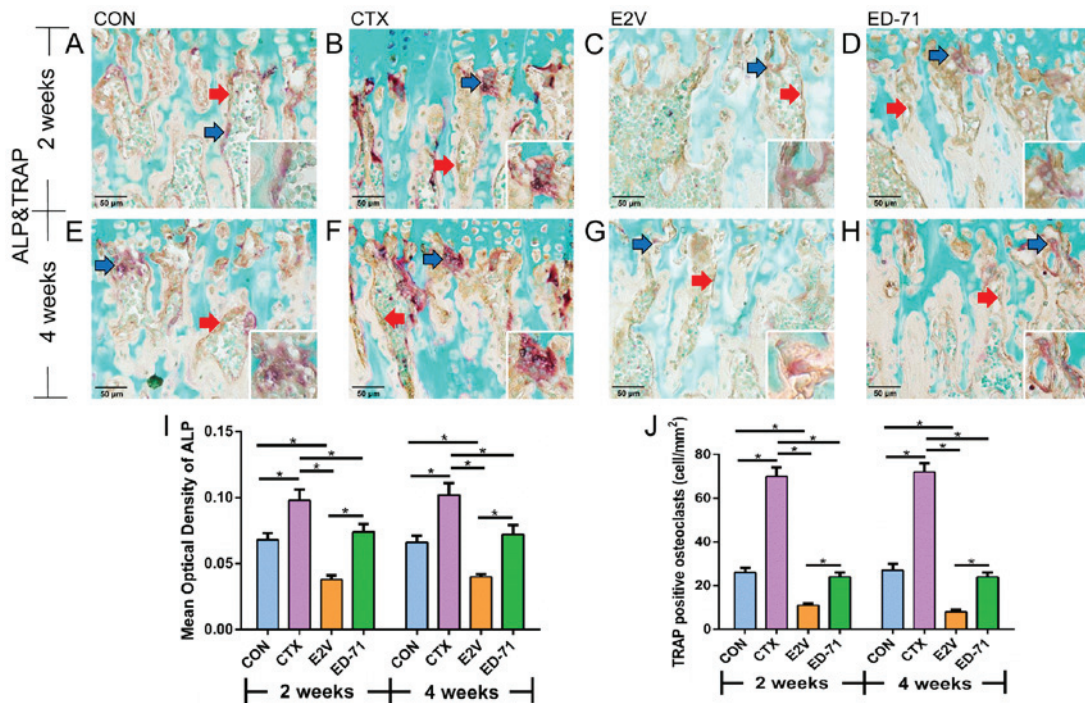


Figure 3. Double staining for ALP and TRAP revealed that ED-71 administration slightly decreased the number of TRAP-positive cells and the areas of ALP-positive cells on the surface of trabecular bone to the control level. (A-D) 2 weeks; (E-H) 4 weeks. ALP-positive cells (brown color) and TRAP-positive cells (purple color) were observed on the surface of trabecular bone (magnification, x400; scale bar, 50 µm). Compared to (C and G) the E2V groups, denser expression of ALP was observed in (D and H) the ED-71 groups, but it was lower than that in (B and F) the CTX groups. (D and H) The ED-71 groups exhibited a slight osteoclast suppression effect compared to (C and G) the E2V groups. The magnified windows display typical TRAP-positive cells (magnification, x1000). Red arrows indicate ALP-positive cells and blue arrows indicate TRAP-positive cells. (I and J) Mean optical density of (I) ALP and (J) TRAP immunoreactivity. ALP-positive osteoblasts and TRAP-positive osteoclasts were slightly decreased to the control level after ED-71 treatment. All corresponding numerical information is provided in Table II. Values are expressed as the mean ± standard deviation (n=10). *P<0.05. CTX, cyclophosphamide; ED-71, eldcalcitol; E2V, estradiol valerate; TRAP, tartrate-resistant acid phosphatase; ALP, alkaline phosphatase.

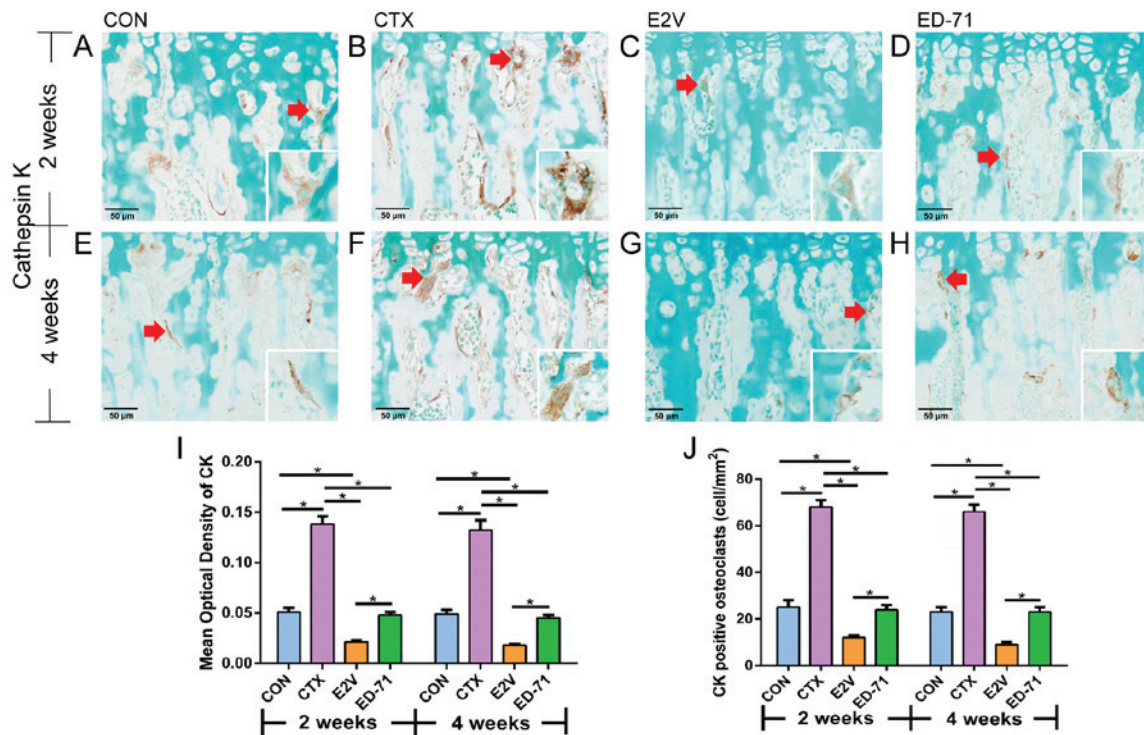


Figure 4. Immunohistochemical detection of CK revealed that ED-71 administration slightly suppressed CK expression. (A-D) 2 weeks; (E-H) 4 weeks. CK-positive cells (brown color) were expressed on the surface of trabecular bone (magnification, x400; scale bar, 50 μ m). (D and H) The ED-71 groups exhibited slight osteoclast suppression compared to (C and G) the E2V groups. Red arrows indicate CK-positive cells and the magnified windows display typical CK-positive cells (magnification, x1000). (I) Mean optical density of CK immunoreactivity. (J) Number of CK-positive osteoclasts in the different groups. CK-positive osteoclasts were decreased after ED-71 treatment. All corresponding numerical information is provided in Table II. Values are expressed as the mean \pm standard deviation (n=10). *P<0.05. CTX, cyclophosphamide; ED-71, eldecalcitol; E2V, estradiol valerate; CON, control; CK, cathepsin K.

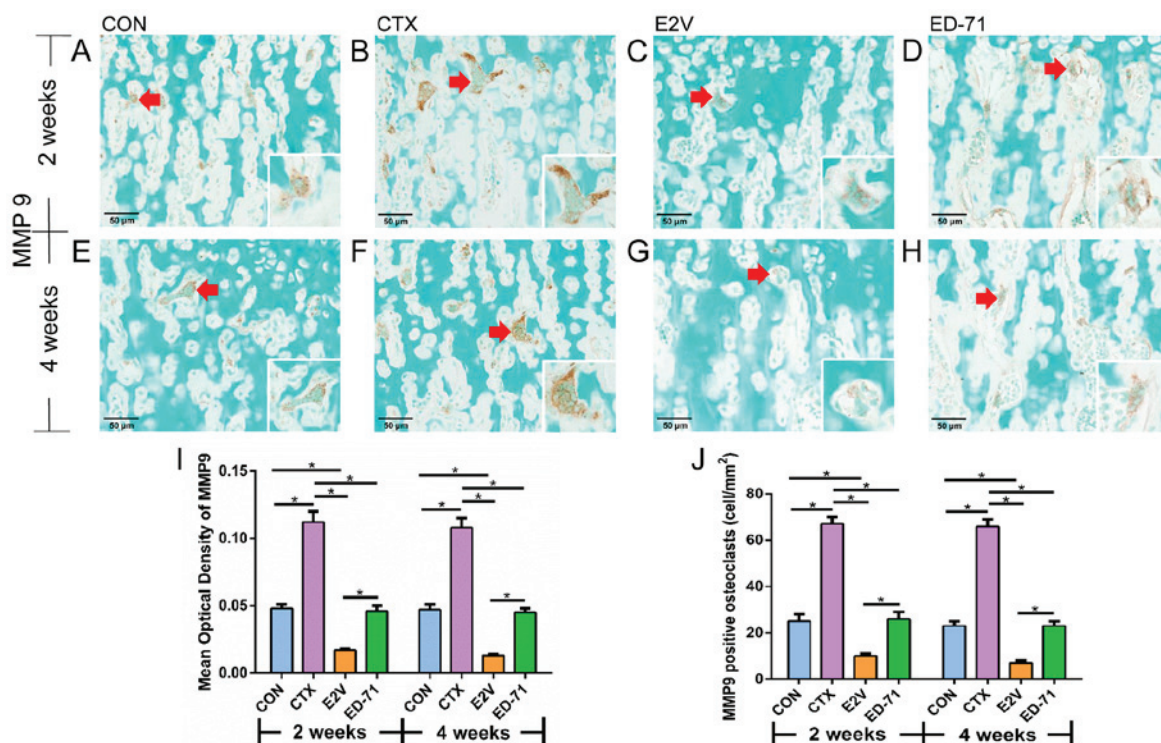


Figure 5. Immunohistochemical detection MMP9 revealed that ED-71 administration slightly suppressed the MMP9 expression. (A-D) 2 weeks; (E-H) 4 weeks. MMP9-positive cells (brown color) were observed on the surface of trabecular bone (magnification, x400; scale bar, 50 μ m). (D and H) The ED-71 groups exhibited slight osteoclasts suppression compared to (C and G) the E2V groups. Red arrows indicate MMP9-positive cells and the magnified windows display typical MMP9-positive cells (magnification, x1000). (I) Mean optical density of MMP9 immunoreactivity. (J) Number of MMP9-positive osteoclasts in the different groups. MMP9-positive osteoclasts were decreased after ED-71 treatment. Values are expressed as the mean \pm standard deviation (n=10). *P<0.05. CTX, cyclophosphamide; ED-71, eldecalcitol; E2V, estradiol valerate; CON, control; MMP, matrix metalloproteinase.

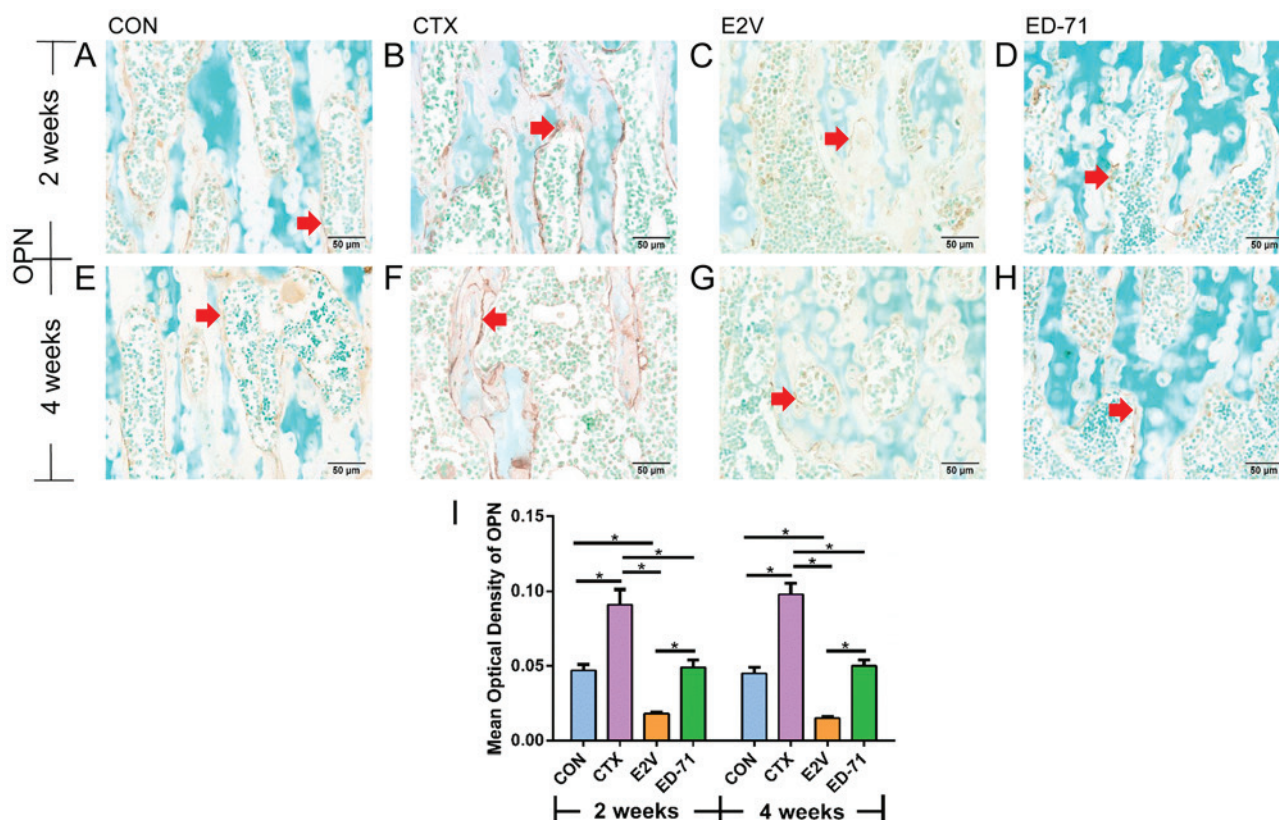


Figure 6. Immunohistochemical detection of OPN revealed that ED-71 administration slightly suppressed the OPN expression to the control level. (A-D) 2 weeks; (E-H) 4 weeks. MMP9-positive cells (brown color) were observed on the surface of trabecular bone (magnification, x400; scale bar, 50 μ m). (C and G) Compared to the E2V groups, denser expression of OPN was observed in (D and H) the ED-71 groups, but was lower than that in (B and F) the CTX groups. Red arrows indicate OPN-positive cells. (I) Mean optical density of OPN immunoreactivity. OPN-positive areas were slightly suppressed after ED-71 treatment. Values are expressed as the mean \pm standard deviation (n=10). *P<0.05. CTX, cyclophosphamide; ED-71, eldelcalcitol; E2V, estradiol valerate; CON, control; OPN, osteopontin.

induce rapid bone loss and increase the risk of osteoporotic fractures. CTX may cause amenorrhea and early onset of menopause (13,14). Therefore, the major reason of CTX-induced osteoporosis is closely linked to ovarian failure (15). Under the conditions of ovarian failure, the balance of bone resorption and bone formation is broken by estrogen deficiency, and osteoporosis may occur as bone resorption predominates. In the present study, the treatment effects of E2V and ED-71 in CTX-induced osteoporosis were investigated. After CTX administration, tibiae displayed clear features of osteoporosis, including shortened metaphyseal trabeculae, increased trabecular separation and reduced number of bone trabeculae. Furthermore, immunohistochemistry indicated that CTX significantly promoted bone resorption by increasing the number and activity of osteoclasts on the trabecular bone surface, and subsequently promoted bone formation by increasing the number and the activity of osteoblasts. The present results are in agreement with those of previous studies indicating that CTX induced a significant decrease in the percentage of hard tissue (9,10,38,39). Furthermore, CTX has been reported to increase the number of osteoclasts to increase bone resorption (10-12).

As an estrogen derivative with a longer pharmacological action than estrogen (32), E2V exhibited a significant effect to prevent bone loss, mainly through markedly suppressing osteoclastic bone resorption, which was indicated by the

low expression of TRAP, CK and MMP9. Furthermore, the expression of ALP and OPN was also significantly inhibited. Therefore, the E2V group displayed an increased number of bone trabeculae, thicker metaphyseal trabeculae and reduced Tb.Sp in comparison with those in the CTX group. A previous study by Tsangari *et al* (40) suggested that reduced bone-formation surface relative to bone-resorption surface is potentially important for the production of bone in the proximal femur and associated with increased fracture risk. Therefore, the improved bone quantity following E2V administration may, in fact, be of poorer quality.

In recent years, ED-71 has become widely recognized in the field of osteoporosis treatment as an active vitamin D analog. Tsurukami *et al* (41) reported that ED-71 not only inhibited bone resorption but also increased parameters of bone formation, including osteoid surface and mineral apposition rate in animal tests, as demonstrated by histomorphometry. In addition, a previous study by our group suggested that ED-71 induced 'mini-modeling' bone formation and led to reduced osteoclast numbers and bone resorption by stimulating preosteoblastic differentiation, rather than their proliferation, which in turn may prevent or diminish cell-to-cell contact between preosteoblasts and osteoclastic precursors (28). In the present study, administration of ED-71 led to a significant suppression of TRAP, CK, MMP9, ALP and OPN, which was less

pronounced than that resulting from E2V administration but closer to the values in the normal control group. These results suggest that, as a milder bone turnover inhibitor than E2V, ED-71 had superior bone formation maintenance ability. Bone turnover comprises two continuous processes: The removal of old bone and the formation of new bone. ALP represents osteoblast activity, while TRAP, CK and MMP9 represent osteoclast activity. OPN regulates the formation and remodeling of mineralized tissue, and also serves as a coupling protein for osteoclastic resorption. CTX may cause high-turnover osteoporosis due to estrogen deficiency induced by ovarian failure. E2V and ED-71 may prevent this bone loss through decreasing the bone turnover rate. As a positive control, E2V treatment led to an increased therapeutic index in comparison with that in the CTX group. However, E2V displayed relative stronger inhibitory effects on both bone formation and bone resorption than ED-71 and thus had a low bone turnover. By contrast, ED-71 had better therapeutic indexes than E2V and maintained the bone mass at the same value as that in the control group, such as the expression level of ALP, TRAP, CK, MMP9, OPN and histological index %Tb.Ar. ED-71 exhibited less inhibitory effects on bone formation and bone resorption with a relatively higher bone turnover compared with those produced by E2V. The balance between the osteoblast and osteoclast numbers, and their activities, determines the quality and quantity of bone (42). Consequently, the combined effect of ED-71 on these two cell types was reflected in the similar quality and quantity of trabecular bone compared with those in the control group after 2 or 4 weeks of treatment.

The present results were in accordance with those of previous studies. Estrogen and ED-71 were reported to exert inhibitory effects on osteoclasts *in vitro*. Śliwiński (43) demonstrated that estradiol inhibits osteoclast formation from mouse bone marrow cells. Furthermore, ED-71 had the same suppressive effects on osteoclasts but was significantly less effective than traditional anti-osteoporosis drugs *in vitro*. ED-71 was able to inhibit M-CSF and RANKL-stimulated osteoclastogenesis *in vitro* and downregulated TRAP, CK, nuclear factor of activated T cells 1 and dendritic cell-specific transmembrane protein mRNA in osteoclasts, but with lower efficiency than $1\alpha,25(\text{OH})_2\text{D}_3$ (25). In summary, ED-71 has a milder inhibitory effect on osteoclasts *in vitro* than that of E2V.

In this study, the results for each parameter at 2 and 4 weeks are virtually identical. That means both E2V and ED-71 seem to produce beneficial effects in short-term treatment. Meanwhile, we don't know the duration of drug administration in human with CTX induced bone loss. We considered that both the high metabolic level in rats and the CTX administration time may influence these results. But we don't think short-term treatment (2 weeks) is sufficient. There is no evidence to prove that the side effects of CTX administration have disappeared. All of them depend on further study.

It is well known that the side effects of high-dose administration of vitamin D analogues are hypercalcemia and hyperphosphatemia. In the present study, ED-71 was applied at the dose of 25 ng/kg/day. Sato *et al* (34) reported that this dose (25 ng/kg/day) of ED-71, which is close to a limit, but in a safety margin of an improved therapeutic

window, was able to correct osteoporosis without causing any hypercalcemia and hyperphosphatemia. Vitamin D analogue-induced bone formation activity was better to prove at hypercalcemic doses (44,45). Therefore, the maximum tolerated dose of ED-71 (25 ng/kg/day) can achieve the highest biological effect and was selected for use in the present study.

At present, most available drugs are aimed at postmenopausal osteoporosis and senile osteoporosis. There is currently no specific clinical treatment aimed at chemotherapy-induced osteoporosis. As a basis for future clinical application, the present study proved that ED-71 has high efficiency in reversing CTX-induced osteoporosis.

In conclusion, the results of the present study suggest that oral administration of ED-71 at a dose of 25 ng/kg/day for 2 or 4 weeks successfully rescued bone loss to reach normal levels close to those of the control group. In comparison with the potent drug E2V (0.1 mg/kg/day), ED-71 was more efficient at normalizing bone mass and bone metabolism. Therefore, ED-71 is a potential treatment option for CTX-induced osteoporosis.

Acknowledgements

Not applicable.

Funding

The present study was partially supported by the National Natural Science Foundation of China (grant no. 81470719 and 81611140133 to LM, grant no. 81771108 to GJ), The Construction Engineering Special Fund of 'Taishan Scholars' (grant no. Ts20151106 to XX) and the Shandong Provincial Natural Science Foundation (BS2015SW001 to LX).

Availability of data and materials

The datasets used and/or analyzed during the present study are available from the corresponding author on reasonable request.

Authors' contributions

WW designed this study and drafted the manuscript. WW and GY contributed to the experimental work, data acquisition and analysis. FW and LH assisted with the construction of the animal model. LX assisted with the data analysis. LM and GJ contributed to conception and critically revised the manuscript. All authors reviewed and gave final approval.

Ethics approval and consent to participate

All animal experiments of the present study were performed according to the Guidelines for Animal Experimentation of Shandong University and approved by the Ethics Committee of the School of Stomatology, Shandong University (Jinan, China; ethics approval no. GD201827).

Patient consent for publication

Not applicable.

Competing interests

The authors declare that they have no competing interests.

References

1. Drugs of choice for cancer. *Treat Guidel Med Lett* 1: 41-52, 2003.
2. Swenerton K, Jeffrey J, Stuart G, Roy M, Krepart G, Carmichael J, Drouin P, Stanimir R, O'Connell G and MacLean G: Cisplatin-cyclophosphamide versus carboplatin-cyclophosphamide in advanced ovarian cancer: A randomized phase III study of the National Cancer Institute of Canada Clinical Trials Group. *J Clin Oncol* 10: 718-726, 1992.
3. Bonadonna G, Valagussa P, Moliterni A, Zambetti M and Brambilla C: Adjuvant cyclophosphamide, methotrexate and fluorouracil in node-positive breast cancer: The results of 20 years of follow-up. *N Engl J Med* 332: 901-906, 1995.
4. The American Society of Health-System Pharmacists: Cyclophosphamide. <https://www.drugs.com/monograph/cyclophosphamide.html>. Accessed 8 May, 2018.
5. Bines J, Oleske DM and Cobleigh MA: Ovarian function in premenopausal women treated with adjuvant chemotherapy for breast cancer. *J Clin Oncol* 14: 1718-1729, 1996.
6. Saarto T, Blomqvist C, Välimäki M, Mäkelä P, Sarna S and Elomaa I: Chemical castration induced by adjuvant cyclophosphamide, methotrexate, and fluorouracil chemotherapy causes rapid bone loss that is reduced by clodronate: A randomized study in premenopausal breast cancer patients. *J Clin Oncol* 15: 1341-1347, 1997.
7. Mattison DR, Chang L, Thorgeirsson SS and Shiromizu K: The effects of cyclophosphamide, azathioprine, and 6-mercaptopurine on oocyte and follicle number in C57BL/6N mice. *Res Commun Chem Pathol Pharmacol* 31: 155-161, 1981.
8. Plowchalk DR and Mattison DR: Reproductive toxicity of cyclophosphamide in the C57BL/6N mouse: 1. Effects on ovarian structure and function. *Reprod Toxicol* 6: 411-421, 1992.
9. Wang TM and Shih C: Study of histomorphometric changes of the mandibular condyles in neonatal and juvenile rats after administration of cyclophosphamide. *Acta Anat (Basel)* 127: 93-99, 1986.
10. Fan C, Georgiou KR, McKinnon RA, Keefe DM, Howe PR and Xian CJ: Combination chemotherapy with cyclophosphamide, epirubicin and 5-fluorouracil causes trabecular bone loss, bone marrow cell depletion and marrow adiposity in female rats. *J Bone Miner Metab* 34: 277-290, 2016.
11. Georgiou KR, Hui SK and Xian CJ: Regulatory pathways associated with bone loss and bone marrow adiposity caused by aging, chemotherapy, glucocorticoid therapy and radiotherapy. *Am J Stem Cells* 1: 205-224, 2012.
12. Oostra DR, Lustberg MB, Reinbolt RE, Pan X, Wesolowski R and Shapiro CL: Association of osteoprotegerin and bone loss after adjuvant chemotherapy in early-stage breast cancer. *Mol Cell Endocrinol* 402: 51-56, 2015.
13. Jonat W, Kaufmann M, Sauerbrei W, Blamey R, Cuzick J, Namer M, Fogelman I, de Haes JC, de Matteis A, Stewart A, *et al*: Goserelin versus cyclophosphamide, methotrexate and fluorouracil as adjuvant therapy in premenopausal patients with node-positive breast cancer: The Zoladex Early Breast Cancer Research Association Study. *J Clin Oncol* 20: 4628-4635, 2002.
14. Shapiro CL and Recht A: Side effects of adjuvant treatment of breast cancer. *N Engl J Med* 344: 1997-2008, 2001.
15. Shapiro CL, Manola J and Leboff M: Ovarian failure after adjuvant chemotherapy is associated with rapid bone loss in women with early-stage breast cancer. *J Clin Oncol* 19: 3306-3311, 2001.
16. Vehmanen L, Saarto T, Elomaa I, Mäkelä P, Välimäki M and Blomqvist C: Long-term impact of chemotherapy-induced ovarian failure on bone mineral density (BMD) in premenopausal breast cancer patients. The effect of adjuvant clodronate treatment. *Eur J Cancer* 37: 2373-2378, 2001.
17. Rizzoli R, Body JJ, Brandi ML, Cannata-Andia J, Chappard D, El Maghraoui A, Glüer CC, Kendler D, Napoli N, Papaioannou A, *et al*: Cancer-associated bone disease. *Osteoporos Int* 24: 2929-2953, 2013.
18. Atanes-Bonome P, Atanes-Bonome A, Rios-Lage P and Atanes-Sandoval AD: Bisphosphonate-related osteonecrosis of the jaw. *Semergen* 40: 143-148, 2014 (In Spanish).
19. Hatakeyama S, Yoshino M, Eto K, Takahashi K, Ishihara J, Ono Y, Saito H and Kubodera N: Synthesis and preliminary biological evaluation of 20-epi-eldecalcitol [20-epi-1 α ,25-dihydroxy-2 β - (3-hydroxypropoxy)vitamin D₃: 20-epi-ED-71]. *J Steroid Biochem Mol Biol* 121: 25-28, 2010.
20. Saito H, Takeda S and Amizuka N: Eldecalcitol and calcitriol stimulates 'bone minimodeling,' focal bone formation without prior bone resorption, in rat trabecular bone. *J Steroid Biochem Mol Biol* 136: 178-182, 2013.
21. Sakai S, Endo K, Takeda S, Mihara M and Shiraishi A: Combination therapy with eldecalcitol and alendronate has therapeutic advantages over monotherapy by improving bone strength. *Bone* 50: 1054-1063, 2012.
22. Harada S, Mizoguchi T, Kobayashi Y, Nakamichi Y, Takeda S, Sakai S, Takahashi F, Saito H, Yasuda H, Udagawa N, *et al*: Daily administration of eldecalcitol (ED-71), an active vitamin D analog, increases bone mineral density by suppressing RANKL expression in mouse trabecular bone. *J Bone Miner Res* 27: 461-473, 2012.
23. Harada S, Takeda S, Uno A, Takahashi F and Saito H: Eldecalcitol is less effective in suppressing parathyroid hormone compared to calcitriol in vivo. *J Steroid Biochem Mol Biol* 121: 281-283, 2010.
24. Hatakeyama S, Nagashima S, Imai N, Takahashi K, Ishihara J, Sugita A, Nihei T, Saito H, Takahashi F and Kubodera N: Synthesis and biological evaluation of a 3-position epimer of 1 α ,25-dihydroxy-2 β -(3-hydroxypropoxy)vitamin D₃ (ED-71). *J Steroid Biochem Mol Biol* 103: 222-226, 2007.
25. Sato Y, Miyauchi Y, Yoshida S, Morita M, Kobayashi T, Kanagawa H, Katsuyama E, Fujie A, Hao W, Tando T, *et al*: The vitamin D analogue ED71 but Not 1,25(OH)₂D₃ targets HIF1 α protein in osteoclasts. *PLoS One* 9: e111845, 2014.
26. Sakai S, Takeda S, Sugimoto M, Shimizu M, Shimonaka Y, Yogo K, Hashimoto J, Bauss F and Endo K: Treatment with the combination of ibandronate plus eldecalcitol has a synergistic effect on inhibition of bone resorption without suppressing bone formation in ovariectomized rats. *Bone* 81: 449-458, 2015.
27. Nakamichi Y, Udagawa N, Horibe K, Mizoguchi T, Yamamoto Y, Nakamura T, Hosoya A, Kato S, Suda T and Takahashi N: VDR in osteoblast-lineage cells primarily mediates vitamin D treatment-induced increase in bone mass by suppressing bone resorption. *J Bone Miner Res* 32: 1297-1308, 2017.
28. de Freitas PH, Hasegawa T, Takeda S, Sasaki M, Tabata C, Oda K, Li M, Saito H and Amizuka N: Eldecalcitol, a second-generation vitamin D analog, drives bone minimodeling and reduces osteoclastic number in trabecular bone of ovariectomized rats. *Bone* 49: 335-342, 2011.
29. Ettinger B, Genant HK and Cann CE: Long-term estrogen replacement therapy prevents bone loss and fractures. *Ann Intern Med* 102: 319-324, 1985.
30. Hornby SB, Evans GP, Hornby SL, Pataki A, Glatt M and Green JR: Long-term zoledronic acid treatment increases bone structure and mechanical strength of long bones of ovariectomized adult rats. *Calcif Tissue Int* 72: 519-527, 2003.
31. Shibata T, Shira-Ishi A, Sato T, Masaki T, Masuda A, Hishiya A, Ishikura N, Higashi S, Uchida Y, Saito MO, *et al*: Vitamin D hormone inhibits osteoclastogenesis in vivo by decreasing the pool of osteoclast precursors in bone marrow. *J Bone Miner Res* 17: 622-629, 2002.
32. Xia W, Meng X and Xing X: Effects of estradiol valerate on osteoporosis in ovariectomized rats. *Zhonghua Fu Chan Ke Za Zhi* 36: 606-609, 2001 (In Chinese).
33. Zhang Z, Song C, Fu X, Liu M, Li Y, Pan J, Liu H, Wang S, Xiang L, Xiao GG and Ju D: High-dose diosgenin reduces bone loss in ovariectomized rats via attenuation of the RANKL/OPG ratio. *Int J Mol Sci* 15: 17130-17147, 2014.
34. Sato M, Lu J, Iturria S, Stayrook KR, Burris LL, Zeng QQ, Schmidt A, Barr RJ, Montrose-Rafizadeh C, Bryant HU and Ma YL: A nonsecosteroidal vitamin D receptor ligand with improved therapeutic window of bone efficacy over hypercalcemia. *J Bone Miner Res* 25: 1326-1336, 2010.
35. Reagan-Shaw S, Nihal M and Ahmad N: Dose translation from animal to human studies revisited. *FASEB J* 22: 659-661, 2008.
36. Li M, Hasegawa T, Hogo H, Tatsumi S, Liu Z, Guo Y, Sasaki M, Tabata C, Yamamoto T, Ikeda K and Amizuka N: Histological examination on osteoblastic activities in the alveolar bone of transgenic mice with induced ablation of osteocytes. *Histol Histopathol* 28: 327-335, 2013.
37. Ma Y, Ma L, Guo Q and Zhang S: Expression of bone morphogenetic protein-2 and its receptors in epithelial ovarian cancer and their influence on the prognosis of ovarian cancer patients. *J Exp Clin Cancer Res* 29: 85, 2010.

38. Hadji P, Ziller M, Maskow C, Albert U and Kalder M: The influence of chemotherapy on bone mineral density, quantitative ultrasonometry and bone turnover in pre-menopausal women with breast cancer. *Eur J Cancer* 45: 3205-3212, 2009.
39. Shapiro CL, Phillips G, Van Poznak CH, Jackson R, Leboff MS, Woodard S and Lemeshow S: Baseline bone mineral density of the total lumbar spine may predict for chemotherapy-induced ovarian failure. *Breast Cancer Res Treat* 90: 41-46, 2005.
40. Tsangari H, Findlay DM, Zannettino AC, Pan B, Kuliwaba JS and Fazzalari NL: Evidence for reduced bone formation surface relative to bone resorption surface in female femoral fragility fracture patients. *Bone* 39: 1226-1235, 2006.
41. Tsurukami H, Nakamura T, Suzuki K, Sato K, Higuchi Y and Nishii Y: A novel synthetic vitamin D analogue, 2 beta-(3-hydroxypropoxy)1 alpha, 25-dihydroxyvitamin D3 (ED-71), increases bone mass by stimulating the bone formation in normal and ovariectomized rats. *Calcif Tissue Int* 54: 142-149, 1994.
42. Khalid AB and Krum SA: Estrogen receptors alpha and beta in bone. *Bone* 87: 130-135, 2016.
43. Sliwinski L, Folwarczna J, Nowińska B, Cegieła U, Pytlik M, Kaczmarczyk-Sedlak I, Trzeciak H and Trzeciak HI: A comparative study of the effects of genistein, estradiol and raloxifene on the murine skeletal system. *Acta Biochim Pol* 56: 261-270, 2009.
44. Erben RG, Scutt AM, Miao D, Kollenkirchen U and Haberey M: Short-term treatment of rats with high dose 1,25-dihydroxyvitamin D3 stimulates bone formation and increases the number of osteoblast precursor cells in bone marrow. *Endocrinology* 138: 4629-4635, 1997.
45. Erben RG, Bromm S and Stangassinger M: Therapeutic efficacy of 1alpha,25-dihydroxyvitamin D3 and calcium in osteopenic ovariectomized rats: Evidence for a direct anabolic effect of 1alpha,25-dihydroxyvitamin D3 on bone. *Endocrinology* 139: 4319-4328, 1998.



This work is licensed under a Creative Commons Attribution-NonCommercial-NoDerivatives 4.0 International (CC BY-NC-ND 4.0) License.