

# Non-Islet Cell Tumor Hypoglycemia: A Rare Cause of Hypoglycemia in Pulmonary Sarcomatoid Cancer

Timothy B. Legare<sup>1</sup>, Oteni Hamilton<sup>2</sup>, Sarah Dhannoon<sup>2</sup>, Sayed Ali<sup>3</sup>

1. College of Medicine, University of Central Florida College of Medicine, Orlando, FL 2. Internal Medicine Residency, University of Central Florida College of Medicine 3. Medicine, Orlando VAMC

✉ **Corresponding author:** Timothy B. Legare, tblegare@knights.ucf.edu

Disclosures can be found in Additional Information at the end of the article

---

## Abstract

Non-islet cell tumor hypoglycemia (NICTH) is a rare paraneoplastic condition caused most commonly by metastatic mesenchymal tumors. A 74-year-old non-diabetic male with an eight-year history of metastatic sarcomatoid lung cancer presented with altered mental status. His previous treatment included a lobectomy and radiation. Laboratory investigations were significant for blood glucose of 28 mg/dL, confirming hypoglycemia. He was hypokalemic, a condition seen in approximately 50% of patients with NICTH, at 2.8 mEq/L of potassium (normal 3.5-5.2 mEq/dL) and his urine toxicology screen was negative. A computed tomography (CT) of the head was negative for any acute events. His tumor burden had progressed as compared to previous CTs. Administration of dextrose resolved his symptoms. Laboratory studies during subsequent hypoglycemic events measured his insulin-like growth factor-I (IGF-I) at 51 ng/mL, insulin-like growth factor-II (IGF-II) at 290 ng/mL, growth hormone (GH) at 0.6 ng/mL, C-peptide at 0.16 ng/mL (low), and insulin levels at <1 uIU/mL. 'Big' IGF-II, the gold standard for the diagnosis of NICTH, was not available at our facility. Based on these results, NICTH was diagnosed clinically. NICTH is a rare condition with episodes of recurrent hypoglycemic episodes in the setting of metastatic cancer. Ideal therapy for NICTH is tumor resection or debulking. In cases of inoperable tumors, glucocorticoids or recombinant human growth hormone (rGH) maintain euglycemia, with glucagon rescue in case of an emergency.

---

**Categories:** Endocrinology/Diabetes/Metabolism, Oncology

**Keywords:** nictH, hypoglycemia, lung cancer

## Introduction

Hypoglycemia is a life-threatening condition with a multitude of causes. Cancer-causing hypoglycemia is broadly categorized into three distinct areas. Hypoglycemia can manifest when a tumor produces insulin as in pancreatic or ectopic insulinomas, when a tumor infiltrates the liver or adrenal glands and causes local destruction, or when tumors produce a paraneoplastic disorder by the production of substances that activate receptors causing hypoglycemia. Non-islet cell tumor hypoglycemia (NICTH) is one such rare paraneoplastic disorder that is characterized by tumor production of partially processed insulin-like growth factor-II (termed 'big'-IGF-II) [1]. The tumors associated with NICTH are usually of mesenchymal origin [2]. Here, we present a case of NICTH in a patient with metastatic sarcomatoid carcinoma of the lung.

## Case Presentation

### How to cite this article

Legare T B, Hamilton O, Dhannoon S, et al. (December 20, 2017) Non-Islet Cell Tumor Hypoglycemia: A Rare Cause of Hypoglycemia in Pulmonary Sarcomatoid Cancer. *Cureus* 9(12): e1972. DOI 10.7759/cureus.1972

Received 07/28/2017

Review began 10/04/2017

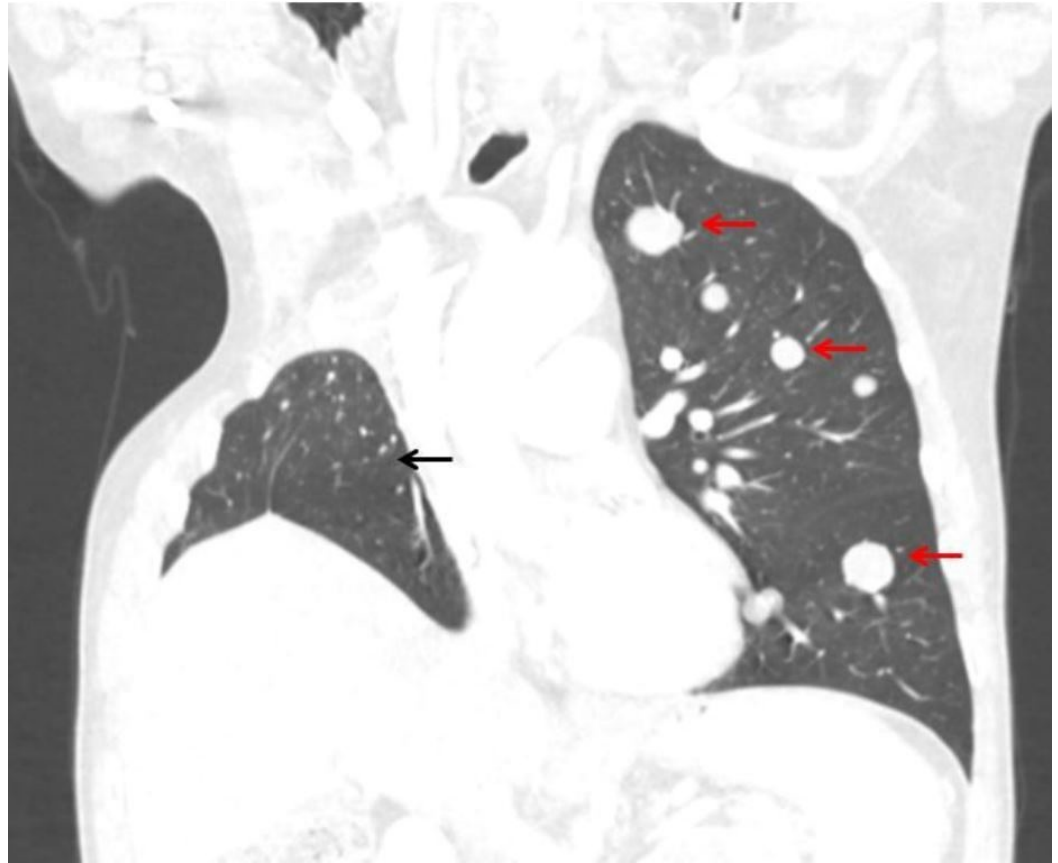
Review ended 12/09/2017

Published 12/20/2017

© Copyright 2017

Legare et al. This is an open access article distributed under the terms of the Creative Commons Attribution License CC-BY 3.0., which permits unrestricted use, distribution, and reproduction in any medium, provided the original author and source are credited.

A 74-year-old non-diabetic male presented to the emergency department with acute onset altered mental status. His past medical history was significant for metastatic sarcomatoid lung cancer following a right upper lobe resection of a 15 cm x 13 cm primary tumor with positive margins. Later, he was found to have metastatic lesions in the left lung, pararenal retroperitoneal compartments, right trapezius, left obturator internus, right pectineus, right hamstring muscles, and the gastrohepatic ligament, which were treated with palliative radiation. The most recent chest computed tomography (CT) is presented below in Figure 1, demonstrating a right upper lobe resection and metastatic lesions in the left lung.



**FIGURE 1: Computed tomography of the chest**

This is a coronal view of the patients CT chest in the preset lung window. The red arrows demonstrate metastatic lesions of pulmonary sarcomatoid lung cancer in the left lung. The black arrow demonstrates the patients' remaining right lower lobe of the lung status, post a right upper lobe resection.

He had previously deferred chemotherapy. He had been resting at home when he abruptly stood from his chair and began to speak nonsensical words to his wife. His speech was similar to a receptive aphasia, with sentences described as “Potato. Word. Image. Done.” He was unresponsive to questions but would mimic the movements of his wife. Additionally, he had profound global weakness during this event, needing both his wife and a neighbor to transport him to the hospital. Upon arrival at the emergency department, a head CT ruled out an acute bleed, his urine drug screen was negative, and his wife denied the use of any over-the-counter medications and herbal supplements. His finger-stick glucose was <45 mg/dL. He was given one liter of 5% dextrose in normal saline with immediate correction of his altered mental status. Initial laboratory investigation, prior to his dextrose correction in the emergency room upon presentation, showed hypokalemia at 2.5 mEq/dL (normal 3.5-5.2 mEq/dL), serum glucose at 28

mg/dL, and hemoglobin A1c (HbA1c) at 5.3%. During his admission, he continued to have hypoglycemic episodes, despite being monitored for caloric intake and medication administration. During one of his hypoglycemic events, he was symptomatic with a blood sugar of 64 mg/dL, blood was redrawn for insulin at <1.0 uIU/mL, C-peptide at 0.16 ng/mL (normal: 0.80-3.85 ng/mL), growth hormone (GH) at 0.6 ng/mL (normal: < 7.1 ng/mL), insulin-like growth factor-I (IGF-I) at 37 ng/mL (Z-Score: -1.3, normal: 34-246 ng/mL), and insulin-like growth factor-II (IGF-II) at 290 ng/mL (normal: 267-616 ng/mL). His ratio of IGF-II to IGF-I was approximately 8:1 and the ratios of IGF-II to IGF-I greater than 10:1 are highly suggestive for NICTH in the setting of an inability to measure IGF-II [3]. He was diagnosed clinically with NICTH based upon his recurrent hypoinsulinemic hypoglycemic episodes and started on oral prednisone 30 mg twice daily. He was discharged with instructions for monitoring hypoglycemia, education on glucagon rescue injection, and close follow-up with both his primary care provider and oncologist. The patient improved clinically on oral steroids. At the three-month follow-up, he required increasing doses of steroids to control his hypoglycemia, as his tumor burden increased. He continued to defer chemotherapy and any surgical treatment option.

## Discussion

The pathophysiology of NICTH is due to the production of under-processed IGF-II, named the 'big'-IGF-II protein. The proposed mechanism of increased 'big'-IGF-II leading to hypoglycemia is that the elevated levels of 'big'-IGF-II displace IGF-I and normally processed IGF-II from the insulin-like growth factor binding proteins (IGFBPs) causing increased free insulin-like growth factors (IGFs) [1]. The free IGF proteins act in an insulin-like manner, causing increased peripheral uptake of glucose in both muscle and adipose, decreased lipolysis, and decreased free glucose production by the liver. In addition to the effects of increased IGFs causing the peripheral utilization of glucose, there is also negative biofeedback via the elevated IGF to suppress the production of growth hormone (GH), further exacerbating the hypoglycemia [1]. The specific diagnosis of NICTH is based upon the values of the serum concentration of 'big'-IGF-II via an immunoblot assay and mature IGF-II via tricine sodium dodecyl sulfate-polyacrylamide gel electrophoresis (SDS-PAGE) analysis [1]. These are proposed as the most reproducible and sensitive tests for distinguishing 'big'-IGF-II from mature IGF-II [4]. Our hospital system did not have access to these tests and relied on a clinical diagnosis of NICTH. A serum ratio of IGF-II:IGF-I that is greater than 10 to one is indicative of NICTH but is not seen in all patients [3]. Additionally, hypokalemia was found in 25 of 47 (53%) patients diagnosed with NICTH [5]. Even though the confirmatory column chromatography of 'big'-IGF-II was not ordered, which is the "gold standard," a clinical diagnosis of NICTH can still be made. In a review of the literature in 2013, the authors suggest that a clinical diagnosis be made in patients with an oncologic disease who present with hypoinsulinemic hypoglycemia and laboratory evidence of a low IGF-I, a normal total IGF-II, and a low GH [3].

The treatment of NICTH is currently best achieved with the resection or debulking of the tumor burden [1]. In cases of inoperable tumors, as seen in our patient, low, moderate, or even high doses of oral glucocorticoids have been effective in stabilizing blood sugar and reducing hypoglycemic events [6-7]. The physiological mechanism of how glucocorticoids influence the pathophysiology of NICTH is not completely elucidated. It has been shown that glucocorticoid therapy reduces the serum levels of 'big'-IGF-II, but the mechanism is not clear. It is proposed that the glucocorticoid therapy either suppresses tumor production of 'big'-IGF-II or increases clearance from the serum [8]. Another therapy that has shown effectiveness in the treatment of NICTH has been the use of human recombinant growth hormone (hGH) [6,8-9]. The mechanism of hGH in suppressing hypoglycemic episodes is increasing IGF binding protein 3 (IGF BP3) and acid labile subunit (ALS), which decrease circulating 'big'-IGF-II while also stimulating hepatic gluconeogenesis [8,10]. The effectiveness of hGH has been shown to reduce the hypoglycemic episodes but did not raise insulin levels as was seen with glucocorticoids [8].

Ultimately, the optimal therapy for patients with disease that cannot be treated surgically or debulking may be a combination treatment of glucocorticoids and hGH.

## Conclusions

This case report concludes that a patient with repetitive hypoinsulinemic hypoglycemic episodes should be evaluated for NICTH. Additionally, the treatment of NICTH can be accomplished with oral glucocorticoids for the maintenance of euglycemia if the risks and benefits have been discussed with the patient.

## Additional Information

### Disclosures

**Human subjects:** Consent was obtained by all participants in this study. **Conflicts of interest:** In compliance with the ICMJE uniform disclosure form, all authors declare the following: **Payment/services info:** All authors have declared that no financial support was received from any organization for the submitted work. **Financial relationships:** All authors have declared that they have no financial relationships at present or within the previous three years with any organizations that might have an interest in the submitted work. **Other relationships:** All authors have declared that there are no other relationships or activities that could appear to have influenced the submitted work.

## References

1. de Groot JW, Rikhof B, van Doorn J, Bilo HJ, Alleman MA, Honkoop AH, van der Graaf WT: Non-islet cell tumour-induced hypoglycaemia: a review of the literature including two new cases. *Endocr Relat Cancer*. 2007, 14:979–993. [10.1677/erc-07-0161](https://doi.org/10.1677/erc-07-0161)
2. Thiruchelvam N, Kistangari G, Listinsky C, Daw H, Kumar V: Life-threatening hypoglycemia resulting from a nonislet cell tumor. *J Community Support Oncol*. 2015, 13:296–297.
3. Dutta P, Aggarwal A, Gogate Y, et al.: Non-islet cell tumor-induced hypoglycemia: a report of five cases and brief review of the literature. *Endocrinol Diabetes Metab Case Rep*. 2013, 2013:130046. [10.1530/edm-13-0046](https://doi.org/10.1530/edm-13-0046)
4. Miraki-Moud F, Grossman AB, Besser M, Monson JP, Camacho-Hubner C: A rapid method for analyzing serum pro-insulin-like growth factor-II in patients with non-islet cell tumor hypoglycemia. *J Clin Endocrinol Metab*. 2005, 90:3819–3823. [10.1210/jc.2004-2090](https://doi.org/10.1210/jc.2004-2090)
5. Fukuda I, Hizuka N, Ishikawa Y, et al.: Clinical features of insulin-like growth factor-II producing non-islet-cell tumor hypoglycemia. *Growth Horm IGF Res*. 2006, 16:211–216. [10.1016/j.gHIR.2006.05.003](https://doi.org/10.1016/j.gHIR.2006.05.003)
6. Bourcigaux N, Arnault-Ouary G, Christol R, Perin L, Charbonnel B, Le Bouc Y: Treatment of hypoglycemia using combined glucocorticoid and recombinant human growth hormone in a patient with a metastatic non-islet cell tumor hypoglycemia. *Clin Ther*. 2005, 27:246–251. [10.1016/j.clinthera.2005.02.004](https://doi.org/10.1016/j.clinthera.2005.02.004)
7. Teale JD, Wark G: The effectiveness of different treatment options for non-islet cell tumour hypoglycaemia. *Clin Endocrinol*. 2004, 60:457–460. [10.1111/j.1365-2265.2004.01989.x](https://doi.org/10.1111/j.1365-2265.2004.01989.x)
8. Teale JD, Marks V: Glucocorticoid therapy suppresses abnormal secretion of big IGF-II by non-islet cell tumours inducing hypoglycaemia (NICTH). *Clin Endocrinol*. 1998, 49:491–498. [10.1046/j.1365-2265.1998.00564.x](https://doi.org/10.1046/j.1365-2265.1998.00564.x)
9. Agus MS, Katz LE, Satin-Smith M, Meadows AT, Hintz RL, Cohen P: Non-islet-cell tumor associated with hypoglycemia in a child: successful long-term therapy with growth hormone. *J Pediatr*. 1995, 127:403–407. [10.1016/S0022-3476\(95\)70071-4](https://doi.org/10.1016/S0022-3476(95)70071-4)
10. Dutta P, Bhansali A, Kumar S, Jayaprakash P, Nahar U: A rare cause of hypoglycaemia. *BMJ Case Rep*. 2009, 2009:1789. [10.1136/bcr.04.2009.1789](https://doi.org/10.1136/bcr.04.2009.1789)