

An interesting case of characteristic methanol toxicity through inhalational exposure

Pratyush Kumar¹, Atul Gogia¹, Atul Kakar¹, Pratyush Miglani¹

¹Department of Family Medicine, Sir Gangaram Hospital, New Delhi, India

ABSTRACT

Methanol poisoning is rare but carries high risk of morbidity and mortality. Most of the cases witnessed in emergency are due to consumption of adulterated alcohol. Here we are reporting a very rare case of methanol poisoning through inhalational exposure leading to putamen necrosis and decreased visual acuity. He had dyselectrolytemia and metabolic acidosis which was successfully managed with early intervention. Its importance lies in the fact that inhalational methanol poisoning is an entity which if picked up early can prevent long-term neurological sequelae.

Keywords: Dyselectrolytemia, methanol, poisoning

Introduction

Methanol is a highly toxic, clear and colorless alcohol resembling ethanol. Poisoning may occur through cutaneous, gastrointestinal or inhalational mode. Methanol is used as a solvent in cleaning solution, dyes, paint removers etc. Methanol poisoning may lead to severe complication such as severe visual dysfunction, metabolic disturbances, permanent neurological dysfunction and even death. Consumption of adulterated alcohol is the usual cause of methanol poisoning in most of the patients; very rarely do we encounter methanol poisoning through inhalational exposure.^[1] Here we report an unusual case of methanol poisoning through exposure of fumes in young healthy male leading to temporary visual blindness who improved after prompt treatment.

Case Report

A 30-year-old healthy male, working in a pharmaceutical company, where iron preparations were being manufactured was reported. He had no co morbidities and presented to the emergency in our hospital with complaints of blurring of vision, restlessness and vomiting. History of exposure to methanol fumes was given by co-workers at the time of presentation and

later confirmed by the patient when his sensorium became better. Written informed consent was taken from the attending relative and later by the patient.

Initial investigations revealed hemoglobin 15.1 gm/dl, total leukocyte count 13,100/cumm, platelet 3.01 lakhs, S. creatinine. 1.07 mg/dl, and SGOT/SGPT 45/45 IU/L. He was examined and was found to have high anion gap metabolic acidosis (pH – 7.05, HCO₃ – 7.9 μmol/L, Na – 135 meq/L, K – 4.27 meq/L, Cl – 106 meq/L.) with respiratory failure. However, methanol level in blood was not checked because of non-availability of standardized protocol and equipments.

He was electively intubated and ventilated. Hemodialysis was done in view of severe metabolic acidosis. NCCT head was done which showed hypodensity in bilateral basal ganglia suggestive of methanol toxicity [Figure 1 Arrow]. He was given 30 ml of 40% ethanol six hourly through ryles tube for 2 days.

Visual evoked potential revealed perception of light bilaterally [Figure 2]. Fundus examination revealed normal disc with anisocoria [Figure 3]. Visual acuity was finger counting close to face. MRI brain was done which showed bilateral putamen involvement consistent with methanol poisoning [Figures 4 and 5 Arrow] for which neurology consultation was taken and treatment continued as per plan. Ultrasound abdomen was normal. 2D ECHO showed left ventricular ejection fraction of 65%.

Access this article online

Quick Response Code:



Website:
www.jfmpc.com

DOI:
10.4103/2249-4863.161359

Address for correspondence: Dr. Pratyush Kumar,
Department of Family Medicine, Sir Gangaram Hospital,
New Delhi - 110 060, India.
E-mail: pratyush410@yahoo.co.in

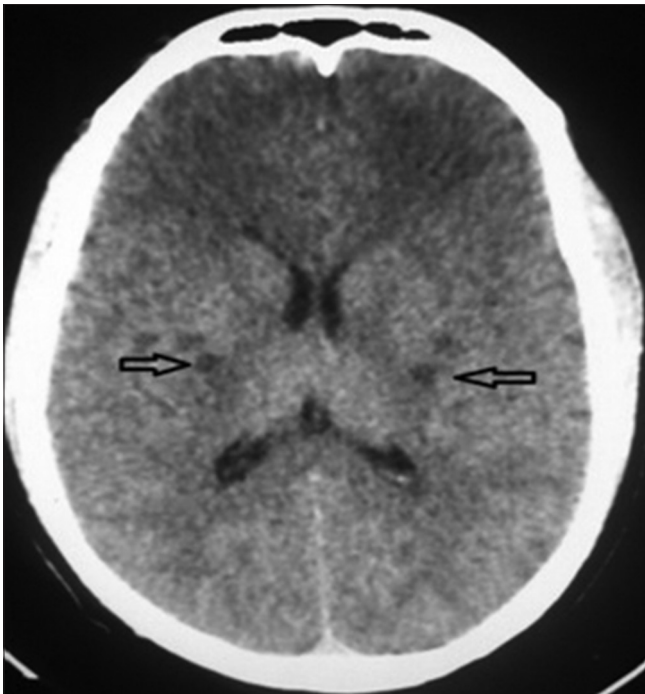


Figure 1: NCCT head showing hypodensity in bilateral basal ganglia

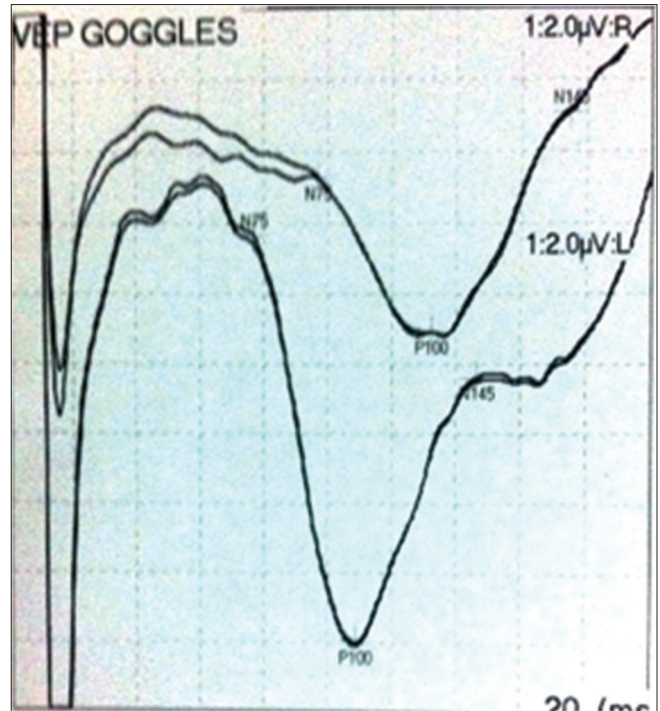


Figure 2: Visual evoked potential showing perception of light bilaterally

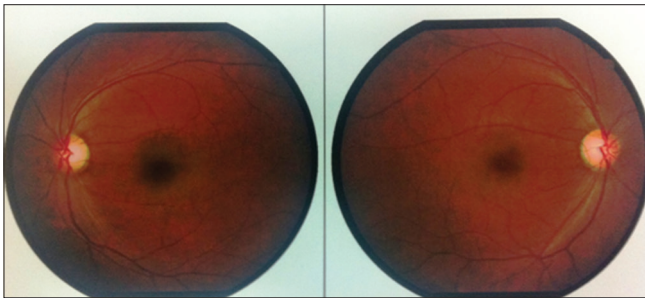


Figure 3: Fundus examination showed normal fundus

Gradually metabolic acidosis improved and symptomatically started feeling better. He was weaned off ventilator and maintained Oxygen saturation well on room air. Regular ophthalmic examination was done which showed improvement in vision bilaterally (left >>right). Neurological assessment of the patient revealed no motor or sensory disturbances. He was discharged on the fifth day. On the follow up, best corrected visual acuity was 6/18 in right and 6/6 in left. In view of decreased vision, oral steroids were started which tapered over 10 days following which his visual acuity improved.

Discussion

Methanol poisoning has been reported in the literature mostly following consumption of fraudulent adulterated alcoholic drinks. Methanol is used as a solvent in cleaning solution, dyes, paint removers etc., Methanol is also used in pharmaceutical industry particularly in making of iron sucrose complex. Methanol fumes may occur at various steps where reaction mixtures are autoclaved at about 120°–125°C for 1-4 h and

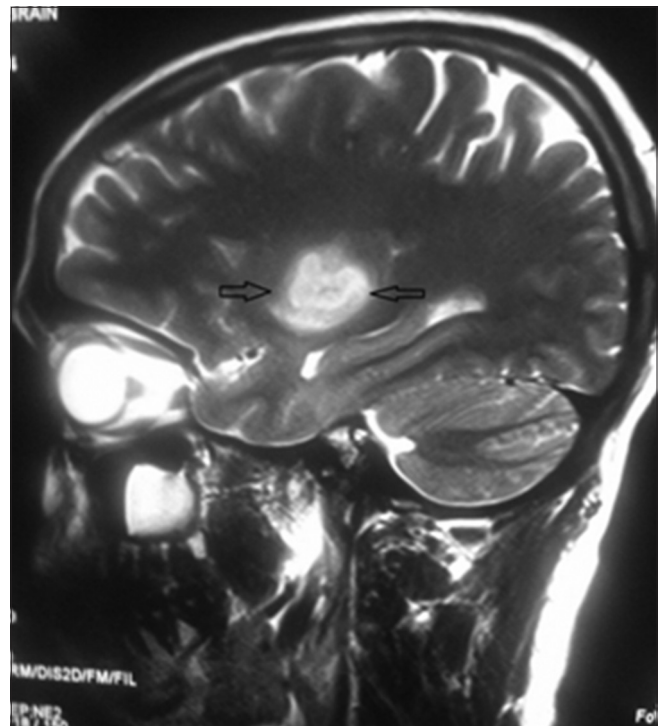


Figure 4: MRI brain sagittal section showing putamen necrosis

dehydrated with methanol at a temperature between 60° and 80°C.

Methanol intoxication leads to neurological, gastrointestinal and ocular complications. There is a latent phase of 6-30 h post-ingestion or longer if the patient has co-ingested, for clinical

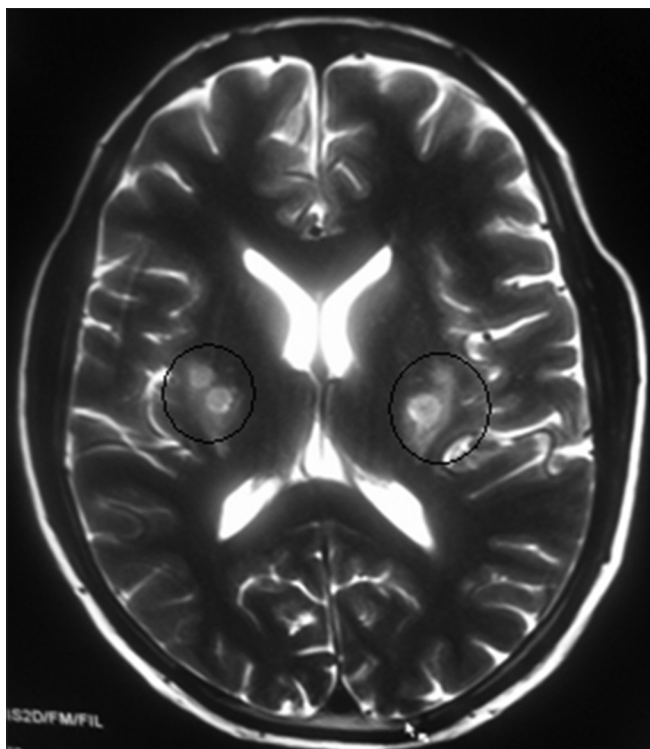


Figure 5: MRI brain axial section showing putamen necrosis

effects of methanol poisoning to occur.^[2] This latency is due to slow metabolism of methyl alcohol to formic acid.

Methanol is oxidized to formaldehyde by alcohol dehydrogenase, which can be subsequently oxidized to formic acid, which is the major toxic metabolite of methanol. Formic acid is primarily responsible for the retinal and optic nerve damage, probably caused by disruption of mitochondrial electron transport.^[3]

Methanol toxicity has been described to appear in three phases.^[4,5] In the early phase, patient presents with mild euphoria, inebriation, weakness, dizziness, and nausea. The second phase is marked by the development of metabolic acidosis characterized by vomiting, abdominal pain, confusion, visual disturbances, photophobia, blurred vision, bilateral mydriasis, unresponsiveness to light and occasional blindness. In the third phase, in direct relation to the degree of metabolic acidosis, neuronal injury occurs with retinal necrosis and hemorrhage in the basal ganglia of the brain. Our patient presented at approximately 32 h post exposure and was considered to be in third phase.

Diagnosis was based on high anion gap metabolic acidosis, visual blurring, and history of exposure to methanol fumes.

It requires early recognition and treatment to prevent permanent sequale. Management requires general supportive care, i.e., mechanical ventilation, intravenous fluids, and vasopressors may be indicated in severe intoxication. Acidosis (pH < 7.3) can be managed by sodium bicarbonate and hemodialysis.

Hemodialysis is the most effective method to rapidly remove toxic acid metabolites and methanol. Indications of hemodialysis are severe metabolic acidosis and evidence of end organ damage.

The further generation of toxic metabolite should be blocked by the administration of fomepizole or ethanol and folinic acid to enhance the metabolism of formic acid. Ethanol or fomepizole should be administered as soon as possible to prevent formate production. Fomepizole is preferred over ethanol as an antidote because of higher affinity and longer duration of action.^[6] Ethanol can be administered both orally and intravenously. IV route is considered safer but may lead to thrombophlebitis. Goal is to maintain a target ethanol concentration of 1000–1500 mg/l. Loading dose of absolute ethanol is 600 mg/kg and standard maintenance dose in non alcoholics is 66 mg/kg/hr, whereas in ethanol abusers is 154 mg/kg/h.

Fomepizole acts similar to ethanol though costly but with fewer side effects given intravenously with loading dose of 15 mg/kg, followed by 10 mg/kg at 12, 24 and 36 hours. After 48 h, fomepizole dose should be increased to 15 mg/kg every 12 h because of enhanced fomepizole clearance due to fomepizole-induced cytochrome P450 (CYP2E1) induction.^[7]

Our patient was given 30 ml of 40% ethanol six hourly through ryles tube for 2 days under intensive care setting with glucose and electrolyte monitoring. Our patient improved clinically on receiving renal replacement therapy. On follow up, his visual acuity also improved after giving oral steroid tapered off over 10 days.

Methanol poisoning has typical presentation on radiological imaging. Non-enhanced CT scan may show hypodensity in the putamen and less often in caudate nucleus but NCCT head may be normal when done within 24 h after methanol ingestion. MR findings in methanol toxicity are bilateral. Putaminal necrosis may have varying degrees of hemorrhage. It is considered most consistent radiographic finding in methanol poisoning. There have been reports of brain lesions involving parietal, temporal, or frontal areas of cerebrum and cerebellar hemispheres on MRI. Putaminal necrosis and hemorrhage is probably due to toxicity caused by of methanol metabolites and metabolic acidosis.^[8-10] High metabolic rates of basal ganglia and optic nerves may also be a predisposing factor for ischemia and necrosis. Putaminal necrosis on MRI is not specific for methanol poisoning. It may be seen in toxic poisoning like carbon monoxide and cyanide poisoning. Certain systemic diseases like Wilsons disease and Leigh disease may also have similar MR findings. There is significant overlap and variability in MRI findings. Carbon monoxide has been found to affect globus pallidus particularly, whereas methanol and cyanide poisoning has propensity to affect putamen. White matter edema may be an additional finding in methanol poisoning.

Clinically, patient may be in distress with complaints of decreased visual acuity; on blood gas analysis, metabolic acidosis may be

evident and MR imaging may show putamen necrosis. Mostly such cases are first attended by primary care physicians so it's important to recognize such occupational hazard, take careful history then act early and act fast. Its importance lies in the fact that inhalational methanol poisoning is an entity which if picked up early can prevent long-term neurological sequelae. Early recognition and referral to higher center by the primary care physician/family physician would be helpful in recovery of these patients.

References

1. Barceloux DG, Bond GR, Krenzelok EP, Cooper H, Vale JA; American Academy of Clinical Toxicology Ad Hoc Committee on the Treatment Guidelines for Methanol Poisoning. American Academy of Clinical Toxicology practice guidelines on the treatment of methanol poisoning. *J Toxicol Clin Toxicol* 2002;40:415-46.
2. Hovda KE, Hunderi OH, Tafjord AB, Dunlop O, Rudberg N, Jacobsen D. Methanol outbreak in Norway 2002-2004: Epidemiology, clinical features and prognostic signs. *J Intern Med* 2005;258:181-90.
3. Treichel JL, Henry MM, Skumatz CM, Eells JT, Burke JM. Formate, the toxic metabolite of methanol, in cultured ocular cells. *Neurotoxicology* 2003;24:825-34.
4. Rowe VK, McCollister SB. Alcohols. In: Clayton GD, Clayton FE, editors *Patty's Industrial Hygiene and Toxicology*. 3rd ed., Vol. 2C. New York: John Wiley & Sons; 1981. p. 4527-708.
5. Loza R, Rodriguez D. A Case of Methanol Poisoning in a Child. *Case Rep Nephrol* 2014;2014:652129.
6. Megarbane B. Treatment of patients with ethylene glycol or methanol poisoning: Focus on fomepizole. *Open Access Emerg Med* 2010;2:67-75.
7. Rietjens SJ, de Lange DW, Meulenbelt J. Ethylene glycol or methanol intoxication: Which antidote should be used, fomepizole or ethanol? *Neth J Med* 2014;72:73-9.
8. Blanco M, Casado R, Vázquez F, Pumara JM. CT and MR imaging findings in methanol intoxication. *AJNR Am J Neuroradiol* 2006;2013:452-4.
9. Gupta N, Sonambekar AA, Daksh SK, Tomar L. A rare presentation of methanol toxicity. *Ann Indian Acad Neurol* 2013;16:249-51.
10. Arora V, Nijjar IB, Multani AS, Singh JP, Abrol R, Chopra R, *et al.* MRI findings in methanol intoxication: A report of two cases. *Br J Radiol* 2007;80:e243-6.

How to cite this article: Kumar P, Gogia A, Kakar A, Miglani P. An interesting case of characteristic methanol toxicity through inhalational exposure. *J Family Med Prim Care* 2015;4:470-3.

Source of Support: Nil. **Conflict of Interest:** None declared.