

Managements of simple liver cysts: ablation therapy versus cyst unroofing

Seong-Ryong Kim, Do-Sang Lee, and Il-Young Park

Department of Surgery, Bucheon St. Mary Hospital, The Catholic University of Korea, Bucheon, Korea

Backgrounds/Aims: Simple liver cysts were easily recognizable with the advanced imaging procedures, such as ultrasound and computed tomography scan. A large cyst or significant symptoms were indications for the treatments. Ablation therapy with sclerotic agents was effective, but there were several complications including severe pain. With the surgical cyst unroofing method introduced, we compared the cyst unroofing method and ablation therapy. **Methods:** Between March 1997 and May 2011, we performed treatments of simple liver cysts in 27 patients. There were 23 women and 4 men (age range: 42-84 years; mean age: 64 years). The cyst unroofing was undergone with laparoscopic (n=13) and open technique (n=1). The ablation therapy was performed with ethanol (n=13) and acetic acid (n=1). **Results:** The usual symptoms of the liver cysts were abdominal mass (n=7), indigestion (n=4), abdominal discomfort (n=3), and the increasing size of the cysts (n=4). The mean diameter of the cysts was 10.9 cm. The cyst unroofing method was performed effectively in 14 patients. One patient had bleeding during operation, and was converted to the open technique. One patient had a bile leak from the cyst, but it was successfully closed with the laparoscopic technique. Among the 14 cases with the ablation therapy, there were 4 complications: hematoma (n=1); cyst leaking during aspiration (n=2); acute renal failure (n=1); and death due to acetic acid intoxication (n=1). **Conclusions:** Laparoscopic cyst unroofing was more effective and safer in management than the ablation therapy in simple liver cysts. (Korean J Hepatobiliary Pancreat Surg 2012;16:134-137)

Key Words: Liver cyst; Ablation; Cyst unroofing

INTRODUCTION

Simple cysts of the liver contain serous fluid, do not communicate with the biliary tree, and do not have septations. They are generally spherical or ovoid and can be as large as 20 cm. Large cysts can compress normal liver, inducing regional atrophy and sometimes compensatory contralateral hypertrophy. In 50% of the cases, the cysts are singular.

Ablation therapy with sclerotic agents is an effective treatment for the liver cysts. However, there are several complications such as severe pain and bleeding. Laparoscopic cyst unroofing method has been introduced as an alternative.¹⁻³ We tried to assess the outcomes of the patients with simple liver cysts, as treated with the ablation therapy or the surgical cyst unroofing method.

METHODS

We treated 27 patients with simple liver cysts in the Bucheon St. Mary Hospital, the Catholic University of Korea, between March 1997 and May 2011. There were 23 women and 4 men (Table 1). We performed the ablation therapy on 14 patients, 13 patients with ethanol and 1 patient with acetic acid. The cyst unroofing was performed in 14 patients.

Table 1. Characteristics of the patients with simple cysts

	Ablation therapy	Surgical un-roofing
Mean age (years)	63.7	62.2
Sex (M/F)	2/12	1/13
Cyst average size (cm)	11.5	10.5
Single/multiple cysts	10/4	8/6

Received: September 29, 2012; **Revised:** October 5, 2012; **Accepted:** October 15, 2012

Corresponding author: Il-Young Park

Department of Surgery, Bucheon St. Mary Hospital, The Catholic University of Korea, 327, Sosa-ro, Wonmi-gu, Bucheon 420-717, Korea
Tel: +82-32-340-7021, Fax: +82-32-340-2544, E-mail: parkiy@catholic.ac.kr

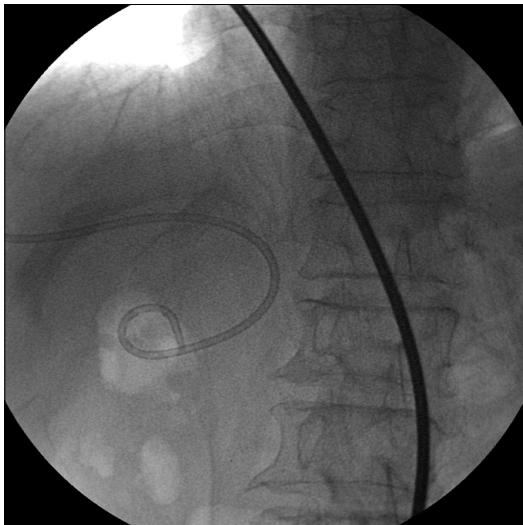

Fig. 1. A pigtail catheter was inserted into the cyst under ultrasound guidance.

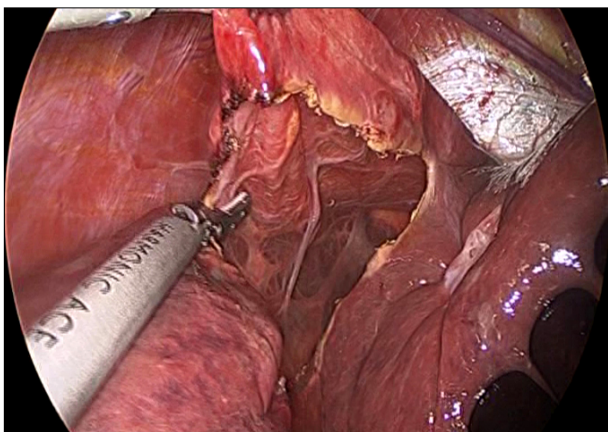


Fig. 2. The cyst was aspirated and unroofed with excision of the wall near the liver tissue by ultrasonic scalpel through laparoscopic approach.

Ablation procedure

In the ablation group, we inserted 7 to 10 Fr. catheter into the cyst using ultrasound. After evacuating the cyst fluid, we injected ablation agent. Ethanol was used in 13 cases, and acetic acid was used in 1 case (Fig. 1). The number of ablation procedure completed per patient was one to three times, and the mean number of the ablation therapy was 1.7 times.

Surgical procedure

Cyst unroofing was completed using the laparoscopic procedure. One case was converted to the open technique, because of bleeding during the operation. The principles

Table 2. Results of cyst treatments

	Ablation therapy	Surgical un-roofing	<i>p</i> -value
Hospital stay (days)	5.9	3.3	0.020
Mean decreased cyst size (cm)	4.2	2.2	Not done
Size decrease (%)	61	78	0.797
Postoperative complication (n)	4	0	Not done

Table 3. Complications following cyst treatments

Ablation therapy	Surgical un-roofing
Pleural effusion (1)	Bleeding during the operation (1) [†]
Bleeding and hematoma (1)	Bile leak during the operation (1)
Acute renal failure (1)	
Death (1)*	

*One patient died due to acetic acid intoxication

[†]The operation was converted to the open procedure

of this surgery were to remove as much of the cyst wall as possible. We inserted 3 to 4 trocars (one 10 mm and two or three 5 mm). We applied ultrasound to find out the location and size of the cyst. The harmonic scalpel was applied to open the cyst and to widely resect it (Fig. 2). The mean operation time was 104 minutes.

RESULTS

The mean age of the patients was 63.7 years old in the ablation group and 62.2 years old in the surgical unroofing group. Two men and twelve women were treated in the ablation group. One man and twelve women were treated in the surgical unroofing group. The average cyst diameter was 11.5 cm in the ablation group and 10.5 cm in the surgical unroofing group. Four patients had multiple cysts, and ten patients had a single cyst in the ablation group. Six patients had multiple cysts, and seven patients had a single cyst in the surgical unroofing group (Table 1).

The average hospital stays after the treatments were 5.9 days for ablation and 3.3 days for unroofing (Table 2). The unroofing group had shorter hospital days compared to the ablation group. The sizes of the cysts were decreased up to 78% of the unroofing group and 61% of the ablation group.

There were 4 cases of postoperative complications in the ablation group: one pleural effusion; one bleeding

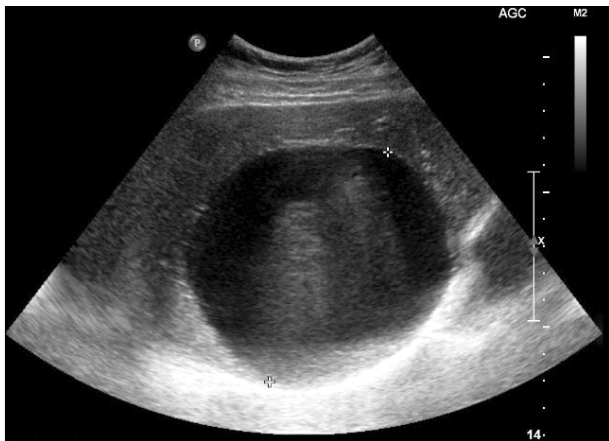

Fig. 3. Abdominal ultrasound shows a well-defined hypoechoic lesion.

with hematoma; one developing acute renal failure; and one death due to acetic acid intoxication. There was no postoperative complication in the unroofing group. However, there was a bleeding developed in one patient during the operation, and converted to open procedure for this patient. There was a bile leak from cyst wall in one case during the operation, and it was closed with suture ligation (Table 3).

DISCUSSION

Simple liver cysts are congenital liver disease. The data related to the epidemiology of cystic liver disease are heterogeneous. In the series of 88,000 abdominal exploration procedures, the incidence of any type of cyst was 17%.⁴ The increasing usage and refinement of abdominal computed tomography and ultrasound revealed that the incidence was around 5%.⁵

Simple cysts are relatively common findings in adults and are mostly asymptomatic incidental radiologic findings. Simple liver cysts are frequently recognized with the advanced imaging procedures such as ultrasound and CT scan. CT scan shows homogeneous, rounded or ovoid, well-defined, and non-enhancing cystic lesion. Although CT demonstrates anatomic relationships, ultrasound is a helpful test of choice to confirm a single, thin-walled simple cyst (Figs. 3, 4).

Hydatid disease, cystadenoma, and metastatic neuroendocrine tumor are the most important differential diagnoses to consider.⁶ A thick or nodular wall raises the sus-

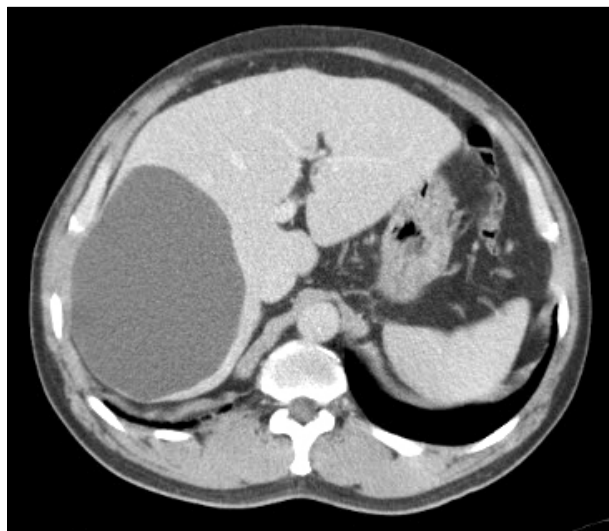


Fig. 4. Abdomen computed tomography shows a well-demarcated lesion with low density and without enhancement after contrast administration.

picion of a cystadenoma but can also represent hemorrhage within the cyst. The most common complication is intra-cystic bleeding, but complications are rare overall.

Occasionally, a large cyst causes symptoms. Liver cysts become symptomatic in about 10% to 16% of patients.⁷ A large cyst or significant symptoms are indications for the treatments. The treatment of simple hepatic cysts is only indicated if they are symptomatic or if there is diagnostic uncertainty. Because most cysts are asymptomatic, a thorough evaluation of the cause of the symptoms must be carried out before attributing them to the cyst.⁸

Nonsurgical treatment consists of aspiration and injection of a sclerosing agent such as ethanol.⁹ Ablation therapy has more complications such as bleeding, infection, and intoxication.^{10,11} Moreover ablation therapy is associated with high rate of recurrence.¹²

Surgical therapy is achieved by fenestration, or unroofing the portion of the cyst that is extrahepatic. Surgical treatment consists of open technique and laparoscopic procedure. Laparoscopic unroofing can be done with minimal risk of bleeding,¹³ less scar, and less postoperative pain. The surgical treatments have less recurrence than the ablation therapy (77.8% in the ablation group vs. 30.8% in the surgical treatment group).¹² Occasionally, a formal anatomical resection is required, but the lesions are usually amenable to simple surgery.¹⁴

We showed that both ablation therapy and laparoscopic

cyst unroofing were effective in terms of decreasing the size of cyst. However, laparoscopic cyst unroofing was a better treatment for the cysts developed in liver, because laparoscopic cyst unroofing had less complications such as bleeding, infection, and intoxication, and had less hospital days after treatment than the ablation therapy.

In conclusion, laparoscopic cyst unroofing was more effective and safer in management than ablation therapy in the treatment of simple liver cysts.

REFERENCES

1. Koperna T, Vogl S, Satzinger U, et al. Nonparasitic cysts of the liver: results and options of surgical treatment. *World J Surg* 1997;21:850-854.
2. Morino M, De Giuli M, Festa V, et al. Laparoscopic management of symptomatic nonparasitic cysts of the liver. Indications and results. *Ann Surg* 1994;219:157-164.
3. Weber T, Sendt W, Scheele J. Laparoscopic unroofing of non-parasitic liver cysts within segments VII and VIII: technical considerations. *J Laparoendosc Adv Surg Tech A* 2004;14:37-42.
4. Sanfelippo PM, Beahrs OH, Weiland LH. Cystic disease of the liver. *Ann Surg* 1974;179:922-925.
5. Caremani M, Vincenti A, Benci A, et al. Ecographic epidemiology of non-parasitic hepatic cysts. *J Clin Ultrasound* 1993;21:115-118.
6. Jones WL, Mountain JC, Warren KW. Symptomatic non-parasitic cysts of the liver. *Br J Surg* 1974;61:118-123.
7. Gigot JF, Hubert C, Banice R, et al. Laparoscopic management of benign liver diseases: where are we? *HPB (Oxford)* 2004;6:197-212.
8. Gaines PA, Sampson MA. The prevalence and characterization of simple hepatic cysts by ultrasound examination. *Br J Radiol* 1989;62:335-337.
9. Chun KS, Park JM, Ha HK, et al. A huge hepatic cyst successfully treated with absolute ethanol. *J Korean Radiol Soc* 1989;25:564-568.
10. Edwards JD, Eckhauser FE, Knol JA, et al. Optimizing surgical management of symptomatic solitary hepatic cysts. *Am Surg* 1987;53:510-514.
11. Andersson R, Jeppsson B, Lunderquist A, et al. Alcohol sclerotherapy of non-parasitic cysts of the liver. *Br J Surg* 1989;76:254-255.
12. Erdogan D, van Delden OM, Rauws EA, et al. Results of percutaneous sclerotherapy and surgical treatment in patients with symptomatic simple liver cysts and polycystic liver disease. *World J Gastroenterol* 2007;13:3095-3100.
13. Z'graggen K, Metzger A, Klaiber C. Symptomatic simple cysts of the liver: treatment by laparoscopic surgery. *Surg Endosc* 1991;5:224-225.
14. Sanchez H, Gagner M, Rossi RL, et al. Surgical management of nonparasitic cystic liver disease. *Am J Surg* 1991;161:113-118.