



## Review Article

## Coronary chronic total occlusion intervention: A pathophysiological perspective

Debabrata Dash<sup>a,b,\*</sup><sup>a</sup>Thumbay Hospital, Ajman, United Arab Emirates<sup>b</sup>Beijing Tiantan Hospital, Beijing, China

## ARTICLE INFO

## Article history:

Received 3 May 2017

Accepted 10 January 2018

Available online 10 January 2018

## Keywords:

Chronic total occlusion

Pathophysiology

Percutaneous coronary intervention

## ABSTRACT

Percutaneous coronary intervention (PCI) of chronic total occlusion (CTO) is the last frontier in coronary intervention. PCI of CTO carries multiple advantages, such as significant improvement in symptoms, improvement in abnormal wall motion and left ventricular function and, possibly, increased long-term survival. As of today the procedural success is markedly improved because of technical innovations and is limited to highly experienced operators. To enhance the overall success rate from a worldwide perspective, a thorough understanding of its pathophysiology is critical to further development of newer techniques and technologies. In this review, the author outlines in-depth the evidence that underpins our understanding of CTO pathophysiology and its insight into CTO intervention that incorporates various steps and techniques to cross the lesion.

© 2018 Published by Elsevier B.V. on behalf of Cardiological Society of India. This is an open access article under the CC BY-NC-ND license (<http://creativecommons.org/licenses/by-nc-nd/4.0/>).

## 1. Introduction

Percutaneous coronary intervention (PCI) of coronary chronic total occlusion (CTO) remains technically demanding and is considered as one of the last frontiers in coronary intervention. Referral for CTO PCI remains low in many countries despite the reported success rates greater than 80% in Japan, USA and European centers.<sup>1</sup> Although plentiful retrospective data exist, there is lack of randomized trials supporting the benefit of CTO PCI on morbidity and mortality. This review aims to shed light on the development of techniques and strategies with an emphasis on procedurally relevant pathophysiology.

## 2. Pathophysiology overview

In essence, the majority of CTOs result from soft plaque rupture followed by thrombotic coronary occlusion and organization of thrombotic material. A minority of CTO results from progression of atheroma. Once coronary artery occlusion occurs, frequently the

thrombus is propagated in a retrograde fashion from the point of occlusion to the proximal segment with a major side branch (SB).<sup>2,3</sup> This thrombus gets organized that is more rigid than fresh thrombus formation, with a dense concentration of collagen-rich fibrous tissue at the proximal and distal ends of the lesions, referred to as proximal and distal fibrous caps, respectively<sup>3</sup> with intervening occluded segments (Table 1). The occluded segment remains biologically active with recanalization, neovascularization, and inflammation giving rise to different composition of CTOs (Table 2).<sup>2,4</sup> The younger CTO lesions are observed to be predominantly soft or lipid laden whereas older lesions are typically hard or calcific.<sup>2</sup> Short duration CTO showed organized or organizing thrombus and presence of necrotic core. Srivasta et al.<sup>2</sup> documented age-related increase in the calcium and collagen content of CTOs which may be the substrate for inability to cross the occlusion with a guidewire. Increase numbers of intimal plaque capillaries are observed with increasing occlusion age. In CTOs less than one year old, the adventitia is the predominant vessel wall location of neovascular channel formation in terms of both number and size. In CTOs more than one year old, intimal plaque capillary numbers and size increase and are not significantly different from adventitia. The high frequency of large neovascular channels in all vessel wall locations even in CTOs of less than one year old duration reflects that the enlargement of growing neovascular channels within CTO is an early event.<sup>2,5</sup> The proximal cap often is fibrocalcific.<sup>6</sup> The distal cap considered to be less resistant than proximal cap, is conceptually important for development of

*Abbreviations:* CTO, chronic total occlusion; PCI, percutaneous coronary intervention; MDCT, multiple detector computed tomography; IVUS, intravascular ultrasound; CART, controlled antegrade and retrograde subintimal tracking.

\* Corresponding author. Present address: Thumbay Hospital, P.O Box 4184, Ajman, United Arab Emirates.

E-mail address: [dr.debabrata@thumbayhospital.ae](mailto:dr.debabrata@thumbayhospital.ae) (D. Dash).

retrograde techniques. This approach can be used after antegrade crossing failure or as an initial situations like ostial occlusions, long occlusions, heavy calcification, occlusions with ambiguous proximal cap, and occlusions with a diffusely diseased distal vessel, occlusion involving a distal major bifurcation and CTO vessels that are difficult to engage such as anomalous coronary arteries. The success of guidewire crossing in CTO PCI might be affected by loose fibrous tissue, pultaceous debris, or intimal plaque microchannels.<sup>2</sup>

CTOs exhibit two types of histological vascular channels that span the occluded segment.<sup>2,5</sup> Endothelialized microchannels (160–230  $\mu\text{m}$ ) generated via neovascularization that connects the CTO from proximal to distal cap are termed histologically recanalized segments. Another type of vascular channels are micro capillaries (<100  $\mu\text{m}$ ) that pass into the small SB or into the vasa vasorum, are termed non-recanalized segments as they do not span the CTO from proximal to distal caps. Short segment CTO with tapered tip stump (Fig. 1) is less likely to have a SB and more likely to have histologically recanalized segments than longer occlusions.<sup>5</sup> The tissue composition of tapered stump is characteristically looser fibrous tissue, with prominent neovascularization and recanalization. These recanalized segments (Fig. 2) may facilitate guidewire entry into distal true lumen within endothelialized microchannels. All occlusions with non-tapered or blunt stump have non-recanalized microcapillaries.<sup>4</sup> Srivatsa et al demonstrated that older CTOs have greater calcification and fibrosis, fewer foam cells and macrophages as compared to younger ones.<sup>2</sup> Fuji et al defined the proximal cap according to angiographic landmarks, and observed abrupt morphology change on intravascular ultrasound (IVUS).<sup>6</sup> Calcium was concentrated particularly in blunt stump proximal cap. A calcified arc was demonstrated in the wall opposite the SB. Suzuki et al found moderately strong correlations between lesion age and indices of calcification demonstrated by IVUS. Very recent CTO with heavy calcium suggests that the CTO has arisen in a vessel with entrenched atheroma.<sup>7</sup> Guo et al. have suggested that the predominant virtual histology characteristic of CTO segments containing confluent necrotic core in contact with dilated guidewire track, is analogous to findings in non CTO vessels.<sup>8</sup>

The CTO has been traditionally divided into intimal and subintimal spaces which are key aspects of pathological information. The subintimal space lies external to the intimal layer but within the vessel architecture that includes the media (smooth muscle) and adventitia. During PCI, subintimal wire passage is within media between internal and external elastic membrane following the path of least resistance. Because of presence of histologically weak connective tissue, dissection in this area spreads easily and widely in both longitudinal and transverse direction. This subintimal space is considered to be the same space as the intramural hematoma in IVUS.<sup>9</sup>

Before formulating a strategy, the interventionist needs to perform a detailed review of the coronary angiography and scrutinize various regions of the artery carrying the CTO lesion (Table 3). In each segment of the CTO lesion, its complexity and severity depends on the pathological composition, the degree of calcification, tortuosity, length or thickness of the segments and at the end, the presence and sizes of the microchannels.<sup>10</sup>

**Table 1**

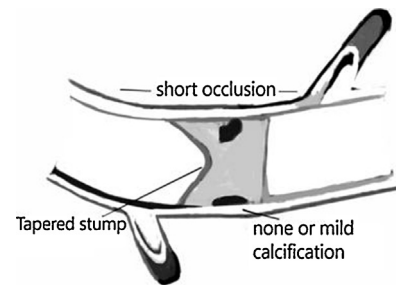
Chronological Pathology of a Coronary Chronic Total Occlusion.

1. Acute phase: Obstructed lumen typically consists of ruptured plaque and thrombus.
2. Early phase: Deposition of proteoglycan matrix
3. Late phase: Negative remodeling consisting of dense collagen and calcium deposit
4. Late phase: Without negative remodeling, the presence of large micro-channels suitable for wire crossing

**Table 2**

Histological Components of Chronic Total Occlusion.<sup>4</sup>

Consistency	Components of occlusion
Very soft	Recanalized lumen, microchannels
Soft	Thrombus, proteoglycans, cholesterol clefts
Firm	Collagen, elastin
Hard	Calcium



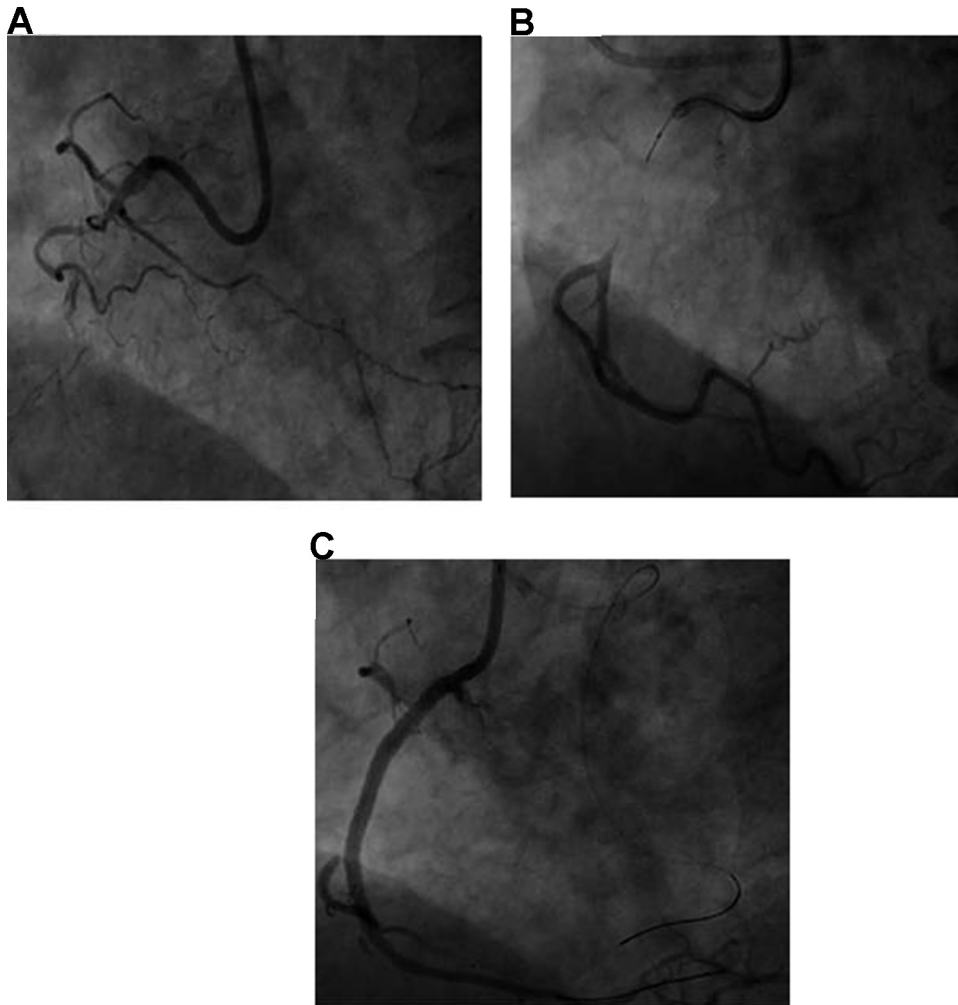
**Fig. 1.** Short segment CTO with tapered stump with mild or no calcification.

### 3. Physiological insight

The revascularization of CTO is embarked upon with the goal of restoration and maintenance of vessel patency. Residual impairment of vessel function has been suggested by the recent studies.<sup>11,12</sup> A reversible hibernation of vascular wall at distal coronary segments follows CTO PCI. The subsequent improvement in vascular wall function appears to be related to recovery of smooth muscle cell function rather than to improvement of endothelial function or to positive remodeling. This impairment of vasomotor tone after CTO recanalization suggests that IVUS is useful for the selection of stent size.<sup>11</sup> Less endothelial dysfunction is correlated with better collateral channel (CC) circulation assessed pre procedure by CC grade as demonstrated by Brugaletta et al.<sup>12</sup>

### 4. Proximal segment pathophysiology

At the outset, the coronary segment proximal to the CTO lesion is scrutinized for its length, tortuosity, calcification, and presence of CCs and SB. It is ideal to have a large 7 or 8-French extra back-up guide to accommodate a microcatheter, IVUS catheter and anchoring techniques should there be possible options in complex CTOs. Coaxiality of the guide with coronary artery ostium would decrease the risk of dissection and improve the probability of gear passage. If the proximal segment is too short and lacks enough landing zone for a large guide, it may be disengaged from the ostium. The heavy calcification of the proximal segment is another impediment to delivery of hardware to the proximal cap. This problem can potentially be overcome by using a buddy wire or the balloon (Fig. 3) or an anchor technique in which a balloon or wire is parked in the SB to immobilize the guide while advancing the hardware. If there is a SB at the proximal cap, then the wire may be preferentially deflected towards the SB rather than penetrating through the true lumen of the CTO.<sup>6</sup> If the CTO lesion is located in



**Fig. 2.** Coronary angiogram depicting occluded RCA with Grade 2 collateral channel.  
 A. Short segment CTO with tapered stump and microchannels  
 B. Navigation of Fielder XT guidewire with Finecross  
 C. Final result with deployment of drug eluting stent after successful microchannel tracking.

**Table 3**  
 Areas of Focus in a Chronic Total Occlusion Lesion.

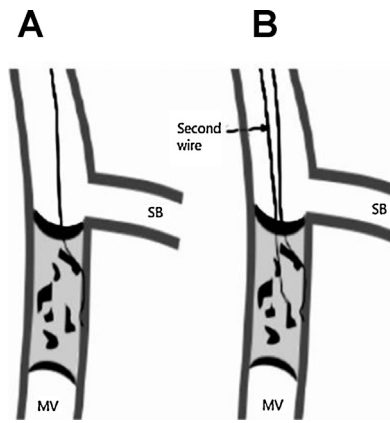
1. Proximal segment
2. Proximal cap
3. Body of lesion
4. Distal cap
5. Distal segment
6. Extraluminal pathology (subintimal tract, calcification)
7. Collateral channels

the distal segment of the coronary artery, then the tip of the guide can be extended using a guide catheter extender such as GuideLiner (Vascular Solutions, Minneapolis, MN, USA), Guidezilla (Boston Scientific, Natick, Massachusetts, USA) or Guidion (IMDS, Netherlands). A smaller straight guide could be inserted inside a larger guide in order to strengthen (called the daughter-in-mother, 5- in -6 or -6 in -7 technique) in an analogous way as a pre-formed guide extender). A long sheath, e.g. 45 cm increases passive support for any guide catheter diameter chosen.

### 5. Proximal cap pathology

The CTO lesion starts at the proximal cap that is made up of a dense concentration of collagen-rich fibrous tissue laced with

calcium. The cap frequently contains small recanalized channels (200  $\mu\text{m}$  or less in diameter), which are potential routes for successful wire crossing. Angiographically proximal cap with tapering stump is the starting place to probe the occlusion with a wire. In contrast, if the proximal cap has a blunt (non-tapered) occlusion, it is necessary to look in multiple projections for the 'dimple sign' that is the hallmark for entry point.<sup>9,10,13</sup> Dimples are lumina inside CTO or potential recanalization channels which may not necessarily be present in all blunt proximal cap. However, there is a higher probability of subintimal wire navigation with eccentrically oriented stump. The probability of wire crossing decreases in presence extensive bridging CCs (caput medusae).<sup>10</sup> The presence of a SB arising at the proximal cap will often repeatedly deflect the wire into it. However, due to high shear stress, a plaque is believed to be build up on the opposite side of the origin of a SB and this may point to the path of the main vessel course.<sup>10,13</sup> In several cases when the guide disengages with a wire tip pin-pointed to the center of the occlusion, inflation of over-the-wire [OTW] balloons coaxial anchor maybe recommended to increase wire support. Dedicated microcatheters (such as the Corsair, Caravel [Asahi Intecc, Aichi, Japan], and Turnpike [Vascular Solutions, MN, Minnesota], Finecross [Terumo, Japan]) have more flexible tapered tip (so increased penetrability), wider inner lumen (for manipulating wire) and the radio-opaque marker is at the tip



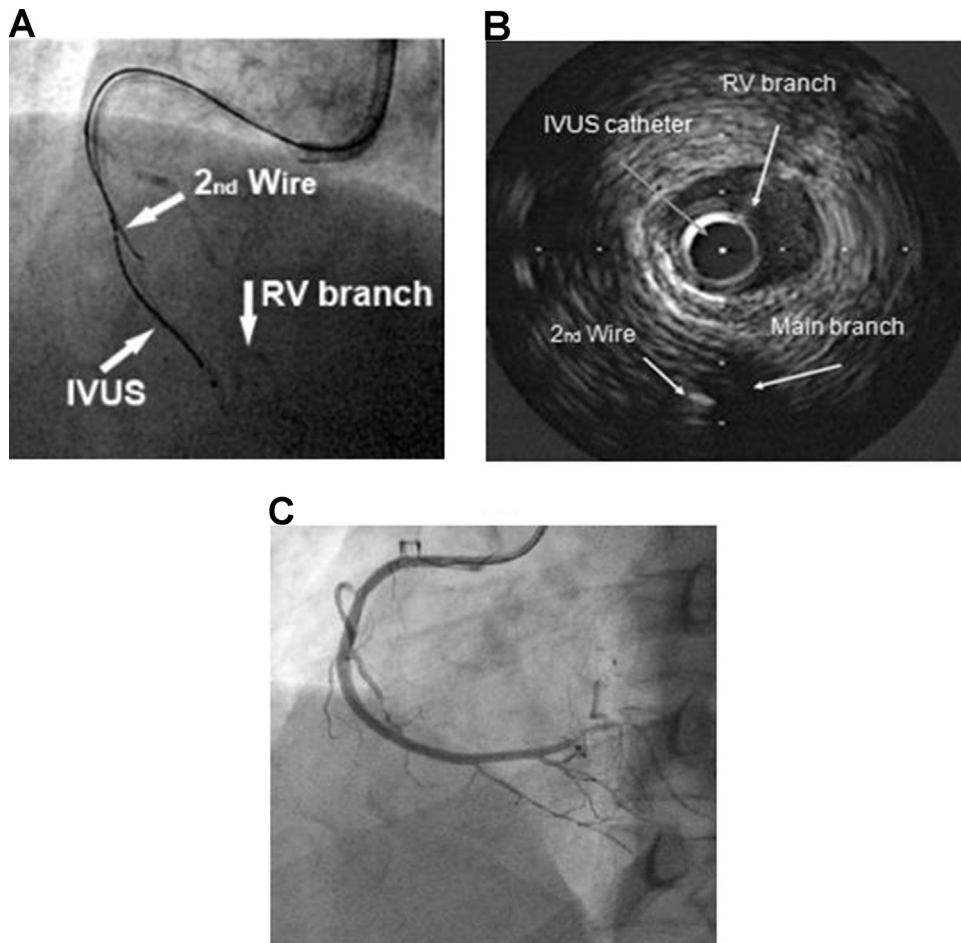
**Fig. 3.** Long segment CTO with heavy calcium.  
 A. Deflection of guidewire into subintimal space because of heavy calcium  
 B. Employment of parallel wire (2nd wire being stiffer and tapered tip) technique for successful navigation into true lumen.

(better assessment of the distance of lesion from microcatheter). The only advantage OTW balloons may have is that they are less expansive.<sup>14</sup> If the wire still fails to cross the proximal cap, IVUS can be helpful to examine plaque composition to facilitate direct wire entry. Even IVUS transducer can be parked in the SB which

provides information about the location of occlusion cap with entry point (seeking a dimple) and assists in navigating the wire into the distal true lumen (Fig. 4).<sup>15,16</sup>

**6. Pathophysiology of body**

The wire enters the body of the CTO lesion once it crosses the cap at the dimple or through a microchannel. The factors impacting further progress include: (1) the type of tissue (loose versus dense fibrous tissue), (2) the amount of calcium deposits, and (3) the availability of large microchannels. There is softer cholesterol laden material consisting of organized thrombus, extracellular matrix, smooth muscle cells and lipid deposits (so called loose tissue) present in a relatively recent CTO lesion.<sup>2,5,17</sup> This soft material contains endothelialized microchannels.<sup>17</sup> In contrast, in an older CTO, the occluded lumen is likely to have dense fibrocalcific areas with fewer microchannels.<sup>17</sup> The transformation of soft foam cell rich and cholesterol laden intimal plaque to hard fibrocalcific lesions in old CTOs might explain the difficulty in crossing these CTOs. A plaque is considered soft if it has more than fifty percent of cholesterol and macrophages with loose fibrous tissue, while a hard plaque is more fibrocalcific with more than fifty percent collagen/calcium deposits filling the true lumen.<sup>5,10</sup> Continuous loose tissue is frequently seen in the tapered entry type of CTO as well as in the short-occlusive-length CTO; the loose tissue is located continuously from the proximal to the distal



**Fig. 4.** Side branch IVUS guided wire crossing.  
 A. Manipulation of second guidewire using IVUS catheter in RV branch in CTO of RCA  
 B. Second guidewire is in true lumen of RCA as depicted in IVUS imaging  
 C. Final result after overlapping DES implantation

end.<sup>5,10</sup> In the middle of these loose or hard tissues, along the body of the CTO lesions, there are microchannels.<sup>2,3</sup>

These neovascularisation channels are approximately 200  $\mu\text{m}$  in diameter, which is slightly smaller than the tip of a tapered wire. Their wall is made of a single cell layer so they are very fragile. In the remodeled type of CTO secondary to the shrinkage of the internal elastic lamina, the number of microchannels is low. In the non-remodeled type, the CTO lesion has less fibrous tissue with numerous and larger microchannels. These microchannels often extend to the small SB and vaso vasorum, whereas others continue longitudinally from the proximal to the distal lumen.<sup>5,10</sup> The longitudinal continuity of microchannels extends to approximately 85% of the total CTO length.<sup>5,10,18</sup> These pathological characteristics provide the basis for many of the CTO PCI techniques. The length of the occluded segment is the most important factor which impacts the success of crossing a CTO. A length greater than 20 mm was a stronger predictor of failure to cross the occlusion than calcification, tortuosity, blunt stump, or a previous unsuccessful attempt.<sup>10,19,20</sup>

### 6.1. Antegrade loose tissue tracking (ALTT)

Both histopathological examinations and animal CTO research models demonstrate that angiographically occluded lesions contain loose tissue segments in both short and long-duration CTO.<sup>2,5</sup> Strauss et al<sup>21</sup> suggest that these cases develop a potential wire track through longitudinal reconstruction of neovascularization. It is recommended to start CTO PCI with a low tip load wire to enter loose connective tissue such as Fielder XT, XTR, XTA, Sion Black wire (Asahi Intec, Aichi, Japan), Wizard 78 (Lifeline, Japan), Gaia 1 (Asahi Intec, Aichi, Japan). Once entered, this type of wire will track tissue preferentially with low resistance rather penetrating into hard plaque. PIKACHU (Prospective Multicenter Registry of IKAzuchi-X for Chronic Total Occlusion) registry supports this concept where approximately 70% of CTOs could be crossed with intermediate stiffness 0.010" hydrophilic wire.<sup>22</sup> Wire handling for ALTT is quite similar to acute myocardial infarction cases, where it can be advanced easily and smoothly by multiple rotations of the wire tip.<sup>14</sup> ALTT is further supported by a technique<sup>23</sup> where contrast is injected via an OTW balloon or microcatheter to enlarge and connect the microchannels already existing within the occlusion. Strauss et al. has further developed this hypothesis by demonstrating the potential of collagenase as therapeutic agent in CTO PCI. The expectation is that collagenase would degrade connective tissue for rapid and reliable wire navigation. A dose finding study reported excellent clinical results.<sup>24</sup> In TOSCA-5 trial, 75 CTO patients with prior documented failed PCI were randomized to placebo control or either 900  $\mu\text{g}$  or 1200  $\mu\text{g}$  intra-microcatheter injection of the collagenase the day before they underwent antegrade CTO PCI. While patients in the study group had more successful soft wire crossing, all patients had similar successful PCI.<sup>25</sup>

### 6.2. Antegrade intentional intimal plaque tracking (AIIPT)

Once the wire gets stuck and/or ALTT seems impossible, it should be manipulated into the intimal plaque, called as AIIPT. For this purpose, a stiff tapered wire with higher penetration force is preferable. The author prefers to use Gaia 2 wire (Asahi Intec, Aichi, Japan) due to its excellent one-to-one torque transmission which enables the operator to steer through tortuous arteries. The resistance of the intimal tissue surrounding the wire tip is relatively high but homogenous so the wire gets deflected towards the true lumen rather than the subintimal space.<sup>16</sup> The use of integrated imaging data from IVUS, computed tomography, and angiography are useful adjuncts for enhanced understanding of vessel anatomy and plaque composition for successful AIIPT.

Yet even with intimal plaque tracking, the existence of high-resistance plaques such as fibrocalcific or dense calcium islands prevents wire navigation across to the whole body of the CTO lesion resulting in procedural failure. Such high-resistance plaques can possibly be punctured by direct pressure at a point with controlled and limited wire rotation of the stiff wires such as Miracle 12, Conquest Pro 9, 12, Gaia 3 (Asahi Intec, Aichi, Japan) and Progress 200 (Abbott Vascular, USA). In presence of proximal SB, the wire position at the CTO entry point can be visualized by using IVUS.

### 6.3. Antegrade subintimal tracking and reentry (ASTR)

The subintimal space is constrained by fibrous and calcified tissue derived from atheroma on the luminal aspect and elastic adventitia on the external aspect of the vessel. A free movement of wire tip during rotation and lesser resistance to advance is a mark of a subintimal position (the wire turns around the vessel lumen, giving the appearance of lengthening the tip curve). The wire is considered usually to be in the false lumen when the resistances of the wire tip to advancement decreases.<sup>10</sup> Visual appearance of the wire tip and retrograde injections are of paramount importance in locating the wire.

With the advancement of the wire into the subintimal space, the probability of successful antegrade CTO PCI decreases considerably without dedicated reentry techniques and/or technologies, because intimal plaque located between the true lumen and subintimal is more resistant than subintimal tissue. An angiographic sign of antegrade subintimal tracking is a "Sigmoid Curve Sign", reflecting spiraling course of the wire around the vessel.<sup>9</sup> If it is suspected, caution should be exercised while visualizing the situation by contrast or IVUS both of which carry the risk of expanding the subintimal space and compressing the distal true lumen. Once the subintimal space collapses, successful wire crossing becomes more difficult and further ischemic myocardial injury may ensue. Even if the wire enters the subintimal space, parallel wire technique and/or IVUS guided antegrade wiring still allow the return of the intimal plaque tracking. While using the parallel wire technique, first wire is left in subintimal space or where it got stuck within the plaque. A second wire, preferably stiffer and tapered tip, is advanced more easily to the direction of true lumen. Reliable subintimal tracking dissection is achieved by looping a polymer-jacketed Fielder XT (Asahi Intec, Aichi, Japan) or Pilot 200 (Abbott Vascular, USA) wire (knuckle wire) and pushing it into a subintimal space that connects with distal true lumen.<sup>26</sup> This technique, introduced by Antonio Colombo, is called subintimal tracking and re-entry (STAR) technique. This technique is reserved as a last-ditch bailout option in CTO PCI due to loss of SB and high rates of in-stent restenosis. Finally, there are several reentry techniques with the common idea of penetrating the tissue between the subintima and distal true lumen using a stiff wire (Mini-subintimal tracking and re-entry<sup>27</sup> or limited antegrade subintimal tracking [LAST]<sup>28</sup> or dedicated reentry device (The CrossBoss and Stingray system [Boston Scientific; Natick, Massachusetts, USA]).<sup>29</sup> Limited dissection/re-entry strategies are preferred, as they limit SB loss, stent length, and the risk for restenosis. Occasionally, subintimal hematoma due to disruption of neovascular channels or filling up of the space with blood at systemic arterial pressure, can compress the distal true lumen, requiring aspiration through an OTW balloon or microcatheter for decompression to enable distal true lumen re-entry (subintimal transcatheter withdrawal [STRAW] technique).<sup>16</sup> In some cases both the CrossBoss catheter and knuckle wire ("Knuckle-Boss technique") may be used to navigate beyond SB or manipulate through calcific or tortuous anatomy. The optimal role and timing of ASTR continues to be the

subject of debate. Good candidates for primary ASTR strategy are those with well defined proximal cap, long lesion ( $\geq 20$  mm) with large caliber distal vessel and good distal re-entry site proximal to SB.

## 7. Distal cap pathology

An analogous distal cap is recognized as a point of difficulty and resistance during wire passage because of chronic buildup of hard plaque around the true lumen. It is conceptually important for retrograde technique as it is less resistant compared to the proximal cap. Another important piece of information is where the collateral enters the arterial segment beyond the CTO. Is it at its distal or mid segment? The suspicion is, if there is any plaque or stenosis at the distal end, then the collaterals would enter the artery in the middle of the CTO segment.<sup>9</sup> Small and irregular vessels downstream beyond the distal cap may represent underfilling, profound spasm, or diffuse atheroma. It is difficult to identify the distal cap by histology or by IVUS. In any case, a small irregular vessel is difficult to enter by antegrade wire escalation or dissection and reentry, and is a reason to consider the retrograde approach.

## 8. Collateral channel (cc) biology

Collateral channels (CCs) originate as arterioles connecting the vascular beds of visible coronary arteries. With increased chronicity of an occlusion, these small arteriole collaterals undergo remodeling to become muscular arteries known as arteriogenesis.<sup>30</sup> The success of CTO PCI has improved to  $>90\%$  in the hands of CTO masters with adoption of retrograde approach that essentially uses the backdoor to pass the guidewire from the donor artery via CCs to penetrate the distal CTO cap. CCs can be as large as 800  $\mu\text{m}$  (0.031"). Only those more than 100  $\mu\text{m}$  are visible angiographically.<sup>31</sup> After PCI of the culprit artery, reduction in flow of the feeding CCs is more rapid in the intramyocardial vessels than in the large caliber epicardial CCs. These CCs do not regress completely, but protection offered by them against subsequent events in the previously occluded vessels, most notably stent thrombosis, is quite limited.<sup>32,33</sup> The best CC would be clearly visible, less tortuous collaterals by super-selective injection, exemplified by Dr. Werner's CC grade 1 or 2 (CCs are graded as follows: CC0, no continuous connection, CC1, continuous thread-like connection; and CC2, continuous, small side branch-like connection).<sup>34</sup> Rentrop<sup>35</sup> classifies CC as grade 0, no visible filling of any collateral channel; grade 1, filling of side branches of the infarct-related artery, grade 2, partial filling of the epicardial vessel of the infarct-related artery, grade 3, complete collateral filling of the epicardial vessel. If there are antegrade bridging CCs from the proximal segment, extra care should be taken to avoid damage of these microchannels. The chance of successful wire crossing is low because these intracoronary CCs consist of dilated vasa vasorum which is very fragile and easily perforated. Manipulation in the proximal segment across the length of the CTO becomes relatively safer in presence of retrograde CCs.<sup>10</sup>

## 9. Utilization of CCs for retrograde wiring

Among the potential CCs for retrograde wiring, the septal CCs are safer and should be the default choice whenever possible. Complications such as wire perforation in these CCs may not be a major problem and resolves spontaneously. However, a haematoma in a septal branch could cause hypotension due to obstruction of the left ventricular outflow tract.<sup>10</sup> Considerable septal tortuosity is a major limitation to wire advancement,

whereas size is less so. Any CC when entered with a microcatheter may cause distant ischemia and require removal of the catheter. During the wire manipulation in epicardial CC, there is some risk of perforation which is a serious complication and can rapidly cause tamponade. An attempt can be made to control this perforation by a balloon tamponade in the native vessel proximal to epicardial CC. Furthermore, balloon dilation of this CC should always be avoided as it may cause vessel rupture and cardiac tamponade. Advancing microcatheter and coiling from both sides that feed the CC might to be required to address perforations.<sup>36</sup> Alternatively it could be embolized with subcutaneous fat, clotted blood or thrombin. It is advisable to perform dual contrast injection from both sides to confirm that there is no bleeding from the antegrade or retrograde side. In patients who have already had coronary artery bypass graft, the chance for tamponade is lower because of the scarring and adherence of the pericardium to epicardium decreasing the possibility of global tamponade.<sup>36</sup> However, some case reports have demonstrated that there is potential for the development of loculated effusions that may compress the cardiac chambers,<sup>37</sup> or the development of intramural hematoma with avulsion of the epicardial arteries as a consequence of vessel perforation in post-CABG patients.<sup>38</sup> No procedure is 100% effective and knowing when to stop a procedure is of paramount importance. The retrograde approach is certainly not burdening the interventionists, rather than a sine qua non of CTO PCI success in spite of some catastrophic complications, many of which the author can see, are easily preventable.<sup>39</sup>

### 9.1. Retrograde intimal plaque tracking vs subintimal plaque tracking

As the distal cap is less rigid than proximal one,<sup>3</sup> intimal plaque tracking is observed up to 60% in IVUS.<sup>40</sup> The retrograde wire should be carefully navigated to enter into proximal true lumen directly (retrograde wire crossing) once intimal plaque tracking is suspected. If the retrograde wire is stuck or its position is unsure, it still can be used as a landmark to further advancement of the antegrade wire into distal true lumen (kissing wire technique).<sup>41</sup> Retrograde wire is easily advanced within the subintimal space because of low tissue resistance. Balloon dilatation is performed once antegrade and retrograde wire tip overlap. The created lumen finally allows wire crossing after connecting both antegradely and retrogradely directed wires. The balloon is inflated either on the retrograde wire using "controlled antegrade and retrograde subintimal tracking (CART)" or on the antegrade wire using "reverse CART" technique. Subsequently there are four possible fates for both antegrade and retrograde wire requiring different strategies (Table 4).<sup>42</sup> The most favourable scenario arises when direction of both antegrade and retrograde wires remain subintimal. The two sides are usually connected when antegrade space is enlarged via balloon dilatation. This is most widely used retrograde dissection re-entry technique called as reverse CART.<sup>43,44</sup> The least favourable scenario arises when antegrade wire is intimal and retrograde wire subintimal. The solution is to create a space by aggressive antegrade dilatation of CTO body for successful navigation of retrograde wire through fenestrations created by aggressive dilatation. When both the antegrade and retrograde wire are intimal, either wire is advanced antegradely or retrogradely with the opposing wire as a landmark towards the opposite channel called as "kissing wire technique". Antegrade balloon dilatation is the next strategy for retrograde navigation of wire. If this fails, the author purposefully undertakes antegrade or retrograde subintimal tracking. A CART procedure has been advocated when the antegrade wire is subintimal and retrograde wire intimal.

**Table 4**  
Retrograde wiring strategies based on guidewire position.

Guidewire Position	Preferred Strategy
Both antegrade and retrograde intimal	1.Kissing wire technique 2. Antegrade balloon dilatation 3. Intentional antegrade or retrograde subintimal tracking
Both antegrade and retrograde subintimal (most favourable)	1.Reverse controlled antegrade or retrograde subintimal (CART) using adequately sized antegrade balloon
Antegrade intimal and retrograde subintimal	1. Aggressive antegrade balloon dilatation for CTO body disruption and opening of a passage
Antegrade subintimal and retrograde intimal	1. Reverse CART 2. CART as second option with caution

**10. Global approach (putting it all together)**

The goal of global approach (putting it all together) has been integration of skillsets to standardize the procedure, and improve outcomes by exploiting conditional probabilities of leveraging approaches when they are most likely to be safe and successful. Four questions are reviewed on the initial angiogram: (1) Is the proximal cap of the CTO apparent by angiography or IVUS? (2) Is the lesion length <20 mm or ≥20 mm? (3) What is the quality of the distal target (size, visibility, involvement of meaningful outflow branches)? and (4) What is the suitability of collaterals for retrograde intervention (for the interventionist in question)? Based on these answers, the initial and provisional strategies can be chalked out (Fig. 5).<sup>43,45</sup>

**11. Conclusion**

CTO represents one of the most difficult procedural challenges encountered by interventionists. Once thought to be untreatable by PCI, CTO is now being successfully opened with improvement in

physician experience and innovation. The clinical experience of CTO PCI outnumber the studies of pathophysiology by post mortem or IVUS. Even this narrow knowledge base has led to tremendous progress in CTO PCI outcomes. “Putting it all together” algorithm utilizing pathophysiological insights, aims at a structured strategies to approach every lesion anticipating success. Wires can successfully traverse the microchannels within the occluded lumen, or subintimal space can be exploited by use of dissection and reentry technology. Further technical developments based upon complete understanding of pathophysiology is critical to shorten the procedure times and enhance procedural safety and efficacy. Future studies of CTO morphology may yet yield in-depth insights into the lesion development that sheds light on a deeper interpretation of the elusive distal cap by IVUS. Expanding the knowledge base may further lead to successful navigation in to the distal true lumen in this fascinating endeavor.

**Funding**

Nil.

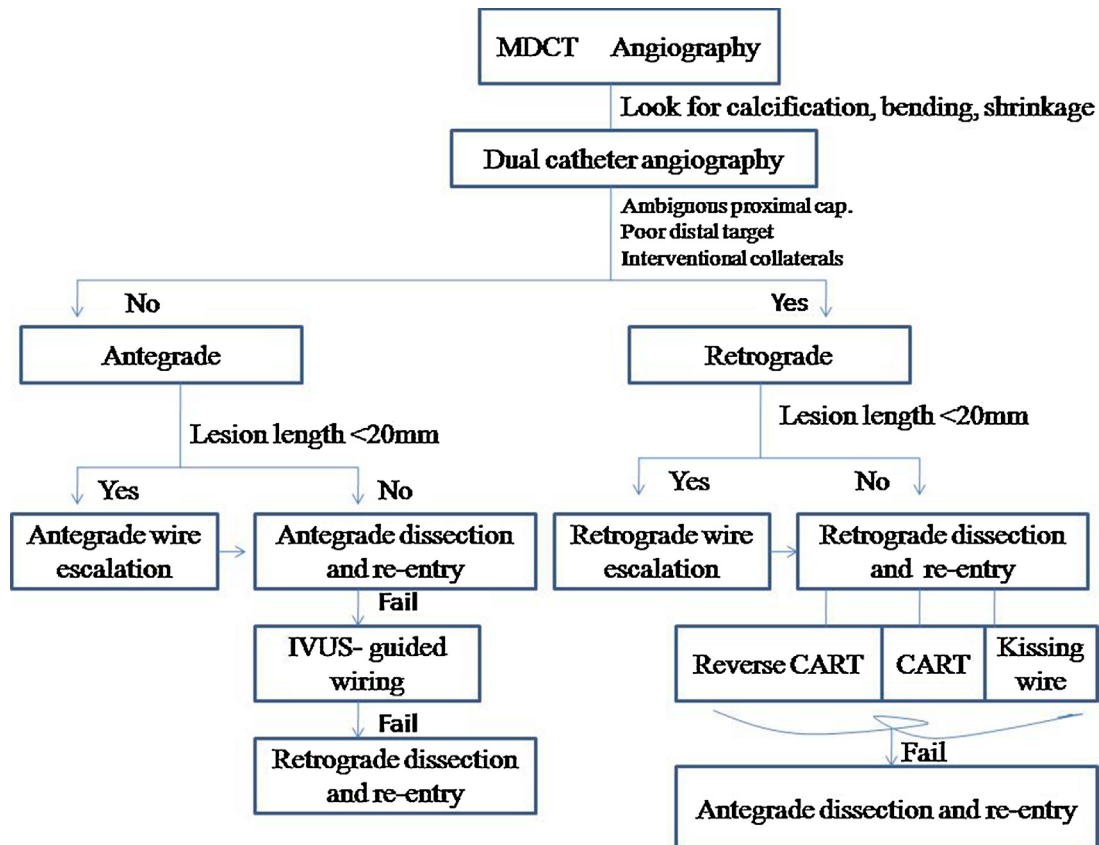


Fig. 5. Algorithm of global approach to CTO PCI<sup>42,45</sup>.

## Conflicts of interest

Nil.

## References

- Bufe A, Haltern G, Dinh W, et al. Recanalization of coronary chronic total occlusions with new techniques including the retrograde approach via collaterals. *Neth Heart J*. 2011;19:162–167.
- Srivatsa SS, Edwards WD, Boos CM, et al. Histological correlates of angiographic chronic total coronary artery occlusions: influence of occlusion duration on neovascular channel patterns and intimal plaque composition. *J Am Coll Cardiol*. 1997;29:955–963.
- Godino C, Carlino M, Al-Lamee R, et al. Coronary chronic total occlusion. *Minerva Cardioangiol*. 2010;58:41–60.
- Mishra S. Unravelling the mystique of CTO interventions: tips and techniques of using hardware to achieve success. *Indian Heart J*. 2017;69:266–276.
- Katsuragawa M, Fujiwara H, Miyamae M, et al. Histologic studies in percutaneous transluminal coronary angioplasty for chronic total occlusion: comparison of tapering and abrupt types of occlusion and short and long occluded segments. *J Am Coll Cardiol*. 1993;21:604–611.
- Fujii K, Ochiai M, Mintz GS, et al. Procedural implications of intravascular ultrasound morphologic features of chronic total coronary occlusions. *Am J Cardiol*. 2006;97:1455–1462.
- Suzuki T, Hosokawa H, Yokoya K, et al. Time-dependent morphologic characteristics in angiographic chronic total coronary occlusion. *Am J Cardiol*. 2001;88:167–169.
- Guo J, Maehara A, Mintz GS, et al. A virtual histology intravascular ultrasound analysis of coronary chronic total occlusions. *Catheter Cardiovasc Interv*. 2013;81:464–470.
- Sumitsuji S, Inoue K, Ochiai M, et al. Fundamental wire technique and current standard strategy of percutaneous intervention for chronic total occlusion with histopathological insights. *JACC Cardiovasc Interv*. 2011;4:941–951.
- Tran P, Phan H, Shah S, et al. Applied pathology for interventions of coronary chronic total occlusion. *Curr Cardio Rev*. 2015;11:273–276.
- Galassi AR, Tomasello SD, Crea F, et al. Transient impairment of vasomotion function after successful chronic total occlusion recanalization. *J Am Coll Cardiol*. 2012;59:711–718.
- Brugaletta S, Martin-Yuste V, Padro T, et al. Endothelial and smooth muscle cells dysfunction distal to recanalized chronic total coronary occlusion and relationship with the collateral connection grade. *JACC Cardiovasc Interv*. 2012;5:170–178.
- Nguyen T, et al. Chronic total occlusion. *Practical handbook of advanced interventional cardiology: tips and tricks*. 4th ed. [ISBN: 978-0-470-67047-7].
- Mishra S. Language of CTO interventions-focus on hardware. *Indian Heart J*. 2016;68:450–463.
- Dash D, Li Li. Intravascular ultrasound guided percutaneous coronary intervention for chronic total occlusion. *Curr Cardio Rev*. 2015;11:323–327.
- Dash D. Guidewire crossing techniques in coronary chronic total occlusion intervention: a to Z. *Indian Heart J*. 2016;68:410–420.
- Touma G, Ramsay David Weaver J. Chronic total occlusions-current techniques and future directions. *Int J Cardiol Heart Vasc*. 2015;7:28–39.
- Munce NR, Strauss BH, Qi X, et al. Intravascular and extravascular microvessel formation in chronic total occlusions a micro-CT imaging study. *J Am Coll Cardiol Img*. 2010;3:797–805.
- Di Mario C, Werner GS, Sianos G, et al. European perspective in the recanalisation of Chronic Total Occlusions (CTO): consensus document from the EuroCTO Club. *EuroIntervention*. 2007;3:30–43.
- Morino Y, Abe M, Morimoto T, et al. Predicting successful guidewire crossing through chronic total occlusion of native coronary lesions within 30 minutes the J-CTO (multicenter CTO registry in Japan) score as a difficulty grading and time assessment tool. *JACC Cardiovasc Interv*. 2011;4:213–221.
- Strauss BH, Segev A, Wright GA, et al. Microvessels in chronic total occlusion: pathways for successful guidewire crossing. *J Interv Cardiol*. 2005;18:425–436.
- Matsukage T, Masutani M, Yoshimachi F, et al. A prospective multicenter registry of 0.010-inch guidewire and compatible system for chronic total occlusion: the PIKACHU registry. *Catheter Cardiovasc Interv*. 2010;75:1006–1012.
- Carlino A, Latib A, Godino C, et al. CTO recanalization by intraocclusion injection of contrast: the microchannel technique. *Catheter Cardiovasc Interv*. 2008;71:20–26.
- Strauss BH, Oshero AB, Radhakrishnan S, et al. Collagenase total occlusion-1 (CTO-1) trial. A phase I, dose-escalation, safety study. *Circulation*. 2012;125:522–528.
- Buller CE. TOSCA-5. A prospective, randomized trial evaluating collagenase infusion in patients with coronary artery chronic total occlusions. .
- Colombo A, Mikhail GW, Michev I, et al. Treating chronic total occlusions using subintimal tracking and reentry: the STAR technique. *Catheter Cardiovasc Interv*. 2005;64:407–411.
- Galassi AR, Tomasello SD, Costanzo L, et al. Mini-STAR as bail out strategy for percutaneous coronary intervention of chronic total occlusion. *Catheter Cardiovasc Interv*. 2012;79:30–40.
- Lombardi WL. Retrograde PCI. What will they think of next? *J Invasive Cardiol*. 2009;21:543.
- Mogabgab O, Patel VG, Michael TT, et al. Long-term outcomes with use of the CrossBoss and stingray coronary CTO crossing and re-entry devices. *J Invasive Cardiol*. 2013;25:579–585.
- Schaper W. Collateral circulation. *Basic Res Cardiol*. 2009;104:5–21.
- Fulton WFM. Arterial anastomoses in the coronary circulation II. Distribution, enumeration and measurement of coronary arterial anastomoses in health and disease. *Scott Med J*. 1963;8:466–474.
- Werner GS, Richartz BM, Gastmann O, et al. Immediate changes of collateral function after successful recanalization of chronic total coronary occlusions. *Circulation*. 2000;102:2959–2965.
- Irving J. CTO pathophysiology: how does this affect management? *Curr Cardio Rev*. 2014;10:99–107.
- Werner GS, Ferrari M, Heinke S, et al. Angiographic assessment of collateral connections in comparison with invasively determined collateral function in chronic coronary occlusions. *Circulation*. 2003;107:1972–1977.
- Rentrop KP, Cohen M, Blanke H, et al. Changes in collateral channel filling immediately after controlled coronary artery occlusion by an angioplasty balloon in human subjects. *J Am Coll Cardiol*. 1985;5:587–592.
- Dash D. Retrograde coronary total occlusion intervention. *Curr Cardio Rev*. 2015;11:291–298.
- Karatasakis A, Akhtar YN, Brilakis ES. Distal coronary perforation in patients with prior coronary artery bypass graft surgery: the importance of early treatment. *Cardiovasc Revasc Med*. 2016;17:412–417.
- Quan VH, Stone JR, Couper GS, et al. Coronary artery perforation by cutting balloon resulting in dissecting subepicardial hematoma and avulsion of the vasculature. *Catheter Cardiovasc Interv*. 2005;64:163–168.10.1002/ccd.20249.
- Dash D. Problems encountered in retrograde recanalization of coronary chronic total occlusion: should we lock the backdoor in 2018? *Indian Heart J*. 2017;10.1016/j.ihj.2017.11.014.
- Tsujita K, Maehara A, Mintz GS, et al. Intravascular ultrasound comparison of the retrograde versus antegrade approach to percutaneous intervention for chronic total occlusions. *JACC Cardiovasc Interv*. 2009;2:846–854.
- Saito S. Different strategies of retrograde approach in coronary angioplasty for chronic total occlusion. *Catheter Cardiovasc Interv*. 2008;71:8–19.
- Dash D. Putting it all together: a global approach to chronic total occlusion revascularization. *J Indian Coll Cardiol*. 2016;6:152–157.10.1016/j.jicc.2016.12.003.
- Dash D. Retrograde coronary chronic total occlusion intervention using a novel reverse controlled antegrade and retrograde subintimal tracking. *J Interv Cardiol*. 2016;29:70–74.
- Dash D. The retrograde recanalization of coronary chronic total occlusion: approaching through the backdoor. *J Heart Lung Cir*. 2017;1:e104.
- Brilakis ES, Grantham A, Rinfret S, et al. A percutaneous treatment algorithm for crossing coronary chronic total occlusions. *JACC Cardiovasc Interv*. 2012;5:367–379.