



OPEN ACCESS

Flexor tendon laceration of the hand from opening a glass ampoule

Emmanuel Pantaleon Estrella ¹, Sarah Olivia Javier Gavino ²

¹Institute of Clinical Epidemiology, University of the Philippines Manila, Manila, Philippines

²Department of Orthopedics, University of the Philippines-Philippine General Hospital, Manila, Philippines

Correspondence to

Dr Sarah Olivia Javier Gavino; sjgavino@alum.up.edu.ph

Accepted 23 September 2022

SUMMARY

Sharps and needlestick injuries are serious work-related injuries to the hand in healthcare workers (HCWs). We present two cases of HCWs with hand injuries from opening a medicinal glass ampoule. The index finger (IF) was involved in both cases, with an associated flexor tendon injury, presenting as inability to flex the proximal and distal interphalangeal joints. Sensation was intact, and radiographs showed no foreign body.

The surgical repair of the flexor tendon injury was carried out using the Wide-awake Local Anaesthesia No Tourniquet technique. The quality of the repair was tested intraoperatively. Physiotherapy involved gradual progression of finger flexion from 30% to 50% to full range of motion. At 36 and 42 months follow-up, they regained the IF range of motion and returned to work. Flexor tendon injuries from opening medicinal glass ampoules are rare but can be devastating, with a long rehabilitation process after surgical repair.

BACKGROUND

Sharps and needlestick injuries are serious work-related injuries to the hand in healthcare workers (HCWs), with a reported prevalence of 20.9%–94%.¹ In one study in China comprising 360 hospitals, a total of 18 344 sharp injuries were reported out of 223 149 respondents.² Nurses usually have the highest prevalence among HCWs.^{2–4} Single-use syringes cause more injuries than any other instrument. In particular, hand injuries on HCWs secondary to their opening of medicinal glass ampoules have been reported in a previous study by Parker⁵ and Carraretto *et al*⁶ to be 6%. Opening glass ampoules exposes HCWs to percutaneous injuries of the hand due to the vertical projections (spikes) that can cause lacerations⁶ wherein the index finger (IF) is the most commonly injured.⁵ In the clinical setting, flexor tendon laceration after opening a glass ampoule has not been given much consideration compared with needlestick and scalpel injuries probably because of the rarity of the injury. Even though ampoule injuries have been reported to account for up to 42% of all sharp injuries, there has only been one report of a severed flexor tendon in an anaesthetist.⁷

Flexor tendon lacerations are uncommon injuries but remain to be one of the most challenging injuries to treat, especially zone II injuries (figure 1).^{8–9} In established flexor tendon lacerations, surgical repair is usually warranted with the traditional manner of using a tourniquet and the patient either sedated under regional or general anaesthesia. In such cases, active movement of the

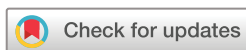repaired tendon is not possible. Recently, the use of Wide-awake Local Anaesthesia (lidocaine with epinephrine as a local anaesthetic) No Tourniquet (WALANT) has gained popularity, in which patients can actively flex their fingers after the tendon repair during the surgery to test the strength of the repair, to assess tendon gliding within the tendon sheath and to create a bloodless field without the use of a tourniquet.¹⁰ If the quality of the tendon repair is assessed to be inadequate, the surgeon can revise the repair while still in the operating room. This procedure has been reported to greatly improve the results of flexor tendon repair and facilitate early rehabilitation.¹¹

CASE PRESENTATION

Two separate HCWs consulted for hand injuries after opening a medicinal glass ampoule. In both instances, the IF was involved with associated flexor tendon laceration. Patient 1 is a right-handed female in her 20s, who sustained a right IF laceration while opening a medicinal glass ampoule. She was assisting a doctor during anaesthesia induction, and was not wearing any gloves when she opened the glass ampoule. Patient 2 is also a right-handed female in her 20s, who was referred 1.5 weeks after the accident. She was opening a medicinal glass




Figure 1 In patient 2, the IF was in an extended position compared with the other fingers. The healed laceration (black line) is seen within the zone II of the hand (shaded area). IF, index finger.



© BMJ Publishing Group Limited 2022. Re-use permitted under CC BY-NC. No commercial re-use. See rights and permissions. Published by BMJ.

To cite: Estrella EP, Gavino SOJ. *BMJ Case Rep* 2022;**15**:e250439. doi:10.1136/bcr-2022-250439

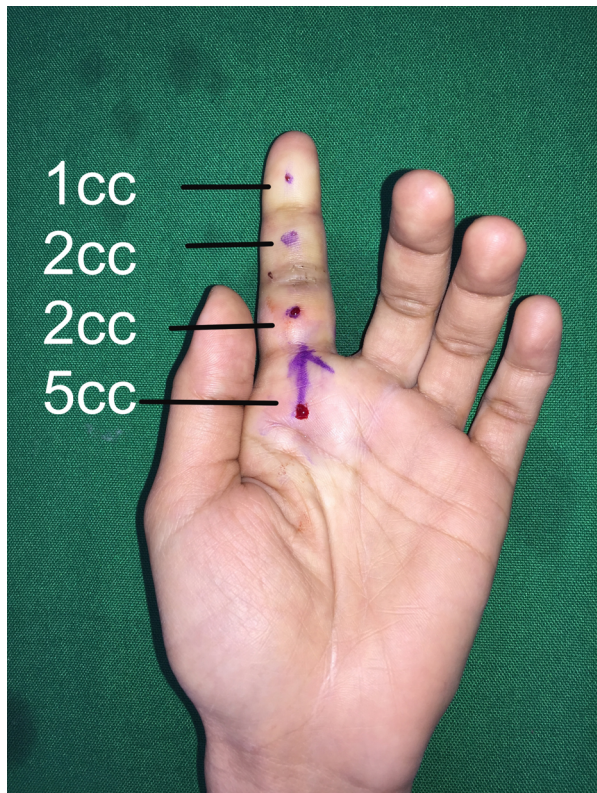


Figure 2 A solution of 10 cc of 1% lidocaine with 1:100 000 epinephrine was injected. The volume of the anaesthesia is indicated per area of the finger where the incision will be made.

ampoule and sustained a laceration on the left IF. The wound was initially managed with suturing. She continued to work and was eventually seen by a general orthopaedic surgeon who referred her to a specialist. In both instances, the opening of the glass ampoule was facing outward. Both patients were unable to flex the proximal and distal interphalangeal joints (PIP and DIP) of the IF, and the site of the laceration was at zone II (figure 1). This physical examination confirmed a complete flexor tendon laceration of the flexor digitorum profundus (FDP) and the flexor digitorum superficialis (FDS). Sensory testing showed intact sensation for the involved fingers. Radiographs showed no foreign body. No further imaging, such as an ultrasound, was done since the physical examination was sufficient for the diagnosis of both cases.

TREATMENT

Both patients were advised surgical exploration and repair. In cooperative patients, surgical repair of the severed flexor tendon can be done while the patient is awake, using the WALANT technique, with 1% lidocaine with 1:100 000 epinephrine, injected to areas where the surgical incision will be made to achieve local anaesthesia and haemostasis (figure 2). Before surgery, the patients were instructed on how to flex the finger for when they will be prompted intraoperatively after the repair. The planned skin approach was done using a Brunner (zigzag) incision to optimise exposure of the tendon (figure 3). The digital nerves were also identified to protect them. Once the lacerated FDP and FDS tendons were identified, a four-core cruciate tendon repair using 4-0 non-absorbable suture with 6-0 non-absorbable circumferential suture on the FDP was done, and a modified Kessler suture technique on the FDS was done (figure 4A,B). Patients

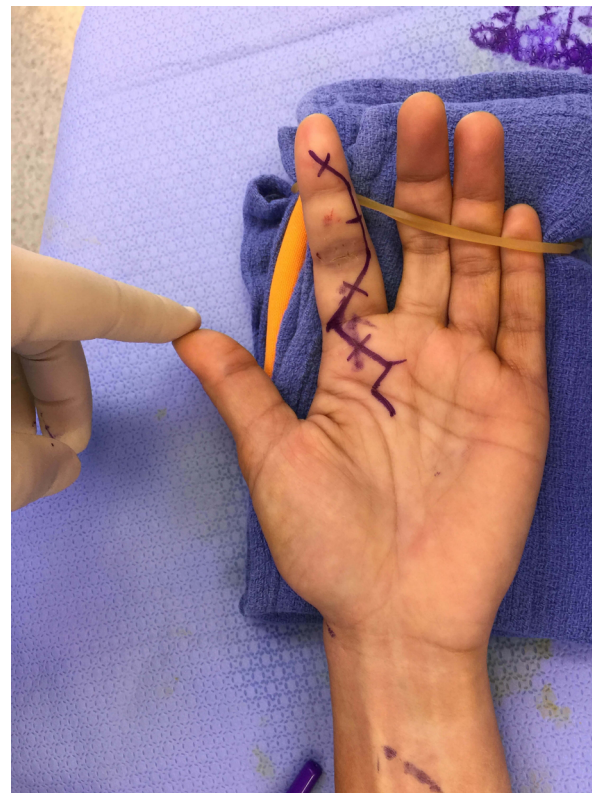


Figure 3 A Brunner (zigzag) incision was planned out to maximise the exposure of the cut tendons for repair.

were asked to flex the finger to full range of motion to assess the repair (videos 1 and 2). Once the repair was adequate, the wounds were closed with non-absorbable sutures, and a dorsal blocking splint was applied to protect the repair. Physiotherapy was started within the week and all the fingers were allowed to flex actively at 30%–50% of the normal range. By the 3rd–4th week, this increased to 75% of full flexion. The flexion was then continued passively, using the other hand to achieve full range of motion (video 3), making sure not to strain too much during active flexion. This was done every 3–4 hours.

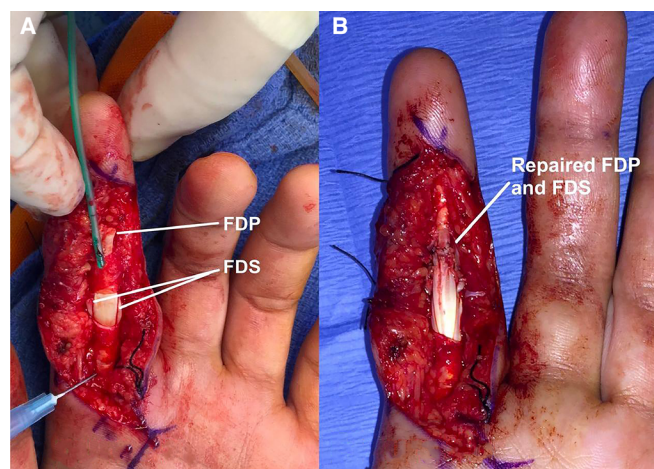
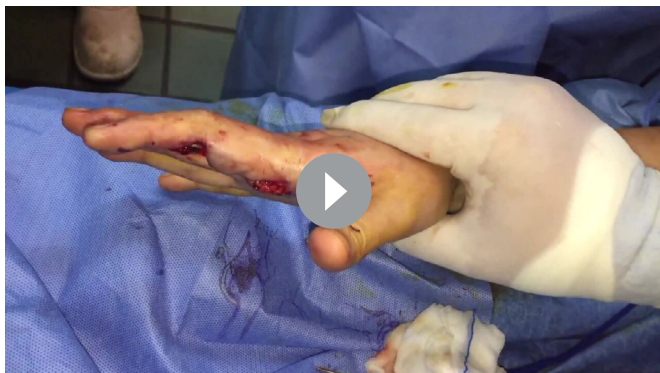

Figure 4 (A,B) Intraoperative pictures of patient 2. In (A), the transected flexor digitorum profundus (FDP) and the two slips of the flexor digitorum superficialis (FDS) were identified. In (B), the repaired FDP and FDS are shown.



Video 1 Patient 1 intraoperative range of motion for the right IF with full flexion and extension of the PIP and DIP joints after repair. IF, index finger. PIP and DIP, proximal and distal interphalangeal.

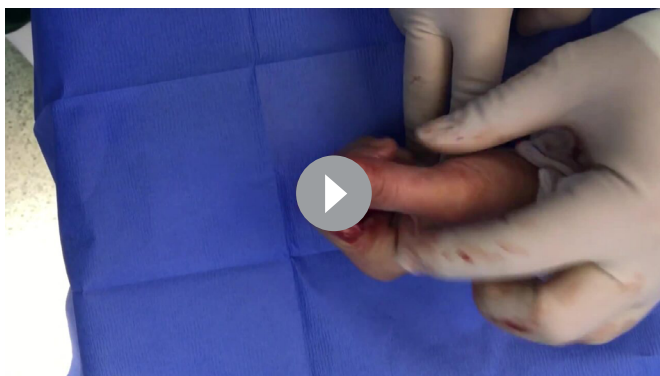OUTCOME AND FOLLOW-UP

Both patients were followed up weekly for the first 3 weeks to assess wound healing and to educate them on the rehabilitation process. Formal referral to an occupational therapist was done on the first week and visits started on the 2nd–3rd week. A hand-based splint was applied to afford wrist extension and flexion with the metacarpophalangeal joint remaining in 60°–70° flexion on the 4–5th week postrepair. The splint was discontinued on the 6–7th week, and any flexion contracture of the interphalangeal joints was managed with volar extension splinting. Unlimited activities and strengthening of finger flexion were started on the 12th week postrepair.

The latest follow-up sessions for patients 1 and 2 were 36 months and 42 months postrepair, respectively. The incisions were completely healed with no signs of infection. Both subjects were able to do almost full active flexion of the IF, PIP and DIP (figure 5A,B; figure 6A,B; videos 4 and 5). Both were able to return to their work.

DISCUSSION

In this report, good outcomes of flexor tendon repair using wide-awake surgery after glass ampoule injury were presented in two cases. A history of penetrating injury with inability to flex the involved digit during physical examination, as seen in these two cases, gives a high index of suspicion of a flexor tendon laceration, which warrants emergency exploration and repair. The prognosis of such injuries if left untreated, given a perennially extended digit that will always ‘get in the way’ during



Video 2 Patient 2 intraoperative range of motion for the left IF. Full range of motion was achieved without tendon repair gapping. IF, index finger.



Video 3 Patient 2 at 4 weeks postrepair on dorsal blocking splint. Patient is allowed 50%–75% range of motion with active flexion and extension within the splint. Passive flexion using the opposite hand to complete full flexion was advised following active extension.

hand use, will severely compromise hand function. Inability to flex one digit can compromise hand use like grip and fine hand movements. The involvement of the IF can compromise hand functions like key pinch and precision grip. In hand injuries from opening a medicinal glass ampoule, Parker⁵ reported the IF as the most commonly injured digit, and the injuries were probably due to the vertical projections (spikes) of the broken ampoule.⁶ Most of the injuries were reported to be minor, affecting only the skin, with minimal bleeding.¹² There are no other descriptions of the injury found in literature, except for one report with an associated flexor tendon transection from opening a medicinal glass ampoule by an anaesthetist,⁷ but no details on the technique of repair and final outcome were mentioned.

The management for established flexor tendon injuries is surgical. The primary repair of the transected flexor tendons is the mainstay of treatment since results are superior to any reconstructive procedure.¹³ After the skin laceration of patient 2 was sutured, no further consultation was initially made since there did

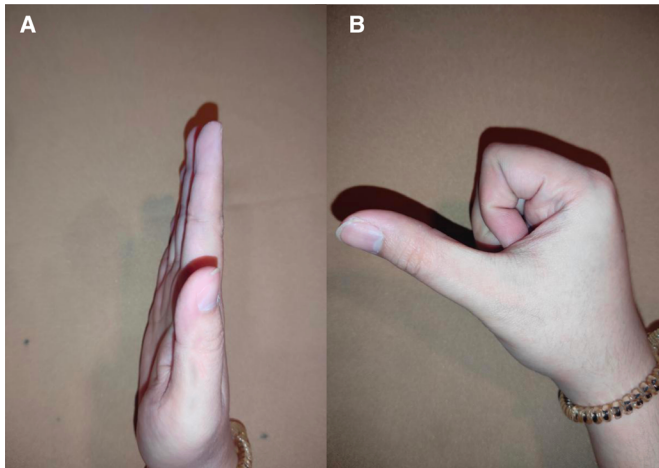



Figure 5 (A,B) Patient 1 at 36 months follow-up with very good range of motion of the right IF. IF, index finger.

not appear to be any other damage caused by the glass ampoule. Early recognition of this injury is very important so that surgical management will not be delayed. After 3 weeks, the tendons would no longer be amenable to primary repair due to proximal tendon end swelling, muscle fibrosis and tendon contraction.¹⁴ A more technically demanding flexor tendon reconstruction using a graft as a single stage or two-stage procedure, or in rare cases, fusion will be done instead. A reconstruction would have to satisfy certain parameters of eligibility as outlined by Pulvertaft in that the finger should not have extensive scarring, the passive motion should be at least nearly full, there should be satisfactory circulation and at least one digital nerve should be intact.¹⁵ An example of a two-stage procedure entails the first stage of placement of a passive silicone tendon implant and then, after 6–12 weeks, an exchange of the silicone implant with a tendon graft.¹⁶ The outcomes of flexor tendon reconstruction are poorer and with higher complication rates compared with primary repair.¹⁴

Flexor tendon injuries, specifically zone II injuries, remain to be a challenge in terms of treatment due to the presence of the pulley system that make them prone to adhesions leading to unpredictable outcomes despite the improvements in



Video 4 Patient 1 at 36 months postrepair with very good range of motion of the right IF. IF, index finger.

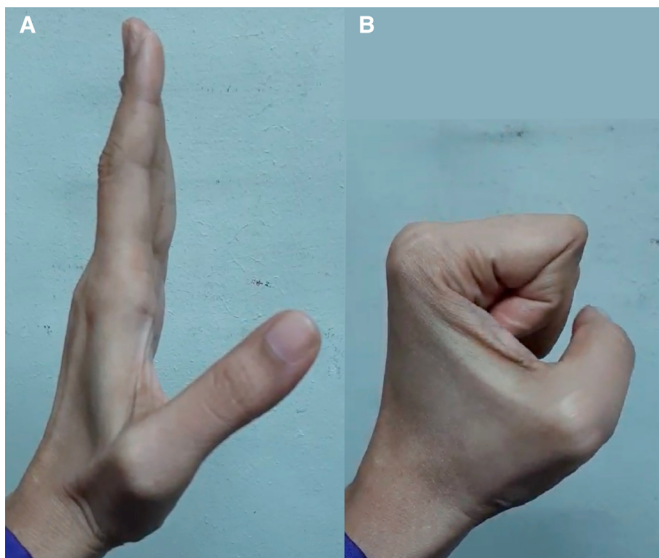
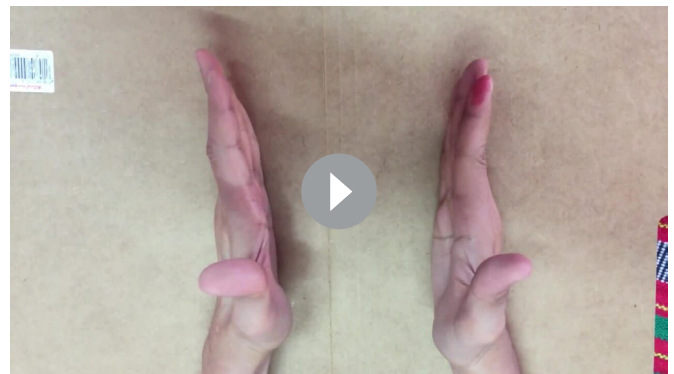


Figure 6 (A,B) Patient 2 at 42 months follow-up with near full range of motion of the left IF. IF, index finger.



Video 5 Patient 2 at 42 months. Left IF showed good outcome with slight PIP joint extension lag compared with the contralateral IF. IF, index finger. PIP, proximal interphalangeal.

surgical technique.⁸ Although good outcomes are expected, poor outcomes in primary flexor tendon repairs often result from tendon adhesions and tendon repair ruptures. In the systematic review and meta-analysis by Dy *et al*,¹⁷ the most common complications after primary repair were reoperation (6%), rupture (4%) and adhesions (4%). Such complications often result in additional surgeries, which can contribute to delayed functional recovery. The challenge of postoperative rehabilitation is in minimising adhesions by early movement without rupturing the repair. Rehabilitation protocols usually entail gradual progression of protected motion until full range of motion is achieved and strengthening exercises can be started, in a span of 8 weeks.¹⁶ In the systematic review and meta-analysis by Xu *et al*,¹⁸ the rehabilitation protocols of early active movement and early passive movement were compared, and results showed good to excellent outcomes for both groups, but favouring greater total active motion in the early active group.

Flexor tendon repair is usually carried out with the use of a tourniquet, and the patient sedated under either regional or general anaesthesia. This procedure does not permit active movement of the repaired tendon intraoperatively to assess the quality of the repair. The WALANT technique was used for the two cases and allowed the surgeon to test the adequacy of the repair during the surgery by observing gapping and tendon gliding through pulleys while the patient performs active flexion and extension of the digit. This can minimise adhesions postoperatively and maximise patient outcomes.^{9–11} The outcomes of flexor tendon repair using WALANT and traditional anaesthesia showed similar functional outcomes and complications in two recent studies.^{19 20} However, WALANT clearly offers the advantage of local anaesthetic combined with the ability to test the repair intraoperatively.

One of the most feared complications of using epinephrine in finger and hand surgery is ischaemia. In a retrospective review of 1073 cases of WALANT surgery in hand and finger surgeries, there were no reported instances of circulatory or ischaemic problems.²¹ In a retrospective review of 4287 wide awake procedures with local anaesthesia and epinephrine, Ilyas *et al*²² reported that there were no instances of tissue necrosis, vascular compromise or phentolamine reversal. This large series on the use of 1:100 000 epinephrine with local anaesthesia showed that it is safe for hand surgery procedures.

It should also be emphasised that these injuries, and their sequelae, are preventable. The use of gloves, syringe bag, cotton, ampoule openers and an outward direction of opening the ampoule are advised to minimise the incidence of glass ampoule injuries.^{6 12 23} Despite these recommendations, HCW compliance remains to be an issue due to bad habits, inconvenience, discomfort and loss of tactile sensitivity when using gloves.^{6 24} For the cases discussed in this report, the injuries occurred in two different hospitals. The authors are connected to only one of the hospitals. In this hospital, the use of gloves and safety ampoule holder have been advocated to prevent similar injuries. Students have been advised against opening glass ampoules; instead, these have been delegated to the experienced nurses.

In summary, flexor tendon injuries from opening medicinal glass ampoules are rare but can be devastating, with a long rehabilitation process after repair. The use of the WALANT technique facilitates real-time confirmation of the strength of repair and tendon gliding within the pulley system in zone II injuries, which in turn can improve the outcome of flexor tendon repairs.

Patient's perspective

Patient's Perspective: Patient 2.

It was a typical day at work when I accidentally cut my left index finger while opening a glass ampoule. The doctor immediately sutured my wound to stop the bleeding. After getting the stitches done, I felt normal, despite some numbness I felt on my finger. I thought that maybe it is just the anaesthetic, and it should wear off soon. I did not realise that this injury would create a more significant impact on me.

I went about my work, and days passed without any thought of consulting anyone regarding my injury. I was not paying any attention to it. However, my co-workers started teasing me because they noticed I could not flex my left index finger. One of the doctors checked my finger and told me, "Ma'am, have you consulted an orthopaedic surgeon regarding your injury? It seems you have cut your tendon." That was when I realised how severe that cut was. It was not because it was a life-threatening condition, but because it would affect my profession. Will I still be able to work as a nurse? How can I apply for work overseas with a damaged finger like this? How can I insert an IV without a firm grasp of my patient's hand? Will patients see me as an able nurse despite my injury?

I consulted an orthopaedic surgeon. He immediately placed my hand on a splint. He scheduled the surgery as soon as possible.

On the day of surgery, I was anxious since it was my first time to be in the operating room as a patient. During the surgery, I was more relaxed because all the staff and doctors were accommodating. During my recovery period, my finger looked like Frankenstein's and had limited movement. The rehabilitation process required several sessions. It was not pleasant at first, to see that my finger could not fully flex as it used to. But with proper guidance in doing the recommended exercises and therapy, I finally recovered and regained control of my injured finger.

The experience has made me more careful in breaking ampoules, and made our department realise the need for ampoule cutters. It also gave me a different perspective in handling patients who have a similar injury as I had.

Learning points

- ▶ Flexor tendon injuries from opening medicinal glass ampoules are rare, but entail tendon repair and a long rehabilitation process.
- ▶ Awareness and early recognition of this injury is important.
- ▶ Using the Wide-awake Local Anaesthesia No Tourniquet technique may improve outcomes since it allows assessment of the strength of repair intraoperatively, thereby allowing earlier range of motion exercises for the patient.

Contributors EPE evaluated the patients, performed the surgeries and followed up on the patients. After EPE's coordination with the patients, consent was secured with the help of SOJG. EPE led the manuscript design. Both EPE and SOJG did the literature review and contributed to the writing and editing of the manuscript. SOJG is the corresponding author.

Funding The authors have not declared a specific grant for this research from any funding agency in the public, commercial or not-for-profit sectors.

Competing interests None declared.

Patient consent for publication Consent obtained directly from patient(s)

Provenance and peer review Not commissioned; externally peer reviewed.

Open access This is an open access article distributed in accordance with the Creative Commons Attribution Non Commercial (CC BY-NC 4.0) license, which permits others to distribute, remix, adapt, build upon this work non-commercially, and license their derivative works on different terms, provided the original work is properly cited and the use is non-commercial. See: <http://creativecommons.org/licenses/by-nc/4.0/>.

Case reports provide a valuable learning resource for the scientific community and can indicate areas of interest for future research. They should not be used in isolation to guide treatment choices or public health policy.

ORCID iDs

Emmanuel Pantaleon Estrella <http://orcid.org/0000-0001-9114-9190>

Sarah Olivia Javier Gavino <http://orcid.org/0000-0001-5076-4648>

REFERENCES

- Ghanei Gheshlagh R, Aslani M, Shabani F, *et al.* Prevalence of needlestick and sharps injuries in the healthcare workers of Iranian hospitals: an updated meta-analysis. *Environ Health Prev Med* 2018;23:44.
- Huang S-L, Lu Q, Fan S-H, *et al.* Sharp instrument injuries among hospital healthcare workers in mainland China: a cross-sectional study. *BMJ Open* 2017;7:e017761.
- Bairami F, Kasani E, Ghorbanpoor M. Needle-Stick and sharp injuries incidents among healthcare workers: an updated survey. *Int J Hosp Res* 2014;3:79–82.
- Saadeh R, Khairallah K, Abozeid H, *et al.* Needle stick and sharp injuries among healthcare workers: a retrospective six-year study. *Sultan Qaboos Univ Med J* 2020;20:54–62.
- Parker MR. The use of protective gloves, the incidence of ampoule injury and the prevalence of hand laceration amongst anaesthetic personnel. *Anaesthesia* 1995;50:726–9.
- Carraretto AR, Curi EF, de Almeida CED, *et al.* Glass ampoules: risks and benefits. *Rev Bras Anestesiologia* 2011;61:513–21.
- Seven Things About Ampoule Injuries You Need To Know [Internet]. Qlicksmart Australia, 2022. Available: <https://www.qlicksmart.com/7-things-ampoule-injuries-you-need-know/> [Accessed 12 Mar 2022].
- Klifto CS, Capo JT, Sapienza A, *et al.* Flexor tendon injuries. *J Am Acad Orthop Surg* 2018;26:e26–35.
- Fulchignoni C, Bonetti MA, Rovere G, *et al.* Wide awake surgery for flexor tendon primary repair: a literature review. *Orthop Rev* 2020;12:8668.
- Lalonde D. Wide awake local anaesthesia no tourniquet technique (WALANT). *BMJ Proc* 2015;9:A81.
- Higgins A, Lalonde DH, Bell M, *et al.* Avoiding flexor tendon repair rupture with intraoperative total active movement examination. *Plast Reconstr Surg* 2010;126:941–5.
- Chiannikulchai N, Kejkornkaew S. A comparative study of Ampoule breaking and resultant injury among registered nurses. *Pacific Rim Int J Nurs Res* 2020;24:89–101.
- Chattopadhyay A, McGoldrick R, Umansky E, *et al.* Principles of tendon reconstruction following complex trauma of the upper limb. *Semin Plast Surg* 2015;29:030–9.
- Lehfeldt M, Ray E, Sherman R. MOC-PS(SM) CME article: treatment of flexor tendon laceration. *Plast Reconstr Surg* 2008;121:1–12.
- Pulvertaft RG. Tendon grafting for the isolated injury of flexor digitorum profundus. *Bull Hosp Jt Dis Orthop Inst* 1984;44:424–34.
- Wolfe SW, Pederson WC, Kozin SH, *et al.* *Green's Operative Hand Surgery*. Philadelphia, PA: Elsevier, 2022.
- Dy CJ, Hernandez-Soria A, Ma Y, *et al.* Complications after flexor tendon repair: a systematic review and meta-analysis. *J Hand Surg Am* 2012;37:543–51.
- Xu H, Huang X, Guo Z, *et al.* Outcome of surgical repair and rehabilitation of flexor tendon injuries in zone II of the hand: systematic review and meta-analysis. *J Hand Surg Am* 2022;S0363-5023(21)00755-3.
- Townsend CB, Henry TW, Matzon JL, *et al.* Functional outcomes of flexor tendon repair in the fingers: a comparison of Wide-Awake local anesthesia no tourniquet versus traditional anesthesia. *Hand* 2022;7:155894472110643.
- Kadhun M, Georgiou A, Kanapathy M, *et al.* Operative outcomes for wide awake local anesthesia versus regional and general anesthesia for flexor tendon repair. *Hand Surg Rehabil* 2022;41:125–30.
- Abdullah S, Chia Hua L, Sheau Yun L, *et al.* A review of 1073 cases of Wide-Awake-Local-Anaesthesia-No-Tourniquet (WALANT) in finger and hand surgeries in an urban hospital in Malaysia. *Cureus* 2021;13:e16269.
- Ilyas AM, Jennings JD, Banner L, *et al.* Wide-Awake surgery with local anesthesia and epinephrine is safe. *Orthopedics* 2020;43:e529–32.
- Centers for Disease Control and Prevention (CDC). Workbook for designing, implementing, and evaluating a sharps injury prevention programme, 2004. Available: <http://www.cdc.gov/sharpsafety/index.html> [Accessed 31 Oct 2021].
- Tiefenthaler W, Gimpl S, Wechselberger G, *et al.* Touch sensitivity with sterile standard surgical gloves and single-use protective gloves. *Anaesthesia* 2006;61:959–61.

Copyright 2022 BMJ Publishing Group. All rights reserved. For permission to reuse any of this content visit <https://www.bmj.com/company/products-services/rights-and-licensing/permissions/>
BMJ Case Report Fellows may re-use this article for personal use and teaching without any further permission.

Become a Fellow of BMJ Case Reports today and you can:

- ▶ Submit as many cases as you like
- ▶ Enjoy fast sympathetic peer review and rapid publication of accepted articles
- ▶ Access all the published articles
- ▶ Re-use any of the published material for personal use and teaching without further permission

Customer Service

If you have any further queries about your subscription, please contact our customer services team on +44 (0) 207111 1105 or via email at support@bmj.com.

Visit casereports.bmj.com for more articles like this and to become a Fellow