



Case Report

Bedside single burr hole craniostomy drainage of chronic subdural hematoma in the emergency room: A useful option in resource challenged settings

Toyin Ayofe Oyemolade¹, Augustine Abiodun Adeolu^{2,3}

¹Division of Neurosurgery, Department of Surgery, Federal Medical Center, Owo, Ondo State, ²Division of Neurosurgery, Department of Surgery, College of Medicine, University of Ibadan, Ibadan, ³Department of Neurological Surgery, University College Hospital Ibadan, Ibadan, Oyo State, Nigeria.

E-mail: *Toyin Ayofe Oyemolade - toyinmolade@yahoo.com; Augustine Abiodun Adeolu - adeoluaa@yahoo.com



***Corresponding author:**

Toyin Ayofe Oyemolade,
Division of Neurosurgery,
Department of Surgery, Federal
Medical Center Owo, Owo,
Ondo State, Nigeria.

toyinmolade@yahoo.com

Received : 08 August 2020

Accepted : 26 September 2020

Published : 21 October 2020

DOI

10.25259/SNI_502_2020

Quick Response Code:



ABSTRACT

Background: In resource challenged environments, the standard treatment of chronic subdural hematoma (CSDH) in the theater may be delayed because of the endemic financial constraint and logistic problems with consequent negative impact on the outcome. An emergency bedside burr hole craniostomy with a local anesthetic at the accident and emergency ward may be lifesaving in patients presenting in extreme neurological conditions in these settings.

Case Description: We presented three patients (one male and two females) with CSDH who presented at our service in poor neurological condition. The patients were between 49 and 70 years. The Glasgow Coma Score ranged from 3 to 6. The three patients had respiratory and pupillary abnormalities at presentation. They all had bedside single frontal burr hole craniostomy drainage of the hematoma under local anesthesia at the accident and emergency unit of the hospital. Surgery was done within 1 h of review by the neurosurgical team in all cases. The duration of hospital stay ranged from 8 to 24 days. The outcome was good in all cases.

Conclusion: Bedside single burr hole craniostomy at the accident and emergency unit may be lifesaving in patients with CSDH who present in extreme neurological condition but in whom prompt standard surgical treatment in the theater is not feasible.

Keywords: Bedside, Burr hole craniostomy, Chronic subdural hematoma, Resource challenged settings

INTRODUCTION

Chronic subdural hematoma (CSDH) is a commonly encountered disease entity in neurosurgical practice.^[6,7,13] It carries a good prognosis when treated adequately.^[7] Surgical treatment options include bedside twist drill craniostomy, burr hole craniostomy, and craniotomy.^[6,7,13] Twist drill craniostomy is cheap, it is the least invasive of surgical therapy for CSDH, it does not require general anesthesia or operating room and it is thus performed at the bed side.^[7,13] It, however, has many limitations and use has not been generally adopted by all neurosurgeons.^[13] In a developing country like ours, bedside twist drill craniostomy is not widely performed; therefore, CSDH is often treated with burr hole craniostomy or craniotomy in the theater. In these settings, patients with CSDH sometimes present to the neurosurgeon in extreme condition but financial constraint and logistic

This is an open-access article distributed under the terms of the Creative Commons Attribution-Non Commercial-Share Alike 4.0 License, which allows others to remix, tweak, and build upon the work non-commercially, as long as the author is credited and the new creations are licensed under the identical terms.

©2020 Published by Scientific Scholar on behalf of Surgical Neurology International

problems may delay surgical intervention in the theater. A bedside burr hole craniostomy under local anesthesia to promptly relieve intracranial pressure at the accident and emergency ward may be lifesaving in these circumstances. We present three cases of CSDH who arrived at our service in extreme neurological conditions and had bedside frontal burr hole craniostomy and subdural drain placement at the accident and emergency ward with good outcome.

CASE DESCRIPTION

Case 1

A 70-year-old man presented with headache of 2 weeks duration, progressive weakness of the left upper and lower limbs of 6 days and loss of consciousness of 3 days. The headache was insidious in onset and worsened in severity progressively. There was no history of trauma and he was not on antiplatelets or anticoagulants. He was referred from a peripheral hospital because of cranial CT scan findings of right hemispheric CSDH [Figure 1]. The Glasgow Coma Score (GCS) at the time of referral was 6. At review, he had irregular respiration, the GCS was 4. The right pupil was 4 mm, while the left was 2 mm, both were reacting sluggishly to light. The relatives had no fund for surgery and activating hospital payment deferment system was considered too late because of his poor clinical condition. We, therefore, opted for an emergency bedside right frontal burr hole craniostomy under local anesthesia, using Hudson's brace and perforator. We drained 100 ml of liquid subdural blood under marked pressure. A subdural drain was placed. He improved immediately after surgery. The respiration became calmer; the immediate postoperative GCS was 8. The GCS became 15 within 36 h. The subdural drain was removed 48 h after surgery and he was ambulated same day. He was discharged on the postoperative day 8. He was seen at the outpatient clinic 6 weeks after discharge. At the time, he was

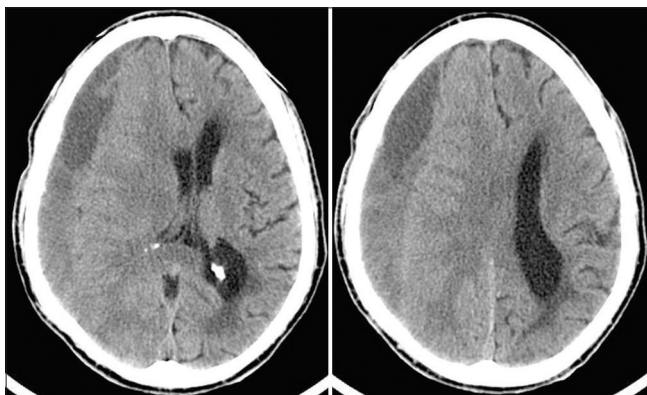


Figure 1: Preoperative cranial CT scan images of the first patient showing right hemispheric chronic subdural hematoma with partial effacement of the right lateral ventricle and midline shift to the left.

ambulating without support and required no assistance for activities of daily living.

Case 2

This 49-year-old woman is a known hypertensive and diabetic with poor drug compliance. She fell in the bathroom 22 days before presentation hitting her head on the bath tub in the process. There was transient loss of consciousness which was regained within 15 min. There was no vomiting, seizure, or craniofacial efflux. She started having generalized headache about 2 h after the fall. She developed left hemiparesis 16 days after and progressive deterioration in level of consciousness after another 2 days. She was referred to the neurologists in our hospital who subsequently invited us because of a brain MRI finding of right hemispheric CSDH [Figure 2]. At review, she had irregular respiration, the GCS was 5. The right pupil was 6 mm in size while the left was 2 mm, both were not reacting to light. The BP was 230/120 mmHg. Random Blood Sugar was 469.8 mg/dl. She had an emergency bedside right frontal burr hole craniostomy with drainage of 90 ml of liquid subdural blood under marked pressure. A subdural drain was placed. She improved immediately after surgery. The respiration became regular and calm, the immediate postoperative GCS was 7. The GCS became 15 within 72 h. The subdural drain was removed 48 h after surgery and she was ambulated on the 3rd postoperative day. Cranial CT scan on the 8th postoperative day [Figure 3] showed no residual hematoma. She was discharged on the postoperative day 8. She was seen at the outpatient clinic 6 weeks after discharge. At the time, she was ambulating without support and required no assistance for activities of daily living.

Case 3

A 67-year-old woman was referred to us with cranial CT scan diagnosed CSDH [Figure 4]. She had presented to the

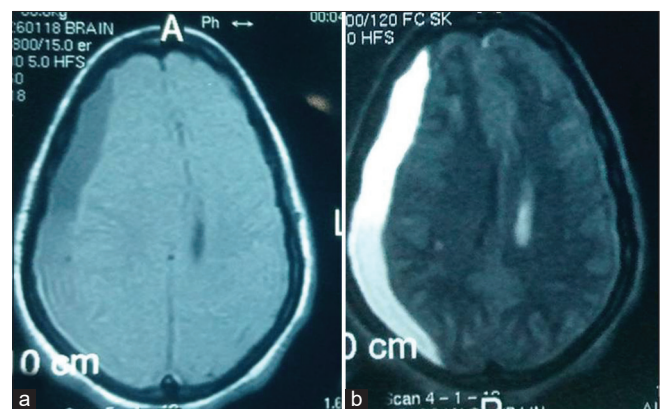


Figure 2: Preoperative cranial T1 (a) and T2 (b) weighted MR images of the second patient showing right hemispheric chronic subdural hematoma (hypo- and isointense on T1WI, hyperintense on T2WI) with midline shift to the left.

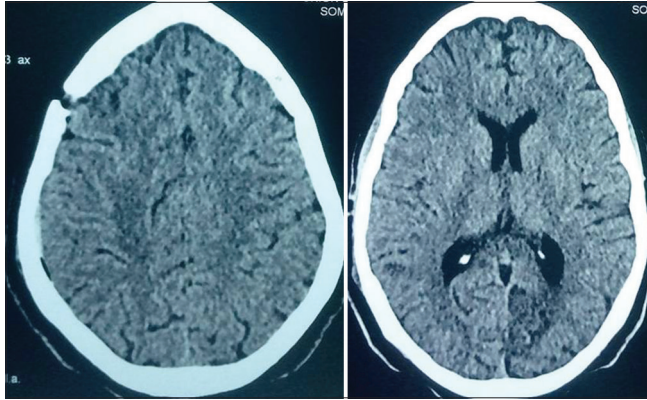


Figure 3: Postoperative cranial CT scan images of the second patient showing right frontal burr hole site, good brain re-expansion, and restoration of the midline.

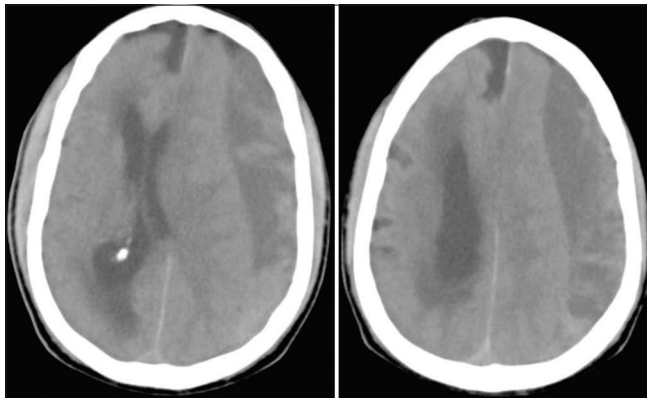


Figure 4: Preoperative cranial CT scan images of the third patient showing left hemispherical chronic subdural hematoma with partial effacement of the left lateral ventricle and midline shift to the right.

referring hospital with 3-week history of headache, 2 weeks of progressive right hemiparesis and 3 days of progressive deterioration in level of consciousness. There was no history of trauma, she was not a known hypertensive and was not any anticoagulant. At presentation, she was gasping. The GCS was 3, the right pupil was 8 mm in size while the left was 5 mm, both were not reacting to light. She had an emergency bedside left frontal burr hole craniostomy with drainage of 70 mls of engine oil colored subdural blood under pressure. A subdural drain was placed. She improved immediately after surgery. The respiration became calmer; the immediate postoperative GCS was 6. She continued to make progressive although slow neurological improvement. She was discharged on the 24th postoperative day. At the time, the GCS was 15, but she had residual right hemiparesis (power Grade 4). She was seen at the outpatient clinic 6 weeks after discharge. She was ambulating without support; the hemiparesis had resolved and required no assistance for activities of daily living.

DISCUSSION

CSDH is the collection of liquefied blood product beneath the dura which may result in increased intracranial pressure and neurological deficits.^[11] It is a frequently encountered condition in neurosurgical practice.^[6-8,13] The incidence of CSDH ranges from 1.7 to 13.3 cases per 100,000.^[1,4,9,15] Advanced age, increasing use of anticoagulants and antiplatelets, alcohol abuse, male gender, seizure, and increased availability of sophisticated head imaging are some of the factors that have been associated with increased occurrence of CSDH.^[2-4,12,13,16]

Surgical options for treatment of CSDH include twist drill craniostomy, burr hole craniostomy, and craniotomy. The optimal surgical treatment, however, remains controversial.^[2,7] The benefits of twist drill craniostomy include minimal invasiveness, shorter hospital stay, and no need for general anesthesia or operating room.^[5,8,13,14] It is particularly useful in emergencies when there might not be enough time to access the theater and perform burr hole craniostomy or craniotomy.^[13] Despite these advantages, twist drill craniostomy may be associated with severe complications including acute intracranial hemorrhage and its use has not been universally adopted by the neurosurgical communities.^[3,13] In addition, twist drill craniostomy has been reported to have a longer drainage time and smaller degree of reversal of midline shift than burr hole craniostomy.^[14] Burr hole craniostomy is associated with a lower recurrence rate than twist drill craniostomy and a lower complication rate than craniotomy.^[10] In Nigeria, twist drill craniostomy is not widely performed and CSDH is, therefore, largely treated with burr hole craniostomy or craniotomy in the theater. However, because of poverty and logistic problems endemic in these settings, surgical treatment of CSDH may sometimes be delayed, fatally so in certain instances.

Our three patients were in poor neurological conditions at the time of presentation to our service. They all had bedside single frontal burr hole minimal subdural irrigation and placement of subdural drain under local anesthesia at the accident and emergency unit of the hospital. Surgery was done within 1 h of review in all the cases with satisfactory outcome. The burr holes were made with Hudson's brace and perforator tools that are readily available in neurosurgical services in resource challenged environments like ours. This bedside procedure has the advantage of been very cheap, circumvents the intrahospital logistic delays often encountered in public hospitals in our setting, provides prompt intracranial decompression, and was a life saver in the presented cases.

In the resource poor setting where we practice obtaining postoperative images is not always feasible for a number

of reasons chief among which is financial constraint. Therefore, postoperative assessment is often limited to clinical evaluation alone as it was the case in two of our patients. Although we do not advocate routine emergency room bedside single burr hole drainage of CSDH, we suggest that this potentially lifesaving procedure should be part of the surgical armamentarium of neurosurgeons in the rural/resource challenged settings who may be faced from time to time with patients with CSDH who are in extreme neurological status but for whom prompt standard treatment options may for one reason or the other be delayed. Where finances and logistics permit, these patients should be followed up with further imaging and scheduling a definitive surgical procedure such as formal burr holes and/or craniotomies depending on the clinicoradiological findings.

CONCLUSION

Prompt standard surgical treatment of CSDH may not always be feasible in resource challenged settings. Bedside single burr hole craniostomy under local anesthesia in the emergency room offers a cheap and prompt means of intracranial decompression in these settings especially in patients presenting in extreme neurological conditions in whom further delay in intervention may worsen the outcome or be fatal.

Declaration of patient consent

The authors certify that they have obtained all appropriate patient consent.

Financial support and sponsorship

Nil.

Conflicts of interest

There are no conflicts of interest.

REFERENCES

- Almenawer SA, Farrokhyar F, Hong C, Alhazzani W, Manoranjan B, Yarascavitch B, *et al.* Chronic subdural hematoma management: A systematic review and meta-analysis of 34,829 patients. *Ann Surg* 2014;259:449-57.
- Bozkurt G, Ayhan S, Akbay A, Palaoglu S. Treatment of chronic subdural hematoma by twist drill craniostomy with irrigation. *Turk Neurosurg* 2006;16:19-24.
- de Bonis P, Trevisi G, de Waure C, Sferrazza A, Volpe M, Pompucci A, *et al.* Antiplatelet/anticoagulant agents and chronic subdural hematoma in the elderly. *PLoS One* 2013;8:e68732.
- Kim SU, Lee DH, Kim YI, Yang SH, Sung JH, Cho CB. Predictive factors for recurrence after burr-hole craniostomy of chronic subdural hematoma. *J Korean Neurosurg Soc* 2017;60:701-9.
- Lee SJ, Hwang SC, Im SB. Twist-drill or burr hole craniostomy for draining chronic subdural hematomas: How to choose it for chronic subdural hematoma drainage. *Korean J Neurotrauma* 2016;12:107-11.
- Makler V, D'Agostino E, Guerin SJ, Jaleel N. Burr hole craniostomy with novel use of subdural drain for evacuation of chronic subdural hematoma: Case series, literature review, and technical note. *Interdiscip Neurosurg* 2019;18:100501.
- Reinges MH, Hasselberg I, Rohde V, Kuker W, Gilsbach JM. Prospective analysis of bedside percutaneous subdural tapping for the treatment of chronic subdural haematoma in adults. *J Neurol Neurosurg Psychiatry* 2000;69:40-7.
- Rohde V, Graf G, Hassler W. Complications of burr-hole craniostomy and closed-system drainage for chronic subdural hematomas: A retrospective analysis of 376 patients. *Neurosurg Rev* 2002;25:89-94.
- Sahyouni R, Goshtasbi K, Mahmoodi A, Tran DK, Chen JW. Chronic subdural hematoma: A historical and clinical perspective. *World Neurosurg* 2017;108:948-53.
- Santarius T, Kirkpatrick PJ, Ganesan D, Chia HL, Jalloh I, Smielewski P, *et al.* Use of drains versus no drains after burr-hole evacuation of chronic subdural haematoma: A randomised controlled trial. *Lancet* 2009;374:1067-73.
- Sivaraju L, Moorthy RK, Jeyaseelan V, Rajshekhar V. Routine placement of subdural drain after burr hole evacuation of chronic and subacute subdural hematoma: A contrarian evidence based approach. *Neurosurg Rev* 2018;41:165-71.
- Smely C, Madlinger A, Scheremet R. Chronic subdural haematoma-a comparison of two different treatment modalities. *Acta Neurochir (Wien)* 1997;139:818-25.
- Szmuda T, Kierońska S, Słoniewski P, Dzierżanowski J. Modified bedside twist drill craniostomy for evacuation of chronic subdural haematoma. *Wideochir Inne Tech Maloinwazyjne* 2019;14:442-50.
- Wang K, Chen D, Cao X, Gao L. A prospective comparative study of twist drill craniostomy versus burr hole craniostomy in patients with chronic subdural hematoma. *Turk Neurosurg* 2017;27:60-5.
- Weigel R, Schmiedek P, Krauss JK. Outcome of contemporary surgery for chronic subdural haematoma: Evidence based review. *J Neurol Neurosurg Psychiatry* 2003;74:937-43.
- Wilberger JE. Pathophysiology of evolution and recurrence of chronic subdural hematoma. *Neurosurg Clin N Am* 2000;11:435-8.

How to cite this article: Oyemolade TA, Adeolu AA. Bedside single burr hole craniostomy drainage of chronic subdural hematoma in the emergency room: A useful option in resource challenged settings. *Surg Neurol Int* 2020;11:349.