

Complete eventration of right hemidiaphragm: A rare presentation

Krushna Makwana¹, Manish Pendse¹

¹Department of Medicine, DY Patil School of Medicine, Navi Mumbai, Maharashtra, India

ABSTRACT

Eventration of the diaphragm is a term used to describe an abnormal elevation of part or whole of the hemidiaphragm, where the whole or part of the diaphragm is made up of a thin fibro membranous sheet replacing normal diaphragmatic musculature. Complete and partial eventration both can occur, however, complete eventration of the right hemidiaphragm in an adult female, as presented in this patient, is rarely seen.

Keywords: Breathlessness, diaphragm, eventration, hemidiaphragm, phrenic nerve, respiratory failure

Introduction

Eventration of the diaphragm is mostly a congenital anomaly, resulting due to the failure of development of muscles of either one or both hemidiaphragms, with the muscle of part or whole of one or both lobes of the diaphragm being replaced partly or in full by a fibro membranous sheet.^[1]

Eventration results in permanent elevation of the hemidiaphragm without defects of continuity. Muscular insertions, pleural and peritoneal layers are normal. Incidence is reported to be 1 in 10,000 live births. Unilateral presentation mostly left sided, in males of all ages is the most common.^[2] Right-sided complete eventration in a female is extremely uncommon. Presenting symptoms are usually dyspnea, with gastrointestinal (GI) symptoms being seen if there is a migration of the abdominal viscera into the thoracic cavity.

Case Report

A 58-year-old female came to the emergency department with

Address for correspondence: Dr. Krushna Makwana, Department of Medicine, DY Patil School of Medicine, Nerul, Navi Mumbai, Maharashtra - 400 706, India.
E-mail: krushna.m@gmail.com

complaints of fever and cough with yellowish expectoration for the past 1 week.

General physical examination was normal. The patient was fairly built and adequately nourished, with no significant history of any infection, trauma, or malignancy in the past. The patient had no history of tobacco chewing, smoking, alcohol intake, or drug use. Nothing significant was noted in the family history.

The patient had a respiratory rate of 26/min, pulse rate was 82/min and regular, temperature was 99 degrees F, blood pressure was 130/90 mmHg, and peripheral oxygen saturation was 100%.

On examination of the chest, decreased movements were noted in the right side in the inframammary, infra-axillary, and infrascapular areas. Tactile vocal fremitus was decreased on the right side, and on percussion, dull note was heard over the same area. Breath sounds were decreased in the right inframammary, infra-axillary, and infrascapular areas.

Laboratory investigations were found to be normal. Echocardiography (ECG) showed a normal sinus rhythm, and two-dimensional ECG revealed left ventricular ejection fraction of 55% with no signs of hypertensive or valvular heart

This is an open access article distributed under the terms of the Creative Commons Attribution-NonCommercial-ShareAlike 3.0 License, which allows others to remix, tweak, and build upon the work non-commercially, as long as the author is credited and the new creations are licensed under the identical terms.

For reprints contact: reprints@medknow.com

How to cite this article: Makwana K, Pendse M. Complete eventration of right hemidiaphragm: A rare presentation. J Family Med Prim Care 2017;6:870-2.

Access this article online

Quick Response Code:



Website:
www.jfmipc.com

DOI:
10.4103/jfmipc.jfmipc_283_17

disease. A chest radiograph showed homogeneous soft tissue opacity at right mid and lower zone obscuring the underlying lung field and left hemidiaphragm, suggestive of a loculated moderate pleural effusion or elevated hemidiaphragm due to subdiaphragmatic pathology [Figure 1]. A high-resolution computed tomography (CT) scan of the chest was performed for further investigation. Elevation of the right hemidiaphragm was noted, with mild right pleural effusion and basal atelectasis. The rest of the lung parenchyma was normal, with no evidence of altered attenuation, mediastinal lymph node enlargement, or interstitial lung disease. A whole-body positron emission tomography (PET)/CT scan with plain and postcontrast CT was performed as a further diagnostic modality to rule out neoplastic causes. The PET/CT scan showed pulling up of the right hemidiaphragm with atelectasis of the adjacent lung parenchyma without any discrete uptake of fludeoxyglucose contrast medium, providing conclusive evidence of complete eventration of the right hemidiaphragm with shift to the left. Minimal right-sided pleural thickening was also noted [Figure 2]. No other significant abnormality was seen anywhere else in the body. With all of these radiological findings, a diagnosis of complete eventration of the right hemidiaphragm was made.

Discussion

Eventration of the diaphragm is a condition where part or whole of the diaphragmatic musculature is replaced by fibrous tissue, with only a few or no interspersed muscle fibers. Its incidence is about 1 in 10,000,^[3] with males being commonly affected as compared to females. Congenital eventration is attributed to the inadequate or absent muscular development of the pleuroperitoneal membrane and is associated with premature birth and other congenital diseases. Acquired eventration is caused when there is pathological involvement of the phrenic nerve, which is most commonly seen as a result of injury to the nerve during instrumentation for delivery, abdominal surgery, or as a consequence of compression or tissue infiltrative injury due to neoplastic etiology.

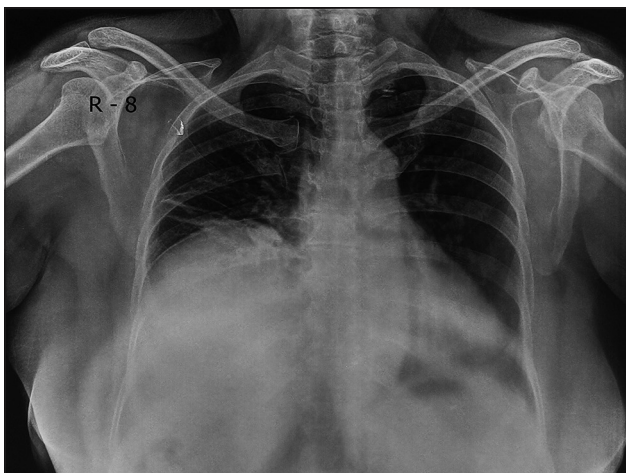


Figure 1: Chest X-ray of the patient showing eventration of right hemidiaphragm

Eventration is classified into partial and complete. Partial eventration can involve anterior, posterolateral or medial segments of the hemidiaphragm.^[3] Complete eventration is typically seen on the left side and partial eventration on the right side. Congenital eventration can often be asymptomatic and can be an incidental finding on chest radiography, or it can also be the cause of respiratory distress in infancy, requiring the use of mechanical ventilation. Congenital eventration in adults is generally asymptomatic and discovered incidentally on routine workup such as chest radiography, as was the case in this patient. However, in adults giving a history of common cold, sudden onset pain in shoulder or neck occurring before the onset of progressive dyspnea and a transient weakness of the arm, high index of suspicion should be maintained to rule out rarer neurologic conditions such as neuralgic amyotrophy.^[4,5] Patients may present with GI symptoms such as nausea, heartburn, postprandial vomiting, constipation, and epigastric discomfort. Typically, the patients present with acute or progressive respiratory failure and recurrent respiratory infections due to reduced diaphragmatic movements.^[6] Obese patients may present with GI symptoms, respiratory embarrassment and in rare cases, cardiac dysfunction due to the raised intra-abdominal pressure exerted by the eventration. All of these are indications for diaphragmatic plication and surgical correction of the other complications.^[7]

Chest radiography is the most common imaging modality used to diagnose eventration. If chest radiograph is indeterminate, then the use of spiral CT with thin sections is preferred for confirming the diagnosis. MRI is used as an additional modality to evaluate the diaphragm in patients with clinical signs but questionable findings on chest X-ray and CT scan.^[8] Additional investigations such as ultrasonography chest, fluoroscopy, and contrast GI screening can also be done to rule out complications. Asymptomatic patients should be managed conservatively, but symptomatic patients, those with both progressive and acute respiratory failure are surgically managed. Plication of the diaphragm is the procedure of choice,^[9] with minimally invasive techniques

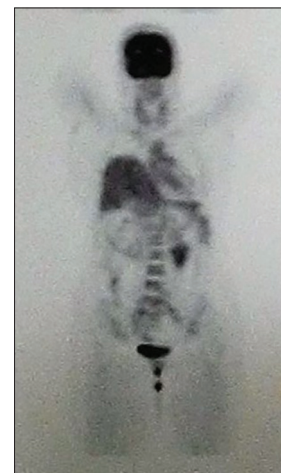

Figure 2: Positron emission tomography–computed tomography image showing pulling up of the right hemidiaphragm

such as laparoscopically assisted diaphragmatic plication being tried out.^[10]

Declaration of patient consent

The authors certify that they have obtained all appropriate patient consent forms. In the form the patient(s) has/have given his/her/their consent for his/her/their images and other clinical information to be reported in the journal. The patients understand that their names and initials will not be published and due efforts will be made to conceal their identity, but anonymity cannot be guaranteed.

Financial support and sponsorship

Nil.

Conflicts of interest

There are no conflicts of interest.

References

1. Kulkarni ML, Sneharoopa B, Vani HN, Nawaz S, Kannan B, Kulkarni PM, *et al.* Eventration of the diaphragm and associations. *Indian J Pediatr* 2007;74:202-5.
2. Nagdeve NG, Sarin YK. Volvulus complicating dextrogastrica in an infant. *Indian Pediatr* 2007;44:142-4.
3. Visouli AN, Mpakas A, Zarogoulidis P, Machairiotis N, Stylianaki A, Katsikogiannis N, *et al.* Video assisted thoracoscopic plication of the left hemidiaphragm in symptomatic eventration in adulthood. *J Thorac Dis* 2012;4 Suppl 1:6-16.
4. Mulvey DA, Aquilina RJ, Elliott MW, Moxham J, Green M. Diaphragmatic dysfunction in neuralgic amyotrophy: An electrophysiologic evaluation of 16 patients presenting with dyspnea. *Am Rev Respir Dis* 1993;147:66-71.
5. Tsao BE, Ostrovskiy DA, Wilbourn AJ, Shields RW Jr. Phrenic neuropathy due to neuralgic amyotrophy. *Neurology* 2006;66:1582-4.
6. Ravisagar P, Abhinav S, Mathur R, Anula S. Eventration of diaphragm presenting as recurrent respiratory tract infections - A case report. *Egypt J Chest Dis Tuberc* 2015;64:291-3.
7. Versteegh MI, Braun J, Voigt PG, Bosman DB, Stolk J, Rabe KF, *et al.* Diaphragm plication in adult patients with diaphragm paralysis leads to long-term improvement of pulmonary function and level of dyspnea. *Eur J Cardiothorac Surg* 2007;32:449-56.
8. Nason LK, Walker CM, McNeeley MF, Burivong W, Fligner CL, Godwin JD, *et al.* Imaging of the diaphragm: Anatomy and function. *Radiographics* 2012;32:E51-70.
9. Weber TR, Tracy TF Jr., Silen ML. The diaphragm: Developmental, traumatic, and neoplastic disorders. *Glenn's Thoracic and Cardiovascular Surgery*. 6th ed. Stamford CT: Appleton and Lange; 1996. p. 618-9.
10. Hüttl TP, Wichmann MW, Reichart B, Geiger TK, Schildberg FW, Meyer G, *et al.* Laparoscopic diaphragmatic plication: Long-term results of a novel surgical technique for postoperative phrenic nerve palsy. *Surg Endosc* 2004;18:547-51.