



Congenital peritoneopericardial diaphragmatic hernia in a family of Persian cats

Carol Margolis¹ , Maja Zakošek Pipan², Jolie Demchur¹, Matan Or¹, Paula Henthorn¹ and Margret L Casal¹

Journal of Feline Medicine and Surgery Open Reports
1–5

© The Author(s) 2018

Article reuse guidelines:

sagepub.com/journals-permissions

DOI: 10.1177/2055116918804305

journals.sagepub.com/home/jfmsopenreports

This paper was handled and processed by the American Editorial Office (AAFP) for publication in *JFMS Open Reports*



Abstract

Case series summary The congenital midline defects of peritoneopericardial diaphragmatic hernia (PPDH) and omphalocele are believed to be related developmental defects, and have both been described in cats and dogs. This case series describes multiple cases of PPDH and omphalocele in related cats. The majority of cats affected with midline defects (PPDH or omphalocele) were male, consistent with previous reports of male overrepresentation.

Relevance and novel information This is the first report of a family of Persian cats affected by PPDH and/or omphalocele. Clinical findings and pedigree information are suggestive of an autosomal recessive mode of inheritance. However, other modes of inheritance cannot be ruled out owing to limited sample size. The findings in this family and previous reports of Persians affected by PPDH warrant further investigation. Based on this information, recommendations for breeding populations of Persians and long-haired cats should include thoracic radiographs to screen for PPDH until a DNA-based genetic test is available.

Keywords: Persian cats; congenital; hernia; inbreeding; pregnant; midline defect

Accepted: 1 September 2018

Introduction

Congenital peritoneopericardial diaphragmatic hernia (PPDH) has been described as a midline defect that is over-represented in long-haired breeds, including Persians, Himalayans, Maine Coons and domestic long-hairs.^{1–3} In over half of the reported cases, PPDH was an incidental finding in mature adults.² Failure of midline fusion during development and prenatal traumatic injury have been suggested as potential pathogeneses of PPDH.^{4–7} This is the first report of congenital PPDH in a family of Persian cats, which may provide evidence for a genetic basis of PPDH in cats.

Case series description

A 16-month-old Persian cat 54 days post-breeding was referred to MJ Ryan Veterinary Hospital of the University of Pennsylvania Medical Genetics Service for a radiographically diagnosed PPDH. The queen had presented to the primary veterinarian for pregnancy radiographs,

and PPDH was incidentally observed along with four fetuses (Figure 1). No clinical signs had been previously noted, and no pre-existing medical conditions were reported. The radiographs sent from the referring veterinarian were reviewed, and an echocardiogram was performed to further assess the extent of the PPDH. Intestinal segments were visualized most prominently on the right

¹Section of Medical Genetics, Department of Clinical Sciences and Advanced Medicine, MJ Ryan Veterinary Hospital of the University of Pennsylvania, Philadelphia, PA, USA

²Clinic for Reproduction and Large Animals, Veterinary Faculty, University of Ljubljana, Ljubljana, Slovenia

Corresponding author:

Carol A Margolis DVM, DACT, Lecturer Medical Genetics, Pediatrics, and Reproduction, 3900 Delancey St, Philadelphia PA 19104, USA

Email: cmargo@upenn.edu



Creative Commons Non Commercial CC BY-NC: This article is distributed under the terms of the Creative Commons

Attribution-NonCommercial 4.0 License (<http://www.creativecommons.org/licenses/by-nc/4.0/>) which permits non-commercial use, reproduction and distribution of the work without further permission provided the original work is attributed as specified on the SAGE and Open Access pages (<https://us.sagepub.com/en-us/nam/open-access-at-sage>).

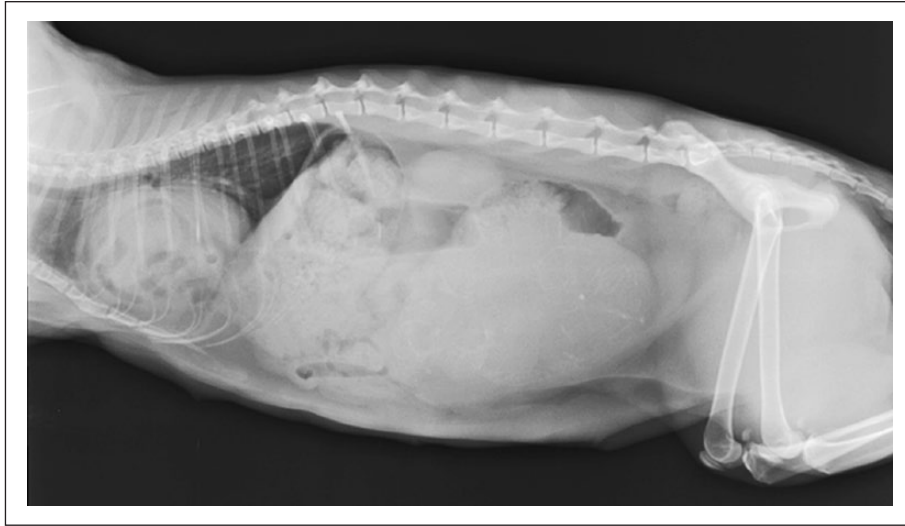

Figure 1 Radiograph of the 16-month-old intact Persian queen 50 days post-breeding, showing severe enlargement of the cardiac silhouette containing both soft tissue and numerous gas opacities, and a poorly defined ventral aspect of the diaphragm. Within the abdomen, early mineralization of four intact fetal skeletons within a fluid-filled uterus causing cranial displacement of the intestines can be seen

side of the heart. Additional intestinal segments, mesentery and a small portion of the liver were also observed adjacent to the heart in left-sided views. While cardiac structure was difficult to assess owing to the surrounding organs, mild right atrial enlargement was observed, with no evidence of significant functional cardiac disease.

At home, the queen was reported to breathe normally with a resting rate of 36–39 breaths per minute; however, during the veterinary visits the cat would have an elevated respiratory rate of 80 breaths per minute with observed effort. Even though stress-related tachypnea seen in cats presenting to a veterinary hospital could not be ruled out, the observed breathing pattern was likely a result of the PPDH, raising concerns for the potential of dystocia. The fetuses continued to have stable heart rates above 200 beats per minute, indicating normal perfusion. To coordinate cesarean section scheduling with the concurrent PPDH repair, fetal maturation and development of fetal peristalsis were monitored.⁸ Once robust fetal peristalsis and final stages of maturation were seen on ultrasound, a cesarean section and PPDH procedure were scheduled for the following day.

A cesarean section, PPDH repair and ovariohysterectomy were performed on day 65 post-breeding. The procedures were performed according to surgical standards and occurred without incident. Gross pathology noted during surgery described a defect in the center of the diaphragm, caudal to the pericardial sac. Most of the liver (right medial, left medial and quadrate lobes) and part of the small intestine were herniated through the diaphragmatic defect into the pericardial sac. The only organ compromised was the liver, which was adherent to the dorsal aspect of the rent in the thoracic side. All the herniated lobes were misshapen

and small. The quadrate liver lobe developed microtears upon reduction and continued to ooze blood following diaphragmatic closure. A hemostatic agent (Surgicel; Ethicon) was applied to the lobe to control hemostasis and prevent further bleeding from the site; however, owing to continued bleeding, part of the lobe was removed using the guillotine technique. The abdomen was routinely closed, and the cat recovered uneventfully.

During neonatal resuscitation, one male neonate was found to have an omphalocele with >50% of the small intestinal segments contained within the peritoneal sac, and was humanely euthanized. Full resuscitation events were attempted in the three remaining male kittens. Two of the three fetuses required prolonged efforts for resuscitation that were followed by poor weight gain and increased respiratory efforts. After 10 days of continued failure to thrive, they were admitted through the emergency service and found to be dyspneic. One of the kittens died during hospitalization, and a post-mortem examination confirmed PPDH with displacement of the left liver lobes into the pericardial sac (Figure 2). Upon diagnosis, the second kitten was radiographed. The thoracic radiographs suggested severe PPDH with what appeared to be the entire liver contained within the pericardium (Figure 3). Owing to the poor prognosis, humane euthanasia was elected and a post-mortem examination was performed.

No complications were reported following the queen's surgery, and it displayed good mothering behavior during the lactation and weaning periods for the remaining kitten. The remaining kitten presented at 17 days of age for evaluation. No cardiothoracic abnormalities were identified on auscultation, and ultrasound was unable to identify non-cardiac organs within the pericardium. The

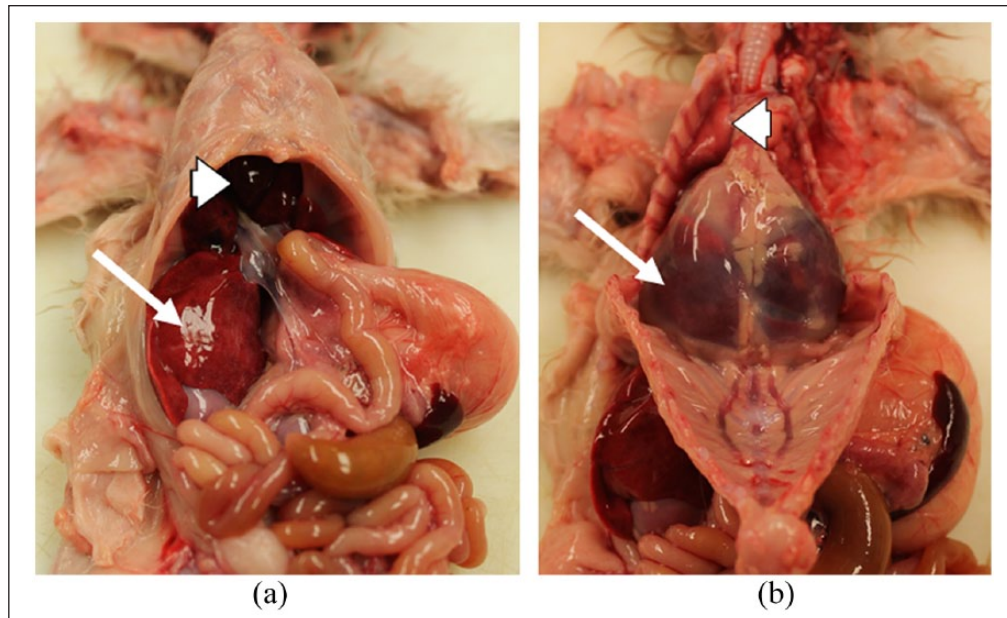


Figure 2 Images of the 10-day-old male intact Persian kitten that died from respiratory distress. (a) The diaphragm has a 16 mm ovoid defect continuous with the pericardial sac. The left liver lobes (large arrowhead) are displaced through the defect, into the pericardial sac. The displaced liver lobes are dark red and congested with blood. The right lateral liver lobe (small arrow) remains in the peritoneal cavity, and is mottled red-tan with physiologic glycogen stores. (b) The thoracic wall is reflected ventrally and caudally, exposing the thoracic cavity. The pericardial sac is markedly enlarged and contains displaced, congested liver lobes (small arrow). The lungs are compressed by the distended pericardium, dark pink-red and atelectic (large arrowhead)

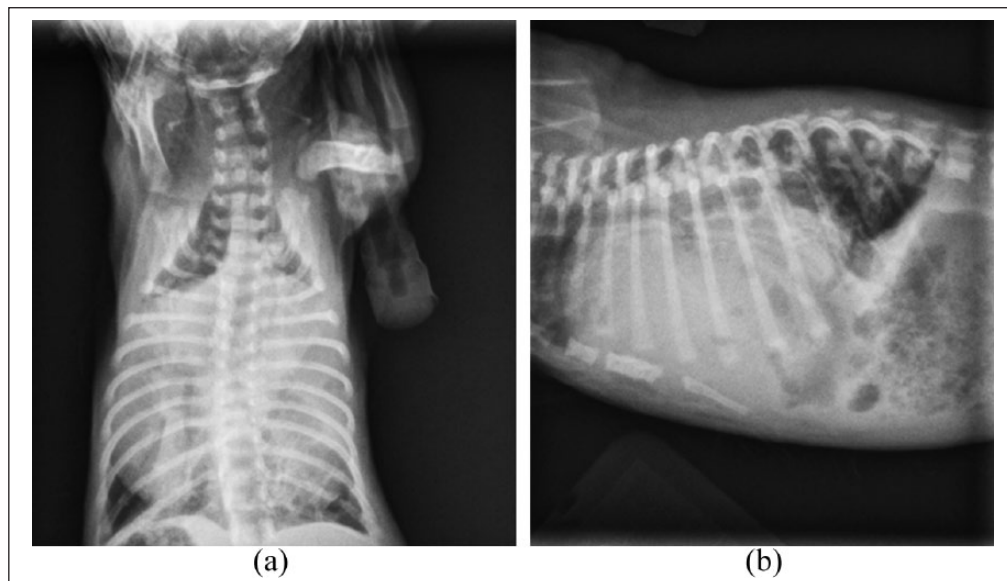


Figure 3 (a) Ventrodorsal and (b) right lateral thoracic radiographs of the 10-day-old male intact Persian kitten that had respiratory distress. The cardiac silhouette/pericardial sac is markedly enlarged, filling the majority of the thoracic cavity and contains both soft tissue and numerous gas opacities that are confluent with the cranial abdomen. The cardiac silhouette causes dorsal and lateral displacement of the lungs and dorsal displacement of the trachea. The ventral margin of the diaphragm is not visible and the stomach is immediately caudal to the visible portion of the mid and dorsal diaphragm

final kitten continued to do well, with normal physical examination findings at the time of writing.

The queen presented here and its litter-sister were bred within 2 weeks of each other by the same tom, which

was an offspring of a male littermate of the queens (Figure 4). Pedigree analysis revealed a minimum coefficient of inbreeding of 12.5%, indicating a high level of inbreeding. Radiographs of the second queen, taken by

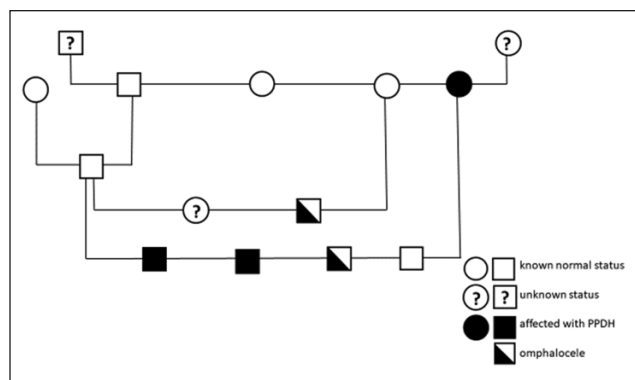


Figure 4 Pedigree of Persian cats with peritoneopericardial diaphragmatic hernia (PPDH; filled), omphalocele (half filled) and without (empty) midline defects. Square symbols indicate males and circles indicate females

the referring veterinarian, revealed two fetuses and no evidence of a PPDH in the queen. The second litter resulted in one male stillborn kitten with an omphalocele and one clinically normal female kitten that, at the time of writing, continued to do well. Thoracic radiographs, which included the cranial 1/3 of the abdomen, were obtained for the tom and both paternal grandparents, none of which showed any abnormalities. Further pedigree information, history or radiographic imaging of additional family members was not available.

Discussion

PPDH is one of the most common congenital defects diagnosed in cats >2 years of age.⁹ Over 100 cases have been reported in domestic pet cats,^{1,2,10} with as many as 50% of these found incidentally,² and with a higher rate of incidental diagnosis occurring in mature and geriatric cats.^{1,11–13} Although not statistically significant, PPDH has been reported at a higher prevalence in males (55–63%).^{1,2} Overall prevalence of PPDH in domestic cat populations has been reported to be 0.062–0.59%.^{2,14} It is reported to be over-represented in long-haired breeds,¹⁵ especially Maine Coons and Persians.^{10,16}

In addition to unknown or genetic causes of midline defects, environmental, chemical and toxin effects must be considered. Several have been identified to contribute to developmental defects, including, but not limited to, intrauterine constriction, vascular disruption, retinoids,

such as Vitamin A in liver diets, and steroid administration.¹⁷ All animals in this study were on Association of American Feed Control Officials-approved diets with no medications or supplements administered prior to or during pregnancy.

Clinical signs reported included none, muffled heart sounds, respiratory distress and/or gastrointestinal signs, such as anorexia, regurgitation or vomiting.^{14,15,18} One case report describes a 4-year-old queen that had given birth to numerous litters without incident or clinical signs of PPDH prior to its diagnosis and repair. These findings, combined with the report of PPDH in the 4-year-old multiparous queen,¹² and the lack of clinical signs in many of the affected animals, suggest that there may be a higher incidence of PPDH in the breeding population than previously described.

Pedigree evaluation of the cats described in this report confirm a familial relationship and suggests an autosomal recessive mode of inheritance for PPDH and omphalocele midline defects (Table 1). However, an autosomal dominant trait with incomplete penetrance cannot be ruled out owing to the higher percentage of affected offspring from these two litters than would have been expected for a simple autosomal recessive inheritance pattern. Most cases of diaphragmatic hernias in people are sporadic; however, variations of *ZFPM2* have been reported in human patients with variable penetrance.¹⁹ Despite reported monogenic forms, isolated cases are believed to be mostly multifactorial or polygenic.¹⁹

The inbreeding coefficient for this family of cats was calculated to be a minimum of 12.5%, with two littermate females bred to the same tom, producing the two litters described here. Mucha et al reported the percentage of inbred individuals within cat breeds to be increasing over time.²⁰ While more experienced breeders generally avoid inbreeding, smaller breeders are often less aware of the potential deleterious conditions that can surface by close inbreeding.²⁰ Close inbreeding results in inbreeding depression, which is characterized by reduced fertility and increased mortality. Persian litter sizes are reported as a mean of 3.8, with smaller litters on first pregnancies, and kitten mortality has been reported as high as 25%,^{21,22} reducing the likelihood of inbreeding alone to be the cause of these small litters and abnormalities. Studies have demonstrated that breeding programs should pay attention to inbreeding

Table 1 Offspring results of peritoneopericardial diaphragmatic hernia (PPDH) affected vs clear matings

Animal	Radiographic evidence of PPDH	Clinically normal offspring	Offspring with omphalocele	Offspring with PPDH
Tom*	No	1 male, 1 female	2 males	2 males
Queen 1	Yes	1 male	1 male	2 males
Queen 2	No	1 female	1 male	0

*All offspring of queens 1 and 2 are sired by the tom: six offspring total in study

practices with consideration for out-crossing or cross-breeding²³ to maintain genetic diversity within the breed. Further insight into breed-specific genetic health can be gained by paying close attention to breeding practices, and pursuing collaborations with breed clubs, associations, and academic or private institutions. Phenotyping healthy and affected animals, banking genetic material, and recording pedigree information will greatly facilitate genome-wide association studies to elucidate the genetic defects of specific inherited diseases.²⁴ As such, the DNA samples from these individuals have been submitted to the Feline Genetics and Comparative Medicine Laboratory at the University of Missouri for further study.

Conclusions

This case series highlights the probability of a hereditary basis of PPDH in Persian cats. While an autosomal recessive mode of inheritance appears likely, an autosomal dominant inheritance with incomplete penetrance cannot be ruled out. The small sample size and incomplete pedigree information contribute to the limitations of this study. Recommendations for pre-breeding health screening of Persians and other long-haired cat breeds should include thoracic radiographs to rule out PPDH. Finally, DNA samples should be collected from affected and unaffected Persians and other long-haired breeds to aid in the development of a genetic screening test.

Conflict of interest The authors declared no potential conflicts of interest with respect to the research, authorship, and/or publication of this article.

Funding The authors received no financial support for the research, authorship, and/or publication of this article.

ORCID iD Carol Margolis  <https://orcid.org/0000-0001-7143-9756>

References

- 1 Reimer SB, Kyles AE, Filipowicz DE, et al. **Long-term outcome of cats treated conservatively or surgically for peritoneopericardial diaphragmatic hernia: 66 cases (1987–2002).** *J Am Vet Med Assoc* 2004; 224: 728–732.
- 2 Burns CG, Bergh MS and McLoughlin MA. **Surgical and nonsurgical treatment of peritoneopericardial diaphragmatic hernia in dogs and cats: 58 cases (1999–2008).** *J Am Vet Med Assoc* 2013; 242: 643.
- 3 Hodgkiss-Geere HM, Palermo V, Liuti T, et al. **Pericardial cyst in a 2-year-old Maine Coon cat following peritoneopericardial diaphragmatic hernia repair.** *J Feline Med Surg* 2015; 17: 381–386.
- 4 Finn JP and Martin CL. **Diaphragmatic pericardial hernia.** *J Small Anim Pract* 1969; 10: 295–300.
- 5 Rendano VT and Parker RB. **Polycystic kidneys and peritoneopericardial diaphragmatic hernia in the cat: a case report.** *J Small Anim Pract* 1976; 17: 479–485.
- 6 Less RD, Bright JM and Orton EC. **Intrapericardial cyst causing cardiac tamponade in a cat.** *J Am Anim Hosp Assoc* 2000; 36: 115–119.
- 7 Liptak JM, Bissett SA, Allan GS, et al. **Hepatic cysts incarcerated in a peritoneopericardial diaphragmatic hernia.** *J Feline Med Surg* 2002; 4: 123–125.
- 8 Lopate C. **Estimation of gestational age and assessment of canine fetal maturation using radiology and ultrasonography: a review.** *Theriogenology* 2008; 70: 397–402.
- 9 Berry CR. **Recognition of congenital heart disease in the adult dog and cat.** In: Bonagura JD, Abott JA and Abrams KL (eds). *Kirk's current veterinary therapy XII. Small animal practice.* Philadelphia, PA: WB Saunders, 1995, pp 833–836.
- 10 Banz AC and Gottfried SD. **Peritoneopericardial diaphragmatic hernia: a retrospective study of 31 cats and eight dogs.** *J Am Anim Hosp Assoc* 2010; 46: 398–404.
- 11 Wallace J, Mullen HS and Lesser MB. **A technique for surgical correction of peritoneal pericardial diaphragmatic hernia in dogs and cats.** *J Am Anim Hosp Assoc* 1992; 28: 503–510.
- 12 Bismuth C and Deroy C. **Congenital cranial ventral abdominal hernia, peritoneopericardial diaphragmatic hernia and sternal cleft in a 4-year-old multiparous pregnant queen.** *J FMS Open Rep* 2017; 3: 1–6. DOI: 10.1177/2055116917747741.
- 13 Choi J, Kim H, Kim M, et al. **Imaging diagnosis—positive contrast peritoneographic features of true diaphragmatic hernia.** *Vet Radiol Ultrasound* 2009; 50: 185–187.
- 14 Murphy LA, Russell NJ, Dulake MI, et al. **Constrictive pericarditis following surgical repair of a peritoneopericardial diaphragmatic hernia in a cat.** *J Feline Med Surg* 2014; 16: 708–712.
- 15 Schuh JC. **Hepatic nodular myelolipomatosis (myelolipomas) associated with a peritoneo-pericardial diaphragmatic hernia in a cat.** *J Comp Pathol* 1987; 97: 231–235.
- 16 Neiger R. **Peritoneopericardial diaphragmatic hernia in cats.** *Compend Contin Educ Pract Vet* 1996; 18: 461–468.
- 17 Brent RL. **Environmental causes of human congenital malformations: the pediatrician's role in dealing with these complex clinical problems caused by a multiplicity of environmental and genetic factors.** *Pediatrics* 2004; 113 (4 Suppl): 957–968.
- 18 Linton M, Tong L, Simon A, et al. **Hepatic fibrosarcoma incarcerated in a peritoneopericardial diaphragmatic hernia in a cat.** *JFMS* 2016; 2: 1–7. DOI: 10.1177/12055116916638681.
- 19 Longoni M, Russell MK, High FA, et al. **Prevalence and penetrance of ZFPM2 mutations and deletions causing congenital diaphragmatic hernia.** *Clin Genet* 2015; 87: 362–367.
- 20 Mucha S, Wolc A, Gradowska A, et al. **Inbreeding rate and genetic structure of cat populations in Poland.** *J Appl Genetics* 2011; 52: 101–110.
- 21 Sparkes AH, Rogers K, Henley WE, et al. **A questionnaire-based study of gestation, parturition and neonatal mortality in pedigree breeding cats in the UK.** *J Feline Med Surg* 2006; 8: 145–157.
- 22 Ström Holst B and Frössling J. **The Swedish breeding cat: population description, infectious diseases and reproductive performance evaluated by a questionnaire.** *J Feline Med Surg* 2009; 11: 793–802.
- 23 Leroy G, Vernet E, Pautet MB, et al. **An insight into population structure and gene flow within pure-bred cats.** *J Anim Breed Genet* 2014; 131: 53–60.
- 24 Wellmann R and Pfeiffer I. **Pedigree analysis for conservation of genetic diversity and purging.** *Genet Res* 2009; 91: 209–219.