

Epidermal Graft Accelerates the Healing of Acute Wound: A Self-controlled Case Report

Nicola Bystrzonowski, BSc,
MBBS, MRCS, MSc*

Nadine Hachach-Haram, BSc,
MBBS, MRCS*

Muholan Kanapathy, MD, MRCS,
MSc*†

Toby Richards, BSc, MBBS,
FRCS, MD*†

Afshin Mosahebi, MBBS,
FRCS(Plast), PhD, MBA*†

Summary: Wound care represents a significant socioeconomic burden, with over half of chronic wounds taking up to a year to heal. Measures to accelerate wound healing are beneficial to patients and also reduce the cost and burden of wound management. Epidermal grafting (EG) is an emerging option for autologous skin grafting in the outpatient setting to improve wound healing. Although several case series have previously reported good clinical outcome with EG, the healing rate in comparison to conservative wound management is not known. In this report, we compare the weekly healing rate of 2 separate wounds in the same patient, one treated with EG and the other with dressings. The treated wound showed accelerated healing, with the healing rate being the highest at the first 2 weeks after EG. The average healing time of the treated wound was 40% faster compared with the control wound. EG accelerates healing of acute wounds, potentially reducing the healthcare cost and surgical burden. (*Plast Reconstr Surg Glob Open* 2016;4:e11119; doi: 10.1097/GOX.0000000000001119; Published online 21 November 2016.)

Wound management represents a significant burden to the healthcare system with the prevalence of patients with wounds in the United Kingdom alone estimated to be about 2.2 million, requiring over 40 million healthcare visits and consuming about 340 million dressings annually.^{1,2} The annual cost for wound management ranges around £4.5 to £5.1 billion in the United Kingdom and \$6 to \$15 billion in the United States.^{1,2} On average, 61% of chronic wounds take up to a year to heal.² Hence, measures to accelerate wound healing are beneficial to patients and also crucial to reduce cost and burden of wound management.

Epidermal grafting (EG) is an emerging option for autologous skin grafting in the outpatient setting to improve wound healing.³⁻⁵ EG involves harvesting the epidermis by applying continuous negative pressure on the donor site to raise blisters (Fig. 1). The roof of the blister is then excised and transferred to the wound. The superficial nature

of the graft enables painless skin grafting to be performed in the outpatient setting with minimal or no donor-site morbidity.^{3,6}

Although several case series have previously reported good clinical outcome with EG,^{3-5,7} the healing rate in comparison to conservative wound management is not known. In this report, we observe the weekly wound healing rate of EG compared with conservative treatment in 2 separate wounds in the same patient.

CASE REPORT

The patient was a 41-year-old policeman who sustained traumatic injuries over the right medial and lateral ankle region while at work after being run over by a car. Radiographs confirmed the absence of a fracture. The patient underwent wound debridement in the operating theatre and was commenced on negative pressure wound therapy (See PDF, Supplemental Digital Content 1, which displays lateral and medial right foot wounds before treatment, <http://links.lww.com/PRSGO/A286>).

Two weeks after negative pressure wound therapy, EG was performed using the CelluTome Epidermal Harvesting System (Acelity, San Antonio, Tex.) in the outpatient specialist clinic as per current clinical protocol.³

From the *Royal Free Hospital Wound Healing Group, Department of Plastic and Reconstructive Surgery, Royal Free London Hospital, London, United Kingdom; and †Royal Free Hospital Wound Healing Group, Department of Plastic and Reconstructive Surgery, Royal Free Hospital, London, United Kingdom.

Received for publication July 21, 2016; accepted September 13, 2016.

Copyright © 2016 The Authors. Published by Wolters Kluwer Health, Inc. on behalf of The American Society of Plastic Surgeons. All rights reserved. This is an open-access article distributed under the terms of the Creative Commons Attribution-Non Commercial-No Derivatives License 4.0 (CCBY-NC-ND), where it is permissible to download and share the work provided it is properly cited. The work cannot be changed in any way or used commercially without permission from the journal.

DOI: 10.1097/GOX.0000000000001119

Disclosure: The authors have no financial interest to declare in relation to the content of this article. The Article Processing Charge was paid for by University College London.

Supplemental digital content is available for this article. Clickable URL citations appear in the text.

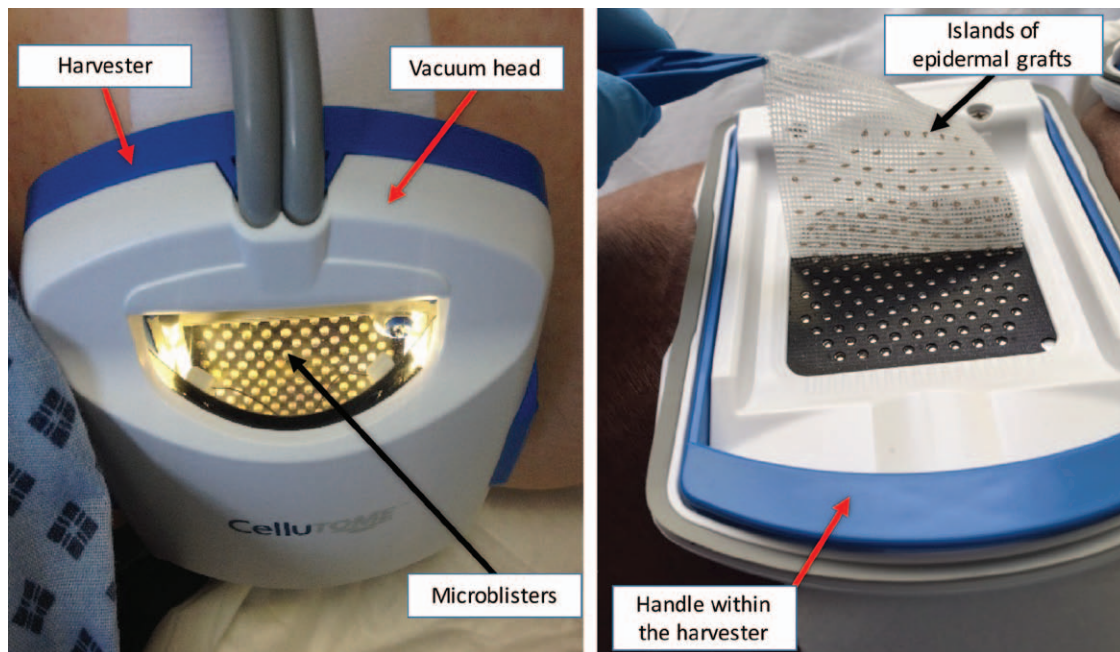


Fig. 1. The harvest technique: the microblisters, visible through the window of the vacuum head, were raised within half an hour by combining negative pressure of 400 to 500 mm Hg and temperature of 40°C. The vacuum head was then detached, leaving behind the harvester. The blue handle within the harvester, attached to an in-built blade, was then pulled up to excise the roof of the blister. The epidermal grafts were then transferred using a silicon dressing to the wound.

The epidermal grafts were harvested from the right thigh and transferred to the larger, lateral ankle wound using Adaptic Touch (Systagenix, Gargrave, England) (Fig. 1), a nonadherent silicon dressing, and secured with gauze and crepe bandage, whereas the donor site was dressed with Tegaderm Film (3M). The medial wound was dressed with Adaptic Touch (Systagenix) and secured with gauze and crepe bandage. The patient reported a pain score of 1 of 10 during the procedure without the use of anesthesia. The patient was allowed to return home on the same day after the procedure.

The patient was reviewed weekly with both wounds managed using similar dressings: Adaptic Touch and iNadine (Systagenix). Three-dimensional (3D) images were taken at each visit using LifeViz 3D camera (Quanticare) to objectively measure the wound surface areas. The weekly wound measurements and the reduction in wound size are shown in Figure 2. The weekly healing rates of the treated and control wounds are shown in Table 1.

Seven weeks after EG, the treated wound achieved complete healing, while the smaller, medial ankle wound achieved complete healing at 6 weeks. The average wound healing rate of the treated wound was 185.52 mm²/wk compared with 132.70 mm²/wk for the control wound. The patient was able to return to work at week 4 of treatment. The donor site achieved complete healing within 3 days.

DISCUSSION

EG harvest using a suction device was first described in 1964 by Kiistala and Mustakallio⁸, and in 1975, Hentzer and Kobayasi⁸ reported excellent clinical outcome for

wound reepithelialization. Several different suction devices have been used over the years, but because of the lack in the consistency of the graft quality, this technique has not gained clinical popularity for wound management.⁹ However, since the recent release of the commercially available CelluTome Epidermal Harvesting System (Acelity) that allows painless, easily reproducible and fully automated harvest in the outpatient setting with minimal donor-site morbidity, this technique is fast becoming a popular option to treat wounds.^{3-5,7,9} However, to the best of our knowledge, the comparison in the healing rate between EG and conservative treatment is yet to be reported.

In this patient, we found that the treated wound had accelerated healing compared with the control wound, with the healing rate being the highest at the first 2 weeks after EG (Table 1). The average healing time of the treated wound was about 40% faster compared with the control wound, whereby the average wound healing rate of the treated wound was 185.52 mm²/wk compared with 132.70 mm²/wk for the control wound. Therefore, based on the healing rate of the control wound, the lateral ankle wound would have only completely healed 3 weeks later if it had been treated conservatively. This implies that the EG has a wound modifying effect, stimulating native wound edge healing. This additional treatment time would have cost an additional £504 for 6 follow-up dressing clinic appointments. The average cost for each visit at our centre is estimated to cost £84, which is almost twice the cost of a single treatment with CelluTome. Furthermore, in addition to reducing the number of visits, the accelerated healing had enabled the patient to return to work earlier.

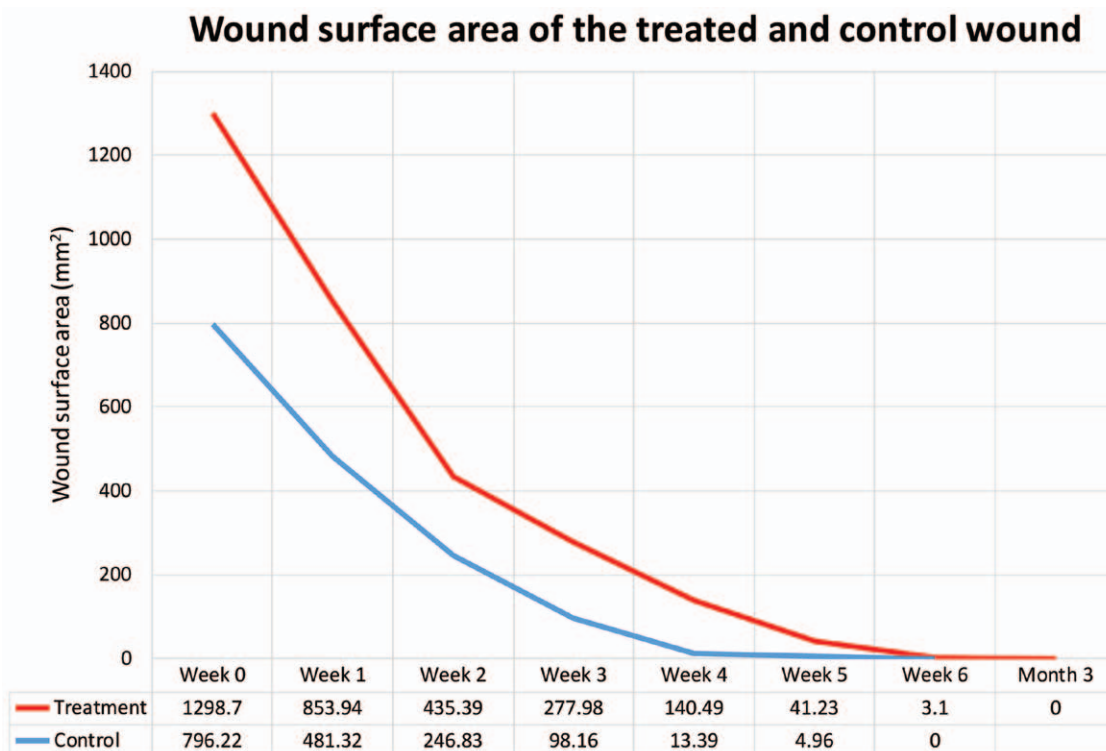


Figure 2. Weekly wound measurement: graph showing the weekly wound surface area of the treated and control wounds (mm²).

Table 1. Weekly Wound Healing Rate (Square Millimeter per Week)

Weekly Healing Rate	Week 0 → 1	Week 1 → 2	Week 2 → 3	Week 3 → 4	Week 4 → 5	Week 5 → 6	Week 6 → 7
Treatment (mm ² /wk)	444.76	418.55	157.41	137.49	99.26	38.13	3.1
Control (mm ² /week)	314.9	234.49	148.67	84.77	8.43	4.96	
Average Healing Rate							
Treatment: 185.52 mm ² /wk							
Control: 132.70 mm ² /wk							

The table shows the weekly reduction in wound surface area. The reduction in size is calculated based on the difference in the wound size to the week before. The average wound healing rate was calculated based on the total reduction in the wound surface area and the healing time.

The EG in this patient did not exhibit graft take as one would have expected to see with split thickness skin graft. Instead, reepithelialization was seen to occur from the wound edge. The precise mechanism of healing of EG is still unclear although EG has been postulated to carry growth factors and cytokines that stimulate wound reepithelialization from the wound edge and at the same time stimulating granulation tissue on the wound bed, behaving more like a tissue-engineered skin graft.⁵

This report only demonstrates the accelerated healing rate of an acute wound; however, we believe that EG has the potential to kick start the healing of chronic, nonhealing wounds.

CONCLUSIONS

We present the comparison of the healing rate of EG with conservative treatment in the same patient. EG accel-

erates healing of acute wounds by 40%, potentially reducing the healthcare cost and surgical burden. We are now undertaking a randomized controlled trial to evaluate the efficacy of EG against split-thickness skin graft to evaluate if EG can be an alternative to split-thickness skin graft for the coverage of healthy granulating wounds.¹⁰

Muholan Kanapathy, MD, MRCS, MSc
 Division of Surgery and Interventional Science
 University College London
 Fourth floor, 74 Huntley Street
 London, United Kingdom, WC1E 6AU
 E-mail: muholan.kanapathy.13@ucl.ac.uk

REFERENCES

- Brigham PA, McLoughlin E. Burn incidence and medical care use in the United States: estimates, trends, and data sources. *J Burn Care Rehabil.* 1996;17:95–107.
- Guest JF, Ayoub N, McIlwraith T, et al. Health economic burden that different wound types impose on the UK's National Health

- Service. *Int Wound J*. 2016. May 26. doi: 10.1111/iwj.12603. [Epub ahead of print]
3. Hachach-Haram N, Bystrzonowski N, Kanapathy M, et al. A prospective, multicentre study on the use of epidermal grafts to optimise outpatient wound management. *Int Wound J*. 2016. Mar 20. doi: 10.1111/iwj.12595. [Epub ahead of print]
 4. Gabriel A, Sobota RV, Champaneria M. Initial experience with a new epidermal harvesting system: overview of epidermal grafting and case series. *Surg Technol Int*. 2014;25:55–61.
 5. Richmond NA, Lamel SA, Braun LR, et al. Epidermal grafting using a novel suction blister-harvesting system for the treatment of pyoderma gangrenosum. *JAMA Dermatol*. 2014;150:999–1000.
 6. Hachach-Haram N, Bystrzonowski N, Kanapathy M, et al. The use of epidermal grafting for the management of acute wounds in the outpatient setting. *J Plast Reconstr Aesthet Surg*. 2015;68:1317–1318.
 7. Serena T, Francius A, Taylor C, et al. Use of a novel epidermal harvesting system in resource-poor countries. *Adv Skin Wound Care* 2015;28:107–112.
 8. Hentzer B, Kobayasi T. Suction blister transplantation for leg ulcers. *Acta Derm Venereol*. 1975;55:207–209.
 9. Kirsner RS, Bernstein B, Bhatia A, et al. Clinical experience and best practices using epidermal skin grafts on wounds. *Wounds* 2015;27:282–292.
 10. Kanapathy M, Hachach-Haram N, Bystrzonowski N, et al. Epidermal Grafting Versus Split-Thickness Skin Grafting for Wound Healing (EPIGRAAFT): study protocol for a randomised controlled trial. *Trials* 2016;17:245.