

HEART FAILURE AND IMAGING

INTERMEDIATE

CASE REPORT: CLINICAL CASE

Cardiac Tamponade Secondary to COVID-19



Mohammed F. Dabbagh, MD,^a Lindsey Aurora, MD,^a Penny D'Souza, DO,^a Allison J. Weinmann, MBBS,^b Pallavi Bhargava, MD,^b Mir B. Basir, DO^a

ABSTRACT

A 67-year-old woman presented with upper respiratory symptoms and was diagnosed with coronavirus disease-2019 (COVID-19). She was found to have a large hemorrhagic pericardial effusion with echocardiographic signs of tamponade and mild left ventricular impairment. Clinical course was complicated by development of takotsubo cardiomyopathy. She was treated with pericardiocentesis, colchicine, corticosteroids, and hydroxychloroquine, with improvement in symptoms. (**Level of Difficulty: Intermediate.**) (J Am Coll Cardiol Case Rep 2020;2:1326-30) © 2020 The Authors. Published by Elsevier on behalf of the American College of Cardiology Foundation. This is an open access article under the CC BY-NC-ND license (<http://creativecommons.org/licenses/by-nc-nd/4.0/>).

HISTORY OF PRESENTATION

A 67-year-old woman presented to the emergency department with cough, mild shortness of breath, and left shoulder pain. Physical exam and radiographic imaging of the chest were unremarkable (Figure 1). A nasopharyngeal swab was positive for severe acute respiratory syndrome-coronavirus-2 (SARS-CoV-2) by reverse transcription polymerase chain reaction. She was discharged home due to mild symptoms.

One week after her initial presentation, she presented with worsening dyspnea and orthopnea.

LEARNING OBJECTIVES

- To recognize that COVID-19 can have extrapulmonary manifestations, which can be readily identified with physical examination and simple diagnostic studies.
- To identify COVID-19 as a potential etiology of hemorrhagic pericardial effusion.

Physical exam was pertinent for a blood pressure of 118/82 mm Hg, heart rate of 122 beats/min, respiratory rate of 24 breaths/min, temperature of 36.8°C, normal oxygen saturation on room air, distant heart sounds, and rales at the lung bases bilaterally.

PAST MEDICAL HISTORY

The patient had a history of nonischemic cardiomyopathy with left ventricular ejection fraction (LVEF) of 15%, diagnosed in 2018 and managed with guideline-directed medical therapy with improvement in her LVEF to 40%. She had not been prescribed antiplatelet agents or anticoagulants and had no history of malignancy or coagulopathy.

DIFFERENTIAL DIAGNOSIS

The differential diagnosis included evolving coronavirus disease-2019 (COVID-19) pneumonia, acute-on-

From the ^aHeart and Vascular Institute, Henry Ford Hospital, Detroit, Michigan; and the ^bDepartment of Infectious Disease, Henry Ford Hospital, Detroit, Michigan. The authors have reported that they have no relationships relevant to the contents of this paper to disclose.

The authors attest they are in compliance with human studies committees and animal welfare regulations of the authors' institutions and Food and Drug Administration guidelines, including patient consent where appropriate. For more information, visit the JACC: Case Reports [author instructions page](#).

Manuscript received April 14, 2020; accepted April 16, 2020.

chronic heart failure exacerbation, acute coronary syndrome, acute pulmonary embolism, myocarditis, and pericardial disease.

INVESTIGATIONS

Chest x-ray film and computed tomography angiogram obtained 1 week prior to admission were negative for pneumonia or pulmonary embolism. Upon re-presentation to the hospital, chest x-ray film demonstrated an enlarged cardiac silhouette and electrocardiography (ECG) revealed low voltage in the limb leads with nonspecific ST-segment changes (Figure 2). Laboratory testing demonstrated normal levels of high-sensitivity cardiac troponin I (cTnI) (<18 ng/l; reference range [RR]: <19 ng/l) and mildly elevated brain natriuretic peptide (54 pg/ml; RR: <50 pg/ml). Transthoracic echocardiography (TTE) (Videos 1 and 2) revealed a large pericardial effusion circumferentially around the entire heart with signs of early right ventricular diastolic collapse, dilated but collapsing inferior vena cava, and mitral valve inflow variation of 31% on pulsed wave Doppler. LVEF was mildly reduced at 40%, with no regional wall motion abnormalities, similar to TTE 1 year prior.

MANAGEMENT

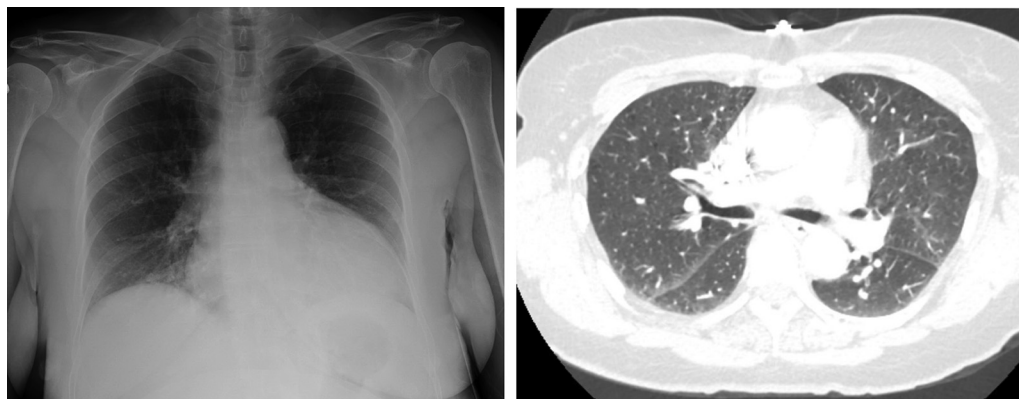
Given the patient's worsening symptoms, rapid expansion of the effusion over 1 week, and early echocardiographic findings of tamponade, we elected to proceed with pericardiocentesis. The patient could not tolerate lying flat because of

severe coughing spells and emesis, so she underwent elective intubation and was taken to the cardiac catheterization laboratory. Pericardiocentesis yielded 800 ml of exudative bloody fluid (fluid lactate dehydrogenase [LDH] 1,697 IU/l, pericardial fluid LDH/serum LDH >0.6). Fluid cytology was negative for malignant cells. Acid-fast bacilli smear was negative, and there was no growth on cultures. Samples of the fluid were frozen in an effort to test the presence of SARS-CoV-2, which is currently not available in our center. Serum autoimmune work-up was negative. In the absence of a history of malignancy, chest trauma, or coagulopathy, we suspected the hemorrhagic effusion to be secondary to COVID-19. Treatment was started with hydroxychloroquine along with colchicine and glucocorticoids given elevated serum inflammatory markers: C-reactive protein (15.9 mg/dl; RR: <0.5 mg/dl), ferritin (593 ng/ml; RR: 11 to 307 ng/ml), D-dimer (6.52 µg/ml; RR: <0.68 µg/ml), and interleukin-6 (8 pg/ml; RR: ≤5 pg/ml). Serial TTE demonstrated resolution of the pericardial effusion; however, the patient was found to have new hypokinesis of the apical and periapical walls concerning for takotsubo cardiomyopathy (TTC) (Video 3). This coincided with a rise in cTnI levels to 2,410 (ng/l) and deep T-wave inversions in precordial leads (V₂ to V₆) (Figure 3). The patient did not develop any chest pain or worsening dyspnea. On the contrary, she reported improvement of

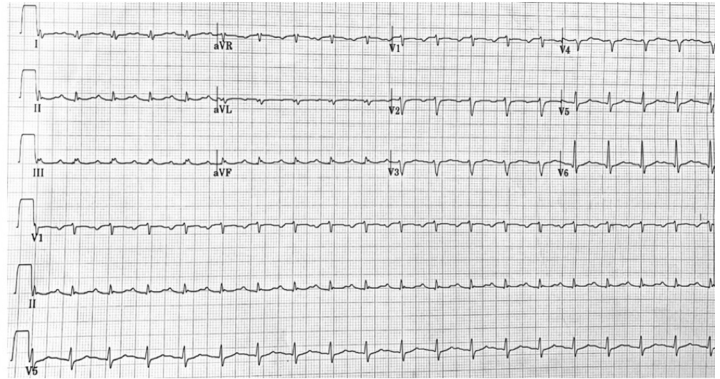
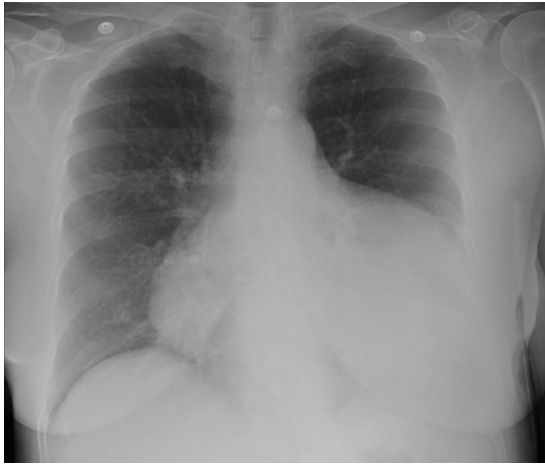ABBREVIATIONS AND ACRONYMS

- COVID-19** = coronavirus disease-2019
- cTnI** = cardiac troponin I
- ECG** = electrocardiography
- LDH** = lactate dehydrogenase
- LVEF** = left ventricular ejection fraction
- RR** = reference range
- SARS-CoV-2** = severe acute respiratory syndrome-coronavirus-2
- TTC** = takotsubo cardiomyopathy
- TTE** = transthoracic echocardiography

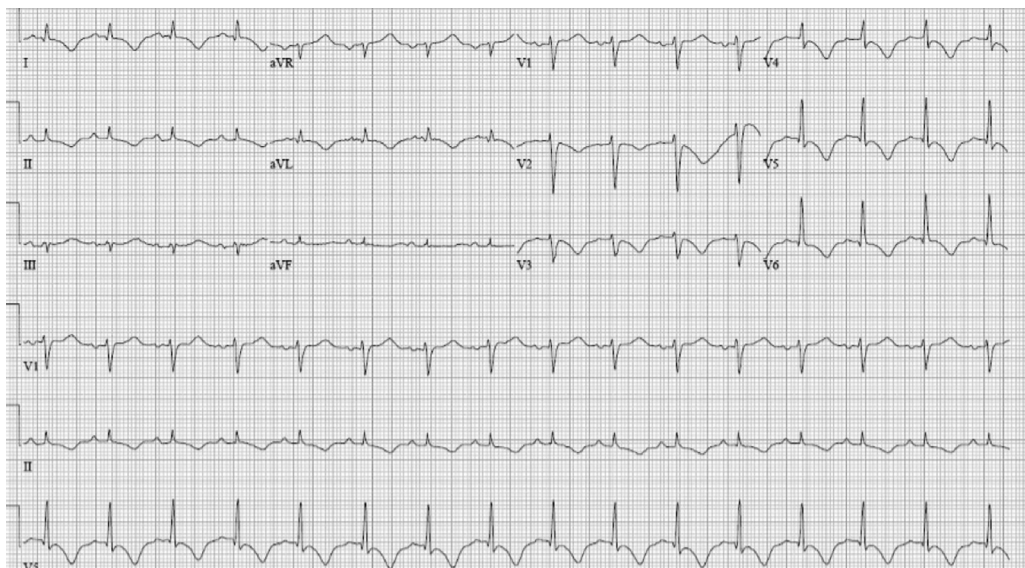
FIGURE 1 Imaging on Initial Presentation



Chest x-ray film (left) and chest computed tomography (right) showing no acute lung disease. Cardiac silhouette appears normal.

FIGURE 2 Chest X-Ray Film and Electrocardiography on Second Presentation

(Left) Chest x-ray film: enlarged cardiac silhouette. **(Right)** Electrocardiography: normal sinus rhythm with low-voltage QRS complex in limb leads and nonspecific ST-segment changes in precordial leads.

FIGURE 3 Electrocardiogram After Pericardiocentesis

Electrocardiography: sinus rhythm with deep T-wave inversions in precordial leads V₂ to V₆.

dyspnea and was subsequently discharged from the hospital.

DISCUSSION

SARS-CoV-2 is the novel virus that causes COVID-19 (1). Early studies from Wuhan, China, demonstrated that patients commonly develop fever, upper respiratory symptoms, and pneumonia (2). As the disease has spread globally, reports of extrapulmonary manifestations have been frequently identified; however, pericardial involvement has been rarely reported (3,4). Here, we report the case of a patient who developed large symptomatic hemorrhagic pericardial effusion causing cardiac tamponade. There were no initial signs of cardiac injury or myocardial involvement, as demonstrated by the absence of cTnI elevation or wall motion abnormalities on TTE. In fact, her symptoms were relatively mild until the development of pericardial effusion.

Viral infections are a common cause of pericarditis and typically entail a benign clinical course (5). Hemorrhagic pericardial effusions have been less commonly associated with viral infections but have been reported in coxsackievirus (6). It is hypothesized that viruses cause pericardial inflammation via direct cytotoxic effects or via immune-mediated mechanisms (5). COVID-19 has been reported to trigger an exaggerated systemic inflammatory response in certain patients; however, details of this response are not fully understood (3). It is plausible that COVID-19, similar to other viral infections, elicits an inflammatory response, leading to pericarditis and subsequent effusion; however, the exact mechanism is unclear. Hemorrhagic effusions have also been reported in other inflammatory states such as Dressler's syndrome, which is thought to result from an immune complex deposition and a subsequent inflammatory cascade post-myocardial infarction (7,8).

After pericardiocentesis, our patient developed TTC as evident by TTE, ECG findings, and cTnI elevation. TTC is a stress-induced cardiomyopathy characterized by transient apical ballooning with regional wall motion abnormalities that occur in association with identifiable emotional or physical stressors including infections (9). The Mayo Clinic proposed the following diagnostic criteria for diagnosis of TTC: transient segmental left ventricular systolic dysfunction, absence of obstructive coronary artery disease, new

ECG abnormalities or modest cardiac troponin elevation, and absence of pheochromocytoma or myocarditis (9). Our patient met these diagnostic criteria clinically and echocardiogram was consistent with apical ballooning. Cardiac magnetic resonance would have definitively ruled out the presence of myocarditis. However, it was not performed, as the patient's condition continued to improve, and we sought to further avoid nonessential medical testing to minimize spread of the disease. Acute coronary syndrome was unlikely, as coronary angiography from 2 years prior showed no significant coronary artery disease, and the patient demonstrated no symptoms of acute coronary syndrome. Although TTC has been widely reported in the setting of severe bacterial infections, cases of TTC attributed to viral infections such as influenza are rare (10). In our case, troponin elevation and apical hypokinesis occurred only after intubation and pericardiocentesis; therefore, stress from these procedures is also a possible etiology.

FOLLOW-UP

Our patient received hydroxychloroquine and low-dose glucocorticoids as per our institutional treatment protocol; however, it is important to note that currently there are no proven data for efficacy of this regimen for COVID-19. We also treated our patient with colchicine, given the elevated inflammatory makers. The patient was continued on guideline-directed medical therapy for nonischemic cardiomyopathy including beta-blockers, angiotensin receptor blockers, and spironolactone. Repeat TTE prior to discharge demonstrated stable ejection fraction and resolution of pericardial effusion.

CONCLUSIONS

We report a rare presentation of COVID-19 infection complicated by a large symptomatic hemorrhagic pericardial effusion and development of TTC.

ADDRESS FOR CORRESPONDENCE: Dr. Mohammed F. Dabbagh, Heart and Vascular Institute, Henry Ford Hospital, 2799 West Grand Boulevard, K14, Detroit, Michigan 48202. E-mail: mdabbag1@hfhs.org. Twitter: [@FerrasDabbagh1](https://twitter.com/FerrasDabbagh1).

REFERENCES

1. World Health Organization. Naming the coronavirus disease (COVID-19) and the virus that causes it. Available at: [https://www.who.int/emergencies/diseases/novel-coronavirus-2019/technical-guidance/naming-the-coronavirus-disease-\(covid-2019\)-and-the-virus-that-causes-it](https://www.who.int/emergencies/diseases/novel-coronavirus-2019/technical-guidance/naming-the-coronavirus-disease-(covid-2019)-and-the-virus-that-causes-it). Accessed March 31, 2020.
2. Guan WJ, Ni ZY, Hu Y, et al. Clinical characteristics of coronavirus disease 2019 in China. *N Engl J Med* 2020;382:1708-20.
3. Inciardi RM, Lupi L, Zaccone G, et al. Cardiac involvement in a patient with coronavirus disease 2019 (COVID-19). *JAMA Cardiol* 2020 Mar 27 [E-pub ahead of print].
4. Salehi S, Abedi A, Balakrishnan S, Gholamrezaezhad A. Coronavirus disease 2019 (COVID-19): a systematic review of imaging findings in 919 patients. *AJR Am J Roentgenol* 2020;215:87-93.
5. Adler Y, Charron P, Imazio M, et al. 2015 ESC Guidelines for the diagnosis and management of pericardial diseases: the Task Force for the Diagnosis and Management of Pericardial Diseases of the European Society of Cardiology (ESC) Endorsed by: The European Association for Cardio-Thoracic Surgery (EACTS). *Eur Heart J* 2015;36:2921-64.
6. Hamasaki A, Uchida T, Yamashita A, et al. Cardiac tamponade caused by acute coxsackievirus infection related pericarditis complicated by aortic stenosis in a hemodialysis patient: a case report. *Surg Case Rep* 2018;4:141.
7. Hertzeanu H, Almog C, Algom M. Cardiac tamponade in Dressler's syndrome. Case report. *Cardiology* 1983;70:31-6.
8. Paelinck B, Dendale PA. Images in clinical medicine. Cardiac tamponade in Dressler's syndrome. *N Engl J Med* 2003;348:e8.
9. Scantlebury DC, Prasad A. Diagnosis of takotsubo cardiomyopathy. *Circ J* 2014;78:2129-39.
10. Cappelletti S, Ciallella C, Aromatario M, et al. Takotsubo cardiomyopathy and sepsis. *Angiology* 2017;68:288-303.

KEY WORDS COVID-19, pericardial effusion, takotsubo cardiomyopathy, tamponade

APPENDIX For supplemental videos, please see the online version of this paper.