

Effect of Extracorporeal Photopheresis on Selected Immunologic Parameters in Psoriasis Vulgaris

ERIC C. VONDERHEID, M.D.,^a ROBERT D. BIGLER, M.D.,^b
THOMAS J. ROGERS, Ph.D.,^c MARSHALL E. KADIN, M.D.,^d
AND THOMAS D. GRIFFIN, M.D.^e

^a*Professor of Medicine, Division of Dermatology, Hahnemann University, Philadelphia, Pennsylvania;* ^b*Assistant Professor of Neoplastic Diseases, Hahnemann University, Philadelphia;* ^c*Associate Professor of Microbiology and Immunology, Temple University School of Medicine, Philadelphia;* ^d*Associate Professor of Pathology, Harvard Medical School and Beth Israel Hospital, Boston, Massachusetts;* ^e*Assistant Clinical Professor of Dermatology, University of Pennsylvania and Graduate Hospital, Philadelphia*

Received July 10, 1989

Extracorporeal photopheresis (ExP) was administered every other week in an outpatient setting to four patients with chronic refractory psoriasis vulgaris without arthropathy. The duration of treatment ranged from six to 13 months. Two patients received methotrexate concomitantly during the initial phase of the study. All patients demonstrated a decrease in erythema, induration, and scaling of lesional skin, accompanied by incomplete clearing of lesions such that the percentage of involvement (SI) ranged between 40 to 80 percent of baseline scores. Exacerbations of psoriasis occurred with minor provocations, and two patients who were predisposed to developing epithelial skin neoplasms as a consequence of prior treatments continued to develop tumors during the study interval. Prolonged ExP treatment was otherwise well tolerated, without evidence of toxicity on routine laboratory safety tests or changes in lymphocyte counts. All patients, however, exhibited decreased intradermal skin responses to recall antigens and a decreased capacity of peripheral lymphocytes to produce interleukin 2 (IL-2) in response to polyclonal stimuli *in vitro*. These observations suggest that the observed anti-inflammatory effect of alternate-week ExP on psoriasis is mediated in part to a direct inhibition of lymphokine production or release by psoralen-ultraviolet-exposed lymphocytes.

INTRODUCTION

Extracorporeal photochemotherapy or photopheresis (ExP) is a recently introduced treatment for patients with cutaneous T-cell lymphoma (CTCL) and potentially other lymphocyte-mediated disorders [1]. With this procedure, peripheral blood leukocytes (containing about 50 percent lymphocytes) are collected by discontinuous leukapheresis, combined with plasma containing the photoactive drug 8-methoxypsoralen (8-MOP) which the patient takes as an oral dose about two hours before, and then exposed to long-wave ultraviolet radiation (UVA) before reinfusing the lethally irradiated cells back to the patient. Edelson has postulated that the reinfused

653

Abbreviations: ANA: antinuclear antibody CTCL: cutaneous T-cell lymphoma 8-MOP: 8-methoxypsoralen ExP: extracorporeal photopheresis IFN-gamma: interferon gamma IL-1: interleukin 1 IL-2: interleukin 2 MTX: methotrexate NK: natural killer PASI: psoriasis area and severity index PUVA: psoralen-ultraviolet A SI: skin surface involvement UVA: long-wave ultraviolet

Address reprint requests to: Eric C. Vonderheid, M.D., Division of Dermatology, Mailstop 401, Hahnemann University, Broad and Vine Streets, Philadelphia, PA 19002

Copyright © 1989 by The Yale Journal of Biology and Medicine, Inc.

All rights of reproduction in any form reserved.

photomodified malignant cells present in the peripheral blood may provide a potent immunogenic stimulus that leads to the development of clonotypic inhibitory immune responses against the malignant T cells in CTCL [2,3].

Considering the mounting evidence that lymphocyte-mediated responses play an important role in the pathogenesis of psoriasis [4–7], we conducted a pilot study in four patients with severe psoriasis vulgaris to determine whether ExP might be therapeutically useful in this disease [8]. This report presents preliminary evidence that administration of ExP every other week has anti-inflammatory effects in psoriasis because of direct effects on circulating lymphocytes reminiscent of those produced by cyclosporine A [6,9].

METHODS

Patients

Four patients with severe refractory psoriasis vulgaris were treated with ExP between July 1987 and October 1988 in an outpatient facility located at Skin and Cancer Hospital, Temple University Health Sciences Center. All had long-standing psoriasis vulgaris, with plaques involving more than 30 percent of the body surface and historical evidence of failing to respond adequately to standard antipsoriatic treatment regimens, and none had evidence of psoriatic arthropathy. Patients 2 and 4 had previously been treated with large cumulative doses of psoralen-ultraviolet A (PUVA), resulting in the formation of multiple epithelial neoplasms in the years preceding the start of ExP. Patient 2 had had five actinic keratoses, 14 keratoacanthomas, one basal cell carcinoma, and four squamous cell carcinomas removed since 1980; patient 4 had had three keratoacanthomas and one basal cell carcinoma removed since 1985. Patient 4 had also experienced methyldopa-induced arthralgias and myalgias associated with a positive 1:1,280 antinuclear antibody (ANA) titer in 1977. Her ANA remained weakly positive off the drug and was 1:40 at the start of ExP. The clinical data concerning the four treated patients is summarized in Table 1.

Treatment Protocol

Each ExP session consisted of the oral administration of methoxypsalen (8-MOP, Oxsoralen, Elder, Bryan, OH) at a dose of 0.6 mg/kg, followed two hours later by collection of leukocyte-enriched blood by discontinuous leukapheresis, using the prototype of the UVAR Photopheresis System (Therakos, King of Prussia, PA). A total of 240 ml of leukocyte-enriched blood is collected and combined with 300 ml of the patient's plasma and 200 ml of sterile normal saline, and then passed as a 1 mm film through a six-chambered disposable sterile cassette exposed to long-wave ultraviolet (UVA) radiation in order to activate the 8-MOP. The leukocyte mixture is given a 270-minute exposure, which provides the average cell with 2 J/cm² of UVA radiation. After the irradiation phase, the entire amount of blood is returned to the patient. Each patient also underwent an initial mock treatment session in which 8-MOP was taken and blood was collected and reinfused without exposure to UVA. Thus, ExP provides for the exposure of a large number of peripheral blood lymphocytes to the effects of photoactivated 8-MOP.

Response to treatment was assessed using two scoring parameters: the percentage of skin surface involvement (SI) and the psoriasis area and severity index (PASI) described originally by Fredriksson and Pettersson [10]. The maximum possible scores

TABLE 1
Clinical Information on Patients with Psoriasis Vulgaris Treated with Extracorporeal Photopheresis

| Patient | Age, Race, Sex | Duration of Disease (years) | Prior Treatments | Other Skin Problems |
|---------|----------------|-----------------------------|---|---|
| 1 | 46, W, M | 12 | Tar + UVB PUVA (112 J/cm ²) MTX (625 mg) | Lichen simplex chronicus Tinea pedis/cruris |
| 2 | 49, W, M | 21 | Prednisone Isotretinoin MTX (2,365 mg) PUVA (> 4,100 J/cm ²) | Epithelial tumors ^a Herpes zoster Verrucae |
| 3 | 27, W, F | 10 | Prednisone Tar + UVB PUVA | None |
| 4 | 50, W, F | 31 | Tar + UVB MTX (595 mg) PUVA (> 8,000 J/cm ²) | Epithelial tumors ^a Herpes zoster |

^aRefer to text for details about tumor types.

for SI and PASI were 100 percent and 72.0, respectively. Punch biopsy specimens from representative psoriatic plaques were taken at three-month intervals and processed for histopathology and immunohistochemistry, using methods previously reported [11]. Intradermal skin testing to *Candida* (1:500), trichophytin (1:500), and PPD-tuberculin (5TU) antigens was performed at six-month intervals.

All patients were monitored at regular intervals throughout the study for evidence of toxicity with a battery of tests, including complete blood counts, biochemical profile, urinalysis, electrocardiograms, and chest roentgenograms. Additional blood samples were obtained at three-month intervals for levels of serum immunoglobulins (IgG, IgM, IgA, and IgE), the C³ and C⁴ components of complement, ANA and anticytoplasmic antibodies (anti-Ro, anti-La), circulating immune complexes, and blood lymphocyte subset analysis, using a panel of commercially available murine monoclonal antibodies (Table 2).

Patients also had blood samples taken one week after the mock treatment session (baseline) and one week after the first (week 1), seventh (three-month), and thirteenth (six-month) ExP sessions for measurement of interleukin 2 (IL-2) responses by lymphocytes *in vitro* to concanavalin A and staphylococcus enterotoxin B. Peripheral blood mononuclear cells were cultured at 10⁶ cells/ml in a tissue culture medium composed of RPMI-1640, supplemented with 5 percent AB serum and 2 mg/ml glutamine for 48 hours at 37°C with or without mitogen stimulation. The supernatants were collected at the termination of culture, and the IL-2 produced was determined by a method modified from Gillis et al. [12]. This assay is based on the capacity of IL-2-containing supernatants to support the growth of the IL-2-dependent cell line CT-20. CT-20 cells were washed three times and resuspended in Dulbecco's minimal essential medium, supplemented with 2 percent fetal calf serum and 50 mcg/ml gentamicin, and 10⁴ cells were placed in 96-well microplates containing serial dilutions of the supernatants to be tested. After incubation for 20 hours, 0.5 μ Ci tritiated thymidine was added, and the thymidine uptake was measured after an additional four hours. Calculation of unit values was carried out as described by Gillis [12].

TABLE 2
Monoclonal Antibodies Used to Immunophenotype Peripheral Blood Lymphocytes^a

| Antibody | Source | Cluster Designation | Antigen Distribution |
|---------------------------|--------------------|---------------------|--------------------------------------|
| T-cell Markers | | | |
| OKT11 | Ortho | CD2 | Pan T-cell, NK cells (SRBC receptor) |
| OKT3 | Ortho | CD3 | Pan T-cell (TCR complex) |
| OKT4 | Ortho | CD4 | T helper/inducer, monocytes |
| OKT8 | Ortho | CD8 | T suppressor/cytotoxic, NK subset |
| B-cell Markers | | | |
| Leu12 | B-D | CD19 | Pan B-cell |
| Leu16 | B-D | CD20 | Pan B-cell, dendritic cells |
| Anti-kappa | Tago | — | Pan B-cell |
| Anti-lambda | Tago | — | Pan B-cell |
| Activation Markers | | | |
| Anti-HLA-DR | B-D | DR | Class II MHC antigen |
| Anti-Tac | Other ^b | CD25 | Activated T-cells (IL-2 receptor) |
| 5E9 | ATCC | CD71 | Transferrin receptor |
| OKT10 | Ortho | CD38 | Restricted multiple lineages |
| Other Markers | | | |
| Leu7 | B-D | CD57 | NK cells |
| Leu11 | B-D | CD16 | NK Cells, PMNs |
| LeuM3 | B-D | CD14 | Monocytes, PMNs |
| OKT6 | Ortho | CD1a | Thymocytes, Langerhans cells |

^aB-D, Becton-Dickinson, Mountain View, CA; Ortho, Ortho Diagnostic Systems, Raritan, NJ; ATCC, American Type Culture Collection, Rockville, MD; NK cells, natural killer cells; PMNs, Polymorphonuclear cells; MHC, mixed histocompatibility complex

^bAnti-Tac antibody is a gift from Thomas Waldmann, M.D.

RESULTS

Clinical Observations

All patients improved to some degree while on ExP (refer to [8] for details). The responses were characterized by decreasing erythema, induration, and scaling initially, followed by actual clearing of some, but not all lesions (Table 3). Of the two response parameters, PASI was much more sensitive to the changes in inflammatory events in lesional skin, correlated well to the patient's symptomatology, and often preceded changes in SI by several weeks; however, SI provided the more clinically relevant parameter to judge overall response.

Compliance to the protocol by all patients was excellent. Patients 1 and 2 were treated concomitantly with methotrexate (MTX) given orally at a dose of 25 mg every other week, alternating with ExP to prevent an exacerbation of disease. Gradually, over the next six months, the dose of MTX was decreased and eventually discontinued. Both patients steadily improved on combined therapy to reach an optimum PASI and SI scores of 2.7 and 9 percent for patient 1 and 5.4 and 30 percent for patient 2, respectively. When maintained on ExP alone, however, their psoriasis began to flare such that lower, previously ineffective doses of MTX (12.5 mg every other week) were administered to determine whether combination therapy would be of benefit. Patient 1 responded only minimally to this regimen, but patient 2 again showed steady improvement until the end of the study.

TABLE 3
Summary of Response Scores in Patients with Psoriasis Vulgaris Treated with ExP

| Patient | ExP Session | Week | PASI | SI (%) | Histopathology |
|---------|-------------|------|------|--------|----------------|
| 1 | Mock | 0 | 18.0 | 40 | Acute |
| | 7 | 13 | 14.4 | 37 | Acute |
| | 13 | 25 | 2.7 | 10 | Chronic |
| | 19 | 37 | 13.5 | 17 | Subacute |
| | 25 (end) | 49 | 15.3 | 20 | Subacute |
| 2 | Mock | 0 | 26.7 | 49 | Chronic |
| | 7 | 13 | 5.4 | 30 | Subacute |
| | 13 | 25 | 9.4 | 38 | Acute |
| | 19 | 37 | 18.8 | 67 | Subacute |
| | 25 | 49 | 6.5 | 43 | Acute |
| | 29 (end) | 57 | 7.1 | 41 | ND |
| 3 | Mock | 0 | 15.9 | 48 | Acute |
| | 7 | 13 | 5.2 | 26 | Chronic |
| | 13 (end) | 25 | 8.5 | 24 | Subacute |
| 4 | Mock | 0 | 14.9 | 48 | Acute |
| | 7 | 13 | 24.3 | 51 | Acute |
| | 13 | 25 | 6.0 | 38 | Chronic |
| | 19 | 37 | 4.8 | 24 | ND |
| | 23 (end) | 45 | 30.4 | 72 | ND |

ND, not done

The other two patients were treated with ExP alone. The psoriasis of patient 3 responded partially over the first three months (PASI, 5.2; SI, 24 percent) but then became worse due to seasonal factors, and she elected to discontinue ExP after six months. The psoriasis of patient 4, after an initial mild exacerbation attributed to withdrawal from prior treatments, improved steadily over the next seven months to a PASI of 4.6 and SI of 23 percent. With the change in the season, however, her disease flared severely beginning after the nineteenth treatment session (37 weeks), and she had to be hospitalized.

ExP was extremely well tolerated and not accompanied by evidence of toxicity on laboratory safety tests. During the study interval, however, patient 2 developed ten keratoacanthomas and one squamous cell carcinoma, and patient 4 developed one keratoacanthoma and two squamous cell carcinomas. These lesions occurred primarily on the legs, which had received extra treatments of PUVA in the past.

Post-Treatment Observations

A few clinical observations have been made in the 12 months after ExP that may pertain to chronic or delayed effects of ExP. Patient 1, who had chronic tinea pedis and cruris due to *Trichophyton rubrum*, developed Majocchi's granuloma on the left arm ten months after ExP (Fig. 1). There otherwise was nothing unusual about his dermatophyte infection. Patient 2, who had long-standing verrucae on the legs prior to ExP, observed most of these lesions to regress spontaneously 28 weeks after ExP (Fig. 2). Skin testing to recall antigens remained unreactive, but the production of IL-2 by peripheral lymphocytes was found to be increased (see below). The persistent low-titer ANA level of patient 4 prior to ExP (baseline measurement, 1:40) became unreactive after six months of ExP, but was again positive (1:320) when checked six months after completing ExP.

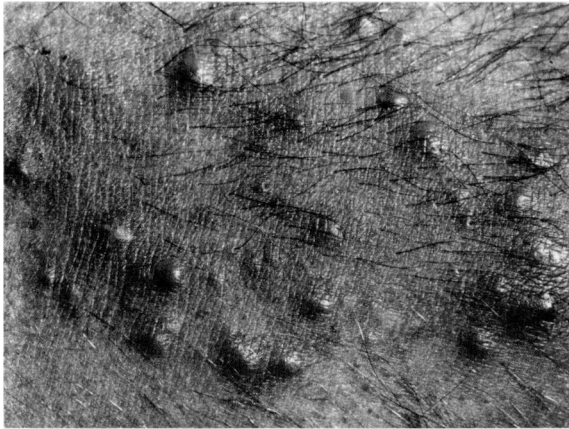


FIG. 1. Cluster of infiltrated papules that developed on the forearm of patient 1 ten months after stopping ExP. A biopsy specimen showed features of a suppurative and granulomatous folliculitis with hyphae within a hair shaft in the dermis consistent with Majocchi's granuloma.

Pathology

There generally was good agreement between histopathologic findings and the overall clinical status of the patient (Table 3). The baseline biopsy specimens from three patients (patient 1, patient 3, and patient 4) showed the features of acute psoriasis prior to ExP and less acute changes in subsequent analyses corresponding to changes in the PASI. For patient 2, however, the histopathologic features correlated poorly with the PASI, possibly the result of sampling "hot spots" within an improving psoriatic lesion [13]. The immunopathologic findings on the same specimens correlated less well to the clinical status. All patients exhibited a clear predominance of CD4+ cells in the dermal infiltrate of baseline biopsy specimens, resulting in a high CD4/CD8 ratio, as might be expected in actively evolving psoriasis. In patients 2 and 4, the specimens at nine months contained an increased number of CD8+ cells, as might be expected in regressing lesions. The level of Tac expression by lymphoid cells varied from nearly absent to low levels and did not correlate with improvement or exacerbations of disease. In the epidermis, the number of keratinocytes expressing T9 and DR antigen varied considerably without apparent correlation to disease activity. Many dendritic cells (Langerhans cells) were also DR-positive.

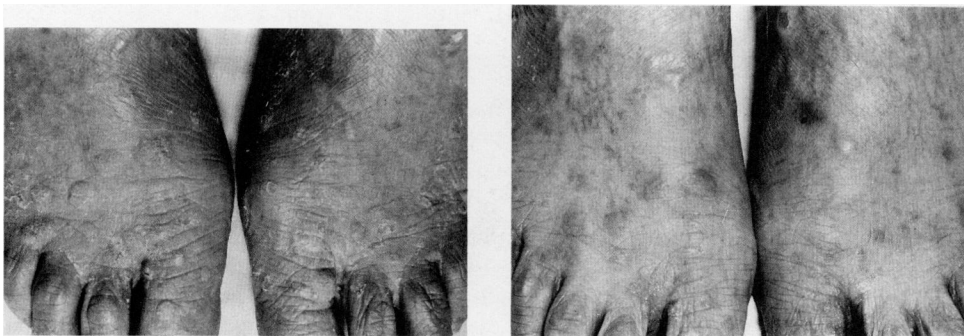


FIG. 2. A. Multiple verrucae on the feet of patient 2 prior to the start of ExP. B. Regression of verrucae to leave hyperpigmentation seven months after stopping ExP.

TABLE 4
Skin Test Results in Patients Treated with Extracorporeal Photopheresis^a

| Patient | Antigen | Pre-ExP | 6 Months | 12 Months | Post-ExP ^b |
|---------|--------------|-------------|----------|-----------|-----------------------|
| 1 | PPD | neg | neg | neg | pos (10 mm) |
| | Trichophytin | pos (30 mm) | neg | neg | neg |
| | Candida | neg | neg | neg | neg |
| 2 | PPD | ?pos (5 mm) | neg | neg | neg |
| | Trichophytin | pos (15 mm) | neg | neg | neg |
| | Candida | neg | neg | neg | neg |
| 3 | PPD | neg | neg | ND | ND |
| | Trichophytin | neg | neg | ND | ND |
| | Candida | neg | neg | ND | ND |
| 4 | PPD | neg | neg | neg | neg |
| | Trichophytin | pos (11 mm) | neg | neg | neg |
| | Candida | neg | neg | neg | neg |

^aSkin test results recorded as neg (negative), pos (positive) with millimeters of induration at 48 hours, or ND (not done)

^bSkin tests applied at 16, 20/30, and 22 weeks after discontinuing ExP on patients 1, 2, and 4, respectively

Skin Testing

The results of intradermal skin testing to *Candida*, trichophytin, and PPD-tuberculin antigens are presented in Table 4. Three patients reacted positively to at least one recall antigen prior to starting ExP, and all became non-reactive within the first six months of treatment. Moreover, the tests remained negative for at least several months after treatments had been stopped.

Lymphocyte Subsets and Immunoglobulins

Changes observed on absolute lymphocyte counts, lymphocyte subsets, and serum IgE levels are summarized in Table 5. The absolute lymphocyte counts for all patients were within normal limits throughout the study except for patient 3, whose baseline lymphocyte count was increased (WBC, 7,500, with 57 percent lymphocytes); this count promptly reverted to normal on subsequent tests. Quantitative IgG, IgM, and IgA levels remained within normal limits. None of the patients developed evidence of antinuclear or anticytoplasmic antibodies, immune complexes, or altered complement levels.

Immunophenotyping revealed only minor changes in lymphocyte subsets for each patient (Table 5). Patient 1 showed an absolute decrease in B cells, which remained unchanged during the study, and only a transient decrease in the number of CD8+ cells at three months. Patient 2 had a normal absolute number of T cells in the baseline specimen, but below normal numbers in specimens obtained at three, six, and 12 months, although the CD4/CD8 ratio remained relatively constant. In addition, there was a relative increase in natural killer (NK) cells and decrease in B cells in the baseline specimen, followed by gradual normalization of these parameters during treatment. Patient 3 had an absolute increase in both CD4 and CD8 cells in the baseline sample, particularly the CD8+ subset, and this increase resulted in a low CD4/CD8 ratio. The high baseline absolute T-cell count of patient 3 decreased to normal within three months, with CD4+ cells affected slightly more than CD8+ cells,

TABLE 5
Selected Blood Immunologic Parameters in Patients Treated with Extracorporeal Photopheresis

| Patient | Parameter | Pre-ExP | 3-Month | 6-Month | 9-Month | 12-Month |
|---------|-------------------|---------|---------|---------|---------|----------|
| 1 | PASI | 18.0 | 14.4 | 2.7 | 13.5 | 15.3 |
| | Lymphocyte count | 1,575 | 2,418 | 1,966 | 1,650 | 1,462 |
| | % T cells | 78 | 60 | 71 | 68 | 79 |
| | CD4/CD8 ratio | 2.8 | 5.0 | 2.6 | 2.0 | 3.5 |
| | % B cells | 3 | 2 | 6 | 3 | 4 |
| | % NK cells | 9 | 8 | 4 | 11 | ND |
| | Serum IgE (IU/ml) | 432 | 598 | 340 | ND | 593 |
| 2 | PASI | 26.6 | 5.4 | 9.4 | 18.8 | 6.5 |
| | Lymphocyte count | 2,480 | 1,670 | 1,524 | 2,050 | 1,670 |
| | % T cells | 58 | 52 | 57 | 64 | 50 |
| | CD4/CD8 ratio | 1.3 | 1.7 | 1.5 | 1.9 | 1.7 |
| | % B cells | 3 | 8 | 10 | 12 | 6 |
| | % NK cells | 19 | 18 | 9 | 8 | ND |
| | IgE | 476 | 518 | 383 | ND | 486 |
| 3 | PASI | 15.9 | 5.2 | 8.5 | ND | ND |
| | Lymphocyte count | 4,275 | 1,647 | 1,848 | ND | ND |
| | % T cells | 85 | 69 | 62 | ND | ND |
| | CD4/CD8 ratio | 1.1 | 1.4 | 0.7 | ND | ND |
| | % B cells | 10 | 17 | 14 | ND | ND |
| | % NK cells | ND | ND | 12 | ND | ND |
| | IgE | 385 | 254 | 168 | ND | ND |
| 4 | PASI | 14.9 | 24.3 | 6.0 | 9.2 | ND |
| | Lymphocyte count | 1,311 | 1,496 | 1,380 | 1,418 | ND |
| | % T cells | 57 | 62 | 67 | 54 | ND |
| | CD4/CD8 ratio | 3.7 | 4.4 | 5.3 | 3.9 | ND |
| | % B cells | 38 | 32 | 25 | 34 | ND |
| | % NK cells | <1 | 5 | <1 | 2 | ND |
| | IgE | 222 | 266 | 289 | ND | ND |

ND, not done

resulting in a further decrease in the CD4/CD8 ratio. Patient 4 showed a low to low-normal absolute T-cell count, mostly due to a decrease in CD8+ cells, resulting in an increased CD4/CD8 ratio. Furthermore, the NK cell population was decreased throughout the study and this effect contributed to the relative, but not absolute increase in B cells.

Activation/proliferation antigens on blood lymphocytes were not found to be a very useful parameter to monitor disease activity or response to treatment. It is worth noting, however, that the level of Tac+ cells in the blood was often increased slightly compared to that of normal blood in these patients (data not shown).

Serum IgE levels were increased slightly in all four patients and remained unchanged during treatment, except for patient 3 whose IgE level normalized.

Interleukin 2 Measurements

The production of IL-2 by peripheral blood lymphocytes in response to concanavalin A and staphylococcus enterotoxin B *in vitro* decreased promptly after starting ExP in all patients and was below detection by six months in three patients (Table 6). In patient 2, the study was repeated 29 weeks after ExP ended and was found to have recovered to above baseline levels.

TABLE 6
Production of Interleukin 2 (IL-2) by Peripheral Blood Lymphocytes in Response to Polyclonal Stimuli^a

| Patient | Time ^b | 1 mcg Con A | 10 mcg Con A | 10 mcg SEB |
|-----------------------|-------------------|--------------------------|--------------|-------------|
| 1 | Post-mock | 0.33 ± 0.02 ^c | 1.66 ± 0.09 | 1.60 ± 0.10 |
| | Week 1 | 0.32 ± 0.03 | 0.45 ± 0.07 | 1.23 ± 0.15 |
| | Week 7 | 0.14 ± 0.02 | 0.21 ± 0.03 | ND |
| | Week 13 | <0.09 | <0.09 | <0.09 |
| 2 | Post-mock | 0.24 ± 0.02 | 0.73 ± 0.05 | ND |
| | Week 1 | 0.09 ± 0.01 | 0.31 ± 0.04 | 0.14 ± 0.10 |
| | Week 7 | <0.09 | <0.09 | <0.09 |
| | Week 13 | <0.09 | <0.09 | <0.09 |
| 3 | Post-ExP | 1.90 ± 0.20 | 2.40 ± 0.19 | 2.60 ± 0.22 |
| | Post-mock | 0.21 ± 0.02 | 0.38 ± 0.04 | 0.64 ± 0.06 |
| | Week 1 | <0.09 | 0.12 ± 0.01 | 0.26 ± 0.03 |
| | Week 7 | <0.09 | <0.09 | <0.09 |
| 4 | Post-mock | 0.70 ± 0.14 | 1.10 ± 0.08 | 1.30 ± 0.13 |
| | Week 13 | <0.09 | 0.41 ± 0.04 | 0.62 ± 0.06 |
| Three normal controls | — | 0.29 ± 0.05 | 0.82 ± 0.06 | 1.50 ± 0.15 |

^aCon A, concanavalin A; SEB, staphylococcal enterotoxin B; ND, not determined

^bSpecimens were taken 1 week after Mock treatment, and 1 week after the first, seventh, and thirteenth ExP treatments; patient 2 had an additional specimen taken 29 weeks after stopping ExP.

^cValues expressed as mean ± standard deviation in units relative to an IL-2 standard

DISCUSSION

Recent studies indicate that cellular immune mechanisms play an important role in the pathogenesis of psoriasis [4–6]. The linkage to certain HLA haplotypes suggests that the inflammatory and immunologic events in psoriasis are under immunogenetic control. Lymphocytes are the earliest cells found in incipient psoriatic lesions [14], and T cells predominate in the dermal infiltrate of established lesions [15–19], together with dendritic antigen-presenting cells [17,20]. The *in situ* ratios of T-helper to T-suppressor cells in the dermal infiltrate is relatively increased in developing psoriatic lesions and relatively decreased in regressing lesions [21]. The majority of these T cells are activated and express class II MHC molecules (HLA-DR) and the IL-2 receptor [8,17,21–23]. Expression of HLA-DR by keratinocytes, a common finding in many inflammatory diseases [24], is thought to be the result of interferon gamma (IFN-gamma) produced by the activated T cells [25,26]. Stimulated keratinocytes also elaborate interleukin 1 (IL-1) and other immunoregulatory cytokines, which could enhance the inflammatory changes of psoriasis [27–29]. For example, when injected into human skin, IL-1 alpha causes erythema and edema, with marked mononuclear cell infiltrate [30]. IL-1 also may contribute to the epidermal proliferation [31] and neutrophil chemotaxis [32,33] that are characteristic of psoriasis. Likewise, systemic IL-2 administration has been reported to exacerbate psoriasis [34].

Our immunopathologic studies are consistent with previous reports showing CD4+ lymphocytes to predominate in the dermal infiltrate of active psoriasis, with an increased number of CD8+ cells in lesions undergoing resolution in two patients who were studied by us. Discrepant results may possibly have resulted from histologic heterogeneity within psoriatic plaques [13]. Tac levels were relatively low compared with malignant and premalignant T-cell lymphoproliferative disorders such as cutaneous T-cell lymphoma [35] or lymphomatoid papulosis [36], and correlated with

disease activity only in patient 2. Expression of class II MHC antigens (DR) by keratinocytes was found in both acute and chronic psoriatic lesions and did not correlate well with the overall clinical status of the patient. The expression of high levels of T9 (transferrin receptor) by keratinocytes, especially in the basal layer, is a new, but not unexpected finding, since T9 expression is generally increased in proliferating cells. The prognostic significance of this finding or its value in monitoring response to therapy will have to be determined. Patient 4 showed a marked reduction in T9 expression at the time of best response.

Although conducted on a small number of patients, this study provides preliminary evidence that ExP given on an alternate-week schedule has a definite, but incomplete therapeutic benefit for patients with severe psoriasis vulgaris refractory to standard therapies, that the response can be enhanced by the concurrent administration of low doses of MTX, and that treatment is well tolerated by patients. The mechanism underlying the response of psoriasis to ExP is unknown but presumably is related in part to a direct effect on lymphocyte function. In this regard, the finding that peripheral blood lymphocytes obtained from patients undergoing treatment lose the capacity to produce IL-2 *in vitro* may be relevant, since it is reminiscent of the cellular effects of cyclosporine A, which has been used to treat severe psoriasis [9,37,38]. A major advantage of ExP compared to systemic drugs is that the bone marrow and other organs are spared the direct toxic effects of treatment.

The effect on IL-2 production *in vitro*, the decreased reactivity to skin test recall antigens, and the possible accelerated formation of epithelial skin neoplasms in predisposed patients suggests that ExP may be immunosuppressive. Since, however, blood samples for the IL-2 assay were obtained one week after treatments with ExP, it may be that the observed inhibition of IL-2 is only a transitory phenomenon limited to the immediate post-treatment period. Measurements at other time points are needed to clarify the significance of this observation. Likewise, it is possible that positive skin tests may have become unreactive during ExP because of the generation of specific inhibitory responses against T cells mediating the skin test responses, analogous to the mechanism proposed for autoimmune diseases [2]. Finally, the acceleration in formation of epithelial skin tumors may be more apparent than real, since both patients had a history of developing such tumors predating the onset of ExP, and one patient was treated concomitantly with MTX. Nevertheless, we feel this observation is sufficiently provocative to warrant reporting it. Prolonged ExP did not result in a reduction of absolute lymphocyte counts or major alterations in lymphocyte subsets in the peripheral blood.

The clinical experience with ExP in erythrodermic variants of CTCL is relevant to provide perspective to the current results. As recently summarized by Edelson [3], patients with this condition usually receive two consecutive sessions of ExP at four-week intervals. The best responses occurred in patients who were immunocompetent, suggesting that they might be able to mount an immunologic response to photomodified malignant T cells. Immunodeficient patients also may respond significantly to ExP if treatments are given more frequently, which is probably the consequence of the simple physical destruction of tumor cells. Our observations suggest that an additional biologic mechanism, namely inhibition of lymphokine production or release by psoralen-ultraviolet-exposed cells, may contribute to the clinical benefit in CTCL, particularly for those with erythrodermic manifestations. Indeed, one of us has observed a patient with Sézary syndrome whose erythroderma cleared completely on

ExP, despite retaining the presence of a chromosomally abnormal malignant T-cell clone in the blood [Vonderheid E: personal observation].

ACKNOWLEDGEMENT

This study was supported by grants from the Benjamin Franklin Partnership of Pennsylvania, the Leonard and Ruth Levine Temple Skin Research Fund, and NIH-NIAID AI-23828 (Dr. Rogers). The authors thank Gerald Pearlman for preparation of the illustrations and Eufrocina Laudico, R.N., for her assistance in this study.

REFERENCES

1. Edelson R, Berger C, Gasparro F, Jegasothy B, Heald P, Wintroub B, Vonderheid E, Knobler R, Wolff K, Plewig G, McKiernan G, Christiansen I, Oster M, Honigsmann H, Wilford H, Kokoschka E, Rehle T, Perez M, Stingl G, Laroche L: Treatment of cutaneous T-cell lymphoma by extracorporeal photochemotherapy. *N Engl J Med* 316:297-303, 1987
2. Edelson R: Light activated drugs. *Scientific Amer* 259:68-75, 1988
3. Edelson RL: Update on photopheresis. *Prog in Dermatol* 23:1-7, 1989
4. Valdimarsson H, Baker BS, Jonsdottir I, Fry L: Psoriasis: A disease of abnormal keratinocyte proliferation induced by T lymphocytes. *Immunology Today* 7:256-259, 1986
5. Gottlieb AB: Immunologic mechanisms in psoriasis. *J Am Acad Dermatol* 18:1376-1380, 1988
6. Bos JD: The pathomechanisms of psoriasis; The skin immune system and cyclosporin. *Br J Dermatol* 118:141-155, 1988
7. Dahl MV: *Clinical Immunodermatology*. Chicago, Year Book Medical Publishers Inc, 1988, pp 268-278
8. Vonderheid EC, Kang C-A, Kadin M, Bigler RD, Griffin TD, Rogers TJ: Extracorporeal photopheresis in psoriasis: Clinical and immunologic observations. *J Am Acad Dermatol*, submitted for publication
9. Bunjes D, Hardt C, Rollinghoff M, Wagner H: Cyclosporin A mediates immunosuppression of primary cytotoxic T cell responses by impairing the release of interleukin-1 and interleukin-2. *Eur J Immunol* 11:657-661, 1981
10. Fredriksson T, Pettersson U: Severe psoriasis: Oral therapy with a new retinoid. *Dermatologica* 157:238-244, 1978
11. Muramoto LM, Kadin ME: Improved detection of lymphoid cell surface antigens in tissues fixed in periodate-lysine-paraformaldehyde (PLP). *Am J Clin Path* 88:589-595, 1987
12. Gillis S, Ferm MM, Ou W, Smith KA: T-cell growth factor: Parameters of production and a quantitative microassay for activity. *J Immunol* 120:2027-2032, 1978
13. Griffin TD, Lattanand A, VanScott EJ: Clinical and histologic heterogeneity of psoriatic plaques: Therapeutic relevance. *Arch Dermatol* 124:216-220, 1988
14. Ragaz A, Ackerman AB: Evolution, maturation, and regression of lesion of psoriasis. *Am J Dermatopathol* 1:199, 1979
15. dePanfilis G, Allegra F: Immunohistochemical study of dermal cell population in psoriatic skin. *Acta Derm-Venerol (Supplement 87):*22-26, 1979
16. Bjerke JR: Subpopulations of mononuclear cells in lesions of psoriasis, lichen planus and discoid lupus erythematosus studied with monoclonal antibodies. *Acta Derm-Venerol* 62:477-483, 1982
17. Bos JD, Hulsebosch HJ, Krieg SR, Bakker PM: Immunocompetent cells in psoriasis; in situ immunophenotyping by monoclonal antibodies. *Arch Dermatol Res* 275:181-189, 1983
18. Baker BS, Swain AF, Valdimarsson H, Fry L: T cell subpopulations in the blood and skin of patients with psoriasis. *Br J Dermatol* 110:37-44, 1984
19. Kaudewitz P, Braun-Falco O, Kind P, Galosi A, Rieber P, Riethmuller G: Distribution of T cell subsets as defined by monoclonal antibodies in skin lesions of psoriasis vulgaris. *Arch Dermatol Res* 276:33-35, 1984
20. Bos JD, van Garderen ID, Krieg SR, Poulter LW: Different in situ distribution patterns of dendritic cells having Langerhans (T6+) and interdigitating (RFD1+) cell immunophenotype in psoriasis, atopic dermatitis, and other inflammatory dermatoses. *J Invest Dermatol* 87:358-361, 1986
21. Baker BS, Swain AF, Fry L, Valdimarsson H: Epidermal T lymphocytes and HLA-DR expression in psoriasis. *Br J Dermatol* 110:555-564, 1984
22. Morhenn VB, Abel EA, Mahrle G: Expression of HLA-DR antigen in skin from patients with psoriasis. *J Invest Dermatol* 78:165-168, 1982

23. Bjerke JR, Matre R: Demonstration of Ia-like antigens on T lymphocytes in lesions of psoriasis, lichen planus and discoid lupus erythematosus. *Acta Derm-Venerol* 63:103-107, 1983
24. Aubock J, Romani N, Grubauer G, Fritsch P: HLA-DR expression on keratinocytes is a common feature of diseased skin. *Br J Dermatol* 114:465-472, 1986
25. Nickoloff BJ, Basham TY, Merigan TC, Morhenn VB: Keratinocyte class II histocompatibility antigen expression. *Br J Dermatol* 112:373-374, 1985
26. Czernielewski JM, Bagot M: Class II MHC antigen expression by human keratinocytes results from lympho-epidermal interactions and gamma interferon production. *Clin Exp Immunol* 66:295-302, 1986
27. Kupper TS, Ballard DW, Chua AO, McGuire JS, Flood PM, Horowitz MC, Langdon R, Lightfoot L, Gubler U: Human keratinocytes contain mRNA indistinguishable from monocyte interleukin 1 alpha and beta mRNA. *J Exp Med* 164:2095-2100, 1986
28. Luger TA, Stadler BM, Katz SI, Oppenheim JJ: Epidermal cell (keratinocyte) derived thymocyte activating factor. *J Immunol* 127:1493-1498, 1981
29. Sauder DN: Interleukin 1. *Arch Dermatol* 125:679-682, 1989
30. Dowd PM, Camp RDR, Greaves MW: In vivo effects of human recombinant interleukin-1 alpha (IL-1 alpha) in normal human skin. *J Invest Dermatol* 88:485, 1987
31. Gilchrist BA, Sauder DN: Autocrine growth stimulation of human keratinocytes by epidermal cell-derived thymocyte activating factor (ETAf): Implications for cellular aging. *Clin Res* 82:585, 1984
32. Camp RD, Fincham NJ, Cunningham FM, Greaves MW, Morris J, Chu A: Psoriatic lesions contain biologically active amounts of an interleukin 1-like compound. *J Immunol* 137:3469-3474, 1986
33. Romero LI, Ikejima T, Pincus SH: In situ localization of interleukin-1 in normal and psoriatic skin. *J Invest Dermatol* 93:518-522, 1989
34. Lee RE, Gaspari AA, Lotze MT, Chang AE, Rosenberg SA: Interleukin 2 and psoriasis. *Arch Dermatol* 124:1811-1815, 1988
35. Nasu K, Said J, Vonderheid E, Olerud J, Sako D, Kadin ME: Immunopathology of cutaneous T-cell lymphomas. *Am J Pathol* 119:436-447, 1985
36. Kadin M, Nasu K, Sako D, Said J, Vonderheid E: Lymphomatoid papulosis: A cutaneous proliferation of activated helper T-cells expressing Hodgkins disease-associated antigens. *Am J Pathol* 119:315-325, 1985
37. Ellis CN, Gorsulowsky DC, Hamilton TA, Billings JK, Prown MD, Headington JT, Cooper KD, Baadsgaard O, Duell EA, Annesley TM, Turcotte JG, Voorhees JJ: Cyclosporin improves psoriasis in a double-blind study. *JAMA* 256:3110-3116, 1986
38. Wentzell JM, Baughman RO, O'Connor GT, Bernier GM Jr: Cyclosporine in the treatment of psoriasis. *Arch Dermatol* 123:163-165, 1987