

## Nondecussating retinal-fugal fiber syndrome: Clinical and neuroimaging clues to diagnosis

*Ankit Balani, Anjani D Kumar, Sapna S Marda, Surendar Alwala*

We report the clinical details and imaging findings for a case of nondecussating retinal-fugal fiber syndrome or isolated achiasma in a 4-year-old female child. Findings included the isolated absence of optic chiasm with unremarkable rest of the optic pathway and midline structures in a child presenting clinically with see-saw nystagmus. Clinically congenital see-saw nystagmus, "mirror reversal" of visual field representation and interocular ipsilateral asymmetry on monocular visual evoked potential point toward achiasma and warrant further evaluation with magnetic resonance imaging (MRI). Isolated achiasma is

a rare condition that may remain undiagnosed unless MRI is done.

**Key words:** Achiasma, congenital nystagmus, magnetic resonance imaging, nondecussating retinal-fugal fiber syndrome

Congenital or infantile nystagmus, presents as involuntary rhythmic oscillatory movements of eye either in horizontal direction, torsional, or sometimes even vertical direction. The etiology is diverse, varying from conditions that impair visual acuity to occasionally life-threatening conditions. Prompt detailed clinical evaluation is warranted to assess for urgency and the need for further investigations. Nondecussating retinal-fugal fiber syndrome (NRFFS) is a rare cause of nystagmus in children diagnosed on magnetic resonance imaging (MRI) with isolated absence of optic chiasm and unremarkable remaining optic pathway. This article illustrates the typical clinical and MRI findings in a young patient with achiasma.

### Case Report

A 4-year-old female child presented to the ophthalmology outpatient department of the hospital with chief complaint of unresponsiveness toward external stimuli since birth aggravated in preceding few days. There was associated

Access this article online	
Quick Response Code:	Website: www.ijo.in
	DOI: 10.4103/0301-4738.171970

Department of Radiology, Yashoda Hospital, Secunderabad, Telangana, India

**Correspondence to:** Dr. Ankit Balani, 61, Shyam Nagar, Pal Link Road, Jodhpur, Rajasthan, India. E-mail: drankitbalani@gmail.com

**Manuscript received:** 28.05.15; **Revision accepted:** 30.10.15

This is an open access article distributed under the terms of the Creative Commons Attribution-NonCommercial-ShareAlike 3.0 License, which allows others to remix, tweak, and build upon the work non-commercially, as long as the author is credited and the new creations are licensed under the identical terms.

**For reprints contact:** reprints@medknow.com

**Cite this article as:** Balani A, Kumar AD, Marda SS, Alwala S. Nondecussating retinal-fugal fiber syndrome: Clinical and neuroimaging clues to diagnosis. Indian J Ophthalmol 2015;63:858-61.

history of near sightedness with child bringing objects very close to the eyes to see them. There was no history of abnormal head movements, torticollis, or any significant family history. The patient did not have any abnormal head posture, face turn, or chin lift. The patient underwent a comprehensive ophthalmic evaluation. There were no limitations in ocular motility, and cover-uncover test did not reveal any strabismus. Ocular movements were symmetrical in all cardinal gaze positions. Her slit-lamp biomicroscopy showed a normal anterior segment, with sluggishly reacting pupils. There was no evidence of relative afferent pupillary defect. Cycloplegic refraction done with atropine revealed moderate myopia of 3 diopters bilaterally. A dilated fundoscopic examination with indirect ophthalmoscopy showed temporal disc pallor in both eyes, with small symmetrical discs (however, there was no evidence of optic nerve hypoplasia). Torchlight examination revealed bilateral, symmetric, conjugate horizontal nystagmus with intermittent disconjugate vertical nystagmus. Intermittent episodes of see-saw nystagmus were also noted. Nystagmus was intermittent and disappeared during sleep. Initial laboratory workup for metabolic and infectious etiology was negative. Visual evoked potential (VEP) could not be performed due to lack of patient cooperation and availability of limited resources. Stereo acuity testing was tested with the Random Dot E test. The patient was unable to appreciate the elevated letters, despite repeating the test thrice; demonstrating the absence of gross stereopsis.

She was referred to us for MRI brain for evaluation of optic pathway, midline congenital and pituitary anomalies. MRI revealed the isolated absence of optic chiasm (achiasma) with normal optic nerves and optic tracts [Figs. 1-3]. There were no other congenital midline anomalies. Pituitary gland was normal [Fig. 1]. The findings suggested the diagnosis of NRFFS or achiasmic syndrome.

## Discussion

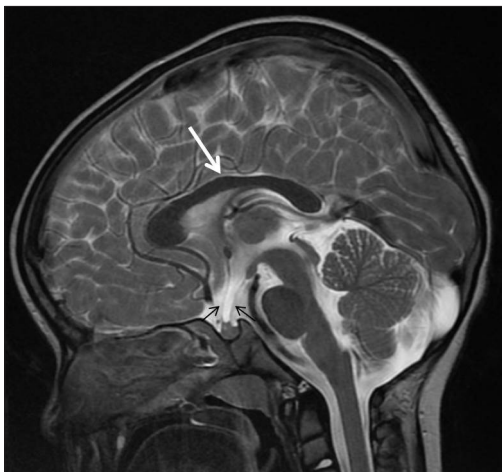
Eye movement disorders can present in the pediatric age group with characteristic rhythmic, oscillatory movements of the eye. See-saw nystagmus is a characteristic,

vertical-torsional eye movement disorder wherein there are intorsion and elevation of one eye and simultaneous extorsion and depression of other eye. It could have either pendular waveform (due to midline bilaterally compressing meso-diencephalic mass) or jerk-waveform (due to unilateral lesion).<sup>[1]</sup> See-saw nystagmus is an important sign of structural anomalies such as achiasma or hemichiasm and thus warrants an evaluation using MRI.<sup>[2]</sup>

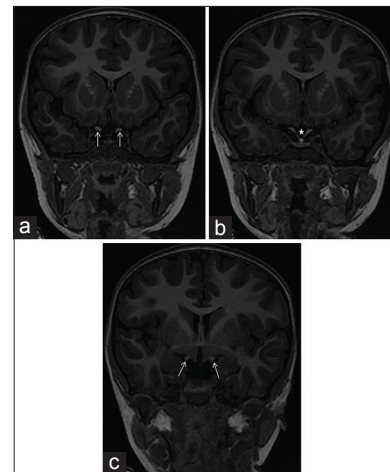
NRFFS or achiasma is a rare cause of nystagmus. In the early 1990s, Williams *et al.* reported a new abnormality i.e. canine achiasma in a Belgian sheep dogs who presented with see-saw nystagmus and showed the failure of crossing of optic nerve fibers at optic chiasm.<sup>[3]</sup> Apkarian *et al.* subsequently recognized achiasma in humans and named it as "NRFFS."<sup>[4]</sup> Electrophysiology reveals "crossed asymmetry" wherein the right cortex receives right eye's visually evoked response and vice versa. See-saw nystagmus may also be observed in patients with dissociated vertical deviation.<sup>[5]</sup> However, this condition was ruled out in our patient since there was no abnormal vertical deviation. Ocular tilt reaction, another rare cause of see-saw nystagmus was ruled out in our patient since there was no evidence of abnormal head posturing, skew deviations or vertical strabismus.<sup>[6]</sup>

It is imperative to highlight several important differences between achiasma and congenital nystagmus. Unlike achiasma, congenital nystagmus may not present at birth apart from a few hereditary cases<sup>[2]</sup> [Table 1] Another important differentiating feature between the two entities is the presence of see-saw nystagmus in achiasma, which is very rare in congenital nystagmus. Rarely, outpatient clinical observation of eye movements may not confidently differentiate between these conditions, unless an increasing velocity exponential of slow phase of the nystagmus is demonstrated on ocular movement recordings. Hence, a detailed imaging evaluation is essential in all patients presenting with nystagmus in young age.

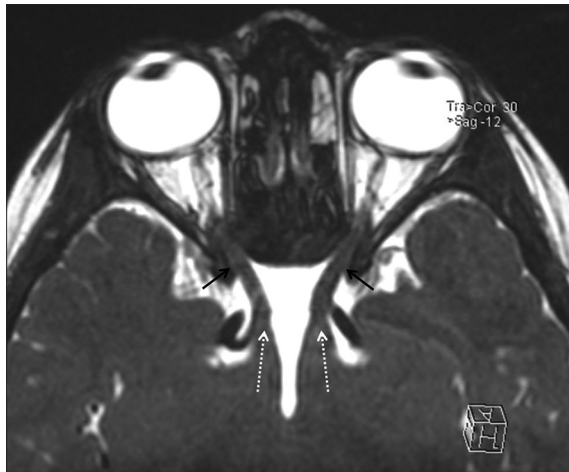Achiasma or hypochiasma has been reported in patients with congenital anophthalmos, midline anomalies like



**Figure 1:** Midline sagittal T2-weighted section of magnetic resonance imaging brain showing absence of optic chiasm. The midline structures, like corpus callosum (thick white arrow), pituitary infundibulum (thin black arrows) etc., are normal. There is mild prominence of infundibular recess of third ventricle



**Figure 2:** Sequential coronal sections (a-c) of T1-weighted inversion recovery sequence of magnetic resonance imaging brain showing transition of optic nerve (arrows in 2a) into optic tracts (arrows in 2c) without normal optic chiasm (asterisk). Normal pituitary gland and infundibulum are noted



**Figure 3:** Curved planar reformatted axial section of heavily T2-weighted image of magnetic resonance imaging brain showing isolated absence of optic chiasm with unremarkable optic nerves (black arrows) and optic tracts (dashed white arrows)

septo-optic dysplasia and in patients with albinism. However, isolated absence of optic chiasm is rare, with only a few cases reported previously.<sup>[7]</sup>

In albinism, abnormal erroneous decussation of temporal retinal-fugal projections occurs at the optic chiasm and these misrouted temporal retinal fibers misalign with normally decussating nasal retinal fibers of the same eye. Therefore, the medial segments of lateral geniculate nucleus layers representing a substantial portion of the ipsilateral visual field are mistakenly aligned with lateral geniculate nucleus layers of opposite, contralateral field. This results in a partial “mirror reversal” of the left and right half visual space coordinates.<sup>[8]</sup>

In achiasma, there is disruption of retinal-fugal projections, organization and function throughout the visual pathways. As against albinism, wherein there is erroneous decussation of temporal retinal fibers at chiasma; the achiasmatic syndrome is characterized by the absence of optic chiasma, and thus all nasal fibers fail to decussate, thereby misprojecting and misaligning with projections of the temporal retina of the same eye. The visual field representation reveals “mirror reversal” of left and right half visual space coordinates in a more complete fashion. Monocular VEP reveals interocular ipsilateral asymmetry differentiating it from albinism wherein pathognomonic interocular contralateral asymmetry is noted.<sup>[8]</sup> In spite of early reorganization and plasticity with multiple inter and intracortical connections, there is usually an absence of gross stereopsis in achiasmatics.<sup>[8]</sup> Typical imaging findings of achiasma include optic nerves transitioning into optic tracts without normal optic chiasm. Functional MRI confirms electrophysiology observations of crossed asymmetry with each ocular cortex receiving complete but monocular visual field. In spite of such large functional abnormalities, vision is normally preserved in most regards because of reorganization of intracortical connections.<sup>[9]</sup>

We wish to highlight the typical clinical and imaging features of a case of NRFFS or achiasma and the need of investigation by MRI of a patient presenting with see-saw

### Table 1: Etiology of congenital nystagmus

**Idiopathic:** Primary abnormality in ocular motor control. Genetic mechanism suggested with genes mapped to X chromosome and band 6p12

**Sensory nystagmus**

Early deprivation: Congenital cataract, congenital glaucoma, peters anomaly

Foveal hypoplasia: Aniridia, albinism

Retinal diseases: Lebers congenital amaurosis, achromatopsia, macular toxoplasmosis

Retinal detachment: Severe retinopathy of prematurity, posterior primary hyperplastic vitreous, familial exudative vitreo-retinopathy

Optic pathway anomalies: Optic nerve hypoplasia, coloboma, atrophy, achiasma

Cortical pathology: Perinatal insult, structural anomalies

Nystagmus associated with albinism: Abnormal pigmentation, foveal hypoplasia, increased chiasmal decussation, refractive errors

Spasmas nutans: Unknown etiology

Nystagmus blockage syndrome

Ventocilla M. Etiology of congenital nystagmus. In: Hampton Roy Sr., editor. Congenital Nystagmus Clinical Presentation. Medscape; 2014. p. 1, 7.

nystagmus for evaluation of optic chiasm. Achiasma needs to be considered as a rare condition presenting with nystagmus in early childhood that may be overlooked unless an MRI is done.

### Acknowledgments

The authors acknowledge the invaluable inputs from Dr. Aniruddha Agarwal, Postdoctoral Clinical research fellow, Truhlsen Eye Institute, UNMC, Omaha and Dr. Eesha Shukla, Resident, B.Y.L. Nair CH. Hospital, Mumbai for proof reading of the article.

### Financial support and sponsorship

Nil.

### Conflicts of Interest

There are no conflicts of interest.

### References

- Endres M, Heide W, Kömpf D. See-saw nystagmus. Clinical aspects, diagnosis, pathophysiology: Observations in 2 patients. *Nervenarzt* 1996;67:484-9.
- Hertle RW, Dell'Osso LF. Nystagmus in Infancy and Childhood: Current Concepts in Mechanisms, Diagnoses, and Management. USA: OUP; 2013.
- Williams R, Garraghty P, Goldowitz D. A new visual system mutation: Achiasmatic dogs with congenital nystagmus. *Soc Neurosci Abstr* 1991;17:187.
- Apkarian P, Bour L, Barth PG. A unique achiasmatic anomaly detected in non-albinos with misrouted retinal-fugal projections. *Eur J Neurosci* 1994;6:501-7.
- Prakash S, Dumoulin SO, Fischbein N, Wandell BA, Liao YJ. Congenital achiasma and see-saw nystagmus in VACTERL syndrome. *J Neuroophthalmol* 2010;30:45-8.
- Choi SY, Kim DH, Lee JH, Kim J. Jerky hemi-seesaw nystagmus and head tilt reaction combined with internuclear ophthalmoplegia from a pontine infarction. *J Clin Neurosci* 2009;16:456-8.

- 
7. Biega TJ, Khademian ZP, Vezina G. Isolated absence of the optic chiasm: A rare cause of congenital nystagmus. *AJNR Am J Neuroradiol* 2007;28:392-3.
  8. Apkarian P. Chiasmal crossing defects in disorders of binocular vision. *Eye (Lond)* 1996;10(Pt 2):222-32.
  9. Hoffmann MB, Kaule FR, Levin N, Masuda Y, Kumar A, Gottlob I, *et al.* Plasticity and stability of the visual system in human achiasma. *Neuron* 2012;75:393-401.
-