

# Incomplete Kawasaki disease in the 2-month-old infant

## A case report

Wei Ma, MD, Juan Sun, MD, Huaili Wang, MD\*

### Abstract

**Rationale:** The diagnosis of Kawasaki disease (KD) is difficult and is often delayed for children whose age falls outside the typical age range of 6 months to 5 years, especially for those with incomplete KD (IKD) or atypical features.

**Patient concerns:** A 2-month-20-day-old girl presented to our hospital with a chief complaint of intermittent fever for 1 day and 1 episode of seizure, with poor feeding and swelling of feet.

**Diagnosis:** Until the appearance of red cracked lips, a diagnosis of IKD was considered. A rise in periungual desquamation of the hands confirmed the diagnosis.

**Interventions:** Intravenous immunoglobulins were administered and aspirin and dipyridamole were used orally.

**Outcome:** The temperature, C-reactive protein, and erythrocyte sedimentation rate returned to normal level and there was no coronary artery lesion.

**Lessons:** This case highlights that the diagnosis of IKD should be considered in children whose primary presentation is fever and neurologic features, lacking principal clinical findings, particularly those <6 months of age.

**Abbreviations:** CRP = C-reactive protein, ESR = erythrocyte sedimentation rate, IKD = incomplete Kawasaki disease, IVIGs = intravenous immunoglobulins, KD = Kawasaki disease.

**Keywords:** diagnosis, incomplete Kawasaki disease, young infant

## 1. Introduction

Kawasaki disease (KD) is a self-limiting systemic vasculitis of small and medium vessels and typically occurs between 6 months and 5 years of age.<sup>[1]</sup> The diagnosis of KD is dependent upon the characteristic clinical signs and symptoms. However, the recognition of incomplete KD (IKD) is not straightforward. In 2004, the American Heart Association highlighted the diagnostic criteria for IKD. The diagnosis should be made in persons who have a fever lasting 5 or more days and at least 2 to 3 of these 5 representative clinical presentations: bilateral conjunctival injection, oral changes, cervical lymphadenopathy, extremity changes such as erythema or palm and sole desquamation, and polymorphous rash; as well as one of following 3 changes: typical laboratory, echocardiographic findings, or typical

periungual desquamation of hands and feet in the recovery stage.<sup>[2]</sup> Here, we described a 2-month-old infant whose diagnosis of IKD was suspected on day 8 of the illness, and confirmed on day 21. Our study was approved by the ethics committee of the First Affiliated Hospital of Zhengzhou University. Written informed consent was obtained from the participant's guardians.

## 2. Case presentation

A 2-month-20-day-old girl presented to our hospital with a chief complaint of intermittent fever for 1 day and 1 episode of seizure, with poor feeding and swelling of feet. Ten days prior to her visit, she was suffering from diarrhea. One week ago, she received a poliomyelitis vaccine, and then had a fever (38.2°C) once. On admission, physical examination was unremarkable except for swelling of soles and tachycardia. Laboratory examinations suggested leukocytosis, thrombocytosis, anemia, mild hypoalbuminemia, hyponatremia, and elevation of acute phase reactants (C-reactive protein [CRP] 106.95 mg/L, erythrocyte sedimentation rate [ESR] 75 mm/h). Urine analysis, cerebrospinal fluid examination, and blood culture were negative. Based on existent clinical and laboratory findings, the patient was initially treated with empirical antibiotics. However, she had a poor response, though there was obvious improvement of swelling of feet and axillary temperature.

On day 8 of admission, the patient presented with red cracked lips. In combination with a fever lasting more than 5 days, the diagnosis of IKD was considered, though echocardiography revealed no abnormalities. Meanwhile, the patient was given a 2 g/kg dose of intravenous immunoglobulin (IVIG) and was started

Editor: N/A.

The authors have no funding and conflicts of interest to disclose.

Department of Pediatric Intensive Care Unit, The First Affiliated Hospital of Zhengzhou University, Zhengzhou, China.

\* Correspondence: Huaili Wang, Department of Pediatric Intensive Care Unit, The First Affiliated Hospital of Zhengzhou University, No. 1, Jianshedong Road, Zhengzhou, China (e-mails: brightsunshinely@163.com, sagacities@163.com).

Copyright © 2018 the Author(s). Published by Wolters Kluwer Health, Inc. This is an open access article distributed under the terms of the Creative Commons Attribution-Non Commercial-No Derivatives License 4.0 (CCBY-NC-ND), where it is permissible to download and share the work provided it is properly cited. The work cannot be changed in any way or used commercially without permission from the journal.

Medicine (2018) 97:50(e13280)

Received: 20 June 2018 / Accepted: 22 October 2018

<http://dx.doi.org/10.1097/MD.0000000000013280>

on low-dose aspirin (4 mg/kg) and dipyridamole (4 mg/kg). The peak temperature decreased from day 8 to 11, ranging from 37.7°C to 38.2°C. However, on day 12, the patient suffered from a high temperature (39.0°C) again. Then we increased the dose of aspirin from 4 to 40 mg/kg. Two days later, the temperature fell to normal level and did not rise again. On day 16, namely the 4th day with normal temperature, the dose of aspirin was decreased back to 4 mg/kg. On day 18, the patient was discharged with follow-up visits. At that time, the level of CRP and ESR declined though not to normal and laboratory examinations still indicated thrombocytosis, anemia, hypoalbuminemia, and hyponatremia. The low-dose aspirin and dipyridamole were taken orally continuously. On day 21, the patient presented typical periungual desquamation of the hands, which was vital proof for the diagnosis of KD. Meanwhile, the level of CRP and ESR decreased to normal and the aspirin was stopped. The level of serum sodium increased to normal on day 46 after admission. The amount of platelet, albumin, and hemoglobin returned to normal level half years after admission, but the dipyridamole was withdrawal when the amount of plate descended to lower than 600 on day 46 after admission. The peak temperature is shown in Figure 1.

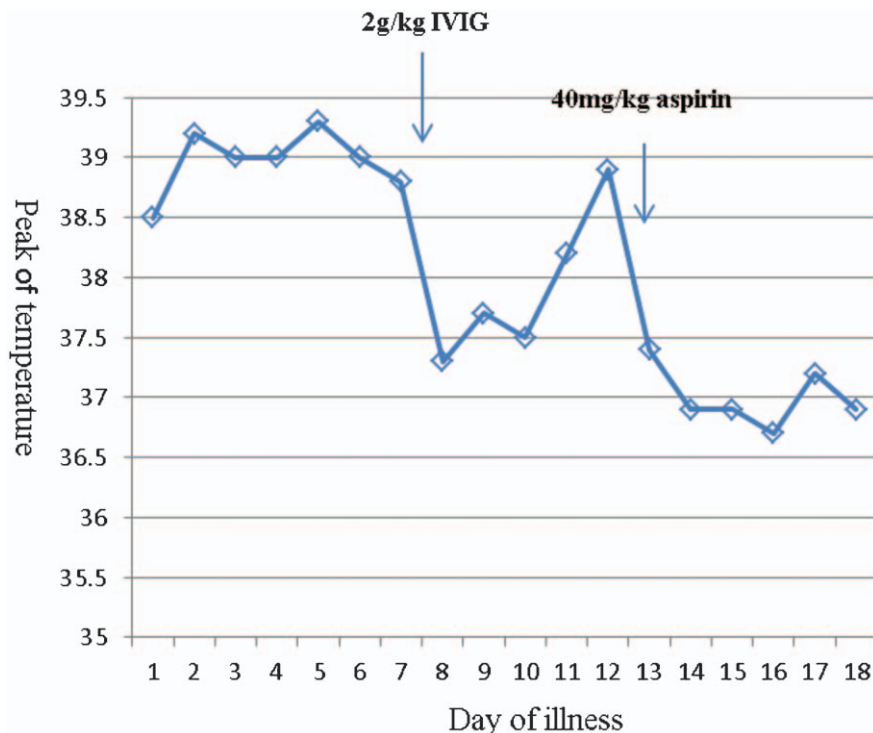
### 3. Discussion

Both the diagnosis and management KD remains a challenge, especially in cases of IKD and refractory KD. The diagnosis of IKD is always difficult and is often delayed because of various, atypical features, and complications, especially in the children outside the typical age of 6 months to 5 years.<sup>[3]</sup> Timely recognition of IKD may decrease the incidence of the fatal complication coronary artery aneurysms from 25% to 4% because of the timely initiation of treatment with IVIG.<sup>[4,5]</sup>

In our case, the course of diagnosis was with delay. The reasons for this may have included:

1. Age: The typical age of KD falls within the ages of 6 months to 5 years.<sup>[6,7]</sup> The incidence of KD in infants younger than 6 month is rare, much less in 2 months old.
2. Rare typical clinical manifestations: In the absence of pathognomonic tests, the diagnosis of KD rest on the identification of principal clinical findings and the exclusion of other clinically similar entities with known causes. The chief complaint was fever and edema of feet, and there were no changes in the eyes, oral cavity with no rashes or cervical lymphadenopathy. Otherwise, poor feeding, seizure may suggest the possibility of aseptic meningitis, rather than KD.
3. Cardiovascular findings: Cardiovascular manifestations may be prominent during acute KD episodes.<sup>[8]</sup> Electrocardiography and echocardiography did not show specific abnormality throughout the course of illness.
4. Poor response of IVIG: About 10% to 20% of patients with KD develop recrudescence or persistent fever at least 36 hours after finishing IVIG infusion.<sup>[9]</sup> Our case exactly fell into the group. Given the preceding 5 considerations, the diagnosis of IKD of the patient was not clear or definite until the appearance of typical periungual desquamation of the hands at the recovery stage.

Multiple therapeutic options in the management of KD have been postulated, but no general consensus has yet been established. The primary treatment included IVIG and ASA. Adjunctive therapies for primary treatment included corticosteroids, biologic agents.<sup>[4]</sup> A meta-analysis found that the addition of corticosteroid therapy to IVIG as an initial treatment in high-risk patients reduced the rate of coronary artery abnormali-



**Figure 1.** Time course of temperature in the patient treatment with intravenous immunoglobulin (IVIG) and aspirin (the unit of measurement of temperature was degrees Celsius, °C).

ties.<sup>[10]</sup> In our case, the patient was treated with IVIG as soon as the suspicion of KD was made, but the response was not good. However, an increase the dosage of ASA achieved a good response. Fortunately, from onset to the last time we follow-up, there was no coronary dilation, which might be due to instituting IVIG within the first 10 days of illness onset of fever.

This case highlights that the diagnosis of IKD should be considered in a child whose primary presentation is fever and neurologic features, lacking principal clinical findings, particularly those <6 months of age.

### Author contributions

**Data curation:** Wei Ma.

**Writing – review & editing:** Huaili Wang.

**Supervision:** Huaili Wang.

**Writing – original draft:** Juan Sun.

### References

- [1] Shulman ST, Rowley AH. Kawasaki disease: insights into pathogenesis and approaches to treatment. *Nat Rev Rheumatol* 2015;11:475–82.
- [2] Newburger JW, Takahashi M, Gerber MA, et al. Diagnosis, treatment, and long-term management of Kawasaki disease: a statement for health professionals from the Committee on Rheumatic Fever, Endocarditis, and Kawasaki Disease, Council on Cardiovascular Disease in the Young, American Heart Association. *Pediatrics* 2004;114:1708–33.
- [3] Sanchez-Manubens J, Bou R, Anton J. Diagnosis and classification of Kawasaki disease. *J Autoimmun* 2014;48-49:113–7.
- [4] McCrindle BW, Rowley AH, Newburger JW, et al. Diagnosis, treatment, and long-term management of Kawasaki disease: a scientific statement for health professionals from the American Heart Association. *Circulation* 2017;135:e927–99.
- [5] Terai M, Shulman ST. Prevalence of coronary artery abnormalities in Kawasaki disease is highly dependent on gamma globulin dose but independent of salicylate dose. *J Pediatr* 1997;131:888–93.
- [6] Dimitriades VR, Brown AG, Gedalia A. Kawasaki disease: pathophysiology, clinical manifestations, and management. *Curr Rheumatol Rep* 2014;16:423.
- [7] Holman RC, Belay ED, Christensen KY, et al. Hospitalizations for Kawasaki syndrome among children in the United States, 1997-2007. *Pediatr Infect Dis J* 2010;29:483–8.
- [8] Abou Sherif S, Ozden Tok O, Taskoylu O, et al. Coronary artery aneurysms: a review of the epidemiology, pathophysiology, diagnosis, and treatment. *Front Cardiovasc Med* 2017;4:24.
- [9] Bar-Meir M, Kalisky I, Schwartz A, et al. Prediction of resistance to intravenous immunoglobulin in children with Kawasaki disease. *J Pediatr Infect Dis Soc* 2018;7:25–9.
- [10] Chen S, Dong Y, Yin Y, et al. Intravenous immunoglobulin plus corticosteroid to prevent coronary artery abnormalities in Kawasaki disease: a meta-analysis. *Heart* 2013;99:76–82.