

Original Article

Larynx-Preserving Partial Pharyngectomy via Lateral Pharyngotomy for the Treatment of Small (T₁₋₂) Hypopharyngeal Squamous Cell Carcinoma

Young Chang Lim, MD^{1,2} · Ha Min Jeong, MD³ · Hyang Ae Shin, MD³ · Eun Chang Choi, MD³

¹Department of Otorhinolaryngology-Head and Neck Surgery, ²Research Institute of Medical Science, Konkuk University School of Medicine, Seoul; ³Department of Otorhinolaryngology, Yonsei University College of Medicine, Seoul, Korea

Objectives. To evaluate the oncologic and functional results of larynx-preserving partial pharyngectomy (LPP) via lateral pharyngotomy approach as a primary treatment for small (T₁ or T₂) hypopharyngeal squamous cell carcinoma (HP-SCC).

Methods. We performed a retrospective review of 23 patients who underwent LPP through lateral pharyngotomy approach for small HPSCC at the our department between January 1991 and June 2007. Fourteen (61%) patients had adjuvant postoperative radiotherapy.

Results. The 2-years and 5-years disease specific survival rate was 77% and 61%, respectively. Nine patients (39%) had tumor recurrence. The most common pattern of recurrence was isolated distant failure (n=4, 44%) followed by local (n=2, 22%) and loco-regional (n=3, 34%) recurrence. The ultimate cure rate of the primary tumor was 87% (20 of 23). Twenty-two of the 23 patients (95%) could be decannulated, tolerate an oral diet, and had acceptable postoperative phonatory function.

Conclusion. LPP via lateral pharyngotomy approach appears to be a feasible procedure for selected small HPSCC patients in terms of both oncologic and functional outcomes.

Key Words. Hypopharyngeal neoplasm, Pharyngectomy, Lateral pharyngotomy, Adjuvant radiotherapy

INTRODUCTION

Hypopharyngeal squamous cell carcinoma (HPSCC) is one of the most aggressive cancers of the head and neck area with a poor prognosis due mainly to an advanced stage at the time of initial diagnosis (1). The 5-year survival rate of HPSCC patients with advanced tumors has been reported to be less than 30% (2, 3). Thus, it is very important to detect the tumor at an early stage to increase the cure rate. However, small HPSCC (T₁ or T₂) is

rare, because it is not until the tumor becomes fairly large that patients experience symptoms.

Although there is still debate surrounding which treatment modality is optimal for treating small HPSCC, organ preservation therapies such as radiotherapy, chemotherapy, or combined chemoradiotherapy have become more popular than surgery in recent years (4, 5). This is probably due to the fact that postoperative functional results, including voice sacrifice from total laryngectomy, are far more severe than those obtained using (chemo) radiotherapy, even though the survival rates are equivalent. However, (chemo) radiotherapy can result in significant morbidities from xerostomia, dysphagia, or mucositis (6, 7). Furthermore, surgical salvage of patients with recurrence has an extremely poor cure rate (8).

The lateral pharyngotomy approach is a well-known surgical approach for selected malignant tumors of hypopharynx (9).

• Received February 4, 2010
Accepted after revision January 4, 2011

• Corresponding author: **Eun Chang Choi, MD**
Department of Otorhinolaryngology, Yonsei University College of Medicine,
262 Seongsan-no, Seodaemun-gu, Seoul 120-752, Korea
Tel: +82-2- 2228-3608, Fax: +82-2-393-0580
E-mail: eunchangmd@yuhs.ac

Copyright © 2011 by Korean Society of Otorhinolaryngology-Head and Neck Surgery.

This is an open-access article distributed under the terms of the Creative Commons Attribution Non-Commercial License (<http://creativecommons.org/licenses/by-nc/3.0>) which permits unrestricted non-commercial use, distribution, and reproduction in any medium, provided the original work is properly cited.

Recently, this procedure can be applied to resection of oropharynx cancer (10).

Unfortunately, few articles regarding larynx-preserving surgery through lateral pharyngotomy approach as a primary treatment for small HPSCC exist because patients with early tumors are rare and because (chemo) radiation is most often used for primary treatment. Recently, larynx-preserving surgery, including laser surgery, robot surgery, and endoscopic tumor resection, have been attempted (11-13). These studies, however, only included a limited subset of patients. Therefore, in this study, we evaluated the oncologic and functional results of larynx-preserving partial pharyngectomy (LPP) performed using lateral pharyngotomy approach as a primary treatment for small HPSCC.

MATERIALS AND METHODS

We performed a retrospective review of 133 previously-untreated consecutive HPSCC patients who visited the Department of Otorhinolaryngology, Yonsei University, Seoul, Korea, between January 1991 and June 2007. Patients who had a large primary tumor (T3 or T4; n=52), who were undergoing chemotherapy or radiotherapy as a primary treatment (n=21), who required more than a total laryngectomy for small HPSCC (n=20), who had a second primary HPSCC (n=7), who had distant metastasis at initial presentation (n=5), or who had non-squamous cell carcinoma (n=2) were excluded, thus 107 patients were excluded in total. Of the remaining 26 patients, 3 patients who underwent LPP via supraglottic laryngectomy approach were also excluded. Therefore, a total of 23 patients were enrolled in this study. LPP via lateral pharyngotomy approach was performed in patients with a tumor less than T2 without impairment of vocal cord movement if 1) the primary lesion was confined to the lateral wall of the pyriform sinus with no involvement of the pyriform apex, 2) the primary lesion was confined to the medial wall of the pyriform sinus with no involvement of the paraglottic space, or 3) the primary lesion was confined to the posterior pharyngeal wall without extension to the upper boundary of the cricoid cartilage with no involvement of the medial wall of the pyriform sinus. Preoperative staging was performed by physical examination, endoscopy, computed tomography, and/or magnetic resonance imaging. All patients were re-staged according to the system determined by the 2002 American Joint Committee on Cancer.

All patients received a lateral pharyngotomy approach accord-

Table 1. Subsites of primary tumors

Subsites	No. (%)
Lateral wall of the pyriform sinus	8 (35)
Medial wall of the pyriform sinus	3 (13)
Posterior hypopharyngeal wall	12 (52)
Total	23 (100)

ing to the previously described surgical procedure (14). Twenty-two (95%) patients underwent neck dissections. The neck dissections were elective or therapeutic, based on the absence or presence of clinically metastatic lymph nodes, respectively, resulting in 12 elective (52%) dissections and 10 (48%) dissections for therapeutic management. Fourteen patients (60%) were treated with bilateral neck dissections. To reconstruct the surgical defect area, a forearm free flap was used in 16 patients (69%) and a split thickness skin graft was used in 2 patients (8%). Primary closure was performed in the remaining five patients (25%). Surgery alone was used to treat 9 patients (39%). Fourteen (61%) patients with pathologic lymph node metastases or a positive resection margin of the primary tumor received postoperative adjuvant radiotherapy. The radiation dose ranged from 5,040 to 6,900 cGy (mean, 5,875 cGy). The mean follow-up period was 50 months, ranging from 5 to 132 months. All patients were followed-up for a minimum of 2 years or until death. Disease-specific survival rates were evaluated by Kaplan Meier analysis using SPSS ver. 13.0 (SPSS Inc., Chicago, IL, USA).

RESULTS

Patient and tumor characteristics

All patients were male with a median age of 61 years (range, 39 to 78 years). Table 1 summarizes the subsites of primary tumors in our study. Clinical and pathologic tumor stages are depicted in Table 2. In fourteen (61%) patients, the primary tumor had an exophytic growth pattern and in 9 patients, an infiltrative pattern. The tumor grade was moderately differentiated in 12 patients, well differentiated in 7 patients, and poorly differentiated in 3 patients. The single remaining patient had an undifferentiated primary tumor. Eleven (48%) patients had pathologically-confirmed metastatic neck lymph nodes. Occult neck me-

Table 2. Clinical and pathologic tumor stages
(A) Clinical stages

	T1	T2	Total
N0	5	8	13
N1	0	2	2
N2a	2	0	2
N2b	2	3	5
N2c	0	1	1
Total	9	14	23

(B) Pathologic tumor node stages

	T1	T2	T3	T4	Total
N0	5	4	2	1	12
N1	0	0	0	0	0
N2a	0	0	0	0	0
N2b	2	5	2	0	9
N2c	0	1	1	0	2
Total	7	10	5	1	23

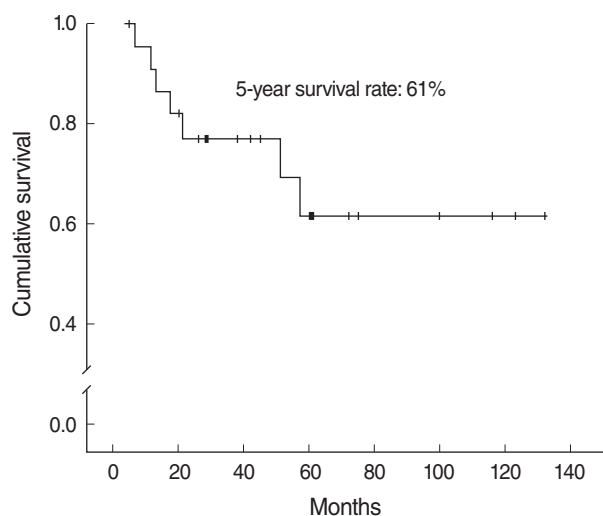


Fig. 1. Five-years survival rate of all patients.

tastasis was found in one patient (1 of 12, 8%) with elective neck dissection. Nine patients (39%) had a positive resection margin.

Survival and recurrence

The 2-year and 5-year disease specific survival rate (DSSR) was 77% and 61%, respectively (Fig. 1). Nine patients (39%) had tumor recurrence. Table 3 shows the recurrence patterns in our patients. Local recurrence developed in one of nine patients (11%) with a positive surgical margin after adjuvant radiotherapy. The sites of distant metastasis were the lung (n=2), bone (n=1), and liver (n=1). A second primary head and neck cancer developed in two patients (7%) over a follow-up period of 61 and 72 months, respectively. These second primary cancers occurred in the tonsils and false vocal cord, respectively. Salvage treatment was attempted in 5 patients (55%) to cure the disease. Of the remaining 4 patients with a recurrent tumor, three patients received only conservative care and one patient refused all treatments. Of the 5 patients who underwent salvage treatments, successful salvage was achieved in 2 patients (40%). One local recurrence and one locoregional recurrence was observed in these 2 patients. Thus, of 5 patients with a local or locoregional recurrence, 2 patients were ultimately cured. The ultimate cure rate of the primary tumor in our study was 87% (20 of 23).

Postoperative complications and functional results

Table 4 shows the postoperative complications we encountered. There was no death in the immediate postoperative period. The two patients with flap dehiscence underwent further reconstructions using a pectoralis myocutaneous flap. Twenty-two of 23 patients (95%) could be decannulated and could tolerate an oral diet. The average time until decannulation and starting an oral diet was 28 days (range, 11 to 113 days) and 17 days (range, 11 to 30 days), respectively. All patients had acceptable postopera-

Table 3. Recurrence patterns

Pattern	No. (%)
Distant metastasis	4 (44)
Local	2 (22)
Loco-regional	3 (34)
Total	9 (100)

Table 4. Postoperative complications

Patterns	No. (%)
Flap dehiscence	2 (33)
Wound infection	2 (33)
Hematoma	1 (17)
Aspiration pneumonia	1 (17)
Total	6 (100)

tive phonatory functions except for one patient who failed to decannulate. A single patient was ultimately unable to decannulate and eat food through an oral route simultaneously. The primary lesion site of this patient with a pathologic T2N2b stage tumor was in the posterior pharyngeal wall; he received forearm free flap reconstruction for the pharyngeal wall defect after surgery.

DISCUSSION

There is no consensus on whether primary surgery or (chemo) radiotherapy is more effective for curing patients with HPSCC, especially early stages of this cancer, because of the absence of prospective randomized studies of surgery with or without adjuvant radiotherapy versus (chemo) radiotherapy with or without salvage surgery. Thus, choice of the treatment modality depends largely on an institution's preferences or entrenched beliefs inherited from teachers. Our institution prefers to treat HPSCC cases with primary surgery rather than (chemo) radiotherapy.

The 5-year DSSR of all 23 patients in our study were 61%, which falls within the wide range of 40% to 92% reported for conservative surgical treatment of HPSCC in previous studies (11, 15-17). The reason for this wide range of survival rates is probably due to the fact that different indications for larynx-preserving surgery were used in the different studies, and it is likely that the postoperative pathologic stages also differed between studies.

If surgery is chosen as the primary treatment modality for small HPSCC, the extent of surgical resection that is needed to attain cure has to be decided on. Surgical options include partial pharyngectomy (PP), total laryngectomy and partial pharyngectomy (TLPP), and total laryngopharyngectomy (TLP), depending on the site of lesion. Czaja and Gluckman (16) evaluated surgical outcomes in 37 patients who underwent primary surgery for small HPSCC. They observed that although all nine of their patients who underwent PP had a negative surgical margin,

four of them (44%) had a local recurrence leading to death. Furthermore, they reported that small HPSCC patients who underwent limited resection (PP) showed statistically significantly worse survival than those who underwent extensive resection (TLPP or TLP). Thus, they recommended a more extensive procedure with a wider margin for surgical treatment of small HPSCC. One generally accepted explanation for the high rate of local recurrence in small HPSCC patients is the high frequency of submucosal spread combined with multiple “skip lesions” or tumor satellites in these patients. We also observed a high rate (39%) of pathologically positive resection margins in our study, even when excision with a minimum 2 cm healthy margin was performed intraoperatively. Interestingly, all 9 patients with positive resection margin had adjuvant radiotherapy and only a single patient (11%) developed a local recurrence. Positive surgical margins after resection of head and neck cancers, including hypopharynx cancer, are known to be strongly associated with local recurrence. Our low rate of local recurrence in patients with a positive resection margin may be due to the use of adjuvant postoperative radiotherapy for small tumors (less than T2). In contrast, 4 of 9 small HPSCC patients (44%) treated by surgery alone had local or locoregional recurrences. Of these 4 patients, two patients died due to the disease. Consistent with our results, Frank et al. (18), in their study of outcomes after primary surgery in 110 HPSCC patients, found that locoregional recurrences were more common in the surgery-only group than the postoperative radiotherapy group (57% vs. 14%, respectively; $P < 0.0001$). In addition, they reported adjusted 5-year survival rates of 18% and 48% ($P < 0.05$) for the surgery and postoperative radiotherapy groups, respectively. Thus, postoperative radiotherapy treatment may improve the survival of small HPSCC patients with risk factors after primary larynx-conserving surgery via lateral pharyngotomy.

Notably, even for small primary tumors, nearly half of the recurrence sites were distant (4 of 9 patients) without local or regional recurrence. The hypopharynx is the site at highest risk of subsequent distant metastases for other head and neck areas, with a relative risk of >10-fold when compared with that of oral cavity cancer, which has the lowest risk (19). Leon et al. (20) also found that cancer of the hypopharynx or supraglottis was an independent risk factor for distant metastases. Taken together, additional treatment strategies should be considered for preventing distant metastases in HPSCC patients, even in those with small cancer.

Very few researchers have evaluated functional outcomes after LPP for small HPSCC. Wang et al. (21), based on a series of 206 patients who underwent larynx-preserving surgery for HPSCC, observed that 67 patients (33%) required a permanent tracheostomy. Goepfert et al. (22) reported a rate of persistent aspiration of 11% and fatal pulmonary complications in patients who underwent conservative surgery for cancer of the hypopharynx. However, Laccourreye reported that all patients treat-

ed with supracricoid hemilaryngopharyngectomy for HPSCC were decannulated and could tolerate an oral diet without gastrostomy or completion total laryngectomy (91.9% of patients); aspiration-related deaths only occurred in 0.7% of patients (23). Notably, Holsinger et al. (24) reported that all 30 patients receiving LPP by means of lateral pharyngotomy approach were decannulated and no patients required a gastrostomy and/or completion total laryngectomy for functional reasons. We found that almost all our patients (96%) could be decannulated, tolerate an oral diet without gastrostomy, and communicate effectively. Failure of decannulation and lack of ability to tolerate an oral diet occurred only in a single patient. The reason for this may be that the reconstructed free flap was too large (4×4 cm) compared to the defect area of the posterior hypopharyngeal wall (2×2.5 cm) after resection in this patient, leading to a restricted airway and difficulty swallowing. Thus, it is crucial to design a flap of appropriate size for reconstruction of the hypopharyngeal defect after partial pharyngectomy.

In conclusion, we found that LPP using an lateral pharyngotomy approach for selected small HPSCC patients is a feasible procedure with respect to oncologic and functional outcomes. This study, however, has the limitations of a small number of enrolled patients and a retrospective study design. Prospective randomized control studies with a large patient population are required to verify our findings.

CONFLICT OF INTEREST

No potential conflict of interest relevant to this article was reported.

ACKNOWLEDGMENT

This work was supported by Konkuk University 2010.

REFERENCES

1. Berrino F, Gatta G. Variation in survival of patients with head and neck cancer in Europe by the site of origin of the tumours. *Eur J Cancer*. 1998 Dec 1;34(14):2154-61.
2. Hoffman HT, Karnell LH, Shah JP, Ariyan S, Brown GS, Fee WE, et al. Hypopharyngeal cancer patient care evaluation. *Laryngoscope*. 1997 Aug;107(8):1005-17.
3. Kraus DH, Zelefsky MJ, Brock HA, Huo J, Harrison LB, Shah JP. Combined surgery and radiation therapy for squamous cell carcinoma of the hypopharynx. *Otolaryngol Head Neck Surg*. 1997 Jun; 116(6 Pt 1):637-41.
4. Nakamura K, Shioyama Y, Kawashima M, Saito Y, Nakamura N, Nakata K, et al. Multi-institutional analysis of early squamous cell carcinoma of the hypopharynx treated with radical radiotherapy. *Int J Radiat Oncol Biol Phys*. 2006 Jul 15;65(4):1045-50.
5. Amdur RJ, Mendenhall WM, Stringer SP, Villaret DB, Cassisi NJ. Or-

- gan preservation with radiotherapy for T1-T2 carcinoma of the pyriform sinus. *Head Neck*. 2001 May;23(5):353-62.
6. Dirix P, Nuyts S, Van den Bogaert W. Radiation-induced xerostomia in patients with head and neck cancer: a literature review. *Cancer*. 2006 Dec 1;107(11):2525-34.
 7. Trotti A, Bellm LA, Epstein JB, Frame D, Fuchs HJ, Gwede CK, et al. Mucositis incidence, severity and associated outcomes in patients with head and neck cancer receiving radiotherapy with or without chemotherapy: a systematic literature review. *Radiother Oncol*. 2003 Mar;66(3):253-62.
 8. Jones AS. The management of early hypopharyngeal cancer: primary radiotherapy and salvage surgery. *Clin Otolaryngol Allied Sci*. 1992 Dec;17(6):545-9.
 9. Ogura JH, Watson RK, Jurema AA. Partial pharyngectomy and neck dissection for posterior hypopharyngeal cancer. Immediate reconstruction with preservation of voice. *Laryngoscope*. 1960 Nov; 70(11):1523-34.
 10. Cocek A, Prucha I, Hahn A. Lateral pharyngotomy extended by resection of the mandibular angle-an alternative approach to the surgical treatment of oropharyngeal (tonsillar) cancers. *Acta Otolaryngol*. 2009 Mar;129(3):318-23.
 11. Martin A, Jackel MC, Christiansen H, Mahmoodzada M, Kron M, Steiner W. Organ preserving transoral laser microsurgery for cancer of the hypopharynx. *Laryngoscope*. 2008 Mar;118(3):398-402.
 12. Park YM, Lee WJ, Lee JG, Lee WS, Choi EC, Chung SM, Kim SH. Transoral robotic surgery (TORS) in laryngeal and hypopharyngeal cancer. *J Laparoendosc Adv Surg Tech A*. 2009 Jun;19(3):361-8.
 13. Shimizu Y, Yamamoto J, Kato M, Yoshida T, Hirota J, Ono Y, et al. Endoscopic submucosal dissection for treatment of early stage hypopharyngeal carcinoma. *Gastrointest Endosc*. 2006 Aug;64(2):255-9.
 14. Byers RM. Anatomic correlates in head and neck surgery. The lateral pharyngotomy. *Head Neck*. 1994 Sep-Oct;16(5):460-2.
 15. Kania R, Hans S, Garcia D, Brasnu D, De Mones E, Laccourreye O. Supracricoid hemilaryngopharyngectomy in patients with invasive squamous cell carcinoma of the pyriform sinus. Part II: Incidence and consequences of local recurrence. *Ann Otol Rhinol Laryngol*. 2005 Feb;114(2):95-104.
 16. Czaja JM, Gluckman JL. Surgical management of early-stage hypopharyngeal carcinoma. *Ann Otol Rhinol Laryngol*. 1997 Nov;106(11):909-13.
 17. Eckel HE, Staar S, Volling P, Sittel C, Damm M, Jungehuelsing M. Surgical treatment for hypopharynx carcinoma: feasibility, mortality, and results. *Otolaryngol Head Neck Surg*. 2001 May;124(5):561-9.
 18. Frank JL, Garb JL, Kay S, McClish DK, Bethke KP, Lind DS, et al. Postoperative radiotherapy improves survival in squamous cell carcinoma of the hypopharynx. *Am J Surg*. 1994 Nov;168(5):476-80.
 19. Garavello W, Ciardo A, Spreafico R, Gaini RM. Risk factors for distant metastases in head and neck squamous cell carcinoma. *Arch Otolaryngol Head Neck Surg*. 2006 Jul;132(7):762-6.
 20. Leon X, Quer M, Orús C, del Prado Venegas M, Lopez M. Distant metastases in head and neck cancer patients who achieved loco-regional control. *Head Neck*. 2000 Oct;22(7):680-6.
 21. Wang T, Li X, Lu Y, Yu Z. Preservation of laryngeal function in treatment of hypopharyngeal carcinoma. *Chin Med J (Engl)*. 2002 Jun; 115(6):892-6.
 22. Goepfert H, Lindberg RD, Jesse RH. Combined laryngeal conservation surgery and irradiation: can we expand the indications for conservation therapy? *Otolaryngol Head Neck Surg*. 1981 Nov-Dec; 89(6):974-8.
 23. Laccourreye O, Ishoo E, de Mones E, Garcia D, Kania R, Hans S. Supracricoid hemilaryngopharyngectomy in patients with invasive squamous cell carcinoma of the pyriform sinus. Part I: Technique, complications, and long-term functional outcome. *Ann Otol Rhinol Laryngol*. 2005 Jan;114(1 Pt 1):25-34.
 24. Holsinger FC, Motamed M, Garcia D, Brasnu D, Ménard M, Laccourreye O. Resection of selected invasive squamous cell carcinoma of the pyriform sinus by means of the lateral pharyngotomy approach: the partial lateral pharyngectomy. *Head Neck*. 2006 Aug;28(8):705-11.