




Since January 2020 Elsevier has created a COVID-19 resource centre with free information in English and Mandarin on the novel coronavirus COVID-19. The COVID-19 resource centre is hosted on Elsevier Connect, the company's public news and information website.

Elsevier hereby grants permission to make all its COVID-19-related research that is available on the COVID-19 resource centre - including this research content - immediately available in PubMed Central and other publicly funded repositories, such as the WHO COVID database with rights for unrestricted research re-use and analyses in any form or by any means with acknowledgement of the original source. These permissions are granted for free by Elsevier for as long as the COVID-19 resource centre remains active.



SARS-CoV2 RNA detection in a pancreatic pseudocyst sample



A B S T R A C T

Keywords:
SARS-CoV2
Covid-19
Pancreatic pseudocyst
Endoscopic drainage

The involvement of gastrointestinal system in SARS-CoV2 related disease, COVID-19, is increasingly recognized. COVID-19 associated pancreatic injury has been suggested, but its correlation with pancreatic disease is still unclear. In this case report, we describe the detection of SARS-CoV2 RNA in a pancreatic pseudocyst fluid sample collected from a patient with SARS-CoV2 associated pneumonia and a pancreatic pseudocyst developed as a complication of an acute edematous pancreatitis. The detection of SARS-CoV2 within the pancreatic collection arise the question of whether this virus has a tropism for pancreatic tissue and whether it plays a role in pancreatic diseases occurrence.

© 2020 IAP and EPC. Published by Elsevier B.V. All rights reserved.

The involvement of the pancreas in SARS-CoV2 related disease, named COVID-19, is increasingly recognized. Amer Hadi et al. reported the occurrence of acute pancreatitis in two of three family members diagnosed with SARS-CoV2 infection [1]. Similarly, Mark M. Aloysius et al. described a case of COVID-19 pneumonia associated with acute severe pancreatitis [2]. The occurrence of pancreatic injury, defined as increasing in amylase and lipase levels, has been described in 17% of 52 patients admitted for COVID-19 pneumonia [3]. ACE 2 receptor, used from the virus to penetrate cells, is widely expressed in the digestive system and in pancreatic cells, thus suggesting a tropism of SARS-CoV2 for pancreatic tissue [4–6]. However, the cytopathic effect of SARS-CoV2 on pancreas is still unclear since the virus isolation on pancreatic tissue or pancreatic juice has not been reported so far.

In April 2020, a 67-years-old woman referred to our department complaining of fever, upper quadrant abdominal pain and vomiting. Her medical history included a recent hospitalization for interstitial edematous acute pancreatitis of unknown origin. On admission, the abdomen appeared distended with a slight tenderness and pain in epigastric and mesogastric regions. Laboratory tests showed an increasing in inflammatory proteins and normal level of pancreatic enzymes and white blood cells. An abdomen CT scan showed the presence of a large pancreatic pseudocyst (16 cm × 8 cm × 12 cm) causing a partial stomach outlet obstruction, Fig. 1a, and a chest CT scan documented bilateral and multiple mottling and “ground glass” opacities, Fig. 1c. The nasopharyngeal swab sample confirmed the presence of SARS-CoV-2 and a diagnosis of COVID-19 pneumonia was made. Since the abdominal issue failed to improve with the conservative therapy, an endoscopic ultrasound-guided transgastric drainage of the pseudocyst using AXIOS™ Stent and Electrocautery Enhanced Delivery System was successfully performed, Fig. 1b. Prior to the endoscopic procedure and using disposable accessories to reduce the risk of contamination, an aliquot of pancreatic pseudocyst fluid was collected and

analyzed. The laboratory tests showed no bacterial growth, increased levels of amylase (900U/L) and normal Carcinoembryonic antigen (CEA) levels. Moreover, a Real-time PCR for SARS-CoV-2 RNA was performed using Allplex™ 2019-nCoV Assay (Seegene, Arrow Diagnostics, South Korea). The pancreatic pseudocyst sample resulted positive for all 3 target genes of SARS-CoV2 researched (E, RdRP and N genes, Ct values = 21.19, 24.04 and 23.44 respectively). The results were then confirmed by amplification with a Quantitative Real-time RT-PCR (Quanty Covid-19, Clonit, Italy) and 2.4×10^6 cps/ml were found within the pseudocyst fluid. The high viral load documented within the sample makes improbable a false positive due to an eventual contamination during the endoscopic procedure.

The potential role of coronaviruses on pancreatic diseases has been shown in the past, in fact SARS-CoV was detected in pancreatic cells and its direct cytopathic effect was hypothesized [7]. Herein we reported, for the first time in literature, a qualitative and quantitative detection of SARS-CoV2 RNA in the fluid of a pancreatic collection, opening to different scenarios: SARS-CoV2 might have a tropism for pancreatic cells leading to a direct cytopathic effect, otherwise the presence of SARS-CoV2 in the pancreatic collection might occur secondarily using other cells (e.g. the inflammatory cells) as Trojan horses or as a retrograde contamination from the intestinal tube. In conclusion, the presence of SARS-CoV2 RNA in a pancreatic collection endorse the involvement of GI system in COVID-19 and may affect our clinical practice. Nevertheless, further studies are needed to clarify the exact role of SARS-CoV2 in causing pancreatic disease.

Contributors

ST and RGL conceived the present study. ST performed data collection. LA performed the endoscopic procedure. CP performed the virologic tests. ST and RGL drafted the manuscript. All authors discussed the results and contributed to the final manuscript.

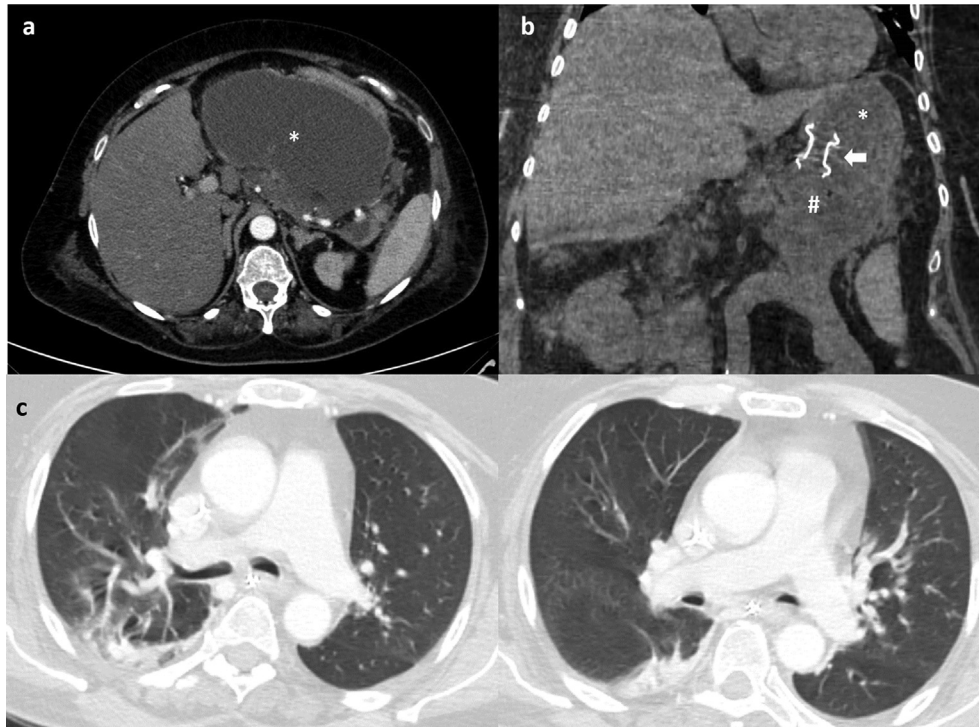


Fig. 1. Abdominal CT scans showing (a) the large pancreatic pseudocyst measuring 16 cm × 8 cm × 12 cm (*) and (b) the Lumen Apposing Metal Stent (white narrow) placed transmurally between stomach (*) and pancreatic pseudocyst (#). (c) Chest CT scan showing bilateral and multiple mottling and ground glass opacities compatible with SARS-CoV2 associated pneumonia.

Funding

None declared.

Patient consent for publication

Acquired directly from the patient.

Declaration of competing interest

A. Larghi: training and fees for Boston Scientific, Medtronic and Pentax. All other authors disclosed no conflict of interest.

Acknowledgments

None declared.

References

- [1] Hadi A et al., Coronavirus Disease-19 (COVID-19) associated with severe acute pancreatitis: Case report on three familymembers, *Pancreatology*, <https://doi.org/10.1016/j.pan.2020.04.021>.
- [2] Aloysius MM, Thatti A, Gupta A, Sharma N, Bansal P, Goyal H. COVID-19 presenting as acute pancreatitis. *Pancreatology* 2020. <https://doi.org/10.1016/j.pan.2020.05>.
- [3] Wang F, Wang H, Fan J, et al. Pancreatic injury patterns in patients with COVID-19 pneumonia. *Gastroenterology* 2020 Apr 1;20:30409–11. pii: S0016-5085.
- [4] Zhang H, Kang Z, Gong H, et al. Digestive system is a potential route of COVID-19: an analysis of single-cell coexpression pattern of key proteins in viral entry process. *Gut* Published Online First: 02 April 2020. doi: 10.1136/gutjnl-2020-320953
- [5] Chen Y, Guo Y, et al. Structure analysis of the receptor binding of 2019-nCoV. pii: S0006-291X Biochem Biophys Res Commun 2020 Feb 17;20. 30339-9.
- [6] Yang Jin-Kui, Lin Shan-Shan, et al. Binding of SARS coronavirus to its receptor damages islets and causes acute diabetes. *Acta Diabetol* 2010;47:193–9.
- [7] Ding Y, He L, Zhang Q, et al. Organ distribution of severe acute respiratory syndrome (SARS) associated coronavirus (SARS-CoV) in SARS patients: implications for pathogenesis and virus transmission pathways. *J Pathol* 2004 Jun;203(2):622–30.

T. Schepis*, A. Larghi, A. Papa, L. Miele

Department of Medical and Surgical Sciences, Gastroenterology Unit,
Fondazione Policlinico Universitario A, Gemelli IRCCS, Rome, Italy

F. Panzuto

Department of Clinical Sciences and Tralational Medicine, Digestive
Disease Unit, Sant'Andrea University Hospital, Rome, Italy

L. De Biase

Department of Clinical and Molecular Medicine, Heart Failure Unit,
Sant'Andrea University Hospital, Rome, Italy

B. Annibale

Department of Clinical Sciences and Tralational Medicine, Digestive
Disease Unit, Sant'Andrea University Hospital, Rome, Italy

P. Cattani

Department of Laboratory and Infective Sciences, Virology Unit,
Fondazione Policlinico Universitario A, Gemelli IRCCS, Rome, Italy

G.L. Rapaccini

Department of Medical and Surgical Sciences, Gastroenterology Unit,
Fondazione Policlinico Universitario A, Gemelli IRCCS, Rome, Italy

* Corresponding author. Gastroenterology Unit, Department of
Medical and Surgical Sciences, Fondazione Policlinico Universitario
A, Gemelli IRCCS, Rome, Italy, Università Cattolica del Sacro Cuore,
Rome, Largo Agostino Gemelli, 8, 00168, Roma, RM, Italy. Tel.: +39
3492823189.

E-mail address: Tommaso.schepis@gmail.com (T. Schepis).

10 May 2020

Available online 28 May 2020