

A Patient With Dysphagia due to an Aortic Aneurysm

Jeong-Ho Kim, MD, Sung-Won Jang, MD, Dong-Bin Kim, MD, Hyun-Jeong Lee, MD, Jae-Gyung Kim, MD, Bum-Jun Kwon, MD, Eun-Ju Cho, MD, Tai-Ho Rho, MD and Jae-Hyung Kim, MD

Division of Cardiology, Department of Internal Medicine, College of Medicine, The Catholic University of Korea, Seoul, Korea

ABSTRACT

Dysphagia aortica is difficulty in swallowing caused by extrinsic compression of the esophagus due to an ectatic, tortuous, or aneurysmatic atherosclerotic thoracic aorta. This condition is very uncommon, and it is usually associated with old age, women with short stature, hypertension, and kyphosis. We report herein a case involving a patient with dysphagia who had an aortic aneurysm. (**Korean Circ J 2009;39:258-260**)

KEY WORDS: Dysphagia; Aortic aneurysm.

Introduction

Dysphagia is the subjective awareness of difficulty in the passage of solids or liquids from the oropharynx to the stomach. Dysphagia can be classified into an oropharyngeal or an esophageal location, and it is caused by neuromuscular motility disorders and mechanical obstruction.¹⁾ Mechanical dysphagia is associated with intrinsic or extrinsic compression, resulting in progressive intolerance to solids. The term, dysphagia aortica, has been used to describe difficulty in swallowing caused by external compression from an ectatic, tortuous, or aneurysmal aorta as a result of age-related degeneration.²⁾ Dysphagia aortica is classically seen in elderly women with short stature who have hypertension and kyphosis.³⁾ We report herein a patient with dysphagia associated with an aortic aneurysm.

Case

An 86-year-old woman presented with worsening nausea and vomiting. Because of her progressive dysphagia to solids for the last 6 months, she had ingested only semi-solids and liquids. Three days before seeking evaluation at our hospital, she had difficulty in swallowing liquids, along with nausea and vomiting. She had lost about 5 kg

of weight. The medical history revealed that she had been diagnosed with primary hypertension, an ascending aortic aneurysm, congestive heart failure, moderate aortic regurgitation, and moderate mitral regurgitation 6 years previously. Because of old age, she did not undergo an operation and she was on symptomatic treatment. She had undergone vertebroplasty due to multiple compression fractures of the thoracic and lumbar vertebrae 5 years ago. On admission to the hospital, she had a chronically ill appearance. The blood pressure was 130/90 mmHg, the pulse rate was 64 beats/min, the respiratory rate was 28 breath/min, the body temperature was 36.0°C, the height was 1.43 m, and the body weight was 37 kg. The physical examination showed a diastolic murmur at the right upper sternal border and a pansystolic ejection murmur at the left lower sternal border. The laboratory findings were as follows: the white blood cell (WBC) count was 5,100/mm³, the hemoglobin was 11.8 g/dL, the platelet count was 151,000/mm³, the blood urea nitrogen (BUN) was 39.8 mg/dL, the creatinine was 1.5 mg/dL, the total protein was 5.8 g/dL, the albumin was 3.2 g/dL, the lactate dehydrogenase (LDH) was 546 IU/L, and the creatinine phosphokinase (CPK) was 380 IU/L. An electrocardiogram (ECG) demonstrated a left axis deviation and left ventricular hypertrophy. Her chest radiograph revealed blunting signs at both costophrenic angles, cardiomegaly with a cardio-thoracic ratio of 0.8, and an enlarged, tortuous aorta (Fig. 1). Computed tomography (CT) of the chest demonstrated an enlarged, tortuous aorta (Fig. 2). The diameters of the ascending thoracic aorta, the descending thoracic aorta, and the proximal abdominal aorta were 7 cm, 6 cm, and 5.3 cm, respectively. There was an intramural thrombus at the level of the descending aorta. The upper gastrointestinal

Received: March 4, 2009

Accepted: March 17, 2009

Correspondence: Sung-Won Jang, MD, Division of Cardiology, Department of Internal Medicine, College of Medicine, The Catholic University of Korea, St. Paul's Hospital, 620-56 Jeonnonng 2-dong, Dongdaemun-gu, Seoul 130-709, Korea

Tel: 82-2-958-2450, Fax: 82-2-968-7250

E-mail: clement@naver.com

barium study revealed marked extrinsic compression of the distal esophagus just above the esophagogastric junction (Fig. 3). We concluded that the symptoms and the results of the imaging studies were consistent with dysphagia aortica. Although we recommended surgical correction of the aortic aneurysm or percutaneous endoscopic gastrostomy, the patient declined any invasive procedures and she was transferred to a nursing home on the 12th hospital day.

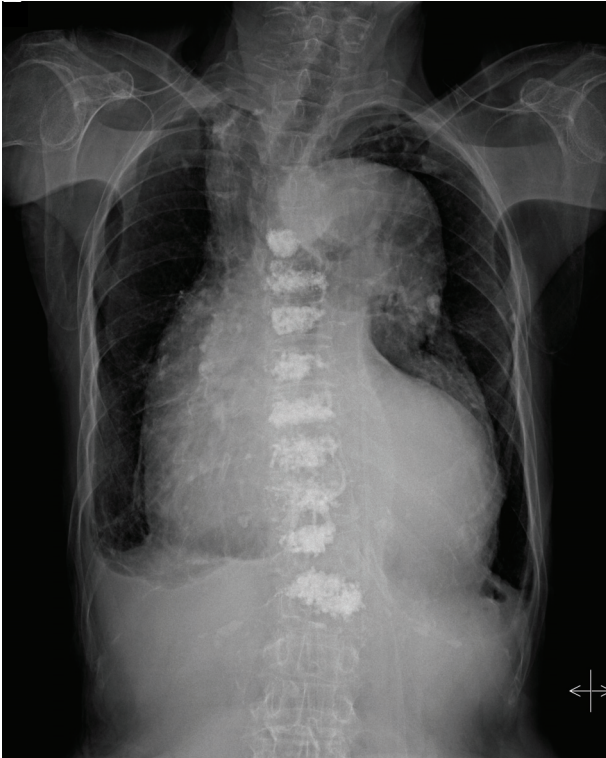


Fig. 1. The posteroanterior chest radiograph showed an enlarged, tortuous aorta.

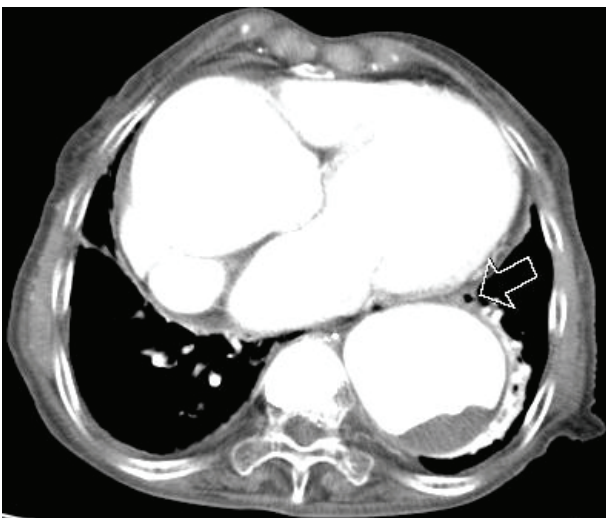


Fig. 2. Chest computed tomography showed an enlarged thoracic aorta with an intramural thrombus at the level of the descending aorta. Note that the distorted esophagus was displaced to the anterolateral aspect of the descending aorta (arrow).

Discussion

The esophagus normally begins on the right side of the thoracic aorta and then descends. The esophagus crosses the aorta anteriorly in the lower third of the posterior mediastinum. This area is called the aortoesophageal decussation site. Then, the esophagus lies on the left side of the aorta and penetrates the diaphragm through the diaphragmatic hiatus.⁴⁾ The aging process and the accompanying degenerative changes with the loss of elasticity causes a dilated, elongated, and distorted aorta, which may result in a so-called reverse C- or reverse S-shaped aorta.³⁾ As a result, the esophagus is pushed and compressed by the aorta against the cardiac chambers, which are anterior in location.⁵⁾

There is no gold standard diagnostic procedure for dysphagia aortica. The association of suggestive symptoms, such as progressive intolerance to solids with concomitant weight loss along with the results of imaging and other diagnostic studies provide a high index of suspicion.⁶⁾ The diagnostic work-up includes radiologic, endoscopic, and manometric studies. On a standard chest radiography and CT scan, the enlargement of the aortic arch and the tortuous dilated aorta can be observed. A barium swallow test may show partial esophageal obstruction and pulsatile movement of the barium synchronous with aortic pulsation.⁷⁾ Endoscopy reveals pulsatile extrinsic compression and stenosis of the lower esophagus with proximal dilatation. Esophageal manometry may demonstrate a localized high pressure band with superimposed pounding that is synchronous with the cardiac pulsation.⁸⁾

However, the typical findings of dysphagia aortica can be inconsistent. The radiographic findings are often inconclusive because a dilated, tortuous thoracic aorta is

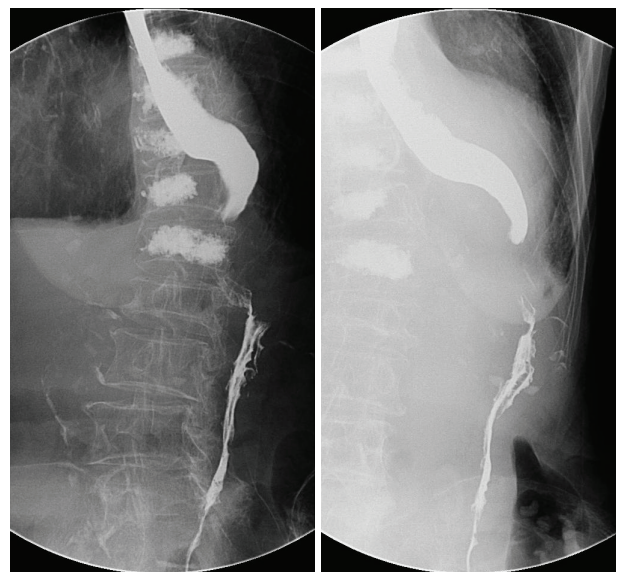


Fig. 3. The upper gastrointestinal barium study showed marked extrinsic compression of the distal esophagus just above the esophagogastric junction.

frequently encountered in elderly patients with dysphagia. Although a CT scan is useful for evaluating not only the aortic lumen, but also the aortic wall,⁹⁾ occasionally this is of no value in assessing compression of the esophagus by the aorta.²⁾ False negative results are common for barium swallow studies. Vascular pulsation commonly appears on endoscopy of the normal esophagus. In addition, the classical manometric features suggestive of dysphagia aortica also occur in normal subjects.⁸⁾

The differential diagnosis of dysphagia aortica includes various common structural and neuromuscular abnormalities.¹⁾ Gastroesophageal reflux disease and motility disorders are common causes of dysphagia. The co-existence of these conditions and the lack of sensitivity and specificity of the usual diagnostic tests make it difficult to diagnose dysphagia aortica with certainty. Wilkinson et al.²⁾ demonstrated that a video solid bolus swallow test could be useful in determining the manometric findings that are suspicious for dysphagia aortica when the standard evaluation fails.

The treatment for dysphagia aortica depends on the severity of the symptoms. Mild cases may be treated conservatively, such as avoiding sticky solids and feeding on a liquid diet. Patients with more severe symptoms may respond to surgery. The surgical procedures include transposition of the distal esophagus, separation of the distal esophagus from the aorta, esophagomyotomy, division of the right crus of the diaphragm, aortic resection, and repair of an aneurysm. For patients who are not candidates for surgery, insertion of a feeding tube via percutaneous endoscopic gastrostomy (PEG) is an option.²⁾

The present case was diagnosed with dysphagia aortica. Although we did not perform esophageal manometry, the

patient's symptoms and imaging studies were consistent with the classic findings of dysphagia aortica. Although the patient declined any invasive procedures, a PEG for a feeding tube might have been helpful for nutritional support.

Dysphagia aortica is an uncommon type of dysphagia that is caused by extrinsic mechanical compression. It should be differentiated from other causes of dysphagia, such as gastroesophageal reflux disease or motility disorders, because dysphagia aortica often requires surgical intervention that can significantly reduce the morbidity and these interventions can be curative in some situations.

REFERENCES

- 1) Spieker MR. *Evaluating dysphagia. Am Fam Physician* 2000;61:3639-48.
- 2) Wilkinson JM, Euinton HA, Smith LF, Bull MJ, Thorpe JA. *Diagnostic dilemmas in dysphagia aortica. Eur J Cardiothorac Surg* 1997;11:222-7.
- 3) Keates PG, Magidson O. *Dysphagia associated with sclerosis of the aorta. Br J Radiol* 1955;28:184-90.
- 4) Snell RS. *Clinical Anatomy for Medical Student. 6th. Philadelphia: Lippincott Williams & Wilkins; 2000. p.113.*
- 5) Mucklow EH, Smith OE. *Dysphagia and the unusual radiographic appearances associated with the variable relationships of the aorta and lower oesophagus. J Fac Radiol* 1954;6:88-95.
- 6) Hilliard AA, Murali NS, Keller AS. *Dysphagia aortica. Ann Intern Med* 2005;142:230-1.
- 7) Birnholz JC, Ferrucci JT, Wyman SM. *Roentgen features of dysphagia aortica. Radiology* 1974;111:93-6.
- 8) Mittal RK, Siskind BN, Hongo M, Flye MW, McCallum RW. *Dysphagia aortica: clinical, radiological, and manometric findings. Dig Dis Sci* 1986;31:379-84.
- 9) Lee J. *Radiological imaging of aortic aneurysms. Korean Circ J* 2007;37:337-45.