

## Acute Postpneumonectomy Empyema with Bronchopleural Fistula Treated with Vacuum-assisted Closure Device

Woo Sik Han, M.D.<sup>1</sup>, Kwhanmien Kim, M.D.<sup>2</sup>

Postpneumonectomy empyema is a life-threatening complication, which is often related with a bronchopleural fistula. After surgical repair of fistula, sterilization of infected pleural cavity is important and usually carried out by long-term cyclic irrigation. We report a case in which vacuum-assisted closure device was successfully applied to sterilize the pleural cavity and obliterate bronchopleural fistula.

Key words: 1. Pneumonectomy  
2. Empyema  
3. Bronchial fistula  
4. Device

### CASE REPORT

A 69-year-old man was referred due to newly developed hemoptysis and was diagnosed as operable adenocarcinoma of the right upper lobe of the lung. Because the tumor was invading the right main bronchus and azygos vein, right pneumonectomy was inevitable. No complication was observed during the immediate postoperative period. However, from the 6th postoperative day, he developed tachypnea, desaturation (SaO<sub>2</sub> 85% to 90% under room air), and atrial fibrillation with rapid ventricle response around 150 beat per minute. Despite increased oxygen supply, desaturation gradually progressed, and the patient was intubated for mechanical ventilation. After initiating positive mechanical ventilation, severe subcutaneous emphysema developed. Bronchoscopic examination revealed a bronchopleural fistula (BPF) on the right main bronchus stump (Fig. 1A). The left lung was isolated

using double lumen endotracheal tube. Exudates in the right pleural cavity were evacuated by closed thoracostomy, and microorganisms such as *Streptococcus pneumonia* and *Pseudomonas aeruginosa* were isolated from the pleural fluid.

After 5 days of conservative treatment with antibiotics and pleural cavity drainage, surgery was decided to obliterate BPF because the onset of empyema was relatively acute and stump fistula was too large to expect spontaneous closure. After redo thoracotomy through previous incision, primary closure of BPF was performed by multiple interrupted sutures along with transposition of omental flap to the bronchial stump (Fig. 1B). After thorough debridement and irrigation of pleural cavity, the right pleural cavity was packed with sterilized gauze and pericostal sutures were applied to approximate the intercostal space. Vacuum-assisted closure (VAC) sponge (Curavac; Daewoong, Seoul, Korea) was applied just above the rib leaving the pleural cavity communicated

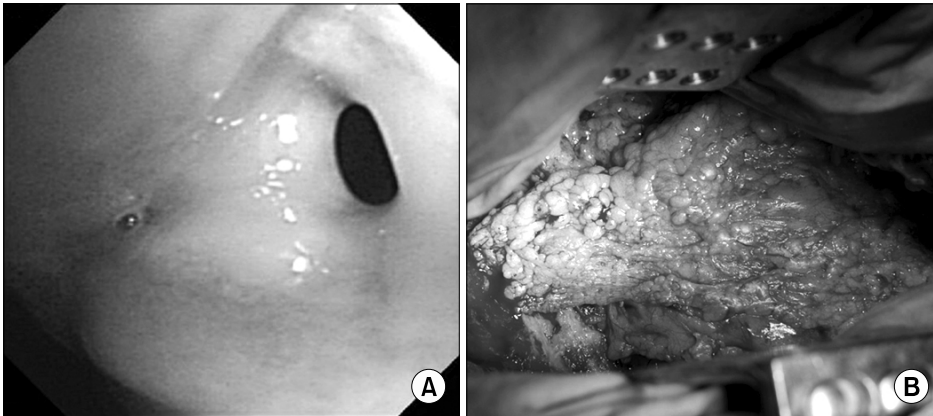
Department of Thoracic and Cardiovascular Surgery, <sup>1</sup>Samsung Medical Center, Sungkyunkwan University School of Medicine, <sup>2</sup>Seoul National University Bundang Hospital, Seoul National University College of Medicine

Received: November 8, 2011, Revised: November 28, 2011, Accepted: December 1, 2011

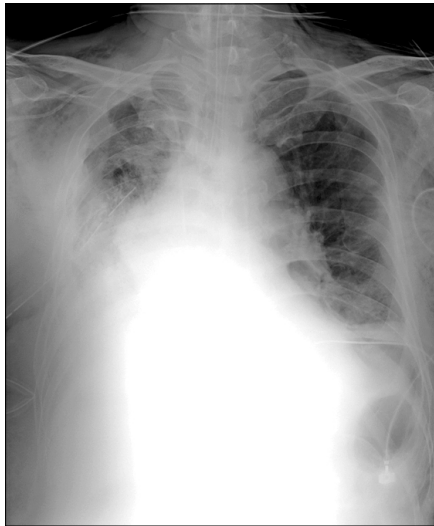
Corresponding author: Kwhanmien Kim, Department of Thoracic and Cardiovascular Surgery, Seoul National University Bundang Hospital, Seoul National University College of Medicine, 82 Gumi-ro, Bundang-gu, Seongnam 463-707, Korea  
(Tel) 82-31-787-7131 (Fax) 82-31-787-4050 (E-mail) kmkim0070@snuh.org

© The Korean Society for Thoracic and Cardiovascular Surgery. 2012. All right reserved.

© This is an open access article distributed under the terms of the Creative Commons Attribution Non-Commercial License (<http://creativecommons.org/licenses/by-nc/3.0>) which permits unrestricted non-commercial use, distribution, and reproduction in any medium, provided the original work is properly cited.



**Fig. 1.** (A) Bronchoscopic finding showing fistula opening at the right main bronchus stump. (B) Omentum flap transpositioned to the repaired bronchial stump.



**Fig. 2.** Chest X-ray showing packed gauze to prevent mediastinal shifting.

through intercostal space. A 12 French chest tube was placed into the VAC sponge to apply negative pressure. The skin above the VAC sponge was widely covered using adhesive drape and negative pressure of 120 mmHg was applied for exudates evacuation. Additional feeding jejunostomy was performed for nutritional support.

Three additional VAC dressing changes were performed under general anesthesia on every 3 days after BPF closure. After confirming that no more organisms from the right pleural cavity were isolated by follow-up microbial culture, Clagett operation was performed on 9th postoperative days from BPF closure and thoracotomy wound could be closed without additional VAC apply. The patient was discharged at

42 days from Clagett operation. The patient remains asymptomatic without any evidence of infection or wound problem for 7 months follow-up.

## DISCUSSION

Postpneumonectomy empyema (PPE) is a life-threatening complication, and is often related with a BPF. Treatment of PPE should be targeted on closure of BPF, effective drainage of pleura cavity, and obliteration of the dead space [1].

One of the most popular approaches to treat PPE with BPF is the closure of bronchial stump followed by irrigation of the pleural space through open window thoracotomy. Delayed closure is performed with dead space filled by antibiotics solution (so-called Clagett operation) [2]. Although this approach has been shown to be highly successful, it forces the patient long hospitalization during the sterilization and stressful daily irrigation with dressing change [3]. So we searched for different methods to shorten the hospitalization period and cost.

Recently, novel technique using VAC has been widely used for various wound infections, such as deep sternal wound infection and open orthopedic fractures. VAC device promotes wound healing by generating negative pressure which leads to granulation tissue formation, removal of exudates, and reduction of edema with increased tissue perfusion by arteriolar dilatation [4]. We borrowed this advantage of VAC for the sterilization of pneumonectomy space instead of daily irrigation with dressing change through open thoracotomy.

In this patient, peribronchial tissue was fresh enough for

early surgical repair because the detection of PPE with BPF was relatively earlier. Also infection in the pleural cavity was relatively not severe. Therefore we thought early sterilization with VAC was possible, if we could obliterate the BPF with omental flap transposition. Before we decided to conduct this procedure, one of our main concerns was complication induced by negative suction pressure, such as bleeding, disruption of repaired fistula, or mediastinal shifting. In this case, we packed sterilized gauze into pleural cavity to avoid direct contact of negative pressure to mediastinum (Fig. 2) [5]. Exudates were evacuated by the VAC system through communication along the intercostal space. By these methods stated above, we could control the PPE effectively for relatively short period, less cost and trouble for patient.

Although VAC dressing in PPE with BPF is not widely used method, it could be an effective alternative method for the open window sterilization with shorter treatment period in selected patients. We report a case of postoperative empyema

successfully treated with VAC system.

## REFERENCES

1. Kim HR, Kim YT, Sung SW, Kim JH. *20-year experience of surgical treatment for postpneumonectomy empyema.* Korean J Thorac Cardiovasc Surg 2002;35:542-7.
2. Gharagozloo F, Trachiotis G, Wolfe A, DuBree KJ, Cox JL. *Pleural space irrigation and modified Clagett procedure for the treatment of early postpneumonectomy empyema.* J Thorac Cardiovasc Surg 1998;116:943-8.
3. Zaheer S, Allen MS, Cassivi SD, et al. *Postpneumonectomy empyema: results after the Clagett procedure.* Ann Thorac Surg 2006;82:279-86.
4. Chang WH, Huh K, Park YW, Kim HJ, Jeong YS, Youm W. *Vacuum-assisted closure in treatment of poststernotomy wound infection and mediastinitis: three cases report.* Korean J Thorac Cardiovasc Surg 2002;35:166-9.
5. Saadi A, Perentes JY, Gonzalez M, et al. *Vacuum-assisted closure device: a useful tool in the management of severe intrathoracic infections.* Ann Thorac Surg 2011;91:1582-9.