


# Comparison of the Medial And Lateral Rotations of the Shoulder Between Non-Athletes and Professional Squash Athletes\*

## *Comparação das rotações medial e lateral do ombro entre não-atletas e atletas profissionais de squash*

José Carlos Souza Vilela<sup>1</sup> Haroldo Oliveira de Freitas Júnior<sup>1</sup> Thiago Rodrigues Sérgio<sup>1</sup>  
 Bruno Jannotti Pádua<sup>1</sup> Eduardo Louzada da Costa<sup>1</sup> Thalles Leandro Abreu Machado<sup>1</sup>   
 Tadeu Fonseca Barbosa<sup>1</sup>

<sup>1</sup> Hospital Unimed BH, Belo Horizonte, MG, Brasil

Rev Bras Ortop 2020;55(2):221–225.

Address for correspondence Thalles Leandro Abreu Machado, MD, Instituto Mineiro de Ortopedia e Traumatologia IMOT, Rua Grão Pará 648, 2º andar, Santa Efigênia, 30.150-340, Belo Horizonte, MG, Brazil (e-mail: thallescirugiadoombro@gmail.com).

### Abstract

**Objective** To compare the medial and lateral rotations of the shoulders and the distances between the coracoid process and the cubital fossa of non-athletic individuals to those of elite squash players.

**Method** The cross-sectional study was performed between March and August 2017. Male and female non-athletes ( $n = 628$ ) were selected at the Orthopedic Emergency Service of our institution. The inclusion criteria were: age between 18 and 60 years, no physical disabilities or cognitive impairments and absence of pain in the upper limbs. Elite squash players ( $n = 30$ ) of various nationalities were selected at an event held in our city. All of the athletes had practiced this sport under high performance requirements for  $> 10$  years and/or 10.000 hours, and all were asymptomatic. Demographic and clinical data were collected through interviews, while physical examinations and shoulder assessments were performed by a single orthopedic practitioner.

**Results** If compared with non-athletes, elite squash players presented significant ( $p < 0.001$ ) mean losses of  $23^{\circ}34'$  in medial rotation and significant ( $p < 0.003$ ) mean gains of  $10^{\circ}23'$  in lateral rotation of the dominant shoulders. There was a significant difference ( $p < 0.008$ ) between non-athletes and athletes regarding the distance between the coracoid process and the cubital fossa in the dominant arm.

### Keywords

- ▶ range of motion
- ▶ shoulder joint
- ▶ rotation

### Introduction

The shoulder is a complex joint that presents the widest range of motion if compared with any other joint in the body. Perfect shoulder function depends on the interaction be-

tween the static (capsule, ligaments and humeral head) and dynamic (muscles in the shoulder girdle, especially the rotator cuff) joint stabilizers.<sup>1</sup>

Sports activities that rely extensively on overhead throwing skills, such as baseball, volleyball, tennis and squash, demand considerable shoulder mobility and stability from the players.<sup>2,3</sup> In the course of these activities, the shoulders of the athletes withstand forces that are far greater than those

\* Study conducted at the Hospital Unimed BH, Belo Horizonte, MG, Brazil.

**Resumo**

**Conclusion** Intensive squash practice causes adaptive changes that trigger glenohumeral medial rotation deficit, accompanied by significant lateral rotation gain, and can generate pathogenic alterations in the shoulder.

**Objetivo** Comparar as rotações medial e lateral dos ombros e as distâncias entre o processo coracoide e a fossa cubital de indivíduos não atletas e de jogadores profissionais de squash.

**Método** O estudo transversal foi realizado entre março e agosto de 2017. Não atletas do sexo feminino e masculino ( $n = 628$ ) foram selecionados no Serviço de Emergência Ortopédica da nossa instituição. Os critérios de inclusão foram: idade entre 18 e 60 anos, ausência de deficiências físicas ou cognitivas e ausência de dor nos membros superiores. Jogadores profissionais de squash ( $n = 30$ ) de várias nacionalidades foram selecionados em um evento realizado em nossa cidade. Todos os atletas praticavam seu esporte em alto nível há  $> 10$  anos e/ou 10.000 horas, e todos eram assintomáticos. Os dados demográficos e clínicos foram coletados por entrevista, enquanto os exames físicos e de ombro foram realizados por um único consultor ortopédico.

**Resultados** Em comparação com os não atletas, os jogadores profissionais de squash apresentaram perdas médias significativas ( $p < 0,001$ ) de  $23^{\circ}34'$  na rotação interna e significativos ( $p < 0,003$ ) ganhos médios de  $10^{\circ}23'$  na rotação externa dos ombros dominantes. Houve diferença significativa ( $p < 0,008$ ) entre não atletas e atletas quanto à distância entre o processo coracoide e a fossa cubital no braço dominante.

**Conclusão** A participação intensiva no squash provoca alterações adaptativas que dão origem ao déficit de rotação interna glenoumeral, acompanhadas de significativo ganho de rotação externa, e podem gerar alterações patogênicas no ombro.

**Palavras-chave**

- ▶ amplitude de movimento
- ▶ articulação do ombro
- ▶ rotação

required during normal physiological motions. For example, the  $72^{\circ}30'$  medial rotation of a baseball pitcher shoulder stands out among the fastest human movements ever recorded, while the serving motion in tennis can propel the ball at a velocity of 240 km/h, and the speed of a “spiked” volley ball can easily exceed 100 km/h.<sup>4,5</sup> During a squash match, the ball can reach speeds above 170mph. Most squash injuries are acute or traumatic events, and a small proportion of those are related to “overuse.”<sup>6</sup> Such repetitive shoulder torques generate various adaptive alterations such as increased glenohumeral lateral rotation, restricted medial rotation, excessive retroversion of the humeral head and of the glenoid itself, and anterior capsular hyperlaxity instability. These alterations may be followed by pathological compensations such as anterior instability and contracture of the posterior capsule, particularly connected to glenohumeral internal rotation deficiency (GIRD).<sup>3,7-10</sup> These alterations can promote internal impingement that may lead to partial or total rupture of the supraspinatus tendon, anterior or posterior labral tears, glenohumeral chondral lesions, chondromalacia of the posterosuperior aspect of the humeral head, rupture of the long head of the biceps tendon and scapular dyskinesis.<sup>7,10</sup>

Loss of medial rotation and its consequences are associated with several factors, most particularly the time spent in practicing the sport.<sup>5,11</sup> Additionally, squash rackets' weight and length increase both the arm leverage and the torque generated by the shoulder resulting in an enhanced potential to cause injury. Preventing and treating GIRD is a straightforward, low-cost, low-risk and highly beneficial way to

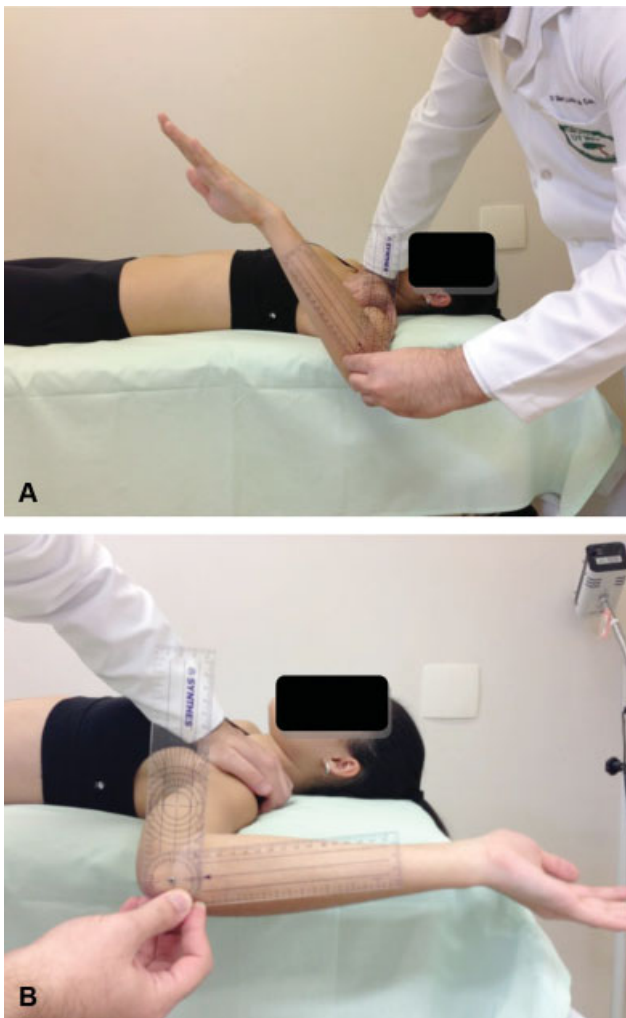
preserve the anatomy and function of the shoulders of athletes.<sup>5</sup> The standard parameter set for the medial rotation of the shoulders of non-athletes ranges between 0 and  $90^{\circ}$ . The aim of the present study was to test the hypothesis that intensive squash practice can cause adaptive changes that trigger glenohumeral medial rotation deficit, which may be accompanied by lateral rotation gain.

**Methods**

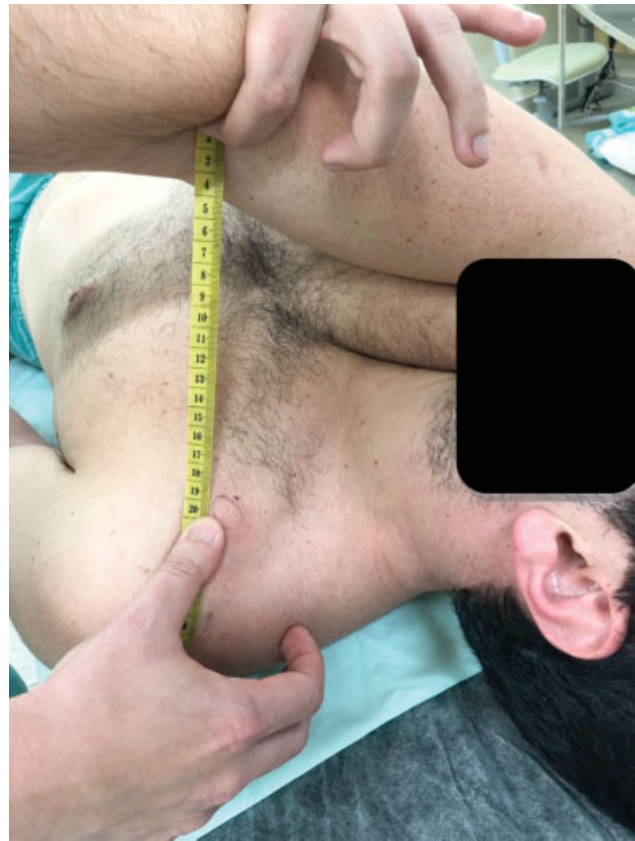A detailed version of the project was submitted to and approved by the Ethical Research Committee of our institution. The aims and objectives of the study were explained to all potential participants emphasizing the voluntary nature of participation. Written informed consent was obtained from all participants prior to starting the study.

This cross-sectional study was conducted between March and August 2017. Male and female participants in the non-athletic group ( $n = 628$ ) were selected at the Orthopedic Emergency Service of our institution. The inclusion criteria were: age between 18 and 60 years old, no physical disabilities or cognitive impairments that could hinder the interview and/or the physical examination, and absence of symptoms or signs of pain in the upper limbs. All of the members of the athletes group had practiced high performance squash for  $> 10$  years and/or 10.000 hours<sup>12</sup> and presented no symptoms or signs of pain in the upper limbs. This group ( $n = 30$ ) comprised individuals of various nationalities selected from the participants of an event held at Academia

Winner Squash, in our city. Demographic and clinical data (gender, age, occupation, dominant arm, level of physical activity) were collected by interviewing the participants. The patients were evaluated in dorsal decubitus, and the physical exams were performed by a single orthopedist, who manually stabilized the scapula while evaluating the shoulders for medial and lateral rotation, with the shoulders and elbows in 90° of abduction and flexion, using as axis a perpendicular line to the floor (► Fig. 1). Posterior capsular tightness was also evaluated using “horizontal side-lying adduction of the humerus” developed and validated Tyler et al.<sup>13</sup>, measuring the distance between the contralateral coracoid process and the cubital fossa with the shoulder in maximum adduction (► Fig. 2).<sup>8</sup> An analogic goniometer (Insize, 35 cm, Fabricante Insize, São Paulo, SP, Brazil) was used to estimate all measurements, which were taken three times and expressed as mean values  $\pm$  standard deviation.<sup>10</sup> Data were analyzed with the aid of SPSS Statistics for Windows, Version 19 (IBM Corp., Armonk, NY, USA). The significances of differences between mean values were assessed using Student *t* tests: differences were considered significant at  $p < 0.05$ .



**Fig. 1** Supine position adopted during physical examination showing: (A) assessment of medial rotation, and (B) assessment of lateral rotation. Source: Author's personal archive.



**Fig. 2** Supine position adopted during physical examination showing the distance between the coracoid process and the cubital fossa. Source: Author's personal archive

## Results

Members of the non-athletic group presented a mean age of 44 years old (range: 18 to 60 years old) and included 245 males and 383 females, of whom 585 were right-handed and 43 were left-handed. The elite athletes group exhibited a mean age of 26.7 years old (range: 18 to 39 years old) and comprised 27 males and 4 females, of whom 27 were right-handed and 4 were left-handed. The mean time period over which the squash players had practiced the sport was  $13.87 \pm 3.71$  years.

Medial and lateral shoulder rotations, as well as the distances between the contralateral coracoid process and the cubital fossa that have been determined for each group are shown in ► Table 1. In comparison with non-athletes, a mean loss of 23°34' in medial rotation and a mean gain of 10°23' in lateral rotation of the dominant shoulders of the elite squash players were statistically significant ( $p < 0.001$  and 0.003, respectively). Furthermore, there was a significant difference ( $p < 0.008$ ) between non-athletes and athletes regarding the distance between the coracoid process and the cubital fossa in the dominant arm.

## Discussion

Correct functioning of the glenohumeral joint requires precise coordination between the muscles of the scapula and the

**Table 1** Mean values of medial and lateral rotation and distance from the coracoid process to the cubital fossa in non-athletes and elite squash players

Parameter	Non-athletes <i>n</i> = 628	Athletes <i>n</i> = 30
Medial rotation (degrees)		
Right shoulder	64.16 ± 11.20	45.27 ± 14.80
Left shoulder	63.02 ± 11.67	74.67 ± 17.21
Dominant shoulder	64.35 ± 11.30	40.77 ± 7.40
Lateral rotation (degrees)		
Right shoulder	90.14 ± 5.98	98.4 ± 13.10
Left shoulder	88.70 ± 7.10	93.67 ± 11.59
Dominant shoulder	90.17 ± 6.05	100.56 ± 12.75
Coracoid process to cubital fossa distance (cm)		
Right arm	24.74 ± 3.17	27 ± 4.67
Left arm	25.61 ± 3.79	27.03 ± 4.73
Dominant arm	24.77 ± 3.19	27.3 ± 4.53

Mean values ± standard deviation of three measurements.

static stabilizers. The delicate balance between shoulder mobility and stability is what ensure since the isometric movements of daily tasks to the explosive throwing actions involved in sporting activities.

Although the problems of internal impingement had been described almost simultaneously in 1991 by Walch et al<sup>14</sup> and by Paley et al,<sup>7</sup> it is still not clear if there is a true association between internal impingement with the internal impact and the medial rotation deficit in subjects who practiced overhead sports.<sup>15</sup> The currently accepted model of the occurrence of medial rotation deficit proposes that posterior capsule contracture is the eliciting factor of the cascade of injuries that affect overhead athletes. As tightness of the posterior capsule develops in the shoulder, the glenohumeral contact point is shifted toward the posterior and superior directions when the shoulder is in abduction and lateral rotation. The hyperangulation and hyperlateral rotation forces cause an overload of the rotator cuff leading to partial tears.<sup>16</sup>

The results presented in the present paper provide an unprecedented comparison between the shoulder motion parameters of asymptomatic squash players with those established for a large and diversified population of non-athletes. Several investigations have demonstrated medial rotation deficits within 10° and 20°, typically accompanied by lateral rotation gains of similar magnitudes, in asymptomatic athletes partaking in overhead sports. In the case of symptomatic athletes, however, the medial rotation deficit is greater than the lateral rotation gain, and deficits in the dominant shoulder may be as high as 25° in comparison with the contralateral shoulder.<sup>10,17</sup> Apparently, 90% of the symptomatic athletes respond positively to rehabilitation programs with deficits being reduced by 10° to 20° degrees.<sup>10</sup> However, it has been reported that athletes exhibiting me-

dial rotation deficit of 19°42' already present internal impingement.<sup>18</sup>

The definition of normal physiological parameters established in the present investigation is not only important for the identification of motion anomalies, but also for the adoption of prophylactic measures that could prevent the aggravation of GIRD and associated lesions. Such causes might be related to the existence of medial rotation deficit together with repetitive overload of the shoulder, conditions that can be treated through rehabilitation programs. Further important points that emerge from this study are: (i) the verification of previous findings of medial rotation deficit in overhead athletes; (ii) the set-up of physiological motion parameters based on measurements taken from a large population of non-athletic individuals (*n* = 628); and (iii) the first report of anatomical dysfunctions observed in asymptomatic elite squash players. The main constraints of the study were: (i) the limited number of athletes (*n* = 30) assessed; (ii) the cross-sectional nature of the investigation and the impossibility of follow-up, with a direct impact on further exploring the association between medial rotation deficit and related symptoms; and (iii) the lack of specialized exams, as nuclear magnetic resonance for example, considering that possible anatomical lesions may not be diagnosed in the clinical examination and that this tool is not ethically justifiable for asymptomatic patients.

## Conclusion

Squash, similarly to other overhead sports, causes adaptive changes that trigger glenohumeral medial rotation deficit accompanied by significant lateral rotation gain and can generate pathogenic alterations in the shoulder.

### Conflict of Interests

The authors have no conflict of interests to declare.

## References

- Bigliani LU, Kelkar R, Flatow EL, Pollock RG, Mow VC. Glenohumeral stability. Biomechanical properties of passive and active stabilizers. *Clin Orthop Relat Res* 1996;(330):13–30
- Bigliani LU, Codd TP, Connor PM, Levine WN, Littlefield MA, Hershon SJ. Shoulder motion and laxity in the professional baseball player. *Am J Sports Med* 1997;25(05):609–613
- Crockett HC, Gross LB, Wilk KE, et al. Osseous adaptation and range of motion at the glenohumeral joint in professional baseball pitchers. *Am J Sports Med* 2002;30(01):20–26
- Wilk KE, Macrina LC, Fleisig GS, et al. Correlation of glenohumeral internal rotation deficit and total rotational motion to shoulder injuries in professional baseball pitchers. *Am J Sports Med* 2011; 39(02):329–335
- Abrams GD, Sheets AL, Andriacchi TP, Safran MR. Review of tennis serve motion analysis and the biomechanics of three serve types with implications for injury. *Sports Biomech* 2011;10(04):378–390
- Jayanthi N, Esser S. Racket sports. *Curr Sports Med Rep* 2013;12 (05):329–336
- Paley KJ, Jobe FW, Pink MM, Kvitne RS, ElAttrache NS. Arthroscopic findings in the overhand throwing athlete: evidence for posterior internal impingement of the rotator cuff. *Arthroscopy* 2000;16(01):35–40

- 8 Myers JB, Laudner KG, Pasquale MR, Bradley JP, Lephart SM. Glenohumeral range of motion deficits and posterior shoulder tightness in throwers with pathologic internal impingement. *Am J Sports Med* 2006;34(03):385-391
- 9 Jobe FW, Giangarra CE, Kvitne RS, Glousman RE. Anterior capsulolabral reconstruction of the shoulder in athletes in overhand sports. *Am J Sports Med* 1991;19(05):428-434
- 10 Burkhart SS, Morgan CD, Kibler WB. The disabled throwing shoulder: spectrum of pathology Part I: pathoanatomy and biomechanics. *Arthroscopy* 2003;19(04):404-420
- 11 Kibler WB, Chandler TJ, Livingston BP, Roetert EP. Shoulder range of motion in elite tennis players. Effect of age and years of tournament play. *Am J Sports Med* 1996;24(03):279-285
- 12 Hodges NJ, Starkes JL, MacMahon C. Expert performance in sport: a cognitive perspective. In: Ericsson KA, Charness N, Feltovich PJ, Hoffman RR. *The Cambridge handbook of expertise and expert performance*. Cambridge: Cambridge University Press; 2006: 471-478
- 13 Tyler TF, Nicholas SJ, Lee SJ, Mullaney M, McHugh MP. Correction of posterior shoulder tightness is associated with symptom resolution in patients with internal impingement. *Am J Sports Med* 2010;38(01):114-119
- 14 Walch G, Liotard JP, Boileau P, Noel E. Un autre conflit de l'épaule: "Le conflit glénoïdien postéro-supérieur. *Rev Chir Orthop Repar Appar Mot* 1991;77(08):571-574
- 15 Sonnery-Cottet B, Edwards TB, Noel E, Walch G. Results of arthroscopic treatment of posterosuperior glenoid impingement in tennis players. *Am J Sports Med* 2002;30(02):227-232
- 16 Barber FA, Morgan CD, Burkhart SS, Jobe CM. Current Controversies. Point counterpoint. Labrum/biceps/cuff dysfunction in the throwing athlete. *Arthroscopy* 1999;15(08):852-857
- 17 Burkhart SS, Morgan CD, Kibler WB. Shoulder injuries in overhead athletes. The "dead arm" revisited. *Clin Sports Med* 2000;19(01):125-158
- 18 Myers JB, Laudner KG, Pasquale MR, Bradley JP, Lephart SM. Scapular position and orientation in throwing athletes. *Am J Sports Med* 2005;33(02):263-271