

Does Combined Access Mandibulotomy, Rim Mandibulectomy and Neck Dissection Compound the Late Effects of Radiotherapy?

Dimitris Tatsis, MD, DDS*; Xin-Ying Kowa, FRCR MBBS, BSc(Hons)†; Deepti Sinha, BDS, MBBS, MME*; Nicholas Kalavrezos, MD, DDS, FRCS *

Lip split mandibulotomy (LSMA) is still considered a valid, safe, and effective approach for access to the posterior oral cavity and oropharynx in ablative and reconstructive surgery. A recent systematic review reports a morbidity spectrum related to this procedure, including osteoradionecrosis of the mandibulotomy site after postoperative radiotherapy, with an incidence rate of 0%–11.9%.¹

Nevertheless, we hypothesize that the combination of LSMA with ipsilateral rim mandibulectomy and neck dissection affect the mandible to a greater extent after postoperative radiotherapy, having detrimental effects in mandibular vascularization. Arteriosclerosis and diffuse intimal thickening increase in the inferior alveolar artery, especially after the sixth decade of life.² The subperiosteal plexus presumably undertakes the major role in mandibular perfusion after degeneration of the inferior alveolar artery, as studies have shown that vascularization of the mandible changes over time. Any disruption in the continuity of the periosteum, such as a rim mandibulectomy, can potentially disrupt the perfusion of the mandible. Furthermore, it has been demonstrated in cadaveric models that the mandible receives its blood supply from the ipsilateral facial artery, and in 50% of the studied models, the facial artery contributes on the contralateral side.³ Vascular communication between the midline of the mandible has also been shown in murine models, via the symphysis, periosteum, and mucosa.⁴ Any disruption to the supply of the facial artery toward the mandible, caused by the neck dissection or the use of the facial vessels for flap anastomosis, in addition to the mandibular split, can further diminish the nutrient vessels to the mandible (Fig. 1).

Recently, two patients have been treated for osteoradionecrosis after the combination of lip split mandibulotomy, ipsilateral rim mandibulectomy, and neck dissection. The first patient, a 53-year-old woman, was initially treated for a poorly differentiated pT4aN0M0 left oropharyngeal squamous cell carcinoma in 2021 with tumor resection via LSMA,

left rim mandibulectomy, neck dissection, and reconstruction with radial forearm free flap. She received postoperative chemoradiotherapy (60–65Gy to the left maxilla/mandible) and eventually developed stage III mandibular ORN requiring surgical intervention, with an extensive segmental mandibulectomy including outer skin excision and a latissimus dorsi free flap to reconstruct the through-and-through tissue defect. The second patient, a 61-year-old woman, was treated for a right parapharyngeal pT2N0M0 mucoepidermoid carcinoma in 2019, with LSMA, parapharyngeal resection in continuity with elective neck dissection, rim mandibulectomy, and reconstruction with a radial forearm free flap. After postoperative radiotherapy (65Gy), she developed stage III mandibular ORN, requiring a lingual rim mandibulectomy to remove the necrotic bone and a radial forearm free flap to reconstruct the defect (Figs. 2 and 3).

To conclude, LSMA does provide adequate access for the posterior oral and oropharynx regions, but the combination with rim mandibulectomy and neck dissection in conjunction with postoperative radiotherapy can be potentially catastrophic to the mandible's blood supply. Alternative approaches, such as transoral robotic surgery or cervical pull-through, despite presenting nonsignificant difference in short-term complications, could provide one less risk factor for osteoradionecrosis of the mandible.⁵

Dimitris Tatsis, MD, DDS

Head & Neck Surgery

University College London Hospital (UCLH)

250 Euston Road

London, NW1 2PG, UK

E-mail: dimitris.tatsis@nhs.net

DISCLOSURE

The authors have no financial interest to declare in relation to the content of this article.

REFERENCES

- Hedayat F, (Jerry) Htwe KK, Vassiliou LV, et al. Morbidity related to the lip-split mandibulotomy approach: a systematic and narrative review. *Br J Oral Maxillofac Surg*. 2022;60:430–436.
- Semba I, Funakoshi K, Kitano M. Histomorphometric analysis of age changes in the human inferior alveolar artery. *Arch Oral Biol*. 2001;46:13–21.
- Molnar G, Plachtovics M, Baksa G, et al. Intraosseous territory of the facial artery in the maxilla and anterior mandible: implications for allotransplantation. *J Craniomaxillofac Surg*. 2012;40:180–184.
- Nilsson LP, Granström G, Röckert HO. Changes in mineral content, mineral deposition and vascular supply of the mandible after osteotomy. *Scand J Plast Reconstr Surg Hand Surg*. 1988;22:15–23.
- Biron VL, O'Connell DA, Barber B, et al. Transoral robotic surgery with radial forearm free flap reconstruction: case control analysis. *J Otolaryngol Head Neck Surg*. 2017;46:20.

From the *Head & Neck Surgery, University College London Hospital NHS Foundation Trust, London, UK; and †Department of Imaging, University College Hospitals London NHS Foundation Trust, 250 Euston Road, London, NW1 2PG, UK.

Received for publication March 15, 2023; accepted May 2, 2023.

Copyright © 2023 The Authors. Published by Wolters Kluwer Health, Inc. on behalf of The American Society of Plastic Surgeons. This is an open-access article distributed under the terms of the Creative Commons Attribution-Non Commercial-No Derivatives License 4.0 (CCBY-NC-ND), where it is permissible to download and share the work provided it is properly cited. The work cannot be changed in any way or used commercially without permission from the journal.

Plast Reconstr Surg Glob Open 2023; 11:e5081; doi: 10.1097/GOX.0000000000005081; Published online 14 June 2023.

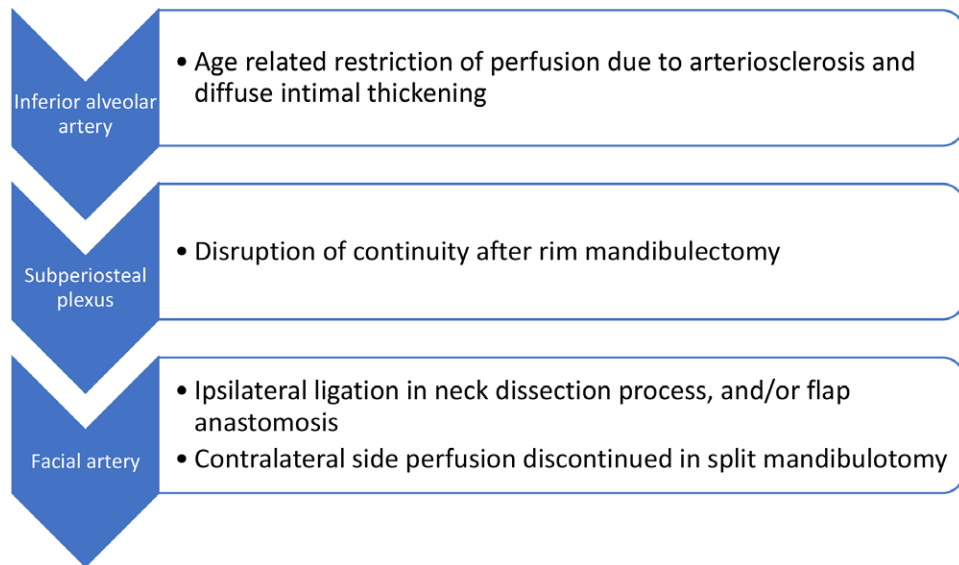


Fig. 1. Summary of vascular contributions in mandibular perfusion and critical steps that disrupt them.

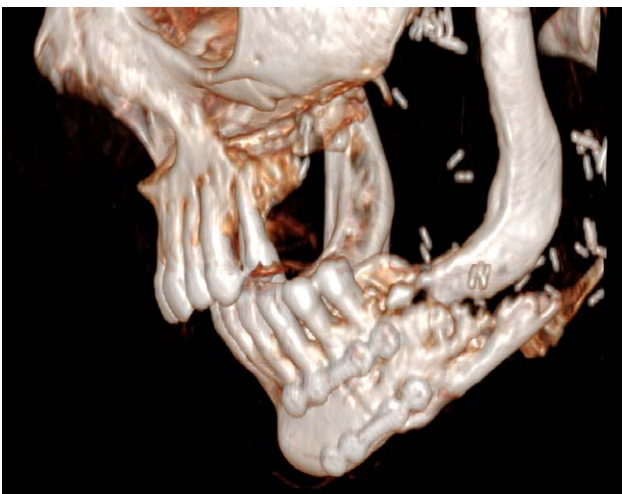


Fig. 2. 3D reconstruction, stage III ORN complicated by a pathological fracture. Exposed bone and bony sequestra visible. Rim mandibulectomy is apparent.

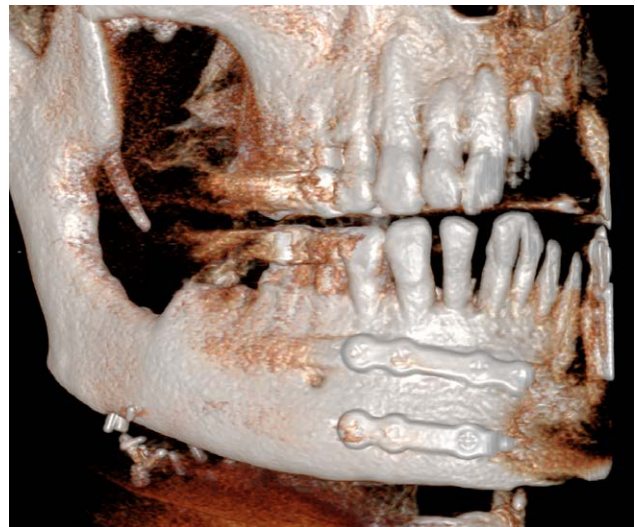

Fig. 3. 3D reconstruction, stage III ORN, lingual plate bone loss. Rim mandibulectomy is apparent.