

Sex Estimation From Sternal Measurements Using Multidetector Computed Tomography

Oguzhan Ekizoglu, MD, Elif Hocaoglu, MD, Ercan Inci, Assoc.Prof., Mustafa Gokhan Bilgili, MD, Dilek Solmaz, MD, Irem Erdil, MD, and Ismail Ozgur Can, Assoc.Prof.

Abstract: We aimed to show the utility and reliability of sternal morphometric analysis for sex estimation.

Sex estimation is a very important step in forensic identification. Skeletal surveys are main methods for sex estimation studies. Morphometric analysis of sternum may provide high accuracy rated data in sex discrimination.

In this study, morphometric analysis of sternum was evaluated in 1 mm chest computed tomography scans for sex estimation. Four hundred forty three subjects (202 female, 241 male, mean age: 44 ± 8.1 [distribution: 30–60 year old]) were included the study. Manubrium length (ML), mesosternum length (2L), Sternebra 1 (S1W), and Sternebra 3 (S3W) width were measured and also sternal index (SI) was calculated. Differences between genders were evaluated by student *t*-test. Predictive factors of sex were determined by discrimination analysis and receiver operating characteristic (ROC) analysis.

Male sternal measurement values are significantly higher than females ($P < 0.001$) while SI is significantly low in males ($P < 0.001$). In discrimination analysis, MSL has high accuracy rate with 80.2% in females and 80.9% in males. MSL also has the best sensitivity (75.9%) and specificity (87.6%) values. Accuracy rates were above 80% in 3 stepwise discrimination analysis for both sexes. Stepwise 1 (ML, MSL, S1W, S3W) has the highest accuracy rate in stepwise discrimination analysis with 86.1% in females and 83.8% in males.

Our study showed that morphometric computed tomography analysis of sternum might provide important information for sex estimation.

(*Medicine* 93(27):e240)

INTRODUCTION

Anthropometric studies of skeletal structures have provided important information for identification procedures. Post-mortem investigations of various skeletal elements provide important data for sex estimation. In cases of advanced destruction of skeletal remains, especially pelvis and craniofacial morphometric studies are frequently used methods.^{1–6} Many

different factors may affect the integrity of skeletal remains. Explosions, putrefaction, traumatic damage, and geographic factors may hinder investigations of the pelvis and skull bones. Also, some studies have reported that the pelvis and skull bones are, in fact, less reliable for sex estimation.^{2–5} The integrity of the sternum may be preserved even in advanced skeletal destruction. Bongiovanni and Spradley⁷ stated that the good condition levels of the manubrium and sternum was above 59% in the Forensic Anthropology Data Bank. Wenzel⁸ reported data on sexual dimorphism in the manubrium and sternum. The author concluded that the length of the manubrium was almost equal in both sexes and the mesosternum was longer in males. Thereafter, “the manubrium of the female sternum exceeds half the length of the body, while the body in the male sternum is at least twice as long as the manubrium” description became known as Hyrtl law.⁹

Morphometric analyses of the sternum can be performed by dry bone direct measurements and radiological methods during the post-mortem period.^{10–20} Some radiological studies and morphometric analyses have been performed in living subjects.^{21–24} In these studies, several parameters—such as the manubrium, mesosternum, and total sternum length, manubrium, sternabra 1, and sternabra 3 width, sternal area, and the sternal index (SI)—were used. Although there are some methodological differences among the studies, morphometric analyses of sternum usually provide 80% or greater accuracy.^{7–23}

This study was designed to assess the utility and reliability of sternal morphometric analysis for sex estimation in a Turkish population.

MATERIALS AND METHODS

Multidetector computed tomography (MDCT) scans of 443 subjects between the age group of 33 to 60 years were assessed. The cases were selected from the easily available general population. This study is approved by the ethics committee of the Bakirköy Dr. Sadi Konuk Hospital/Istanbul. Informed consent was not given because we retrospectively examined the previous thorax CT images. Subjects with sternal trauma, congenital or acquired thorax deformity were excluded from the study. MDCT imaging was performed in without sedation or contrast material. MDCT examination was obtained using a 40-row MDCT scanner (Siemens Medical Solutions, Erlangen, Germany) from the period of June 2013 to December 2013. A routine thoracic CT protocol was followed. All scans were obtained with the following parameters: tube voltage, 120 kV, effective mAs, 120, and slice thickness 1 mm. All images were transferred to a commercially available workstation. On the workstation, multiplane reformatting (MPR) of images in the sagittal and coronal planes were obtained, and three-dimensional images of the

Editor: Partha Sinha.

Received: September 4, 2014; revised: October 9, 2014; accepted: October 10, 2014.

From the Department of Forensic Medicine (OE); Department of Radiology (EH, EI, IE); Department of Orthopaedics, Bakirkoy Dr. Sadi Konuk Training and Research Hospital, Istanbul, Turkey (MGB); Department of Rheumatology, Namik Kemal University, Faculty of Medicine, Tekirdag, Turkey (DS); and Department of Forensic Medicine, Dokuz Eylul University, Faculty of Medicine, Izmir, Turkey (IOC).

Correspondence: Oguzhan Ekizoglu, Department of Forensic Medicine, Bakirkoy Dr.Sadi Konuk Training and Research, Hospital, Tevfik Saglam Cad. No: 11, 34147 Bakirkoy, Istanbul, Turkey (e-mail: drekizoglu@gmail.com).

The authors have no funding and conflicts of interest to disclose. Copyright © 2014 Wolters Kluwer Health | Lippincott Williams & Wilkins. This is an open access article distributed under the Creative Commons Attribution-NoDerivatives License 4.0, which allows for redistribution, commercial and non-commercial, as long as it is passed along unchanged and in whole, with credit to the author.

ISSN: 0025-7974

DOI: 10.1097/MD.0000000000000240

sternum were obtained. Measurements were performed according to Bass³ as follows:

- Manubrium length (ML): the distance from the jugular notch to the sagittal midpoint of the manubriosternal joint.
- Mesosternum length (MSL): the distance from the sternal angle to the sagittal midpoint of the xiphisternal joint.
- Sternebra 1 width (S1W): the distance between the left and the right first sternebra (depressions between the articulation notches for the second and third costal cartilage).
- Sternebra 3 width (S3W): the distance between the left and right third sternebra (depressions between the articulation notches for the fourth and fifth costal cartilage).
- Sternal index: (manubrium length/mesosternum length) \times 100.
- ML and MSL were measured from sagittal images; S1W and S3W were measured from coronal reformatted images (Figures 1 and 2).

STATISTICAL ANALYSIS

Continuous variables are reported as means and standard deviation. Categorical variables are indicated as percentages. Discrimination analysis and receiver operating characteristic (ROC) analyses were used to define the predictive factors of sex estimation. Classification accuracies of the derived discriminant functions were evaluated by a leave-one-out cross-validation procedure. To determine the optimum cut-off value, sensitivity, specificity, positive predictive value, and negative predictive value were calculated by ROC analysis. Continuous variables were evaluated between groups with Student's *t*-test. The SPSS software (ver. 16; SPSS Inc., Chicago, IL) was used for statistical analyses. *P* values <0.05 were considered to indicate statistical significance.

RESULTS

In total, 443 subjects (202 females, mean age: 45.6, and 241 males, mean age: 54.4) were included. The age range was 30 to 60 years (mean, 44 ± 8.1). Mean values of ML, MSL, S1W, and S3W were higher in males and the differences were statistically significant ($P < 0.001$). The SI was significantly higher in females ($P < 0.001$). Mean measurement values according to sex, standard deviations, and *P* values for significant differences are shown in Table 1.

A multiple regression analysis was performed and discriminant scores were calculated for sternal measurements (Table 2). The accuracy of sex prediction was calculated using the discrimination analysis of sternal measurements. In direct discrimination analysis, MSL had the highest accuracy—80.2% in females and 80.9% in males. Each 3 step-wise discrimination analysis showed an accuracy rate greater than 80% for both sexes. The step-wise 1 (ML, MSL, S1W, S3W) analysis had the highest accuracy (86.1% for females and 83.8% for males). Accuracy values for all measurements after direct and step-wise analyses are shown in Table 3.

ROC analysis was used to determine the optimum values for sex estimation. The optimum cut-off value was determined from sensitivity and specificity values. The optimum sensitivity and specificity values for sex discrimination were identified in the MSL measurement. The sensitivity of MSL was 75.9% and specificity was 87.6%. ROC analysis results for all sternal measurements are shown in Table 4.

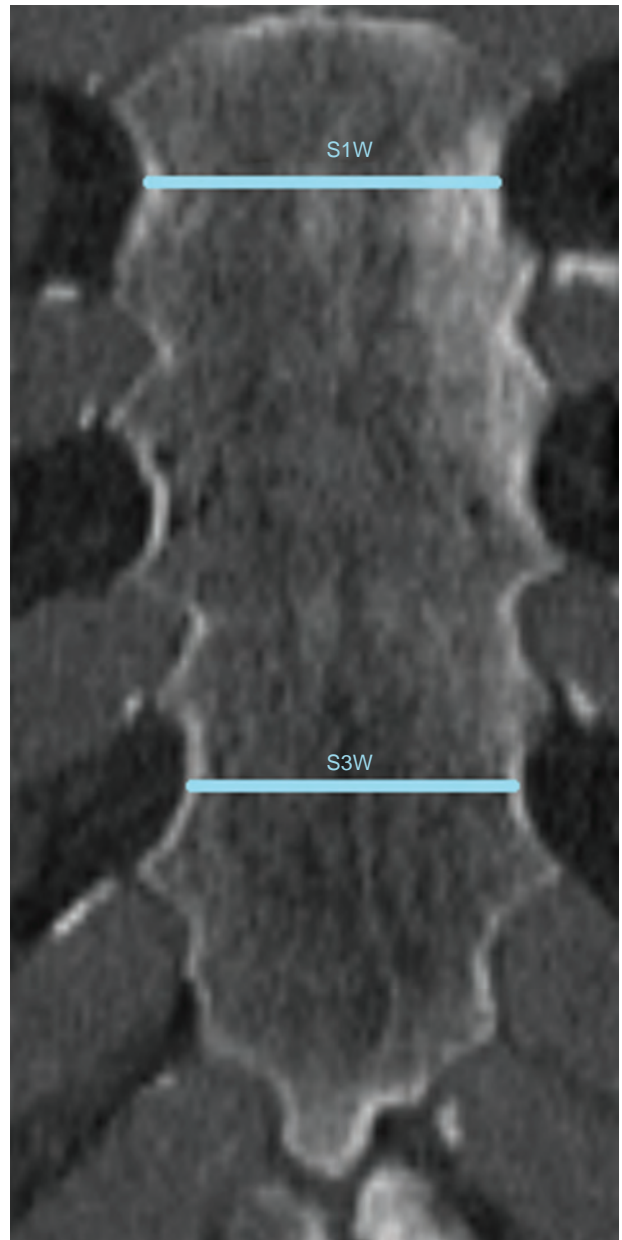


FIGURE 1. Coronal reformatted MDCT image shows sternebra 1 width (S1W) and sternebra 3 width (S3W).

DISCUSSION

Morphometric analyses of various bones by direct measurements from skeletal remains or radiological methods are the basic anthropological options for sex estimation. Trauma, putrefaction, and disappearance for various reasons are the main obstacles to obtaining bones with high integrity.^{2,5} In these circumstances, data collected from a single bone may be important for sex estimation. In the literature, pelvic studies yielded 95% accuracy for sex estimation.^{6,25} Morphometric parameters of the craniofacial region also provide accurate results.^{26–30} The accuracy was reported as 80% for females and 74.3% for males, with an overall level of 77.15%, for the morphometric analysis of maxillary sinuses in a Turkish

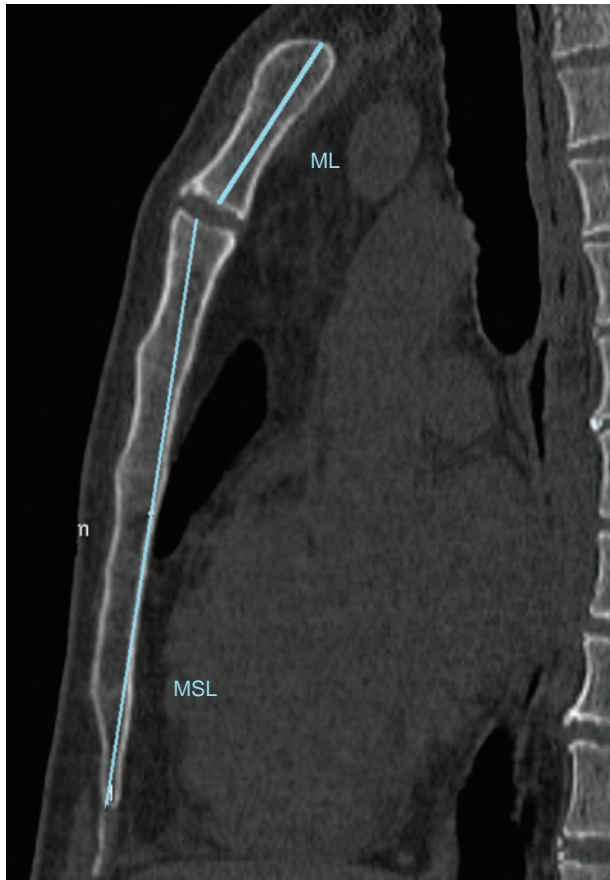

FIGURE 2. Sagittal reformatted MDCT image shows the sagittal dimension of the manubrium. (ML) and the sagittal dimension of the mesosternum (MSL).

TABLE 1. Mean Measurement Values According to Sex

Variables	Female	Male	P-Value
Age, mean ± SD	44 ± 8.1	44 ± 8.1	>0.05
Manubrium length mm, mean ± SD	48.2 ± 4.5	52.5 ± 5.2	<0.001
Mesosternum length mm, mean ± SD	89.1 ± 9.2	104.9 ± 10.6	<0.001
S1W, mean ± SD	25.0 ± 3.2	28.8 ± 3.7	<0.001
S3W, mean ± SD	30.2 ± 6.3	34.1 ± 5.4	<0.001
Sternal index, mean ± SD	54.7 ± 8.1	50.7 ± 9.5	<0.001

population.²⁶ Especially terrorist blastic attacks may cause mass mortality. In these situations the speed of identification process has gained importance. Besides if mass graves investigations are taken into consideration, single preserved bone pieces in disintegrated skeletons could provide a rapid classification in disaster victims identification (DVI).^{31,32} Sternum has a robust structure and its preserved integrity is the main bony structural advantages. As identified in our study, sternum may provide over a 80% sex discrimination property. Fast and easy CT scanning of preserved single bony parts “like sternum” can enable an effective identification method for researchers.³²

Investigation of the reliability of sternum measurements for sex estimation is important because they can be used solely for determination. Morphometric sternum studies provide population-specific data and also highlight differences between populations. We found statistically significant differences in all measured areas (MSL, ML, SW1, SW3, SI) between the sexes. Previous sternal morphometric studies also reported significant differences between the sexes, similar to our study, and in other measurement parameters.^{7–24,33–36} These results also show the negligible effect of ethnicity on sex differences. Assessing similarities and differences in sternal morphometric analysis data from previous studies is important for determining the reliability of measurement methods. Ramadan et al²¹ studied 340 CT views in a Turkish population and reported the following sternal measurements: MSL 50.3, ML 85.1, SW1 25.2, SW3 30.7, and SI 59.8 in females and MSL 53.9, ML

TABLE 2. Discriminant Function Equations for Sternal Dimensions

	ML	MSL	S1W	S3W	SI	Stepwise Analysis (4 Variables) ^a	Stepwise Analysis (Sternum)	Stepwise Analysis (Mesosternum) ^a
Eigen values	0.185	0.618	0.289	0.110	0.049	1.048	0.810	0.908
% of variance	100	100	100	100	100	100	100	100
Cumulative%	100	100	100	100	100	100	100	100
Canonical correlation	0.395	0.618	0.473	0.315	0.216	0.715	0.669	0.690
Wilks lambda	0.844	0.618	0.776	0.901	0.953	0.488	0.553	0.524
Chi-square	74.8	211.8	111.7	46.0	21.0	314.968	261.028	284.228
Significance	<0.001	<0.001	<0.001	<0.001	<0.001	<0.001	<0.001	<0.001
Structure matrix	1	1	1	1	1	MSL: 0.768 ML:0.420 S1W: 0.525	MSL: 0.873 ML: 0.478	MSL: 0.825 S1W: 0.564
Unstandardized Coefficient	0.201 Constant: -10.156	0.100 Constant: -9.759	0.285 Constant: -7.720	0.171 Constant: -5.554	0.112 Constant: -5.874	MSL: 0.077 ML: 0.074 S1W: 0.137 Constant: -14.984	MSL: 0.88 ML:0.98 Constant: -13.520	MSL: 0.82 S1W: 0.101 Constant: -12.424
Group centroids	Female: -0.469 Male:0.393	Female: -0.856 Male:0.718	Female: -0.586 Male:0.491	Female: -0.362 Male:0.303	Female: 0.241 Male:-0.202	Female: -1.115 Male:0.935	Female: -0.981 Male:0.822	Female: -1.038 Male:0.870

^a Variable CSWS3 was not selected in the analysis.

TABLE 3. Accuracy Rates of Direct and Stepwise Discriminant Analysis

Group			Predicted Group Membership Cross-Validated		Total
			Female	Male	
ML	%	Female	71.3	28.7	100
		Male	32.4	67.6	100
MSL	%	Female	80.2	19.8	100
		Male	19.1	80.9	100
S1W	%	Female	76.7	23.3	100
		Male	32.0	68.0	100
S3W	%	Female	70.8	29.2	100
		Male	42.7	57.3	100
SI	%	Female	56.4	43.6	100
		Male	35.7	64.3	100
Stepwise analysis (ML, MSL, S1W, S3W)	%	Female	86.1	13.9	100
		Male	16.2	83.8	100
Stepwise analysis (ML, MSL)	%	Female	81.7	18.3	100
		Male	19.5	80.5	100
Stepwise analysis (MSL, S1W, S3W)	%	Female	83.7	16.3	100
		Male	16.6	83.4	100

100.7, SW1 28.7, SW3 34.9, and SI 54.1 in males. Our study used a similar methodology and reported results similar to the study by Ramadan et al. We found that MSL had the highest accuracy (female: 80.2% and male: 80.9%) after direct discrimination analysis. Ramadan et al²¹ reported this as 71% for females and 83% for males. Although MSL measurements may vary among populations by sex many studies have reported 70% to 85% accuracies with high reliabilities.^{7,10–12,16,19–23} MSL also had the highest sensitivity and specificity (75.9% and 87.6%) using 98.7 as the cut-off value. The reliabilities of ML, S1W, S3W, and the SI were lower than that of MSL in the literature and our study.^{7,10–12,16,19–23}

The lowest accuracies were with the SI in females (56.4%) and SW3 in males (57.3%). ML, SW1, and SW3 accuracies were lower in males. Bongiovanni and Spradley⁷ emphasized the weakness of SI for sex estimation in their cut-off analysis. They found frequencies of 61% for males and 55.6% for females at a cut-off value of 50%. At a cut-off value of 51.25%, the reported frequencies were 67.39% in males and 52.78% in females. In our study, if the cut-off value for SI was accepted as 50%, 56.9% of females were above, and 71.3% of males were below, this value. At a “best” cut-off value of 51.3%, 59.7% of females were above it, and 70.1% of males below it. These results illustrate the weakness of SI for sex estimation.

Sternal morphometric investigations are also important for determining differences between populations. Population-specific studies concluded that mean sternum measurements in South African¹⁰ and Indian^{11–16} populations were lower than those of European,^{17,18,20,24,33,34} US,^{4,7} and Canadian populations. However, ethnic differences within national populations might affect the results. Studies comparing North and West

Indian populations reported larger female sternum measurements in North India and greater male sternum measurements in West India.^{11–16}

Discrimination analysis of sternal measurement parameters is a successful method for sex estimation. Previous studies used direct discrimination analysis and different combinations of analysis methods for measurement data. Maculoso and Lucena¹⁹ studied a Spanish population and reported a stepwise analysis of 5 linear dimensions (ML, corpus sterni length, manubrium width, CSWS1 (corpus sterni width at first sternebra), and CSWS3 (corpus sterni width at third sternebra)), yielded a sex classification accuracy of 89.7%. For the manubrium, both length and breadth measurements were selected in the step-wise analysis, providing a sex prediction accuracy of 87.1%. In their Western Australia study, Franklin et al²² combined the length of the manubrium, body, and corpus sterni width at the first sternebra; the accuracy of sex classification was 84.5%. Morphometric dry bone or sternum imaging studies have reported 80% to 90% accuracies with combined analyses of multiple parameters.^{7,10–12,19–23} We obtained the highest accuracy rate in the Step-wise 1 (ML, MSL, S1W, S3W) discrimination analysis; 86.1% for females and 83.8% for males, and accuracy was greater than 80% after 3 stepwise discrimination analyses for both sexes. Similar to the report by Ramadan et al²¹ we used 6 combinations. Ramadan et al²¹ reported 81.8% to 88.2% accuracies. Despite the differences between the combinations, the accuracies for Turkish populations were similar in both studies.

Direct measurement analyses can be performed on skeletal remains; however, this is not always possible.^{1,5} The increasing clinical diagnostic importance of radiological methods has resulted in an abundance of images. Technically, CT and MRI have high resolution and enable three-dimensional images to be obtained. These properties can provide detailed information for morphometric studies. In 2012, the Royal College of Radiologists reported a 26.5% increase in numbers of radiological images compared with in 2004/2005. They reported an 86% increase in use of CT and a 125% increase in MRI modalities.³⁶ We conclude that based on the increased numbers of radiology-based studies and appropriate analyses, other bones, such as the sternum, can also be used for forensic anthropologic evaluations.

TABLE 4. ROC Analysis Results for Sternal Dimensions

	ML	MSL	S1W	S3W	SI
Best cut-off value %	50.8	98.7	27.1	30.2	51.3
Se, %	65.9	75.9	67.2	76.7	59.7
Sp, %	74.2	87.6	80.6	55.9	69.8
PPV, %	75.4	88.0	80.6	67.5	70.2
NPV, %	64.0	75.3	67.4	66.9	59.2
AUC	0.737	0.888	0.796	0.714	0.665

CONCLUSIONS

A sternal morphometric analysis method provided information for sex estimation in a Turkish population. MSL had an accuracy of 80.2% in females and 80.9% in males. Step-wise 1 (ML, MSL, S1W, S3W) had high accuracy: 86.1% in females and 83.8% in males. We found smaller sternum sizes and poor reliability of SI in females, similar to previous studies. The highest sensitivity (75.9%) and specificity (87.6%) were with MSL; SI had the lowest sensitivity and specificity.

The increasing numbers of morphometric studies, especially those in different populations, provide researchers with important data. CT can be used for morphometric analyses of living subjects or found bones. If skeletal parts, such as the pelvis or skull, cannot be found or are damaged, forensic specialists, and forensic anthropologists can use the sternum for accurate sex estimation.

REFERENCES

- Krogman WM, Iscan MY. *The Human Skeleton In Forensic Medicine*. 2nd edn. Springfield, IL: Charles C. Thomas Publishing; 1986.
- Byers SN. *Introduction to Forensic Anthropology: A Textbook*. Boston: Allyn and Bacon; 2002.
- Bass WM. *Human Osteology: A Laboratory and Field Manual*. 5th edn. Columbia: Missouri Archaeological Society; 2005.
- Spradley MK, Jantz RL. Sex estimation in forensic anthropology: skull versus postcranial elements. *J Forensic Sci*. 2011;56:289–296.
- Haglund WD, Sorg MH. *Advances in Forensic Taphonomy: Method, Theory, and Archaeological Perspective*. New York: CRC Press; 2002.
- Phenice TW. A newly developed visual method of sexing the Os pubis. *Am J Phys Anthropol*. 1969;30:297–301.
- Bongiovanni R, Spradley MK. Estimating sex of the human skeleton based on metrics of the sternum. *Forensic Sci Int*. 2012;219:2901–2907.
- Wenzel J, cited by Ashley GT. A comparison of human and anthropoid mesosterna. *Am J Phys Anthropol*. 1956;14:449–465.
- Hyrtil J, cited by Dwight T. The sternum as an index of sex, height and age. *J Anat Physiol*. 1881;15:327–330.
- Macaluso PJ Jr. The efficacy of sternal measurements for sex estimation in South African blacks. *Forensic Sci Int*. 2010;202:111.e1–111.e7.
- Hunnargi SA, Menezes RG, Kanchan T, et al. Sexual dimorphism of the human sternum in a Maharashtrian population of India: a morphometric analysis. *Leg Med*. 2008;10:6–10.
- Mukhopadhyay PP. Determination of sex from adult sternum by discriminant function analysis on autopsy sample of Indian Bengali population: a new approach. *J Indian Acad Forensic Med*. 2010;34:321–324.
- Singh J, Pathak RK, Singh D. Morphometric sex determination from various sternal widths of Northwest Indian sternums collected from autopsy cadavers: a comparison of sexing methods. *Egypt J Forensic Sci*. 2012;doi:10.1016/j.ejfs.2011.12.002.
- Singh J, Pathak RK. Morphometric sexual dimorphism of human sternum in a north Indian autopsy sample: sexing efficacy of different statistical techniques and a comparison with other sexing methods. *Forensic Sci Int*. 2013;228:174.e1–174.e10. doi:10.1016/j.forsciint.2013.03.020.
- Menezes RG, Kanchan T, Kumar GP, et al. Stature estimation from the length of the sternum in South Indian males: a preliminary study. *J Forensic Leg Med*. 2009;16:441–443.
- Dahiphale VP, Baheete BH, Kamkhedkar SG. Sexing the human sternum in Marathwada Region. *J Anat Soc India*. 2002;51:162–167.
- Fernández ED, Sáez AS, Moro JI. Anthropological determination of sex by studying the sternum. *Rev Esc de Med Leg*. 2007;6:27–42.
- Marinho L, Almeida D, Santos A, Cardoso HFV. Is the length of the sternum reliable for estimating adult stature? A pilot study using fresh sterna and a test of two methods using dry sterna. *J Forensic Sci*. 2012;220:292e1–292e4.
- Macaluso PJ Jr, Lucena J. Estimation of sex from sternal dimensions derived from chest plate radiographs in contemporary spaniards. *Int J Legal Med*. 2013;128:389–395. doi:10.1007/s00414-013-0910-z.
- Torwalt CRMM, Hoppa RD. A test of sex determination from measurements of chest radiographs. *J Forensic Sci*. 2005;50:785–790.
- Ramadan SU, Türkmen N, Dolgun NA, et al. Sex determination from measurements of the sternum and fourth rib using multislice computed tomography of the chest. *Forensic Sci Int*. 2010;197:120e1–120e5.
- Franklin D, Flavel A, Kuliukas A, et al. Estimation of sex from sternal measurements in a Western Australian population. *Forensic Sci Int*. 2012;217:230.e1–230.e5.
- Franklin D, Cardini A, Flavel A, Kuliukas A. The application of traditional and geometric morphometric analyses for forensic quantification of sexual dimorphism: preliminary investigations in a Western Australian population. *Int J Legal Med*. 2012;126:549–558.
- Osunwoke EA, Gwunireama IU, Orish CN, et al. A study of sexual dimorphism of the human sternum in the southern Nigerian population. *J Appl Biosci*. 2010;26:1636–1639.
- Sutherland L, Suchey J. Use of the ventral arc in pubic sex determination. *J Forensic Sci*. 1991;36:501–511.
- Ekizoglu O, Ince E, Hocaoglu E, et al. The use of maxillary sinus dimensions in gender determination: a thin-slice multidetector computed tomography assisted morphometric study. *J Craniofac Surg*. 2014;25:957–960.
- Cameriere R, Ferrante L, Mirtella D, et al. Frontal sinuses for identification: quality of classifications, possible error and potential corrections. *J Forensic Sci*. 2005;50:1–4.
- Emirzeoglu M, Sahin B, Bilgic S, et al. Volumetric evaluation of the paranasal sinuses in normal subjects using computer tomography images: a stereological study. *Auris Nasus Larynx*. 2007;34:191–195.
- Fernandes CL. Forensic ethnic identification of crania. The role of the maxillary sinus—a new approach. *Am J Forensic Med Pathol*. 2004;25:302–313.
- Deshmukh AG, Deversh DB. Comparison of cranial sex determination by univariate and multivariate analysis. *J Anat Soc India*. 2006;55:1.
- Morgan O. *Management of Dead Bodies After Disasters: A Field Manual for First Responders*. Washington, DC: PAHO; 2006.
- Sidler M, Jackowski C, Dirnhofer R, et al. Use of multislice computed tomography in disaster victim identification—advantages and limitations. *Forensic Sci Int*. 2007;169:118–128.
- Ashley GT. The human sternum: the influence of sex and age on its measurements. *J Forensic Med*. 1956;3:27–43.
- Teige K. Morphometric studies of X-rays of the sternum, *Zeitschrift für Rechtsmedizin*. *J Legal Med*. 1983;90:199–204.
- Mall G, Sprinzl G, Koebeke J. Clinical morphology of the sternum. *Biomed Technol (Berlin)*. 1991;36:288–289.
- The Royal College of Radiologists. Investing in the clinical radiology workforce—The quality and efficiency case, 2012. Accessed date: April 11, 2014 https://www.rcr.ac.uk/docs/radiology/pdf/RCR_CRWorkforce_June2012.pdf