

## Evaluation of Myocardial Strain by 2-Dimensional Speckle Tracking Echocardiography in Patients with Facioscapulohumeral Muscular Dystrophy

### ABSTRACT

**Background:** Facioscapulohumeral muscular dystrophy is one of the most common congenital muscle disorders. Whether facioscapulohumeral muscular dystrophy causes cardiac involvement is still controversial. Although electrocardiography and conventional echocardiography studies have been performed, there is no data on strain echocardiography in facioscapulohumeral muscular dystrophy. Our study aims to compare the myocardial strain parameters by 2-dimensional speckle tracking echocardiography in patients with facioscapulohumeral muscular dystrophy and the normal group.

**Methods:** This prospective single-center study included 35 patients with facioscapulohumeral muscular dystrophy and 54 control patients. Demographic, clinical, and laboratory parameters of both groups were compared. In addition to conventional echocardiography images, myocardial strain parameters were performed using 2-dimensional speckle tracking echocardiography.

**Results:** The median age of the study population was 25 (19-35 IQR) and 51 (57.3%) of them were male. Left ventricle-global circumferential strain was significantly lower in the facioscapulohumeral muscular dystrophy group than in the normal group [-20.3 (-22.0; -19.0) vs. -21.6 (-22.5; -20.0),  $P = .020$ ]. Two-dimensional speckle tracking echocardiography findings except left ventricle-global circumferential strain [for left ventricle-global longitudinal strain  $P = .259$ , for left ventricle-global radial strain  $P = .338$ , for right ventricle-global circumferential strain  $P = .250$ , and for right ventricle-free wall longitudinal strain  $P = .288$ ] were similar in both groups.

**Conclusions:** As a result of our study, there was no significant difference between 2-dimensional speckle tracking echocardiography parameters other than the left ventricle-global circumferential strain between facioscapulohumeral muscular dystrophy and normal groups.

**Keywords:** Cardiac involvement, echocardiography, imaging, FSHD, strain

### INTRODUCTION

Facioscapulohumeral muscular dystrophy (FSHD) (also known as Landouzy and Dejerine syndrome) is the third most common type of muscular dystrophy which occurs with a frequency of 4-12/100 000, after Duchenne muscular dystrophy and Myotonic Dystrophy.<sup>1</sup> This disease is inherited autosomal dominant. It follows with slowly progressive weakness of the face, scapular, shoulder, leg, and hip girdle muscles. The onset of the disease is usually in the second decade, in the form of weakness in the facial muscles. After shoulder involvement, it progresses with the involvement of the abdominal and leg muscles. The severity and clinic of the disease are variable, it does not affect life expectancy.<sup>2,3</sup> Clinical findings, electromyography (EMG), muscle biopsies, histological and electrophysiological studies, and molecular genetic methods are used for diagnosis.<sup>4</sup> The genetic anomaly is localized to 4q35, and the molecular diagnosis is based on the detection of deletion at the D4Z4 locus.<sup>2</sup>

Although the association of congenital muscle disorders with cardiomyopathy or cardiac anomalies is well known, cardiac involvement in FSHD is random and it has been shown in a limited number of studies. The majority of these studies include

### ORIGINAL INVESTIGATION

Ferhat Işık<sup>ID</sup><sup>1</sup>

Abdurrahman Akyüz<sup>ID</sup><sup>1</sup>

Murat Çap<sup>ID</sup><sup>1</sup>

Askeri Türken<sup>ID</sup><sup>2</sup>

Süleyman Varsak<sup>ID</sup><sup>3</sup>

Erkan Baysal<sup>ID</sup><sup>1</sup>

<sup>1</sup>Department of Cardiology, Gazi Yaşargil Training and Research Hospital, Diyarbakir, Turkey

<sup>2</sup>Department of Physical Therapy and Rehabilitation, Gazi Yaşargil Training and Research Hospital, Diyarbakir, Turkey

<sup>3</sup>Bingöl University Health Services Vocational School, Bingöl, Turkey

#### Corresponding author:

Ferhat Işık

✉ frht\_0316@hotmail.com

Received: August 23, 2021

Accepted: February 7, 2022

Available Online Date: May 13, 2022

**Cite this article as:** Işık F, Akyüz A, Çap M, Türken A, Varsak S, Baysal E. Evaluation of myocardial strain by 2-dimensional speckle tracking echocardiography in patients with facioscapulohumeral muscular dystrophy. *Anatol J Cardiol.* 2022;26(7):525-531.

DOI:10.5152/AnatolJCardiol.2022.907



Copyright@Author(s) - Available online at anatoljcardiol.com.

Content of this journal is licensed under a Creative Commons Attribution-NonCommercial 4.0 International License.

electrocardiographic parameters and conventional echocardiographic measurements.<sup>5</sup> Our study aims to compare myocardial strain measurements by 2-dimensional speckle tracking strain echocardiography (2D-STE) which has been performed not yet, between patients with FSHD and the normal population.

## METHODS

### Study Population

In our study, 35 FSHD patients who were diagnosed with physical examination, family history, EMG, and genetic screening method and followed up in the Physical Medicine and Rehabilitation Department outpatient of our hospital were enrolled between July 2019 and December 2019. Fifty-four patients who were in the same age group and admitted to the cardiology outpatient clinic as a control group were included in the study. Clinical, laboratory, electrocardiographic, and echocardiographic parameters of all patients were evaluated. Patients with atrial fibrillation and pacemaker rhythm were excluded. Laboratory parameters were obtained from the electronic records of our hospital. Informed consent was obtained from all participants. The ethics committee approval required for our study was obtained from the Ethics Committee commission of our hospital (decision date: 04.07.2019, decision no: 320).

### Echocardiographic Assessment

Vivid S70 systems (GE Healthcare, Horton, Norway) were used to obtain all echocardiographic images, which were then moved to the EchoPAC workstation. Three consecutive heart cycles were taken and images were acquired at a frame rate of 60-80 frames/s. Conventional apical 4-chamber, apical 2-chamber, parasternal long-axis, and parasternal short-axis images were obtained for cardiac cavity measurements, wall thickness, and systolic and diastolic parameters. Biplane left ventricular ejection fraction (LVEF) was measured using the modified Simpson method. Strain analysis by 2D-STE was performed by 2 independent of each other experienced cardiologists according to the guidelines from 2D grayscale images recorded using EchoPAC software.<sup>6</sup> Analyses were performed for 3 apical (LV 4-chamber, 2-chamber, and 3-chamber views) and 3 short-axis views (LV basal, mid, and apical views). The program tracked the LV myocardium's boundaries automatically, with manual adjustments made as required. The program measured the strain values

in each view after manual adjustments. Aortic valve closure in the apical long-axis view was defined as end systole. After processing all 3 apical views, a 17-segment bull's-eye view was created. Left ventricular global longitudinal strain-transmural, endocardial, and epicardial measurements (LVGLS-trans, LVGLS-endo, and LVGLS-epi, respectively) were automatically calculated by the EchoPAC software. The average strain values for global circumferential strain (GCS) and global radial strain (GRS) were determined using apical, mid-ventricular, and basal short-axis parasternal views. Right ventricular-global longitudinal strain (RV-GLS) and right ventricular-free wall longitudinal (RV-FWLS) strain measurements were made from the apical 4-chamber view. Two sample 2D-STE images of the patient and normal group are given in Figure 1A and Figure 1B.

### Statistical Analysis

The analysis of the data was carried out using SPSS (Statistical Package for Social Science for Windows)-24 packaged software. The continuous variables were presented as a median interquartile range (IQR) (25-75%) owing to their non-normal distribution. The histogram and Shapiro-Wilks test were used to verify the normal distribution of data. The categorical variables were expressed as percentages. The Chi-square test was used to compare categorical variables between groups. Continuous variables were compared by the Mann-Whitney U-test. Intraobserver and interobserver reproducibility were assessed using the intraclass correlation coefficient (ICC). For intra- and interobserver agreement, coefficients of variation (CoV) were calculated by dividing the standard deviation of the differences by the mean. Also, ICC was assessed using a model of absolute agreement. There was an excellent agreement when  $ICC > 0.74$ , good when  $ICC = 0.60-0.74$ , fair when  $ICC = 0.40-0.59$ , and poor when  $ICC < 0.4$ .<sup>7</sup> The statistical significance level of the obtained data was interpreted with the "P" value. Values of  $P < .05$  were considered to be statistically significant.

## RESULTS

Eighty-nine patients were included in the study. The median age of the study population was 25 (19-35 IQR), and 51 (57.3%) of the patients were male. The study population was divided into FSHD ( $n=35$ ) and the normal group ( $n=54$ ). Aspartate transaminase ( $P < .001$ ), alanine transaminase ( $P < .001$ ), and creatinine kinase ( $P < .001$ ) were significantly higher in the FSHD group. Body mass index ( $P=.003$ ), body surface area ( $P=.009$ ), lymphocyte count ( $P=.017$ ), and creatinine ( $P < .001$ ) were significantly higher in the normal group. Demographic, laboratory, and clinical features of the 2 groups are presented comparatively in Table 1.

In electrocardiographic findings, branch blocks [all in right bundle branch block (RBBB) morphology] were higher in the FSHD group ( $P=.017$ ), corrected QT was higher in the normal group ( $P=.001$ ). In conventional echocardiography findings, LV diastolic diameter ( $P=.020$ ), LV systolic diameter ( $P=.002$ ), and RV end diastolic area ( $P=.033$ ) were significantly higher in the normal group. In tissue doppler images, early and late diastolic velocities in the left ventricular lateral wall (for e wave;  $P < .001$ , for a wave;  $P = .040$ ) and ventricular septum (for e

## HIGHLIGHTS

- Facioscapulohumeral muscular dystrophy is a common congenital muscle disease.
- Myocardial strain imaging provides more accurate results than conventional echocardiographic methods in evaluating myocardial functions.
- There is no study on myocardial strain imaging in patients with facioscapulohumeral muscular dystrophy.
- Left ventricular-global circumferential strain is lower in patients with facioscapulohumeral muscular dystrophy.

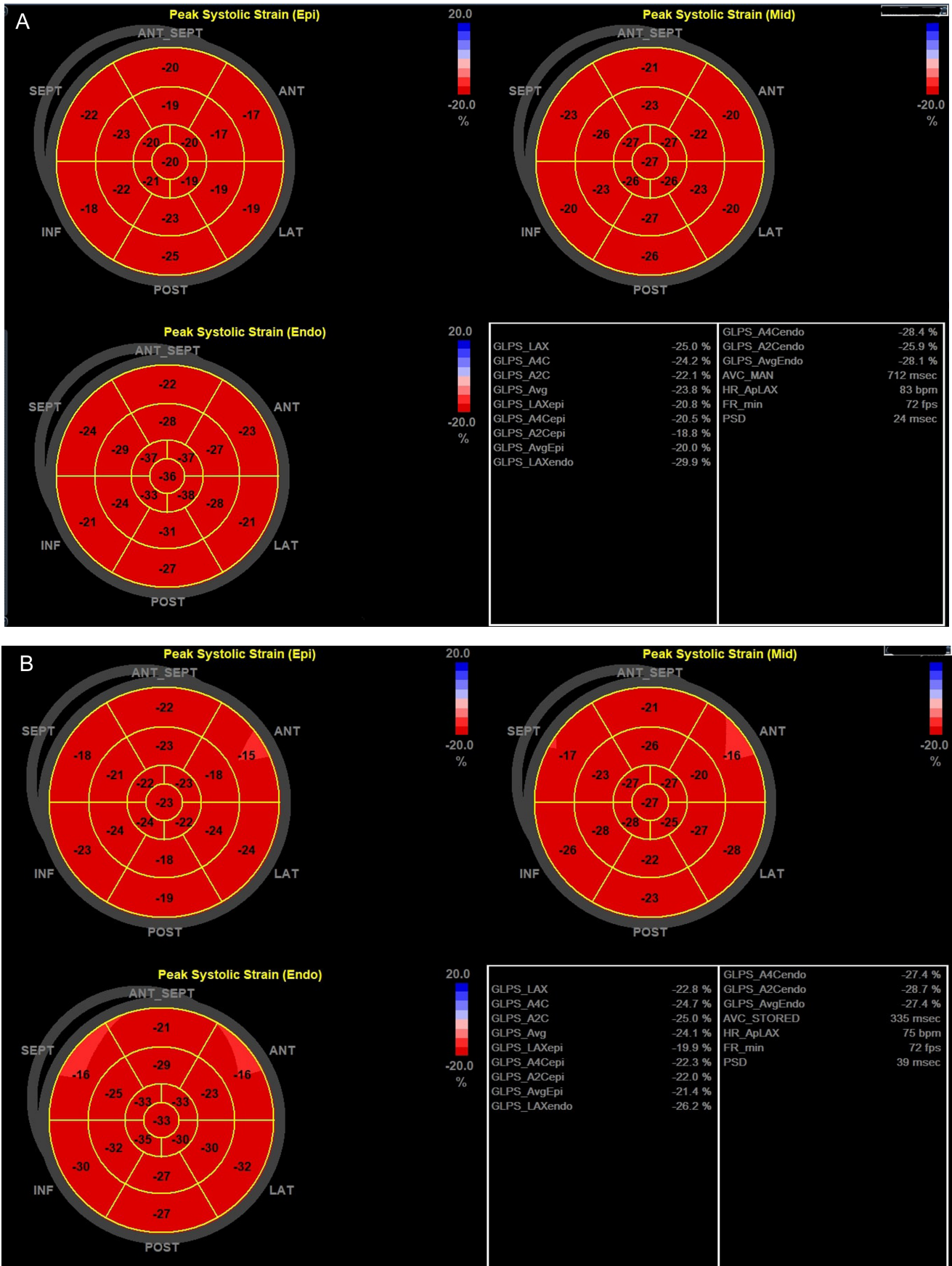


Figure 1. A sample of 2D-STE analysis of the (A) patient group and (B) normal group.

**Table 1. Demographic, Clinical, and Laboratory Parameters of the Study Population**

	Total (n = 89)	FSHD Group (n = 35)	Control Group (n = 54)	P
Age (years)	25 (19-35)	25 (18-41)	25 (19-33)	.762
Gender male, n(%)	51 (57.3)	21 (60.0)	30 (55.6)	.827
Body surface area, m <sup>2</sup>	1.72 (1.53-1.90)	1.62 (1.41-1.85)	1.79 (1.58-1.93)	.009
Body mass index, kg/m <sup>2</sup>	21.71 (19.38-25.03)	19.78 (18.35-24.46)	23.46 (21.13-25.78)	.003
Diabetes mellitus, n (%)	1	1	None	NA
Hypertension, n (%)	1	1	None	NA
Smoking, n (%)	12 (14)	3 (9)	9 (16)	.352
Coronary artery disease, n (%)	None	None	None	NA
Aspartate transaminase, IU/L	20.0 (17.0-25.0)	23.0 (19.0-29.5)	18 (15.7-22.2)	<.001
Alanine transaminase, IU/L	16.0 (13.0-27.0)	22.0 (16.0-31.5)	14.0 (11.0-24.2)	<.001
Sodium, meq/L	139 (138-141)	139 (138-141)	140 (139-140)	.996
Potassium, meq/L	4.2 (4.0-4.5)	4.1 (3.8-4.4)	4.3 (4.1-4.5)	.102
Creatinine, mg/dL	0.69 (0.60-0.82)	0.65 (0.57-0.70)	0.80 (0.66-0.92)	<.001
Creatin kinase U/L	126 (91-247)	252 (155-452)	107 (76-127)	<.001
Hemoglobin, gr/dL	14.4 (13.0-15.9)	14.5 (13.6-16.1)	14.0 (12.8-15.9)	.309
White blood cell, 10 <sup>9</sup> /L	7.50 (6.23-9.29)	7.65 (6.51-9.31)	7.25 (6.22-9.33)	.844

Continuous variables are presented given as median (interquartile range), and categorical variables were expressed as numbers (%). NA, not applicable.

wave;  $P = .009$ , for a wave;  $P = .026$ ) were significantly lower in the FSHD group. In strain echocardiography findings, LV-GCS was significantly higher in the normal group [ $-21.6$  ( $-22.5$ ;  $-20.0$ ) vs.  $-20.3$  ( $-22.0$ ;  $-19.0$ ),  $P = .020$ ]. Strain findings except for LV-GCS were similar in both groups. The electrocardiographic and echocardiographic findings of the 2 groups are presented in Table 2. Intra- and interobserver variability of LV myocardial strain parameters and ejection fraction (EF) are given in Table 3.

## DISCUSSION

Data on cardiac involvement in FSHD is limited. In our study, the presence of cardiac involvement in patients with FSHD was investigated by 2D-STE. To the best of our knowledge, this is the first study in which strain echocardiographic imaging was performed in patients with FSHD. As a result of our study, LV-GCS decreased in patients with FSHD compared to the normal population. Other 2D-STE parameters were similar between both groups.

FSHD is a common type of congenital muscle disease. There are 2 subgroups FSHD-1 and FSHD-2. The disease is seen as 95% FSHD-1.<sup>8,9</sup> FSHD progresses with age and abdominal and leg muscle involvement occurs after upper extremity involvement. Patients with FSHD do not generally suffer from major cardiac symptoms,<sup>10</sup> but the heterogeneous clinical findings reported to date have shown that heart alterations may be associated with the disease.<sup>11</sup> Shortly, there is no clarity about cardiac involvement. Myocardial strain calculated by STE is an advanced echocardiographic technique that allows measurement of myocardial deformation using a semi-automatic software initially developed for application to the LV and then used for the assessment of all cardiac chambers. STE provides additional information about cardiac function by

an angle-independent segmental measurement of myocardial fibers' movement throughout the cardiac cycle. It achieved early diagnosis of subclinical myocardial impairment even when conventional measurements such as LVEF were normal.<sup>12-14</sup> Previously, clinical studies have been conducted with ECG and basic echocardiographic images related to FSHD, but there are no advanced echocardiographic imaging studies. In a study, it was found that only 5 out of 100 patients had major arrhythmic events in electrocardiographic examination in patients with FSHD (severe atrioventricular block, ventricular tachycardia, etc.). Other patients were observed with minor anomalies (e.g., such as incomplete RBBB, sinus bradycardia, short PR interval) or normal electrocardiographic findings. Annual ECG follow-up is recommended for patients.<sup>15</sup> In another study, 56 patients diagnosed with FSHD were followed for an average of 7.2 years. Significant cardiac involvement was not observed in these patients, while the most common minor cardiac anomaly was incomplete RBBB (25%). Only 3 patients, 1 or more significant cardiac events (heart failure and/or atrial fibrillation) were observed.<sup>16</sup> In our study, the most common ECG anomaly was RBBB, and it was more common in the FSHD group.

In a study, 8-year electrocardiographic and echocardiographic follow-up of patients with FSHD was performed. In the echocardiographic examination, basic parameters such as ventricular diameters, ventricular functions, valve structures, wall movements, and wall thickness were examined. Echocardiographic abnormalities were not observed in the follow-up of the patients. It was stated that patients with FSHD and who do not have cardiac complaints do not need specific cardiac screening or follow-up.<sup>5</sup> Galetta et al<sup>17</sup> compared patients with FSHD and the healthy group according to echocardiographic findings. Tissue doppler-imaging systolic and early diastolic velocities of both the ventricular

**Table 2. Electrocardiographic and Echocardiographic Findings of the Study Population**

	Total (n = 89)	FSHD Group (n = 35)	Control Group (n = 54)	P
Heart rate, beat/min	87 (77-92)	87 (80-93)	86 (76-92)	.751
QRS duration, ms	88.5 (82.0-96.0)	85.5 (76.2-96.0)	89.5 (84.0-95.7)	.165
QT duration, ms	345 (325-360)	341 (316-359)	349 (331-366)	.220
Corrected QT duration, ms	401 (382-423)	389 (373-406)	417 (396-428)	.001
Fragmented QRS, n (%)	6 (6.7)	3 (8.5)	3 (5.6)	.634
Branch blocks, n (%)	9 (10.1)	7 (20.0)	2 (3.7)	.017
LV diastolic diameter, mm	4.5 (4.2-4.7)	4.4 (4.2-4.6)	4.6 (4.3-4.8)	.020
LV systolic diameter, mm	2.7 (2.4-2.9)	2.6 (2.3-2.7)	2.7 (2.6-2.9)	.002
Septum thickness, mm	9 (8-10)	9 (8-11)	9 (8-10)	.770
LV posterior wall thickness, mm	9 (8-10)	9 (8-10)	9 (8-10)	.616
LV diastolic volume index, mL/m <sup>2</sup>	56.44 (50.12-61.42)	55.73 (44.63-59.71)	56.97 (52.27-61.83)	.078
LV systolic volume index, mL/m <sup>2</sup>	19.84 (18.06-22.03)	19.77 (17.21-21.91)	19.85 (18.55-22.28)	.483
Biplane ejection fraction, %	64.0 (63.0-66.0)	64.0 (63.0-66.0)	64.0 (62.8-66.0)	.813
Mitral E wave, cm/s	0.90 (0.79-0.98)	0.83 (0.73-0.95)	0.91 (0.83-1.03)	.014
Mitral A wave, cm/s	0.66 (0.56-0.80)	0.63 (0.54-0.71)	0.68 (0.58-0.83)	.058
Lateral e wave, cm/s	18.0 (14.0-21.0)	16.0 (12.0-19.0)	19.0 (16.0-22.0)	<.001
Lateral a wave, cm/s	10.0 (8.0-11.0)	10.0 (8.0-11.0)	10.0 (9.0-12.0)	.040
Lateral Sm, cm/s	9.0 (8.0-11.0)	9.0 (8.0-13.0)	9.5 (8.0-11.0)	.879
Septal e wave, cm/s	14.0 (12.0-16.5)	13.0 (10.0-16.0)	15.0 (13.0-17.0)	.009
Septal a wave, cm/s	9.0 (8.0-11.0)	8.0 (7.0-10.0)	9.0 (9.0-11.0)	.026
Septal Sm, cm/s	9.0 (8.0-10.0)	8.0 (8.0-10.0)	9.0 (8.8-10.0)	.052
Apical 4 chamber LS, %	-19.7[(-21.1)-(-18.3)]	-19.9[(-21.6)-(-17.6)]	-19.7[(-21.1)-(-18.6)]	.605
Apical 2 chamber LS, %	-20.1[(-22.1)-(-18.9)]	-19.9[(-21.8)-(-18.2)]	-20.4[(-22.2)-(-19.4)]	.305
Apical 3 chamber LS, %	-19.8[(-21.7)-(-18.5)]	-19.2[(-20.6)-(-18.2)]	-19.9[(-21.8)-(-18.7)]	.150
LV-GLS, %	-20.0[(-21.2)-(-18.9)]	-19.8[(-21.2)-(-18.4)]	-20.1[(-21.5)-(-19.0)]	.259
LV GLS-endocardium, %	-23.1[(-24.7)-(-21.7)]	-22.8[(-24.8)-(-20.8)]	-23.2[(-24.6)-(-21.8)]	.364
LV GLS-epicardium, %	-17.5[(-18.9)-(-16.5)]	-17.1[(-18.3)-(-15.4)]	-17.8[(-19.2)-(-16.7)]	.104
LV-GCS, %	-21.1[(-22.4)-(-19.6)]	-20.3[(-22.0)-(-19.0)]	-21.6[(-22.5)-(-20.0)]	.020
LV-GRS, %	43.6 (38.3-47.8)	42.3 (38.3-47.3)	45.3 (38.8-48.6)	.338
RV EDA, cm <sup>2</sup>	15.9 (13.9-19.2)	15.1 (13.6-18.2)	16.8 (15.5-19.9)	.033
RV ESA, cm <sup>2</sup>	8.8 (7.5-10.2)	8.1 (7.5-10.2)	9.1 (7.7-10.8)	.208
RV FAC, %	45.8 (42.0-48.3)	44.5 (41.1-46.6)	46.5 (42.2-49.1)	.055
TAPSE, mm	22 (20-24)	22 (19-25)	22 (21-23)	.446
RV-GLS total, %	-23.5[(-25.7)-(-20.9)]	-22.7[(-27.1)-(-19.4)]	-23.7[(-25.4)-(-21.7)]	.250
RV free wall longitudinal strain, %	-28.0[(-31.1)-(-24.0)]	-26.2[(-32.0)-(-22.4)]	-28.2[(-30.0)-(-25.9)]	.288

Continuous variables are presented given as median (interquartile range), and categorical variables were expressed as numbers (%). EDA, end diastolic area; ESA, end systolic area; FAC, fractional area change; GCS, global circumferential strain; GLS, Global longitudinal strain; GRS, global radial strain; LS, layer strain; LV, left ventricle; RV, right ventricle; Sm, peak systolic velocity at myocardial segments; TAPSE, tricuspid annular plane systolic excursion.

septum and the LV lateral wall were found lower in patients with FSHD. Integrated backscatter (IBS) analysis of the ventricular septum and LV posterior wall was found lower in the FSHD group. Heart diameters measured by M-mod were similar.<sup>17</sup> In our study, early and late diastolic velocities of the LV lateral wall and ventricular septum in the FSHD group were found lower in tissue doppler records. Systolic velocities were found similar. Also, heart diameters were lower in the FSHD group. In a magnetic resonance imaging study by Blaszczyk et al<sup>18</sup> patients with FSHD whose preserved EF were compared with the normal patient group. Focal and diffuse subclinical myocardial injury was more common in cardiac

magnetic resonance imaging (CMRI) in the FSHD group. The 3 most frequent locations were the basal segments (inferolateral, inferior, and interventricular septum). The pattern of the fibrosis was nonischemic and mostly located intramural and subepicardial.<sup>18</sup> The circumferential plane is the major axis of systolic motion in the left ventricle and, as such, has been used by several investigators as a primary strain to use as an index.<sup>19</sup> In a study, left ventricular myocardial peak circumferential strain (LVMPCS) was evaluated using CMRI in patients with Duchenne muscular dystrophy (DMD). It has been emphasized that LVMPCS is reduced in DMD before global systolic functional abnormalities, regardless of age

**Table 3. Intraobserver and Interobserver Agreement**

	Intraobserver CoV(%)	Intraobserver Agreement (ICC, 95% CI)	Interobserver CoV(%)	Interobserver Agreement (ICC, 95% CI)
LV-GLS	10.3	0.87 (0.81-0.92)	9.9	0.73 (0.57-0.83)
LV-GCS	8.7	0.82 (0.73-0.88)	8.4	0.78 (0.61-0.87)
LV-GRS	12.7	0.76 (0.63-0.84)	12.9	0.69 (0.52-0.79)
EF	4.5	0.91 (0.86-0.95)	4.3	0.89 (0.81-0.93)

CI, Confidence interval; CoV, coefficient of variation; EF, ejection fraction; GCS, global circumferential strain; GLS, global longitudinal strain; GRS, global radial strain; ICC, intraclass correlation coefficients; LS, layer strain; LV, left ventricle.

or EF. The study stated that this decrease may continue with aging. Also, the study considers that the loss of cell membrane integrity leads to degeneration of myocytes, as a result of which myocyte necrosis and fibrosis play a role in the reduction of strain.<sup>20</sup> Another CMRI study revealed that LVMPCS changes may indicate disease progression in a short period of time in DMD patients in which EF changes are not significant. In addition, serial LVMPCS measurements are more sensitive than EF and can provide reliable monitoring of the progression of DMD-related cardiac dysfunction before overt heart failure develops.<sup>19</sup> In the study of Siegel et al<sup>21</sup> LV-GLS and LV-GCS were evaluated by CMRI in DMD patients. The average circumferential strain was significantly decreased in DMD compared to controls ( $-18.8 \pm 6.1$  vs.  $-25.5 \pm 3.2$ ;  $P < .001$ ) but there were no significant differences in longitudinal strain measures.<sup>21</sup> Under all these data, we have focused on the assessment of LV-GCS in 2D-STE.

Unfortunately, satisfactory data on cardiac involvement in FSHD patients are not available. Many studies have been conducted on these patients whose results are inconsistent with each other. Although data on cardiac involvement are known in a few traditional echocardiographic studies, there are no studies involving more complex echocardiographic data such as 2D-STE. In our study, strain echo findings were almost similar between the patient group and the normal group. Only LV-GCS was lower in the FSHD group. Besides, finding the circumferential strain is reduced while longitudinal is not, is consistent with CMRI findings that show a pattern of nonischemic fibrosis. However, we cannot fully say whether these are a coincidence or not. LV-GCS may be the first impaired myocardial strain parameter in FSHD patients. Therefore, serial measurements are needed to see the change in myocardial strain parameters in FSHD patients. Long-term studies to evaluate cardiac involvement in these patients may provide insight in the future.

### Study Limitations

There are certain limitations to our study. This study is a single-center cross-sectional and the sample size of the matched groups is relatively small. In some of our patient populations, there was no genetic confirmation of diagnoses. Studies with patients with larger sample sizes and confirmed genetic diagnoses may lead to different results. Although echocardiography analyses were performed by 2 different cardiologists, LV-GCS and LV-GRS measurements may be suboptimal, as parasternal short-axis views are insufficient in some FSHD patients due to chest deformity.

### CONCLUSIONS

There is no consistent data on cardiac involvement in patients with FSHD. In this imaging study, myocardial strain parameters were evaluated for the first time in FSHD patients. In conclusion only LV-GCS was significantly less in 2D-STE decreased in FSHD patients. There was no significant difference between the 2 groups in terms of other strain parameters.

**Ethics Committee Approval:** Ethical committee approval was received from the Ethics Committee of University of Health Sciences Gazi Yaşargil Training and Research Hospital (approval no: 320 - date: 04.07.2019).

**Informed Consent:** Written informed consent was obtained from all participants who participated in this study.

**Peer-review:** Externally peer-reviewed.

**Author Contributions:** Concept – F.I., A.A., M.Ç.; Design – F.I., A.A., M.Ç.; Supervision – E.B.; Funding – None; Materials – A.T., S.V.; Data Collection and/or Processing – F.I., A.A., M.Ç., A.T., S.V.; Analysis and/or Interpretation – F.I.; Literature Review – F.I., E.B.; Writing – F.I.; Critical Review – F.I., M.Ç.

**Acknowledgments:** None.

**Declaration of Interests:** No conflict of interest.

**Funding:** No funding.

### REFERENCES

- Richards M, Coppée F, Thomas N, Belayew A, Upadhyaya M. Facioscapulohumeral muscular dystrophy (FSHD): an enigma unravelled? *Hum Genet.* 2012;131(3):325-340. [CrossRef]
- Statland JM, Tawil R. Facioscapulohumeral muscular dystrophy. *Continuum (Minneapolis, Minn).* 2016 December;22(6):1916-1931. [CrossRef]
- Orrell RW. Facioscapulohumeral dystrophy and scapuloperoneal syndromes. *Handb Clin Neurol.* 2011;101:167-180. [CrossRef]
- Kanagawa M, Toda T. The genetic and molecular basis of muscular dystrophy: roles of cell-matrix linkage in the pathogenesis. *J Hum Genet.* 2006;51(11):915-926. [CrossRef]
- van Dijk GP, van der Kooij E, Behin A, et al. High prevalence of incomplete right bundle branch block in facioscapulohumeral muscular dystrophy without cardiac symptoms. *Funct Neurol.* 2014;29(3):159-165.
- Voigt JU, Pedrizzetti G, Lysyansky P, et al. Definitions for a common standard for 2D speckle tracking echocardiography: consensus document of the EACVI/Ase/Industry task force to standardize deformation imaging. *J Am Soc Echocardiogr.* 2015;28(2):183-193. [CrossRef]

7. Kowallick JT, Morton G, Lamata P, et al. Inter-study reproducibility of left ventricular torsion and torsion rate quantification using MR myocardial feature tracking. *J Magn Reson Imaging*. 2016;43(1):128-137. [\[CrossRef\]](#)
8. Statland JM, Tawil R. Facioscapulohumeral muscular dystrophy: molecular pathological advances and future directions. *Curr Opin Neurol*. 2011;24(5):423-428. [\[CrossRef\]](#)
9. de Greef JC, Lemmers RJ, Camaño P, et al. Clinical features of facioscapulohumeral muscular dystrophy 2. *Neurology*. 2010;75(17):1548-1554. [\[CrossRef\]](#)
10. Trevisan CP, Pastorello E, Armani M, et al. Facioscapulohumeral muscular dystrophy and occurrence of heart arrhythmia. *Eur Neurol*. 2006;56(1):1-5. [\[CrossRef\]](#)
11. Finsterer J, Stöllberger C, Meng G. Cardiac involvement in facioscapulohumeral muscular dystrophy. *Cardiology*. 2005;103(2):81-83. [\[CrossRef\]](#)
12. Mondillo S, Galderisi M, Mele D, et al. Speckle-tracking echocardiography: a new technique for assessing myocardial function. *J Ultrasound Med*. 2011;30(1):71-83. [\[CrossRef\]](#)
13. Cameli M, Mandoli GE, Sciacaluga C, Mondillo S. More than 10 years of speckle tracking echocardiography: still a novel technique or a definite tool for clinical practice? *Echocardiography*. 2019;36(5):958-970. [\[CrossRef\]](#)
14. Pastore MC, De Carli G, Mandoli GE, et al. The prognostic role of speckle tracking echocardiography in clinical practice: evidence and reference values from the literature. *Heart Fail Rev*. 2021;26(6):1371-1381. [\[CrossRef\]](#)
15. Laforêt P, de Toma C, Eymard B, et al. Cardiac involvement in genetically confirmed facioscapulohumeral muscular dystrophy. *Neurology*. 1998;51(5):1454-1456. [\[CrossRef\]](#)
16. Labombarda F, Maurice M, Simon JP, et al. Cardiac abnormalities in type 1 facioscapulohumeral muscular dystrophy. *J Clin Neuromuscul Dis*. 2017;18(4):199-206. [\[CrossRef\]](#)
17. Galetta F, Franzoni F, Sposito R, et al. Subclinical cardiac involvement in patients with facioscapulohumeral muscular dystrophy. *Neuromuscul Disord*. 2005;15(6):403-408. [\[CrossRef\]](#)
18. Blaszczyk E, Grieben U, von Knobelsdorff-Brenkenhoff F, et al. Subclinical myocardial injury in patients with facioscapulohumeral muscular dystrophy 1 and preserved ejection fraction—assessment by cardiovascular magnetic resonance. *J Cardiovasc Magn Reson*. 2019;21(1):25. [\[CrossRef\]](#)
19. Hagenbuch SC, Gottliebson WM, Wansapura J, et al. Detection of progressive cardiac dysfunction by serial evaluation of circumferential strain in patients with Duchenne muscular dystrophy. *Am J Cardiol*. 2010;105(10):1451-1455. [\[CrossRef\]](#)
20. Hor KN, Wansapura J, Markham LW, et al. Circumferential strain analysis identifies strata of cardiomyopathy in Duchenne muscular dystrophy: a cardiac magnetic resonance tagging study. *J Am Coll Cardiol*. 2009;53(14):1204-1210. [\[CrossRef\]](#)
21. Siegel B, Olivieri L, Gordish-Dressman H, Spurney CF. Myocardial strain using cardiac MR feature tracking and speckle tracking echocardiography in Duchenne muscular dystrophy patients. *Pediatr Cardiol*. 2018;39(3):478-483. [\[CrossRef\]](#)