

All-Autograft Multiligament Knee Reconstruction of the Posterior Cruciate Ligament, Anterior Cruciate Ligament, and Posterolateral Corner (KD-III)



Iftach Hetsroni, M.D., Gideon Mann, M.D., Gabriel Marino, M.D., and Nissim Ohana, M.D.

Abstract: Multiligament knee reconstruction constitutes a challenging entity. While allograft use gained popularity in this scenario because it can reduce surgery time and the risk of donor-site morbidities, in some places high-quality allografts are not readily available. In addition, allografts are subjected to some disadvantages compared with autografts, including slower biological incorporation and risk of disease transmission. Choosing and using wisely autografts to address these cases becomes valuable for these reasons. In this manuscript a technique is described for performing all-autograft multiligament knee reconstruction of the posterior cruciate ligament, anterior cruciate ligament and posterolateral corner.

Multiligament knee injuries constitute a challenging entity in terms of diagnosis and management. Despite a consensus that reconstruction of all insufficient ligaments in young and healthy adults is superior over nonoperative strategy,^{1,2} there are still a few issues that are controversial. Optimal sequence of ligament reconstruction and sequence of graft tensioning are 2 topics that require further attention. While some investigators favor tensioning and fixing the posterior cruciate ligament (PCL) first to restore the central pivot and tibial step-off,³ others favor simultaneous tensioning of both cruciate ligaments and fixing the anterior cruciate ligament (ACL) first.⁴ Graft choice for reconstructing the multiligament injured knee is another issue that deserves attention. Allograft use is appealing because it may reduce surgery time and potential donor-site morbidities, particularly in these cases that require 3 or more grafts. Nevertheless, a few

disadvantages of using allografts compared with autografts for reconstructing the knee ligaments can be mentioned, including greater financial costs,⁵ concerns of tissue quality with slower biological incorporation,⁶ disease transmission,⁷ and some evidence of greater failure rates and inferior functional outcomes in young active adults, at least for the anterior cruciate ligament.⁸ For these reasons, and particularly in areas in which high-quality nonirradiated allografts are not available, graft choice becomes a critical problem as recently pointed out.² In this manuscript, a technique is described for performing multiligament knee reconstruction of the PCL, ACL, and posterolateral corner (PLC) by using autografts only. This can be of particular value in medical facilities in which high-quality nonirradiated allograft tissue is not readily available, or in combination with allograft use according to surgeon's preference and patient factors.

Surgical Technique (Video 1)

In the operating room, and before beginning surgery, the following steps are performed:

1. The patient is placed in a supine position. A tourniquet cuff (Zimmer, Dover, OH) is placed around the proximal thigh. The tourniquet is not inflated throughout the entire surgery, which is expected to be approximately 3 to 5 hours, to decrease postoperative risks such as neuropraxia and thromboembolic events (Table 1). It is, however, placed as a safety measure to be used if graft harvest becomes difficult for the surgeon due to local bleeding or for any other reason of inadvertent bleeding. A lateral

From Department of Orthopedic Surgery, Meir General Hospital, Kfar Saba, affiliated to Sackler Faculty of Medicine, Tel Aviv University, Tel Aviv, Israel.

The authors report that they have no conflicts of interest in the authorship and publication of this article. Full ICMJE author disclosure forms are available for this article online, as [supplementary material](#).

Received January 21, 2021; accepted February 14, 2021.

Address correspondence to Iftach Hetsroni, M.D., Department of Orthopedic Surgery, Meir General Hospital, Tsharnichovski St. 59, Kfar Saba 44281, Israel. E-mail: iftachhetsroni@gmail.com

© 2021 THE AUTHORS. Published by Elsevier Inc. on behalf of the Arthroscopy Association of North America. This is an open access article under the CC BY-NC-ND license (<http://creativecommons.org/licenses/by-nc-nd/4.0/>). 2212-6287/21128

<https://doi.org/10.1016/j.eats.2021.02.027>

Table 1. Tips and Pitfalls During All Autograft Multiligament KD-III Knee Reconstruction

Tips

- A thigh tourniquet cuff is placed but not inflated throughout the surgery to decrease risks of thromboembolic disease
- Both lower limbs are prepped and draped to enable autograft harvest of both limbs
- The PCL tibial tunnel posterior aperture is located slightly lateral and distal to the central point between the medial and lateral posterior tibial spines to decrease the killer turn and achieve optimal PCL graft restraining vector
- Smoothing the edges of the posterior aperture of the PCL tibial tunnel may ease graft passage
- Care is taken to avoid tunnel convergence at the anterior ACL and PCL tibial tunnels aperture
- Autograft harvest is performed only after all graft tunnels are prepared and shuttle sutures passed and any meniscus repair performed as needed
- During quadriceps tendon–bone autograft harvest, to avoid detachment of the quadriceps tendon at the patella insertion it is important to flip the tendinous part of the graft and observe the insertion, so that intact tendon–bone junction remains during harvesting the patella bone plug.
- Before harvesting the contralateral Semitendinosus for the PLC reconstruction, the posterolateral exposure of all relevant structures including the fibular head and the FCL and popliteus femoral insertions as well as tunnel preparation in the fibular head take place
- A backup cortical fixation for the cruciate grafts on the anteromedial tibial cortex distally to the apertures of the tibial tunnels is recommended

Pitfalls

- Placing the drill guide pin for the PCL tibial tunnel aperture at the back slightly medial or proximal to the central point between the medial and lateral posterior tibial spines may result in a killer turn and suboptimal PCL graft restraining vector. Location of this crucial guide pin should therefore be verified without compromises before reaming the PCL tibial tunnel
- ACL and PCL tibial tunnels anterior aperture convergence should be avoided
- Detachment of the Quadriceps tendinous part from the patella bone plug during harvest may result from misinterpreting the gross anatomy at this junctional area

ACL, anterior cruciate ligament; FCL, fibular collateral ligament; MRI, magnetic resonance imaging; PCL, posterior cruciate ligament; PLC, posterolateral corner.

thigh-post (Maquet, Rastatt, Germany) and a 3-liter arthroscopic irrigation bag strapped distally onto the operating table and used as a foot bolster enable positioning and supporting the knee at 90° flexion as well as mobilizing it freely from flexion towards extension during the operation as needed.

2. The knee is examined under anesthesia with emphasis on range of motion and ligament laxity, including ACL, PCL, medial collateral ligament, fibular collateral ligament (FCL), and corners. In this case, positive findings of the left knee included grade 3+ Lachman, grade 2+ pivot shift, grade 3+ anterior drawer, and grade 3+ posterior drawer tests, high-grade varus laxity, and a positive posterolateral drawer test without hyperextension deformity.

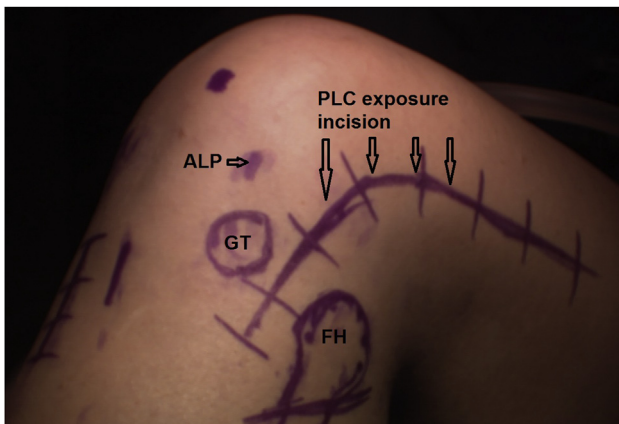


Fig 1. This is the left knee. Patient is in the supine position. All relevant skin markings on the lateral side are drawn, including anterolateral portal (ALP), Gerdy tubercle (GT), fibular head (FH), and a lateral hockey stick incision for exposing and reconstructing the posterolateral corner (PLC).

3. Both lower limbs are then prepped and draped to be able to harvest autologous ligaments from both limbs during surgery (Table 1).

Surgical steps for ACL-PCL-FCL and PLC reconstructions are then performed as follows:

1. All relevant skin markings on the lateral side are drawn, including anterolateral portal, Gerdy

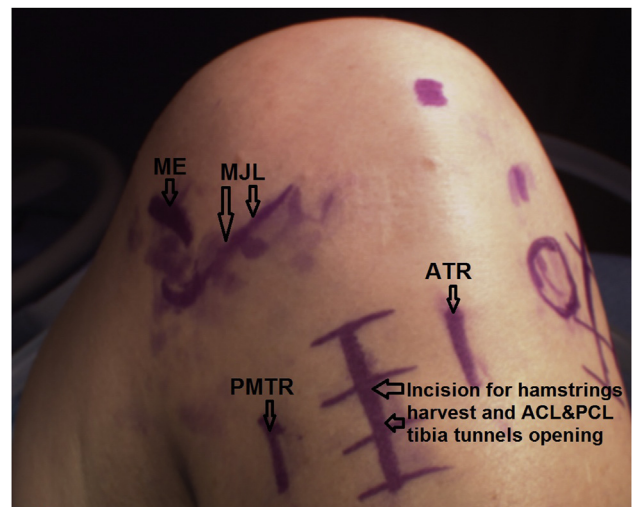


Fig 2. This is the left knee. Patient is in the supine position. All relevant skin markings on the medial side are drawn, including medial joint line (MJL) and medial epicondyle area (ME) as well as posteromedial tibial ridge (PMTR) for possible medial-sided procedures if needed such as meniscus inside-out repair, anteromedial incision marking for hamstrings harvest and tibia tunnels openings of the anterior cruciate ligament and posterior cruciate ligament, and anterior tibial ridge (ATR).

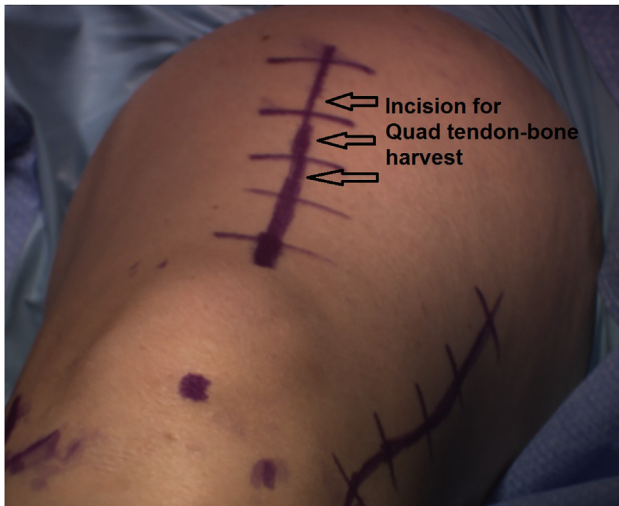

Fig 3. This is the left knee. Patient is in the supine position. Skin marking for quadriceps tendon harvest is drawn

tubercle, fibular head, and a lateral hockey stick incision for exposing and reconstructing the PLC (Fig 1).

2. All relevant skin markings on the medial side are drawn, including medial joint line and medial epicondyle area as well as posteromedial tibial ridge for possible medial-sided procedures if needed such as meniscus inside-out repair, anteromedial incision marking for hamstrings harvest and tibia tunnels openings of the ACL and PCL, and anterior tibial ridge (Fig 2).
3. Skin marking for quadriceps tendon harvest is drawn (Fig 3).
4. Systematic arthroscopic evaluation of all knee compartments is performed with a 30° arthroscope (Olympus Inc., Center Valley, PA) using standard anterolateral and anteromedial portals. ACL and PCL probing confirmed in this case high-grade tears of both cruciate ligaments (Fig 4).

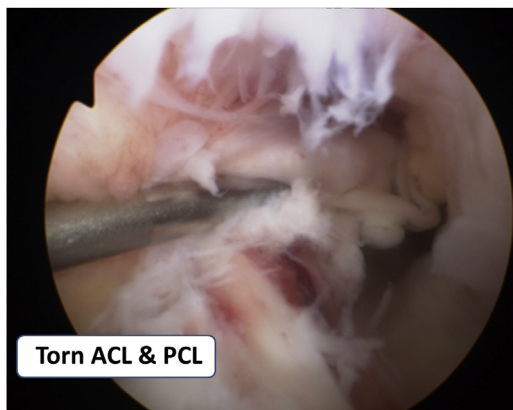


Fig 4. Patient is in the supine position. A 30° arthroscope (Olympus Inc., Center Valley, PA) through the anterolateral portal shows anterior cruciate ligament (ACL) and posterior cruciate ligament (PCL) high-grade tears in a left knee.

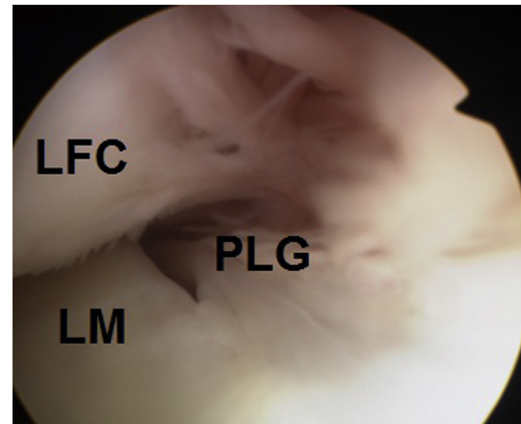


Fig 5. Patient is in the supine position. A 30° arthroscope (Olympus Inc., Center Valley, PA) through the anterolateral portal of a left knee shows the posterolateral gutter (PLG) with torn popliteus tendon fibers. (LFC, lateral femoral condyle; LM, lateral meniscus.)

5. The posterolateral gutter is inspected and reveals scarring tissue and torn fibers of the popliteus tendon (Fig 5).
6. The lateral compartment tibiofemoral gapping under varus stress is then evaluated and shows high-grade instability (Fig 6).
7. In the case presented in [Video 1](#), a lateral drive-through sign confirms high-grade laxity of the PLC restraints.
8. After torn ACL tissue is debrided using a 5.0-mm full-radius resector shaver (Stryker, San Jose, CA), a femoral socket is prepared for the ACL graft. For this purpose, preoperative magnetic resonance imaging (MRI), axial cut, is used for measuring the cross-sectional area of the semitendinosus and gracilis tendons at the level of the medial femoral

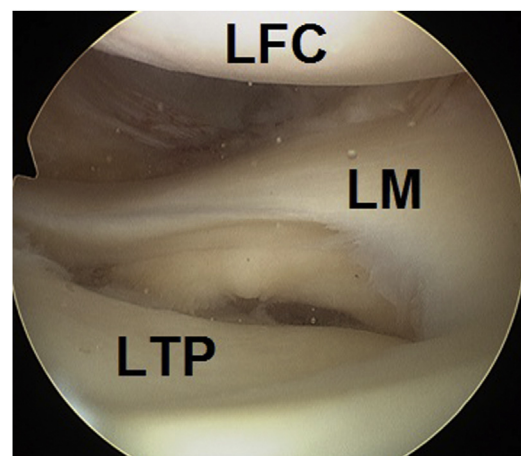


Fig 6. Patient is in the supine position. A 30° arthroscope (Olympus Inc., Center Valley, PA) through the anterolateral portal of a left knee shows high-grade lateral compartment tibiofemoral gapping. (LFC, lateral femoral condyle; LM, lateral meniscus; LTP, lateral tibial plateau.)

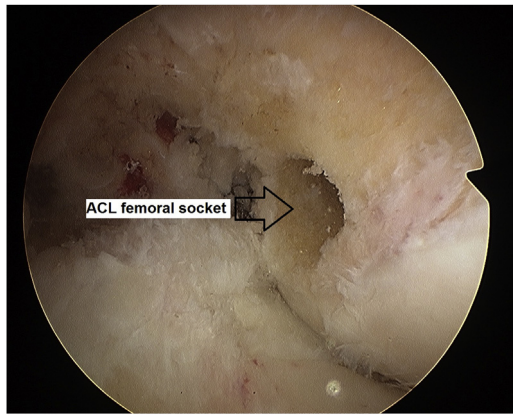


Fig 7. Patient is in the supine position. A 30° arthroscope (Olympus Inc., Center Valley, PA) through the anterolateral portal of a left knee shows the anterior cruciate ligament (ACL) femoral socket.

condyle for predicting the quadrupled semi tendinosus-gracilis graft size as previously described.⁹ In this case, the predicted quadrupled graft was measured 9 mm. With the knee at 120° flexion, a 6-mm over-the-top femoral offset guide (Arthrex, Naples, FL) is inserted through an anteromedial portal, and a 4.0-mm ACL Tightrope Drill pin (Arthrex) is centered through this offset guide at the femoral ACL footprint. Using a 9-mm diameter low-profile reamer (Arthrex), a socket is prepared over the drill pin to a depth that maintains a bone bridge of 7 mm between the socket roof and the outer lateral femoral cortex (Fig 7).

9. For preparing the PCL femoral socket, a stump of the anterolateral (AL) PCL bundle is left at the femur insertion to facilitate identifying desired socket location (Fig 8).

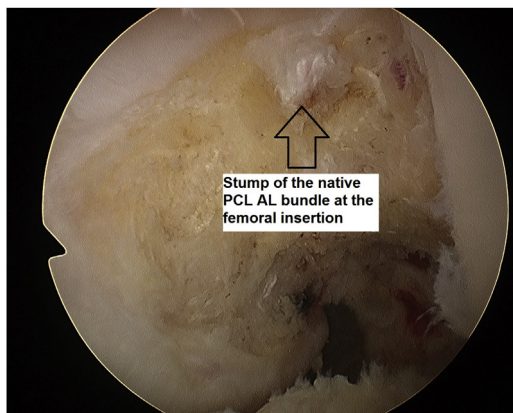


Fig 8. Patient is in the supine position. A 30° arthroscope (Olympus Inc., Center Valley, PA) through the anterolateral portal of a left knee shows a stump of the AL PCL bundle which facilitates identifying correct location for establishment of the PCL femoral socket. (AL, anterolateral; PCL, posterior cruciate ligament.)

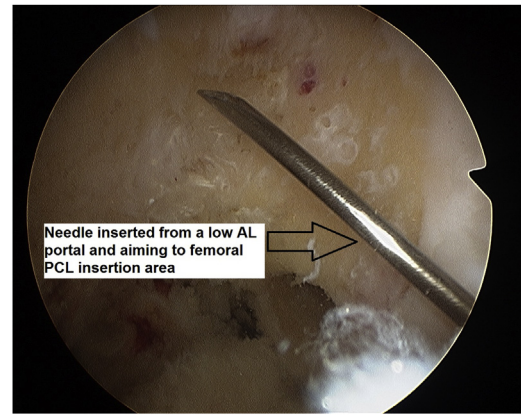


Fig 9. Patient is in the supine position. With the left knee at 110° flexion, a 30° arthroscope (Olympus Inc., Center Valley, PA) through the anteromedial portal of a left knee shows a needle inserted through a low AL portal and aiming to the desired PCL femoral socket location. (AL, anterolateral; PCL, posterior cruciate ligament.)

10. With the knee at 110° flexion, a low AL portal is established with the assistance of a needle aiming to the desired PCL femoral socket location (Fig 9).
11. A 10-mm diameter low-profile reamer (Arthrex) is inserted through the low AL portal and held at the AL PCL bundle femoral insertion location on the femur flush against the subchondral bone (Fig 10).
12. A 2.4-mm drill guide pin (Arthrex) is inserted through the reamer (Fig 11).
13. The PCL femoral socket is reamed to a depth of 20 mm (Fig 12).
14. The posteromedial (PM) portal is then established with the knee at 90° and the assistance of a needle and should be located proximal enough to enable

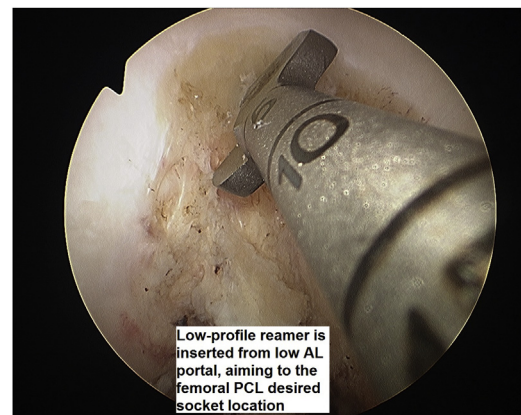

Fig 10. Patient is in the supine position. A 30° arthroscope (Olympus Inc., Center Valley, PA) through the anteromedial portal of a left knee shows a 10-mm diameter low-profile reamer (Arthrex, Naples, FL) inserted through the low AL portal and held at the AL PCL bundle femoral insertion location on the femur flush against the subchondral bone. (AL, anterolateral; PCL, posterior cruciate ligament.)

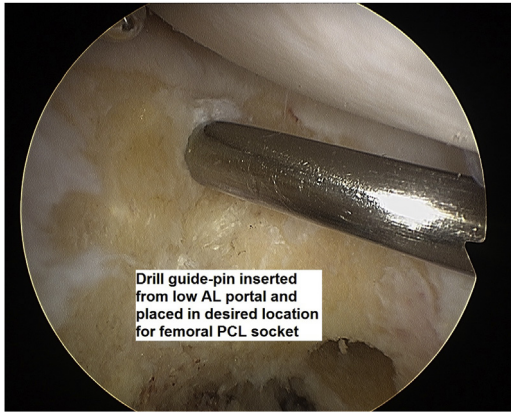


Fig 11. Patient is in the supine position. A 30° arthroscope (Olympus Inc., Center Valley, PA) through the anteromedial portal of a left knee shows a 2.4-mm drill guide pin (Arthrex, Naples, FL) which was inserted through the low profile reamer. (AL, anterolateral; PCL, posterior cruciate ligament.)

direct aiming of the working tools through this portal toward the PCL tibial insertion area (Fig 13).

15. At this point, a 70° arthroscope (Olympus Inc., Center Valley, PA) is introduced through the AL portal which enables viewing the PCL tibial insertion area.
16. After soft tissue and remaining PCL tissue is cleaned off the back at the tibial PCL insertion area as presented in the video, using ArthroCare Sports medicine wand (Smith & Nephew, Andover, MA), a tibial PCL hook arm (Arthrex) is then inserted through the AM portal and seated flush against the medial and lateral posterior tibial spines (Fig 14).
17. Using the tibial PCL hook arm for aiming, a 2.4-mm drill guide pin (Arthrex) is aimed to exit posteriorly between the tibial spines of the PCL tibial insertion slightly lateral and distal to the center of the native PCL insertion (Fig 15) as described previously.¹⁰

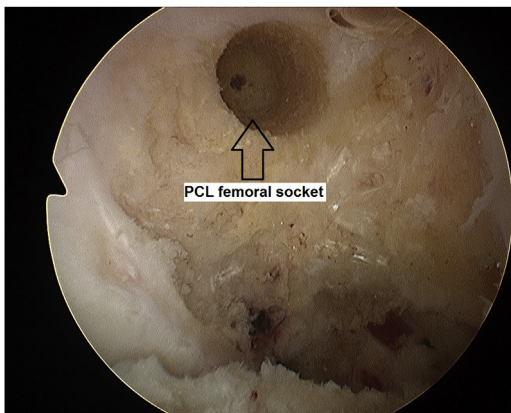


Fig 12. Patient is in the supine position. A 30° arthroscope (Olympus Inc., Center Valley, PA) through the anterolateral portal of a left knee shows the PCL femoral socket which is reamed to a depth of 20 mm. (PCL, posterior cruciate ligament.)

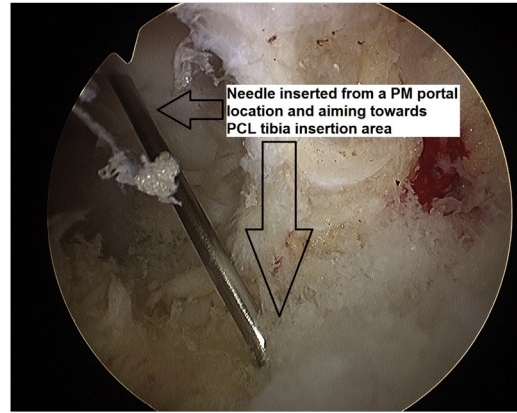


Fig 13. Patient is in the supine position. A 30° arthroscope (Olympus Inc., Center Valley, PA) through the anterolateral portal of a left knee shows a needle which is inserted through a PM portal point and aiming toward the PCL tibial insertion area. (PCL, posterior cruciate ligament; PM, posteromedial.)

This also can be monitored with fluoroscopy. The slightly distal location of the tunnel relative to the center of the native PCL reduces the "killer turn" of the PCL graft at the back¹¹ (Table 1).

18. Before reaming the PCL tibia tunnel over the guide pin from front to back, arthroscopic spoon is introduced through the PM portal and held against the tip of the drill guide pin to prevent posterior migration of the drill guide pin during tunnel reaming and prevent from the reamer to drive far back beyond the posterior tibial cortex (Fig 16).
19. A 10-mm diameter tibia tunnel is then prepared front to back with the knee held at 90° flexion, using 10-mm reamer (Arthrex) (Fig 17). Tunnel edges at the back are then smoothed as a measure to decrease "killer turn" and ease graft passage as presented in the movie (Table 1).

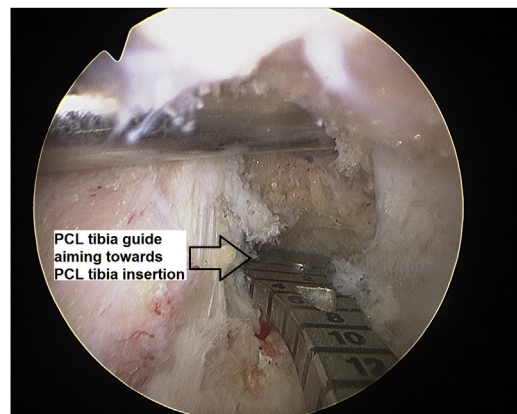


Fig 14. Patient is in the supine position. A 70° arthroscope (Olympus Inc., Center Valley, PA) through the anterolateral portal of a left knee shows a tibial PCL hook arm (Arthrex, Naples, FL) which is inserted through the AM portal and seated flush against the medial and lateral posterior tibial spines. (AM, anteromedial; PCL, posterior cruciate ligament.)

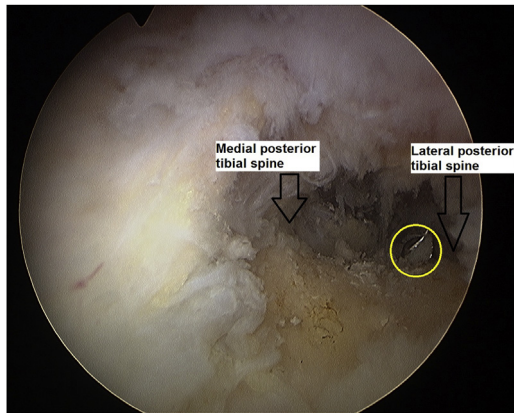


Fig 15. Patient is in the supine position. A 70° arthroscope (Olympus Inc., Center Valley, PA) through the anterolateral portal of a left knee shows the tip of the 2.4-mm drill guide pin (Arthrex, Naples, FL) (yellow circle) exiting posteriorly between the tibial spines of the PCL tibia insertion slightly lateral and distal to the center of the native PCL insertion. (PCL, posterior cruciate ligament.)

20. The ACL tibial tunnel is then prepared and reamed according to the preoperative MRI measurements. In this case, a 9-mm tunnel was prepared (Fig 18). Care is taken to avoid ACL and PCL tunnel convergence at the anteromedial tibial cortex (Table 1).
21. Two separate shuttle suture open loops (ETHIBOND #5; Ethicon, Inc., Somerville, NJ) are then passed into the knee for shuttling the PCL graft. Both suture loops are introduced separately through the AM portal (Fig 19) while keeping the closed part of each loop outside the AM portal. The 2 limbs of one suture (the open side of the loop) are inserted into the femoral socket (Fig 19, black star) and then out of the anteromedial femoral cortex. The 2 limbs of the second suture are inserted into

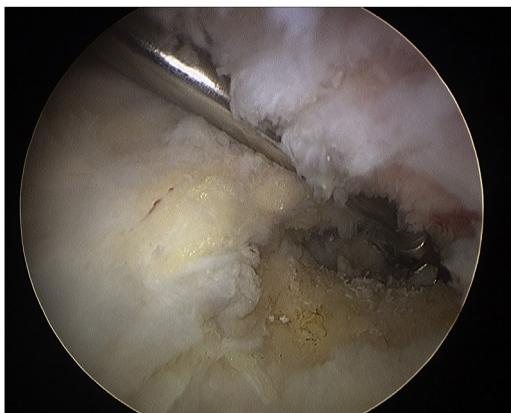


Fig 16. Patient is in the supine position. A 70° arthroscope (Olympus Inc., Center Valley, PA) through the anterolateral portal of a left knee shows arthroscopic spoon introduced through the PM portal and held against the tip of the drill guide pin. (PM, posteromedial.)

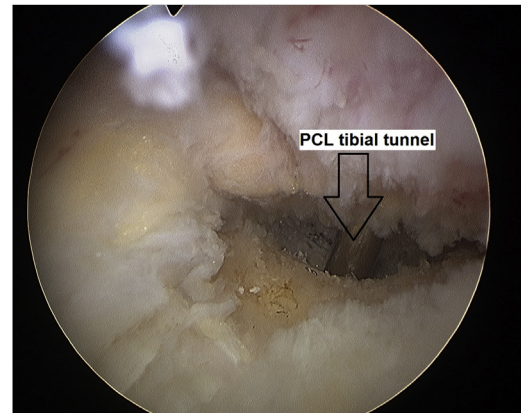


Fig 17. Patient is in the supine position. A 70° arthroscope (Olympus Inc., Center Valley, PA, USA) through the anterolateral portal of a left knee shows the posterior aperture of the 10-mm diameter PCL tibial tunnel (a switching stick passed in the tunnel emphasizes its location). (PCL, posterior cruciate ligament.)

the posterior aperture of the tibial PCL tunnel (Fig 19, black circle) to finally exit at the anterior aperture of the tunnel.

22. To facilitate graft passage, a switching stick is introduced through the PM portal and used as a pulley over which the PCL tibial tunnel shuttle suture is held (Fig 20, yellow star). This will later ease graft passage from front to back into the PCL tibial tunnel and then graft pulling toward the anterior tibial aperture of the PCL tunnel.
23. Another shuttle suture is then inserted into the femoral ACL socket and tibial ACL tunnel.
24. At this point, full-thickness quadriceps tendon autograft is harvested 10 mm wide, starting proximally (Fig 21).
25. The proximal tip of the quadriceps tendon graft is held with a whipstitch suture (ETHIBOND #5; Ethicon Inc.). Once the harvest of the quadriceps

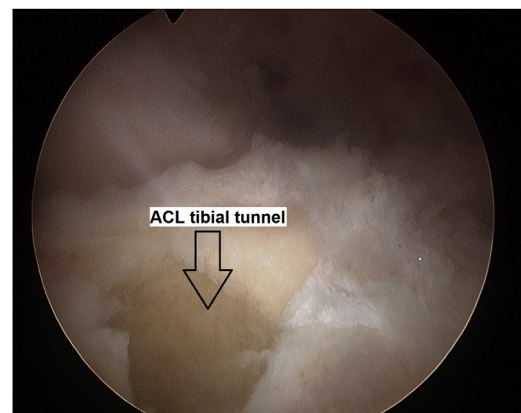


Fig 18. Patient is in the supine position. A 9-mm tibial tunnel is prepared at the anatomic location for the ACL tibial insertion. (ACL, anterior cruciate ligament.)

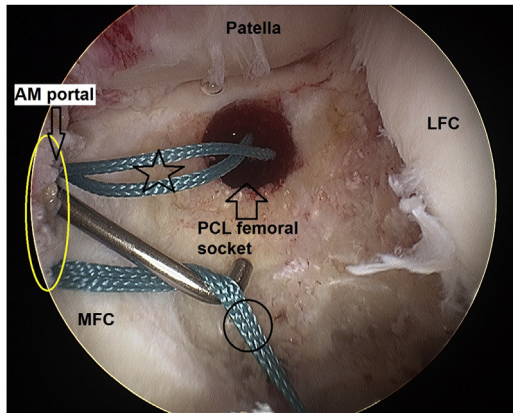


Fig 19. Patient is in the supine position. A 70° arthroscope (Olympus Inc., Center Valley, PA) through the anterolateral portal of a left knee shows two separate shuttle suture loops for shuttling the PCL graft introduced separately through the AM portal (yellow ellipse). The 2 limbs of one suture (the open side of the loop) are inserted into the femoral socket (black star) and then out of the anteromedial femoral cortex. The 2 limbs of the second suture are inserted into the posterior aperture of the tibial PCL tunnel (black circle) to finally exit at the anterior aperture of the tunnel. (AM, anteromedial; LFC, lateral femoral condyle; MFC, medial femoral condyle; PCL, posterior cruciate ligament.)

tendon reach the proximal patellar pole, the graft is flipped to identify the quadriceps bone insertion (Fig 22) (Table 1).

26. The quadriceps graft harvest is finalized and prepared on a side table with a proximal patellar bone plug measuring 10 × 20mm (Fig 23). Two 1.5-mm drill holes are made through the bone plug and one suture is inserted in each hole (ETHIBOND #5; Ethicon Inc.). The quadriceps harvest site is irrigated

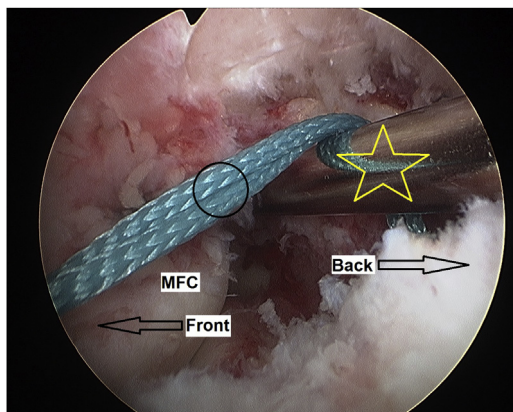


Fig 20. Patient is in the supine position. A 70° arthroscope (Olympus Inc., Center Valley, PA) through the anterolateral portal of a left knee shows a switching stick (yellow star) which is introduced through the PM portal and used as a pulley over which the PCL tibial tunnel shuttle suture (black circle) is held. (MFC, medial femoral condyle; PCL, posterior cruciate ligament; PM, posteromedial.)

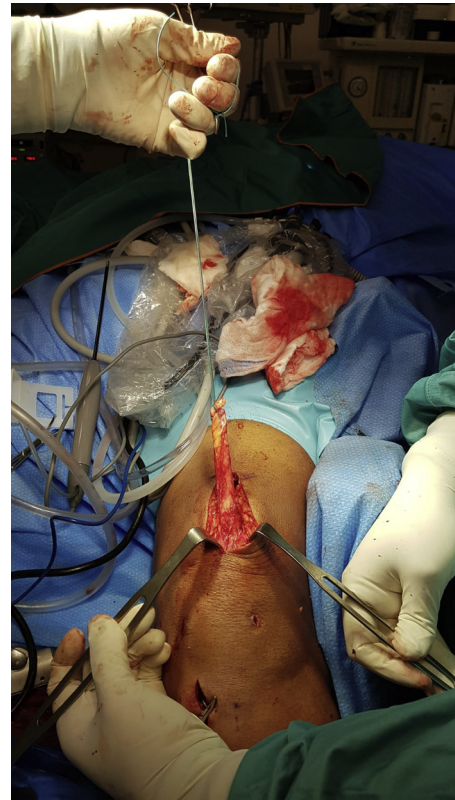

Fig 21. Patient is in the supine position. A full-thickness quadriceps tendon autograft is harvested 10 mm wide, starting proximally.

and firmly closed using VICRYL #1 sutures, starting proximally to prevent quadriceps tendon–muscle retraction.

27. The quadriceps-bone autograft is inserted into the knee through the AM portal in the following manner: Outside the knee, the ETHIBOND sutures of the quadriceps bone plug are inserted into the shuttle suture loop that passes through the femoral PCL socket, and the ETHIBOND suture of the whipstitch soft-tissue tip of the Quadriceps graft is inserted into the shuttle suture loop that passes through the tibial PCL tunnel. The shuttle suture that exits the PCL tibial tunnel at the front is then pulled anteriorly and takes the graft into the knee. Pulling this shuttle suture ceases once the bone plug is viewed in the intercondylar notch (Fig 24).
28. Arthroscopic probe is used to manipulate the bone plug into the femoral socket (Fig 25).
29. The quadriceps bone plug is fixed in the femoral socket using a 7 × 20-mm titanium screw (Arthrex) (Fig 26).
30. The knee is cycled to ensure that the quadriceps graft passed fully into the tibial tunnel without graft tethering posteriorly in the tunnel.
31. Ipsilateral semitendinosus and gracilis autografts are then harvested and prepared on a TightRope RT

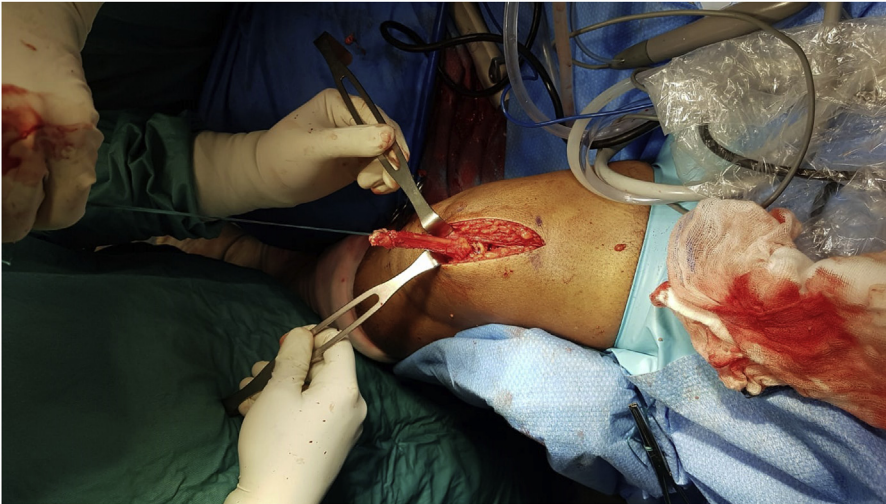

Fig 22. Patient is in the supine position. The quadriceps tendon graft is flipped to identify the tendon–bone insertion.

device (Arthrex). The quadrupled graft is measured to confirm it fits the femoral and tibial ACL tunnels. In case of more than 1-mm undersize of the quadrupled graft relative to the bone tunnels, a contralateral gracilis tendon can be used to augment the graft thickness. If the quadrupled graft is slightly oversize relative to the bone tunnels, the femoral socket and tibial ACL tunnel are 0.5 mm to 1.0 mm enlarged accordingly.

32. The quadrupled semitendinosus-gracilis ACL autograft is inserted into the knee and fixed on the femur with the TightRope RT device (Arthrex) (Fig 27).
33. The knee is cycled to ensure that the quadrupled ACL graft is not tethered in the tibial ACL tunnel.
34. A lateral hockey-stick incision is made on the lateral side with the knee at 90° flexion. The common peroneal nerve is identified and released (Fig 28).
35. Any avulsions of the lateral and posterolateral restraints are identified at the fibular head (Fig 29,

yellow circle) and repaired as needed. In this case, FCL avulsion was identified.

36. A split is made through the anterior fibers of the iliotibial band (ITB). The femoral insertions of the FCL and popliteus tendon are identified (Fig 30).
37. A 6-mm tunnel is reamed over a 2.4-mm drill guide pin (Arthrex) through the fibular head, starting laterally on the anterior edge of the native FCL fibular insertion and aiming 45° proximal and posterior.
38. A contralateral semitendinosus tendon is then harvested and prepared on a side table with a whipstitch suture (ETHIBOND #5; Ethicon Inc.) at each end.
39. The semitendinosus graft is passed through the 6-mm fibular head tunnel. The graft limb that exits the anterior aperture of the fibular head tunnel is passed under the ITB and follows the course of the

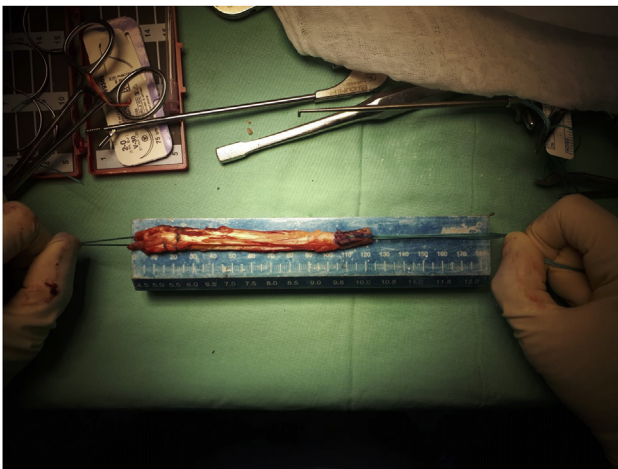

Fig 23. The finalized quadriceps tendon graft with a proximal patellar bone plug measuring 10 × 20-mm on a side table.

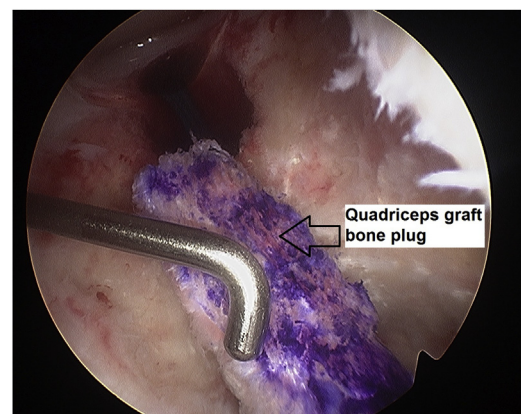


Fig 24. Patient is in the supine position. A 30° arthroscope (Olympus Inc., Center Valley, PA) through the anterolateral portal of a left knee shows the quadriceps graft bone plug in the intercondylar notch adjacent to the PCL femoral socket. (PCL, posterior cruciate ligament.)

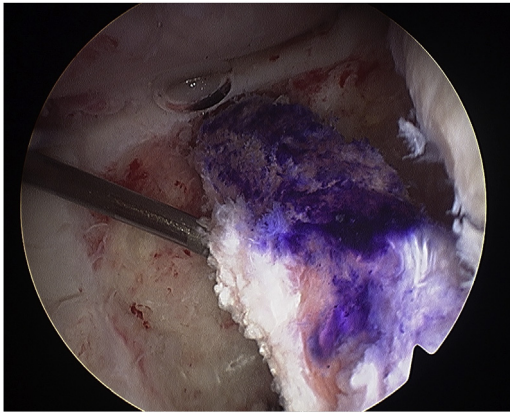


Fig 25. Patient is in the supine position. A 30° arthroscope (Olympus Inc., Center Valley, PA) through the anterolateral portal of a left knee shows arthroscopic probe manipulating the Quadriceps graft bone plug into the PCL femoral socket. (PCL, posterior cruciate ligament.)

native FCL to reconstruct the FCL restraining vector. The graft limb that exits the posterior aperture of the fibular head tunnel is passed under the Biceps femoris and under the ITB towards the location of the popliteus femoral insertion to reconstruct a PLC restraining vector (Fig 31).

40. The PCL quadriceps tendon-bone autograft is tensioned first. It is fixed in the tibial tunnel using a 10 × 25-mm titanium soft screw (Arthrex) while restoring the step-off with the knee at 80° to 90° flexion. The ACL quadrupled semitendinosus-gracilis autograft is tensioned second. It is fixed in the tibial tunnel using a 9 × 25-mm titanium soft screw (Arthrex) with the knee at 0° extension. A backup cortical fixation is added to both PCL and ACL autografts by tying the whipstitch ETHIBOND sutures of both grafts to a 4.0-mm cancellous screw and washer (Table 1).

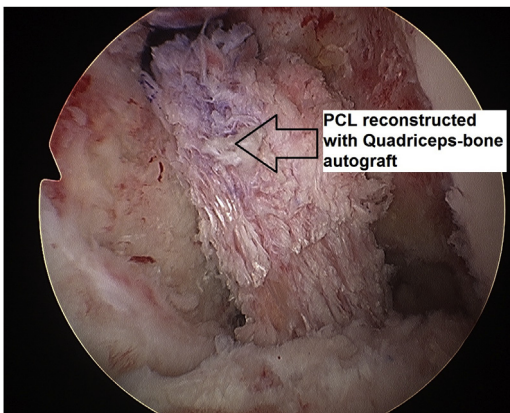


Fig 26. Patient is in the supine position. A 30° arthroscope (Olympus Inc., Center Valley, PA) through the anterolateral portal of a left knee shows the quadriceps graft bone plug fixed in the femoral socket using a 7 × 20-mm titanium screw (Arthrex, Naples, FL). (PCL, posterior cruciate ligament.)

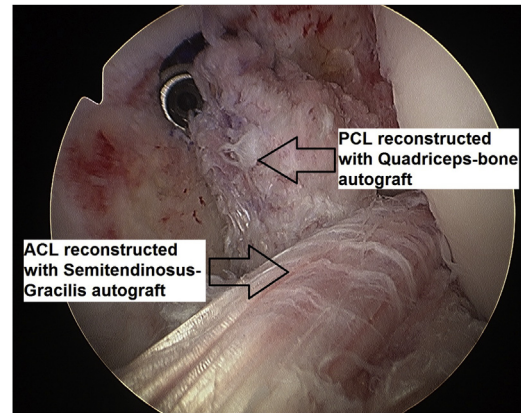


Fig 27. Patient is in the supine position. A 30° arthroscope (Olympus Inc., Center Valley, PA) through the anterolateral portal of a left knee shows final configuration of the ACL and PCL reconstructions. The ACL is reconstructed with a quadrupled semitendinosus–gracilis autograft and the PCL is reconstructed with a quadriceps–bone autograft. (ACL, anterior cruciate ligament; PCL, posterior cruciate ligament.)

41. In chronic cases in which posterolateral or mid-lateral capsule laxity is identified, a posterolateral capsule shift is performed by splitting the

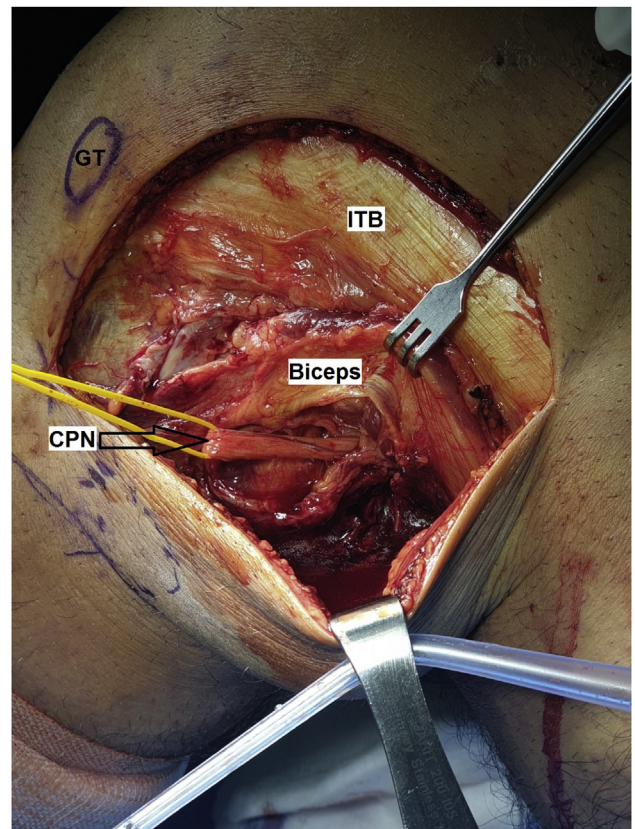


Fig 28. This is the left knee. The patient is in the supine position and the knee at 90° flexion. The CPN is identified and released. The nerve is protected and isolated using a yellow vessel-loop. (CPN, common peroneal nerve; GT, Gerdy tubercle; ITB, iliotibial band.)

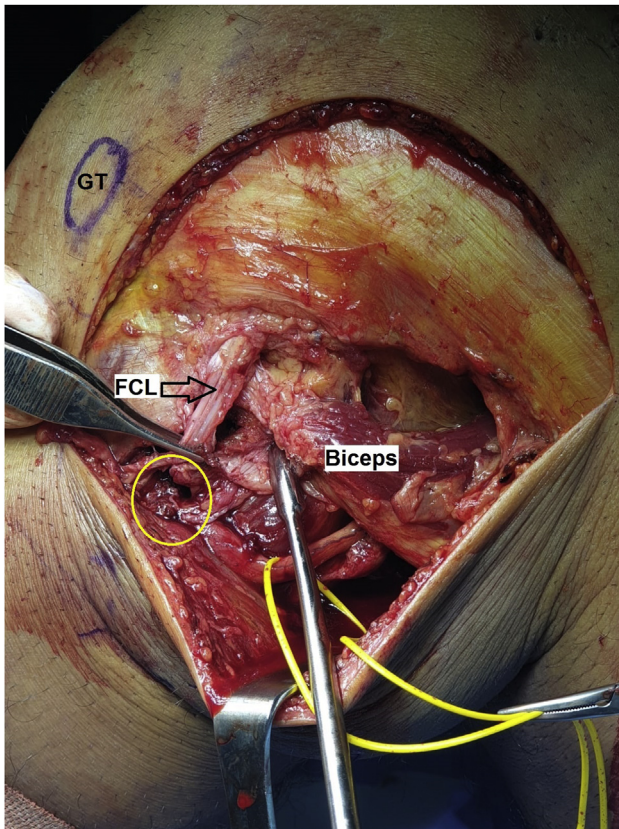


Fig 29. This is the left knee. The patient is in the supine position and the knee at 90° flexion. FCL avulsion is identified off the fibular head (yellow circle). (FCL, fibular collateral ligament; GT, Gerdy tubercle.)

posterolateral capsule from the FCL area and adding 3 to 5 mattress sutures which tighten the posterolateral capsule to the FCL. The tightening of the sutures is performed with the knee at 90° flexion (Fig 32).

42. A 4.5 × 35-mm titanium screw with an 18-mm spiked washer (Arthrex) is inserted just between the femoral insertion points of the FCL and popliteus. With the knee at 20° flexion, minimal valgus load and neutral rotation, both semitendinosus limbs around the 4.5-mm screw are then pulled anteriorly. The 4.5-mm screw in the 18-mm spiked washer is fully driven until the semitendinosus graft limbs fixation is firm and complete (Fig 33).
43. The anterior ITB split and the split between the posterior ITB fibers and biceps femoris are closed to restore the anatomy of the superficial posterolateral restraining layer (Fig 34).

Early postoperative protocol includes wearing a T-scope knee brace (Breg Inc., Carlsbad, CA). The patient is instructed to place a pillow under the leg from the knee and distally whenever in a supine position to provide a posterior tibial support and decrease gravity forces over the PCL graft. Range of motion is allowed

0 to 30° during the first 2 weeks, 0 to 60° during the third and fourth weeks, 0 to 90° during the fifth and sixth weeks, and then unrestricted range of motion is encouraged. All range of motion exercises are performed in a prone position during the first 3 months. Weight-bearing is avoided for 6 weeks, after which stationary bike exercises are initiated together with gradual increase in open and closed kinetic chain exercises. The knee brace is used for 12 weeks during walking to ensure FCL-PLC graft protection during soft tissue-to-bone incorporation. Crutches are used until gait pattern is normalized. Emphasis is applied to restoring knee extensors and flexors strength during the next months. Running is allowed after 4 to 6 months, and only after symmetric step-down test is achieved. At 9 to 12 months postoperatively, in addition to physical examination and functional tests, MRI of the knee is obtained to appreciate signal and orientation of all reconstructed ligaments (Fig 35). This can assist in decision-making regarding recommended type and level of return to sports. Tips and pearls, and advantages and disadvantages, of the technique described are summarized in Tables 1 and 2.

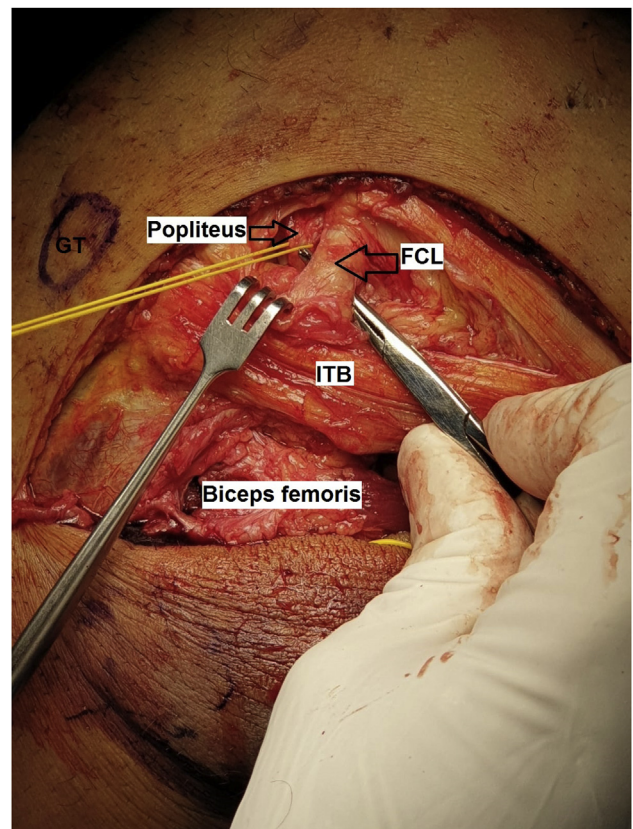


Fig 30. This is the left knee. The patient is in the supine position and the knee at 90° flexion. A split is made through the anterior fibers of the ITB and the femoral insertions of the FCL and popliteus tendon (held separately with a yellow vessel-loop) are identified. (FCL, fibular collateral ligament; ITB, iliotibial band.)

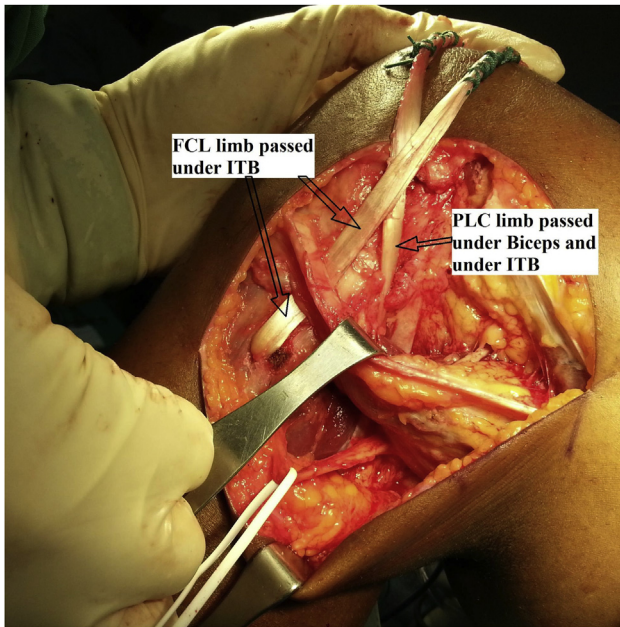


Fig 31. This is the left knee. The patient is in the supine position and the knee at 90° flexion. The contralateral semitendinosus graft is passed through the 6mm fibular head tunnel. The graft limb that exits the anterior aperture of the fibular head tunnel is passed under the ITB. The graft limb that exit the posterior aperture of the fibular head tunnel is passed under the biceps femoris and under the ITB. (FCL, fibular collateral ligament; ITB, iliotibial band; PLC, posterolateral corner.)

Discussion

Multiligament knee reconstruction with the use of autografts has gained less popularity compared with allografts.² Nevertheless, using autografts has a role in these complex cases, particularly in places where high-quality allografts are not available. This manuscript presents a technique for using solely autografts to reconstruct a case of a KD-IIIIL injury. Choosing the specific autografts as described addresses important principles. For reconstructing the PCL, harvesting a full-thickness quadriceps tendon with a proximal patellar bone plug as described achieves several goals that may be of critical importance. First, the quadriceps tendon seems appropriate graft choice for PCL reconstruction as it is the thickest and most resilient graft of all autograft choices¹² and has stiffness which resembles the native PCL.¹³ This is important to withstand the high loads subjected to the PCL graft which may lead to gradual increase in posterior knee laxity during the rehabilitation process despite perfect posterior stability obtained during the operation.¹⁴ Furthermore, harvesting the tendon with a patellar bone plug elongates the PCL graft by 2 cm. This is important because a long graft which passes from the femoral socket to the anterior aperture of the PCL tibial tunnel facilitates graft

fixation in the tibial tunnel with an interference screw. In case that the graft does not reach the anterior aperture of the tibial tunnel, the whipstitch ETHIBOND sutures of the graft can be tied over a cortical post on the anteromedial tibial cortex. Another advantage of using a tendon–bone autograft in this case is that bone-to-bone healing in the femoral PCL socket allows fast graft–host incorporation which is desired and recommended by previous investigators for PCL reconstruction¹³ (Table 2). Of note, a single- and not a double-bundle reconstruction of the PCL is demonstrated in this technique. This is supported by the fact that despite possible biomechanical advantages of a double-bundle PCL reconstruction, functional outcome studies still show similar results compared to single bundle PCL reconstruction.^{15,16} Following the harvest of a full-thickness quadriceps tendon–bone autograft, additional harvest from the extensor mechanism could increase the risk of extensor mechanism graft morbidities such as persistent weakness and risk of patellar fracture. Therefore, for the ACL reconstruction, avoiding bone–patellar tendon–bone autograft is recommended, despite the fact it is considered the “gold standard” graft for ACL reconstruction in young active adults. In this case therefore, the semitendinosus and gracilis tendons are used as a quadrupled autograft which is also a reliable option for reconstructing the ACL in young adults. Following these autograft choices for PCL and ACL reconstruction, an additional graft is needed to address in this KD-IIIIL scenario the insufficient posterolateral restraints. While posterolateral reconstruction is by itself another issue of ongoing controversy within the multiple ligament injured knee scenario¹⁷ and can be performed by using two or three

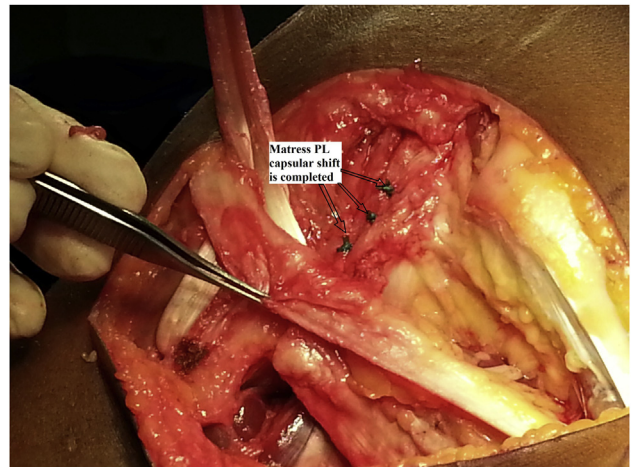


Fig 32. This is the left knee. The patient is in the supine position and the knee at 90° flexion. A posterolateral (PL) capsular shift is performed using 3 to 5 mattress configuration sutures.

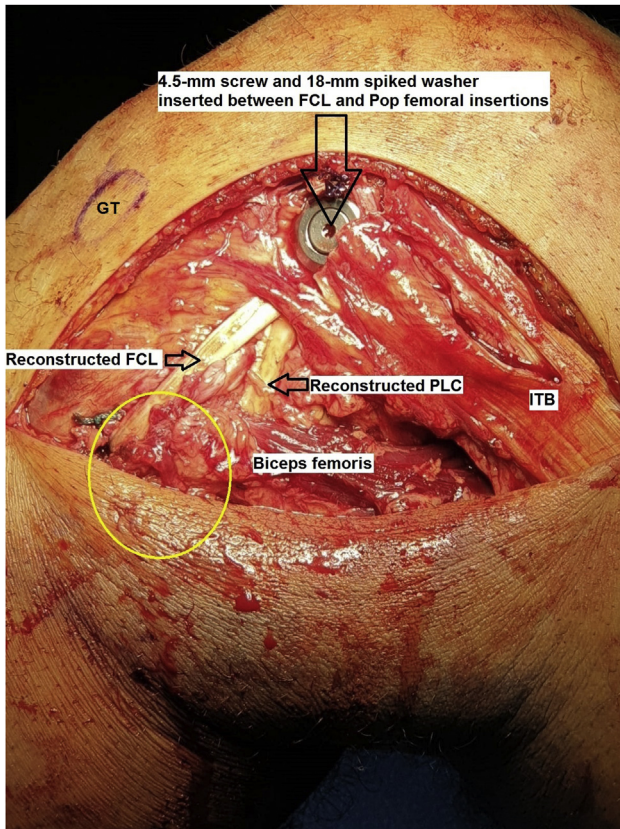


Fig 33. This is the left knee. The patient is in the supine position and the knee at 90° flexion. The final configuration of the contralateral semitendinosus autograft that reconstructs the FCL and PLC restraining vectors is seen. A 4.5 × 35-mm titanium screw with an 18-mm spiked washer (Arthrex, Naples, FL) is inserted just between the femoral insertion points of the FCL and popliteus and fixes both graft limbs. The fibular head area is marked with a yellow circle. (FCL, fibular collateral ligament; GT, Gerdy tubercle; ITB, iliotibial band; PLC, posterolateral corner.)

autografts and multiple fixation points on the femur and on the tibia in order to adhere to the anatomic PLC reconstruction technique,¹⁸ in some cases, as in the case presented, without a substantial hyper-extension deformity, a single graft can be used, adhering to the principles of a fibular head-based PLC reconstruction with hardware fixation on the femur only.¹⁹ For this purpose, the contralateral knee Semitendinosus is a good graft option as demonstrated and can address resiliency and length requirements.

In the technique presented, PCL and ACL graft harvest is performed after the femoral sockets and the tibial tunnels are ready with shuttle sutures in place (Table 1). This technique requires careful preoperative planning of the semitendinosus and gracilis surface area on the preoperative MRI as suggested.⁹ The advantage is that by doing so, all autografts harvested remain

exterior to the body only a few minutes until they are all passed through the knee tunnels and sockets. In such a long operation, this may decrease the potential for graft contamination and possible infection. This is why soaking the autografts in vancomycin is avoided in this technique, although graft soaking in vancomycin can be an option based on surgeon's preference. Disadvantages of using the described technique should be remembered and include time-consuming surgery compared with using allografts, and potential risks of multiple donor site morbidities (Table 2). Furthermore, limiting autograft number to 3 or 4 may be recommended to limit the risk of multiple donor sites morbidities, but this may also result in not fully addressing other scenarios of multiligament injuries such as those which require double-bundle constructs (i.e., anatomic PLC reconstruction or double-bundle PCL reconstruction). In summary, multiligament KD-III knee reconstruction can be addressed by an all-autograft approach, although it is a time-consuming surgery and holds increased risk for donor site morbidities compared to

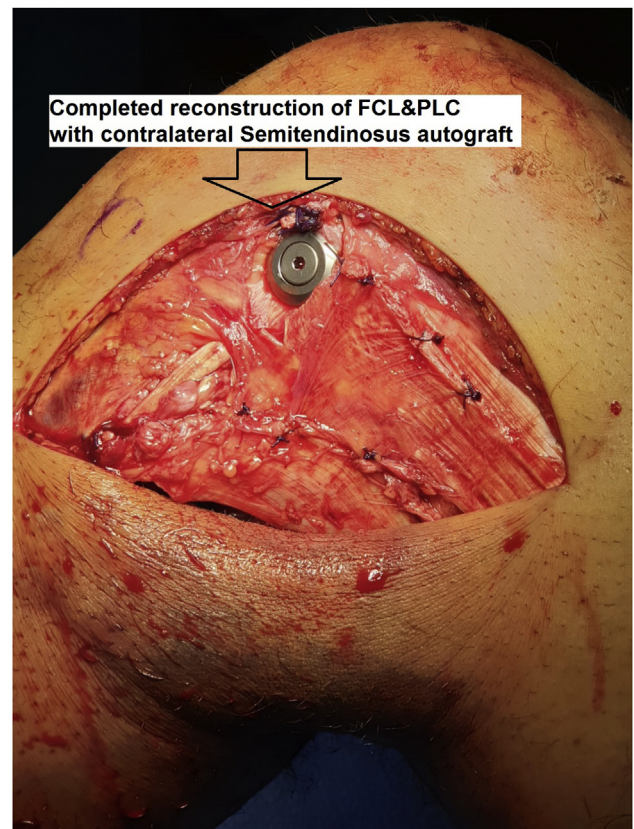


Fig 34. This is the left knee. The patient is in the supine position and the knee at 90° flexion. The anterior ITB split and the split between the posterior ITB fibers and Biceps femoris are closed to restore the anatomy of the superficial posterolateral restraining layer. (FCL, fibular collateral ligament; ITB, iliotibial band; PLC, posterolateral corner.)

Reconstructed ACL + PCL + FCL&PLC at 1-year postoperatively

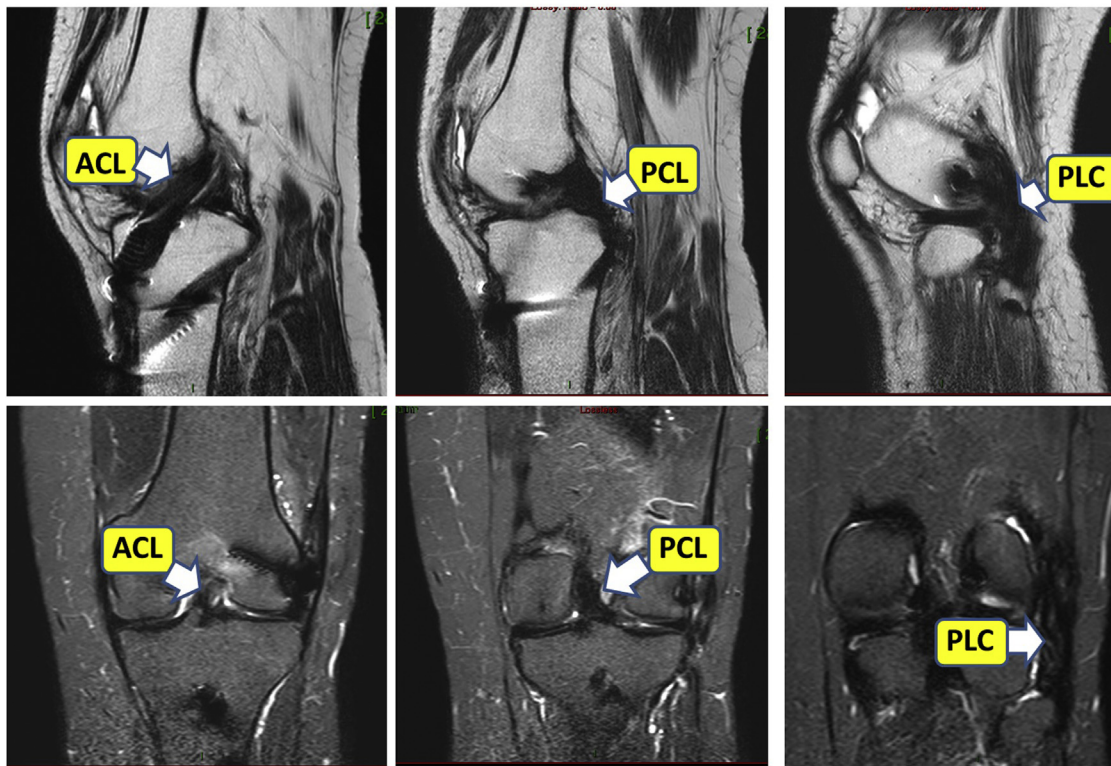


Fig 35. One-year postoperative magnetic resonance imaging of the left knee showing low signal well-aligned reconstructed ligaments including ACL (left-sided upper image sagittal view and left-sided lower image coronal view), PCL (central upper image sagittal view and central lower image coronal view), and PLC (right-sided upper image sagittal view and right-sided lower image coronal view). (ACL, anterior cruciate ligament; PCL, posterior cruciate ligament; PLC, posterolateral corner.)

using allografts. This approach may be of particular value in places where high-quality nonirradiated allografts are not available or in combination with allograft use according to surgeon's preference and patient factors.

Table 2. Advantages/Disadvantages of Performing All-Autograft Compared With Allograft Multiligament Knee Reconstruction

Advantages

- Potentially faster graft-host biological incorporation
- Significantly reduced financial costs of the operation
- Provide a management strategy for multiligament knee injuries in areas where high-quality nonirradiated allografts are not available

Disadvantages

- Time-consuming surgery
- Potential risk of multiple donor-sites morbidity
- Limiting the number of autografts to 3 or 4 to avoid greater risks of donor sites morbidities may lead to not fully addressing all scenarios of multiligament injuries or for surgeons who prefer double-bundle constructs

References

1. Peskun CJ, Whelan DB. Outcomes of operative and nonoperative treatment of multiligament knee injuries: An evidence-based review. *Sports Med Arthrosc* 2011;19:167-173.
2. Moatshe G, Chahla J, LaPrade RF, Engebretsen L. Diagnosis and treatment of multiligament knee injury: State of the art. *J ISAKOS* 2017;2:152-161.
3. Fanelli GC, Edson CJ. Surgical treatment of combined PCL-ACL medial and lateral side injuries (global laxity): Surgical technique and 2- to 18-year results. *J Knee Surg* 2012;25:307-316.
4. Kim SJ, Kim SH, Jung M, Kim JM, Lee SW. Does sequence of graft tensioning affect outcomes in combined anterior and posterior cruciate ligament reconstructions? *Clin Orthop Relat Res* 2015;473:235-243.
5. Nagda SH, Altobelli GG, Bowdry KA, Brewster CE, Lombardo SJ. Cost analysis of outpatient anterior cruciate ligament reconstruction: Autograft versus allograft. *Clin Orthop Relat Res* 2010;468:1418-1422.
6. Tom JA, Rodeo SA. Soft tissue allografts for knee reconstruction in sports medicine. *Clin Orthop Relat Res* 2002;402:135-156.

7. Mroz TE, Joyce MJ, Steinmetz MP, Lieberman IH, Wang JC. Musculoskeletal allograft risks and recalls in the United States. *J Am Acad Orthop Surg* 2008;16:559-565.
8. Mascarenhas R, Erickson BJ, Sayegh ET, et al. Is there a higher failure rate of allografts compared with autografts in anterior cruciate ligament reconstruction: A systematic review of overlapping meta-analysis. *Arthroscopy* 2015;31:364-372.
9. Leiter J, Elkurbo M, McRae S, Chiu J, Froese W, MacDonald P. Using pre-operative MRI to predict intra-operative hamstrings graft size for anterior cruciate ligament reconstruction. *Knee Surg Sports Traumatol Arthrosc* 2017;25:229-235.
10. Tompkins M, Keller TC, Milewski MD, et al. Transtibial tunnel placement in posterior cruciate ligament reconstruction: How it relates to the anatomic footprint. *Orthop J Sports Med* 2014;2. 2325967114523384.
11. Wang Z, Xiong Y, Chen G, et al. Modified tibial tunnel placement for single-bundle posterior cruciate ligament reconstruction reduces the "Killer Turn" in a biomechanical model. *Medicine* 2019;98.
12. Offerhaus C, Albers M, Nagai K, et al. Individualized anterior cruciate ligament graft matching: In-vivo comparison of cross-sectional areas of hamstring, patellar, and quadriceps tendon grafts and ACL insertion area. *Am J Sports Med* 2018;46:2646-2652.
13. Hoher J, Scheffler S, Weiler A. Graft choice and graft fixation in PCL reconstruction. *Knee Surg Sports Traumatol Arthrosc* 2003;11:297-306.
14. Gwinner C, Jung TM, Schatka I, Weiler A. Posterior laxity increases over time after PCL reconstruction. *Knee Surg Sports Traumatol Arthrosc* 2019;27:389-396.
15. Chahla J, Williams BT, LaPrade RF. Posterior cruciate ligament. *Arthroscopy* 2020;36:333-335.
16. Fanelli GC, Beck JD, Edson CJ. Single compared to double-bundle PCL reconstruction using allograft tissue. *J Knee Surg* 2012;25:59-64.
17. Chahla J, Murray IR, Robinson J, et al. Posterolateral corner of the knee: An expert consensus statement on diagnosis, classification, treatment, and rehabilitation. *Knee Surg Sports Traumatol Arthrosc* 2019;27:2520-2529.
18. Franciozi CE, Albertoni LJB, Kubota MS, et al. A hamstring-based anatomic posterolateral knee reconstruction with autografts improves both radiographic instability and functional outcomes. *Arthroscopy* 2019;35:1676-1685.
19. Fanelli GC. Fibular head-based posterolateral reconstruction of the knee: Surgical technique and outcomes. *J Knee Surg* 2015;28:455-463.