


# A Peculiar Peritoneum: A Case of Tuberculosis in a Male Without Known Risk Factors

Journal of Investigative Medicine High Impact Case Reports  
Volume 10: 1–3  
© 2022 American Federation for Medical Research  
DOI: 10.1177/23247096221142278  
journals.sagepub.com/home/hic  


Joshua Wynne, MD<sup>1\*</sup>, Kimberline Chew, MD<sup>1\*</sup>, Pooja Kothari, MD<sup>1</sup>, Maxwell Bressman, MD<sup>1,2</sup>, and Clara Tow, MD<sup>2,3</sup>

## Abstract

Peritoneal tuberculosis is an uncommon diagnosis in developed countries and most commonly presents in patients with known risk factors for tuberculosis. We report a case of a patient without tuberculosis risk factors who presented with 4 years of intermittent fevers, several weeks of increasing abdominal distention, and newly discovered elevated liver tests. The diagnosis of peritoneal tuberculosis was confirmed following an extensive workup with a positive ascitic fluid culture for *Mycobacterium tuberculosis*. The patient's fevers resolved with antibiotic therapy, and antibiotic therapy was subsequently de-escalated based on the susceptibility profile.

## Keywords

peritoneal, extrapulmonary, tuberculosis, ascites

## Introduction

Peritoneal tuberculosis (TB) accounts for 6.1% of extrapulmonary TB cases in the United States<sup>1</sup> and is associated with mortality of around 19%.<sup>2</sup> The diagnosis of peritoneal TB is difficult given its rarity in developed countries, insidious onset, and variable presentations. We present a case of a patient without TB risk factors who developed new-onset abdominal ascites and was found to have peritoneal TB.

## Case Presentation

A 52-year-old HIV-negative African American man was sent to the hospital for persistent fever and newly elevated liver tests. He noted intermittent fevers over the past 4 years, with minimal outpatient workup pursued but patient was lost to follow-up. He also reported a 100-pound intentional weight loss over the past 2 years, although without significant lifestyle changes to accomplish this and despite increasing abdominal distension over the recent weeks. The patient was born in the United States, works as a bus driver, and had lived in the Bronx, New York, for his entire life. He had no known exposure to TB and neither he nor known family members and friends ever lived or traveled to areas endemic with TB. He also had never lived in a shelter, been incarcerated, and had no history of intravenous (IV) drug use.

Initial laboratory findings were significant for aspartate aminotransferase (AST) 141 U/L, alanine aminotransferase

(ALT) 48 U/L, alkaline phosphatase 242 U/L, albumin 2.6 g/dL, total bilirubin 2.2 mg/dL, direct bilirubin 1.4 mg/dK, a platelet count of 79K/ $\mu$ L, and international normalized ratio (INR) of 1.5. Computed tomography of the chest, abdomen, and pelvis with contrast demonstrated left lung upper lobe micronodules, heterogeneous-appearing liver, splenomegaly, and large volume abdominal ascites (Figure 1). Mediastinal, lower thoracic, and abdominopelvic lymphadenopathy was also present. Diagnostic paracentesis yielded white blood cell (WBC) count of 3300 cells/ $\mu$ L, with lymphocytic predominance (82%) and a low serum albumin ascites gradient (SAAG) of 0.8 g/dL. Fluid culture and cytology were negative for bacteria and malignant cells. Ceftriaxone was started for spontaneous bacterial peritonitis given the presence of elevated ascitic neutrophils (363 cells/ $\mu$ L).

<sup>1</sup>Montefiore Medical Center Department of Internal Medicine, Bronx, NY, USA

<sup>2</sup>Albert Einstein College of Medicine, Bronx, NY, USA

<sup>3</sup>Montefiore Medical Center Division of Hepatology, Bronx, NY, USA

\*Co-first authors.

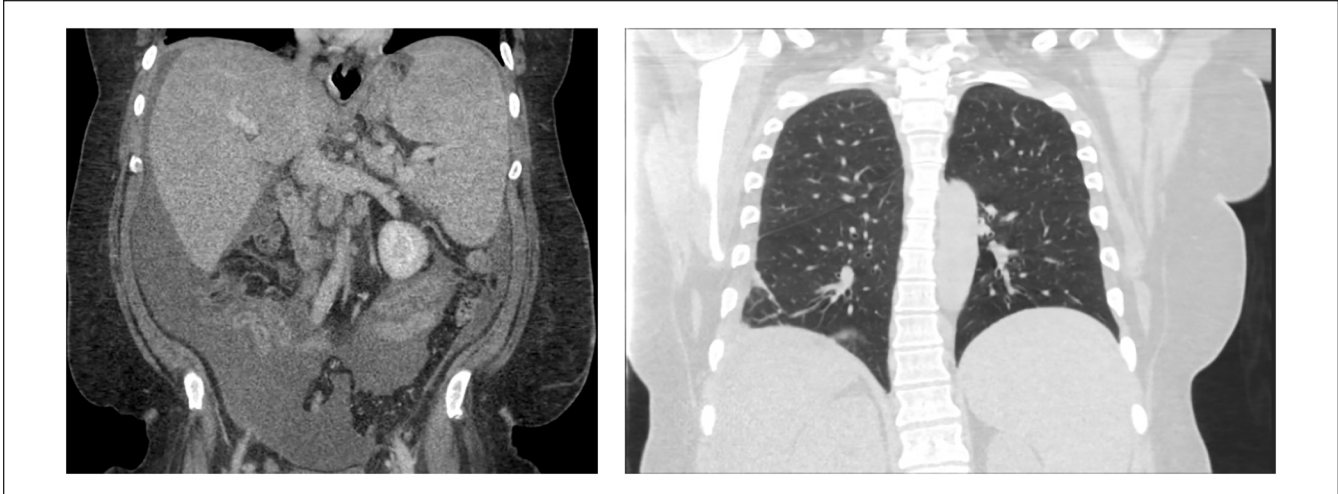
Received September 28, 2022. Revised November 3, 2022. Accepted November 12, 2022.

## Corresponding Author:

Joshua Wynne, MD, Department of Medicine, Montefiore Medical Center, 111 East 210th Street, Bronx, NY 10467, USA.

Email: jowynne@montefiore.org





**Figure 1.** Computed tomography (CT) of the abdomen and pelvis (left) and CT of the chest (right).

Extensive laboratory testing ruled out viral hepatitis and genetic and autoimmune liver disease. Liver biopsy revealed 40% macrovesicular steatosis, mixed portal inflammation, and moderate fibrosis (stage 2/4) consistent with nonalcoholic steatohepatitis. Evaluation for underlying malignancy, including serum protein electrophoresis, urine protein electrophoresis, peripheral flow cytometry, and paracentesis flow cytometry, was normal. A bone marrow biopsy showed normocellular marrow.

Given the presence of lung nodules and marked peritoneal lymphocytosis, a QuantiFERON-TB gold test was sent, which returned positive. Three acid-fast bacillus (AFB) sputum smears were negative, as was the sputum Gene Xpert testing for rifampin resistance. Repeat paracentesis found an elevated adenosine deaminase (114.4 U/L), consistent with TB. Given concern for active TB, the patient was started on empiric rifampin, isoniazid, pyrazinamide, ethambutol (RIPE) therapy for peritoneal TB, after which the patient defervesced and remained afebrile. Although isolated TB peritonitis is very rare, blood and sputum cultures were negative, and no other sources of infection were identified. Three weeks after hospital discharge, the AFB culture from ascitic fluid became positive for growth of *Mycobacterium tuberculosis*. Based on the susceptibility profile, RIPE therapy was de-escalated to isoniazid and rifampin.

## Discussion

This case illustrates peritoneal TB in an immunocompetent patient with no known socioeconomic or behavioral risk factors. He also had no known medical risk factors that increase the chance of developing peritoneal TB, including cirrhosis, HIV infection, diabetes mellitus, cancer, treatment with anti-tumor necrosis factor agents, or the use of peritoneal dialysis.<sup>3</sup>

The only identifiable risk factor for TB is that the patient lives in the Bronx. In 2020, the New York City (NYC) TB incidence rate was 5.1 per 100 000, which is more than 2

times higher than the national TB rate. Among the boroughs of NYC, the Bronx had the second highest incidence rate of 5.5 per 100 000, with Queens having the highest rate at 7.3 per 100 000.<sup>4</sup> The high incidence rate is likely multifactorial and includes crowded living spaces, large immigrant communities, and lower socioeconomic status.<sup>5</sup>

Peritoneal TB is difficult to diagnose due to its insidious nature and varying clinical features. Common symptoms include abdominal pain, fever, and weight loss which are non-specific. Ascitic fluid analysis usually shows lymphocytic predominance with SAAG below 1.1 g/dL. Diagnostic gold standard is the *Mycobacterium* culture from ascitic fluid samples or peritoneal biopsy specimen. However, the sensitivity of AFB smear and mycobacterial cultures in ascitic fluid for diagnosing peritoneal TB is ~3% and <20%, respectively.<sup>6-8</sup> Furthermore, these tests are not appropriate for prompt diagnosis because they typically require more than 3 to 4 weeks of incubation. There are limited studies establishing the yield of ascitic fluid GeneXpert *Mycobacterium tuberculosis/resistance* to rifampicin (MTB/RIF) for diagnosis of peritoneal TB, although some studies showed that sensitivity is poor from 4% to 28%.<sup>9-11</sup> Although peritoneal biopsy can be diagnostic in up to 95% of cases and pathologies revealing caseating granulomas have almost 100% sensitivity,<sup>2,11</sup> it holds inherent procedural risks.

Multiple studies have shown that measurement of adenosine deaminase (ADA) can assist in the diagnosis of peritoneal TB. ADA level above 30 U/L is known to have a sensitivity of 94% in diagnosing peritoneal TB.<sup>7</sup> In a meta-analysis of 12 prospective studies, it was shown that by using cut-off values between 36 and 40 U/L, with an optimal value of 39 U/L, ADA levels had a 100% sensitivity and 97% specificity in diagnosing peritoneal TB.<sup>12</sup>

Reaching the final diagnosis for this case was challenging as TB was not high on the differential due to lack of appreciable risk factors. Given its high mortality, early diagnosis and

initiation of treatment are essential. Our case highlights the importance for clinicians to consider peritoneal TB in patients with lymphocytic ascites with an SAAG of  $<1.1$  g/dL. Although the United States does experience a low rate of TB, there are communities with significant prevalence based on multiple risk factors. Furthermore, in cases where definitive diagnosis of TB is difficult, elevated ascitic fluid ADA may be helpful in initiating prompt treatment while awaiting culture results and helping to avoid invasive peritoneal biopsy.

### Authors' Note

Prior Presentation of Abstract Statement: Abstract was presented at the American College of Gastroenterology Annual Scientific Meeting from October 21 to 26 in Charlotte, North Carolina.

### Declaration of Conflicting Interests

The author(s) declared no potential conflicts of interest with respect to the research, authorship, and/or publication of this article.

### Funding

The author(s) received no financial support for the research, authorship, and/or publication of this article.

### Ethics Approval

Our institution does not require ethical approval for reporting individual cases or case series.

### Informed Consent

Written informed consent was obtained from the patient for their anonymized information to be published in this article.

### References

1. Centers for Disease Control and Prevention. TB incidence in the United States, 1953-2014. Published 2014. Accessed November 22, 2022. <http://www.cdc.gov/tb/statistics/tbcases.htm>
2. Chow KM, Chow VC, Szeto CC. Indication for peritoneal biopsy in tuberculous peritonitis. *Am J Surg*. 2003;185(6):567-573.
3. Leonardo FJ, Diana MP. Tuberculosis: a risk factor approach. In: Ntumba JK, ed. *Tuberculosis*. IntechOpen; 2018. doi: 10.5772/intechopen.73538
4. New York City Department of Health and Mental Hygiene. Bureau of Tuberculosis Control Annual Summary. Published 2020. Accessed November 22, 2022. [https://www.health.ny.gov/statistics/diseases/communicable/tuberculosis/docs/2020\\_annual\\_report.pdf](https://www.health.ny.gov/statistics/diseases/communicable/tuberculosis/docs/2020_annual_report.pdf)
5. Shakil AO, Korula J, Kanel GC, Murray NG, Reynolds TB. Diagnostic features of tuberculous peritonitis in the absence and presence of chronic liver disease: a case control study. *Am J Med*. 1996;100(2):179-185.
6. Drucker E, Alcabes P, Bosworth W, et al. Childhood tuberculosis in the Bronx, New York. *Lancet*. 1994;343(8911):1482-1485. doi:10.1016/s0140-6736(94)92588-7
7. Marshall JB. Tuberculosis of the gastrointestinal tract and peritoneum. *Am J Gastroenterol*. 1993;88(7):989-999.
8. Sanai FM, Bzeizi KI. Systematic review: tuberculous peritonitis—presenting features, diagnostic strategies and treatment. *Aliment Pharmacol Ther*. 2005;22:685-700.
9. Rufai SB, Singh S, Singh A, Kumar P, Singh J, Vishal A. Performance of Xpert MTB/RIF on ascitic fluid samples for detection of abdominal tuberculosis. *J Lab Physicians*. 2017;9(1):47-52.
10. Ahmad R, Changeez M, Khan JS, et al. Diagnostic accuracy of peritoneal fluid GeneXpert in the diagnosis of intestinal tuberculosis, keeping histopathology as the gold standard. *Cureus*. 2018;10:3451-3454.
11. Manohar A, Simjee AE, Haffjee AA, Pettengell KE. Symptoms and investigative findings in 145 patients with tuberculous peritonitis diagnosed by peritoneoscopy and biopsy over a five year period. *Gut*. 1990;31(10):1130-1132.
12. Riquelme A, Calvo M, Salech F, et al. Value of adenosine deaminase (ADA) in ascitic fluid for the diagnosis of tuberculous peritonitis: a meta-analysis. *J Clin Gastroenterol*. 2006;40(8):705-710.