

Isolated third nerve palsy: A rare presentation of high grade glioma

Deepak Kumar Singh, Neha Singh¹, Ragini Singh¹

Department of Neurosurgery, Dr. Ram Manohar Lohia Institute of Medical Sciences, ¹Department of Radiodiagnosis and Imaging, King George's Medical University (Erstwhile CSMMU), Lucknow, Uttar Pradesh, India

ABSTRACT

High grade gliomas account for almost one-third of primary central nervous system neoplasm, mainly in adults with a mean age of 41 years. They usually present with symptoms of raised intracranial pressure such as headache, vomiting, and seizures. We report a case of 55-year-old male presenting with right side complete third nerve palsy. Magnetic resonance imaging revealed an intraaxial tumor of the right medial temporal lobe. The tumor was removed grossly, and the histological diagnosis was anaplastic astrocytoma (WHO grade 3). We discuss clinical presentation of this case along with pertinent literature.

Key words: Glioma, isolated third nerve palsy, ptosis, temporal lobe tumor

Introduction

Isolated nonpupil sparing third nerve paresis indicates extraaxial compressive lesions such as posterior communicating artery (PCommA) aneurysm, pituitary tumors with extension into cavernous sinus, or clival tumors. Supratentorial gliomas commonly present with seizures, headache, auditory, visual hallucination, and behavioral disturbances.^[1] Isolated third nerve paresis alone is very rare both as an early sign and in the advanced stage of supratentorial intraaxial gliomas. A review of literature identified only three cases of gliomas presenting with isolated complete ipsilateral third nerve paresis.^[2-4] We are reporting an unusual case of high grade glioma presenting as isolated complete third nerve paresis.

Case Report

A 55-year-old male patient presented with a history of double vision in right lateral gaze for 1 month and drooping of the right

eyelid for 15 days. There is no history of significant headache, vomiting, or weight loss. The neuro-ophthalmological assessment showed a best corrected visual acuity of 0.8 in both eyes. The right eye exhibited a complete palpebral ptosis with exotropia of -50 prismatic dioptres [Figure 1]. Right eye exhibited a severe limitation of supraductions, adduction, and infraduction with preservation of abduction. Right pupil was in middle midriasis and did not respond to direct and consensual light reflex. The left eye was completely normal on evaluation. The fundus assessment of both eyes did not reveal pathological alteration and rest of neurological examination was unremarkable.

Routine blood investigations including biochemical profile, blood count, thyroid function, and vasculitis screen were normal or negative. Computed tomography revealed a mildly enhancing space occupying lesion in the right medial temporal lobe. The magnetic resonance imaging revealed an intraaxial mass lesion in right medial temporal lobe and uncus. The mass lesion was extending into the cavernous sinus and right crural cistern and compressing the right cerebral peduncle. It was displaying signal intensities, hyperintense to cerebrospinal fluid (CSF) on T1 and T2-fluid attenuation inversion recovery sequences, and hypointense to CSF on T2 sequences with poor

Access this article online	
Quick Response Code:	Website: www.asianjns.org
	DOI: 10.4103/1793-5482.175645

Address for correspondence:

Dr. Deepak Kumar Singh, Department of Neurosurgery, Dr. Ram Manohar Lohia Institute of Medical Sciences, Lucknow, Uttar Pradesh, India.
E-mail: gkp.deepak@gmail.com

This is an open access article distributed under the terms of the Creative Commons Attribution-NonCommercial-ShareAlike 3.0 License, which allows others to remix, tweak, and build upon the work non-commercially, as long as the author is credited and the new creations are licensed under the identical terms.

For reprints contact: reprints@medknow.com

How to cite this article: Singh DK, Singh N, Singh R. Isolated third nerve palsy: A rare presentation of high grade glioma. Asian J Neurosurg 2016;11:171-2.

gadolinium contrast enhancement [Figures 2 and 3]. There was no restriction on diffusion weighted images. Based on radiological findings, a diagnosis of high grade glioma was made, and the patient was prepared for surgery.

The patient was operated under general anesthesia. A right temporal craniotomy was done, and gross total excision was achieved through transsylvian approach. The tumor was soft, suck able, and pink-greyish in appearance and was not attached to dura on any point. Tumor borders were ill-defined on cranial and lateral aspect. Tumor was infiltrating the lateral wall of right cavernous sinus and was markedly adherent to right third nerve, cerebral peduncle, and perforators of right PComMA. A gross total excision was achieved using microneurosurgical techniques.

Histopathological examination showed increased cellularity of atypical astrocytes with pleomorphism and high nuclear/cytoplasmic ratio. There was no evidence of necrosis or vascular proliferation. Immunohistochemical findings revealed a strong positivity to glial fibrillary acidic protein with MIB-1 staining index of 40%. Based on histopathological findings [Figure 4], a diagnosis of anaplastic astrocytoma (WHO grade 3) was made, and the patient was referred to radiotherapy department for adjuvant chemo-radiotherapy.

The patient was doing well at 2 months postoperative follow-up, but there was no improvement in the right third nerve paresis.

Discussion

The differential diagnosis of unilateral nonpupil sparing third nerve immediately raises concern for a compressive

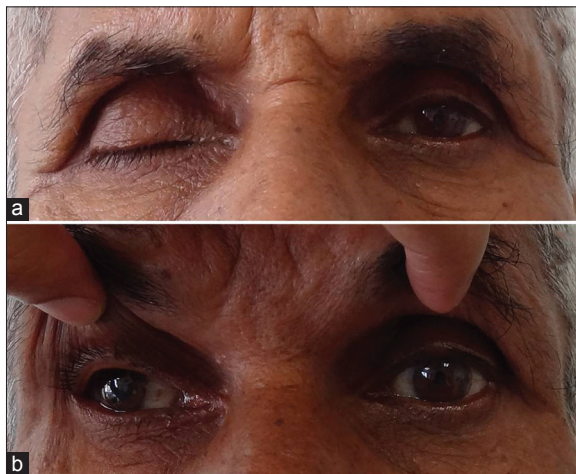

Figure 1: Clinical image of patient showing drooping of right eyelid (a) the right pupil is dilated and deviated laterally (b)

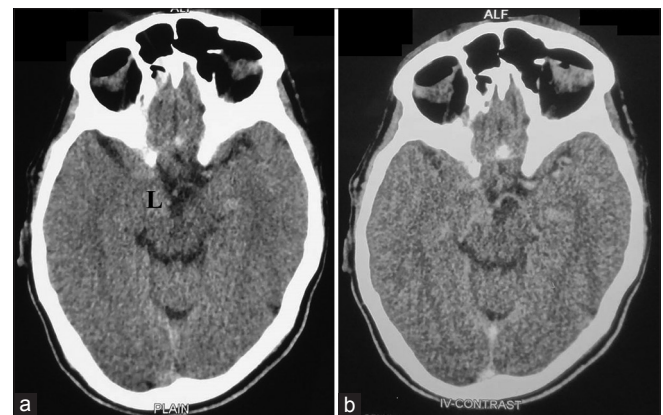


Figure 2: plain (a) and postcontrast (b) axial computed tomography images of the patient showing a mildly enhancing mass lesion (L) involving right medial temporal region and uncus

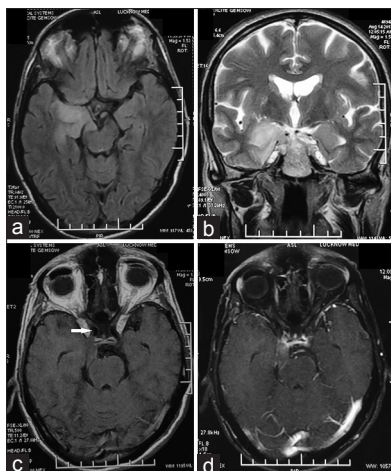


Figure 3: Magnetic resonance imaging brain axial images show an ill-defined lesion hyperintense on T2-fluid attenuation inversion recovery (a) and T2-weighted image (b) and hypointense on the T1-weighted image (c) involving right medial temporal lobe and uncus. The lesion is extending in crural cistern with compression over right cerebral peduncle. Mild enhancement is noted on the postcontrast T1-weighted image. (d) Extension in the cavernous sign is also noted (arrow)

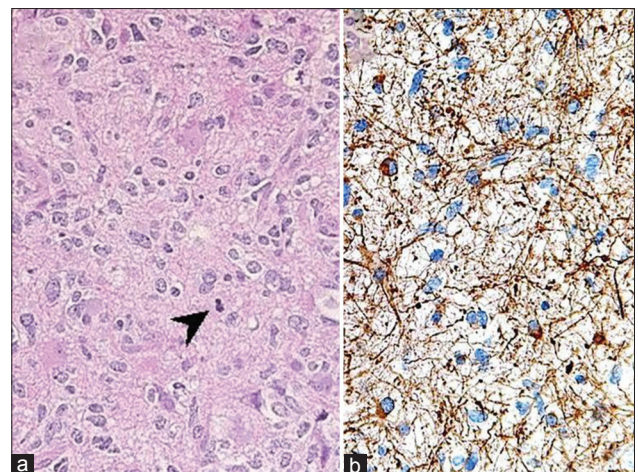


Figure 4: Microphotograph shows (a) nuclear atypia with elongated nuclei and increased mitoses (arrow head). There is a marked absence of necrosis and vascular proliferation. (b) Tumor cells are strongly positive to glial fibrillary acidic protein on immunostaining

lesion. The most common offender is an expanding aneurysm, however, third nerve tumors, uncal herniation, and mass lesions of the cavernous sinus can also produce a nonpupil sparing third nerve palsy. Approximately, 90% of cases of aneurysmal third nerve palsy are due to a PComMA aneurysm; the remaining 10% of cases are due to aneurysms of the cavernous portion of the internal carotid artery or basilar tip, particularly superior cerebellar artery aneurysms.^[5]

Isolated nonpupil sparing third nerve palsy is very rare as a presenting sign in intraaxial tumors. A review of the literature revealed only three cases of high grade gliomas presenting as complete third nerve paresis.^[2-4] The most likely mechanism of oculomotor nerve paresis seems to be from the direct compression by the tumor. In our case, the tumor was directly compressing the third nerve and was markedly adherent to it. Another possible mechanism is direct invasion of third nerve by the tumor. Al-yamany *et al.* described a case of isolated third nerve palsy due to its leptomeningeal invasion before entry into cavernous sinus.^[4] One case of primary glioblastoma of third nerve was reported by Reifenberger *et al.*, postmortem examination of which revealed an extraparenchymal tumor, which completely destroyed the third nerve and infiltrated the surrounding structures superficially.^[6]

Conclusion

We presented a case of high grade glioma (WHO grade 3) with an unusual clinical presentation in the form of isolated third nerve palsy and suggest that in a case of complete third nerve palsy the differential diagnosis should always include a tumor of the temporal lobe.

Financial support and sponsorship

Nil.

Conflicts of interest

There are no conflicts of interest.

References

1. See SJ, Gilbert MR. Anaplastic astrocytoma: Diagnosis, prognosis, and management. *Semin Oncol* 2004;31:618-34.
2. Tanaka K, Sasayama T, Kawamura A, Kondoh T, Kanomata N, Kohmura E. Isolated oculomotor nerve paresis in anaplastic astrocytoma with exophytic invasion. *Neurol Med Chir (Tokyo)* 2006;46:198-201.
3. Sharma K, Kanaujia V, Lal H, Jaiswal S, Jaiswal AK. Isolated oculomotor nerve palsy: An unusual presentation of temporal lobe tumor. *Asian J Neurosurg* 2010;5:70-2.
4. Al-Yamany M, Al-Shayji A, Bernstein M. Isolated oculomotor nerve palsy: An unusual presentation of glioblastoma multiforme. Case report and review of the literature. *J Neurooncol* 1999;41:77-80.
5. Keane JR. Aneurysms and third nerve palsies. *Ann Neurol* 1983;14:696-7.
6. Reifenberger G, Boström J, Bettag M, Bock WJ, Wechsler W, Kepes JJ. Primary glioblastoma multiforme of the oculomotor nerve. Case report. *J Neurosurg* 1996;84:1062-6.