



Biliary atresia and congenital disorders of the extrahepatic bile ducts

Ali Islek, Gokhan Tumgor

Specialty type: Gastroenterology and hepatology

Provenance and peer review: Invited article; Externally peer reviewed.

Peer-review model: Single blind

Peer-review report's scientific quality classification

Grade A (Excellent): 0
Grade B (Very good): 0
Grade C (Good): C, C
Grade D (Fair): 0
Grade E (Poor): 0

P-Reviewer: Khera PS, India; Vij M, India

A-Editor: Sarma MS, India

Received: January 15, 2022

Peer-review started: January 15, 2022

First decision: March 8, 2022

Revised: March 10, 2022

Accepted: June 13, 2022

Article in press: June 13, 2022

Published online: July 5, 2022



Ali Islek, Gokhan Tumgor, Department of Pediatric Gastroenterology, Cukurova University School of Medicine, Adana 01320, Turkey

Corresponding author: Gokhan Tumgor, MD, Professor, Department of Pediatric Gastroenterology, Cukurova University School of Medicine, Balcali, Adana 01320, Turkey.
gtumgor74@yahoo.com

Abstract

Biliary atresia (BA) and choledochal cysts are diseases of the intrahepatic and extrahepatic biliary tree. While their exact etiopathogeneses are not known, they should be treated promptly due to the potential for irreversible parenchymal liver disease. A diagnosis of BA may be easy or complicated, but should not be delayed. BA is always treated surgically, and performing the surgery before the age of 2 mo greatly increases its effectiveness and extends the time until the need for liver transplantation arises. While the more common types of choledochal cysts require surgical treatment, some can be treated with endoscopic retrograde cholangiopancreatography. Choledochal cysts may cause recurrent cholangitis and the potential for malignancy should not be ignored.

Key Words: Biliary atresia; Choledochal cyst; Cholestasis; Conjugated hyperbilirubinemia

©The Author(s) 2022. Published by Baishideng Publishing Group Inc. All rights reserved.

Core Tip: Biliary atresia (BA) and choledochal cysts are diseases that cause obstructive cholestasis. While the diagnosis of BA can be rather complicated, it should be made as early as possible and treated with a Kasai hepatoportoenterostomy before the age of 2 mo for a good prognosis. All patients with persistent acholic stool and elevated gamma-glutamyl transferase should be evaluated for BA, although normal ultrasonography will not rule out BA, and such patients are candidates for intraoperative cholangiography. Choledochal cysts can present symptoms at any age, and as recurrent cholangitis attacks will lead to chronic liver disease with potential malignancy, treatment and long-term follow-up are essential.

Citation: Islek A, Tumgor G. Biliary atresia and congenital disorders of the extrahepatic bile ducts. *World J Gastrointest Pharmacol Ther* 2022; 13(4): 33-46

URL: <https://www.wjgnet.com/2150-5349/full/v13/i4/33.htm>

DOI: <https://dx.doi.org/10.4292/wjgpt.v13.i4.33>

INTRODUCTION

Jaundice develops as a result of excessive bilirubin production, a decrease in its excretion, or both. An increase in the conjugated bilirubin fraction is observed in cholestatic patients. Conjugated and direct bilirubin are often treated as synonyms, although direct hyperbilirubinemia is the sum of conjugated bilirubin and delta bilirubin, and an increase in both results in jaundice[1]. Conjugated (direct) hyperbilirubinemia is defined as serum conjugated bilirubin > 1 mg/dL when total bilirubin is < 5 mg/dL, or when serum conjugated bilirubin accounts for > 20% of the total bilirubin when the total bilirubin is > 5 mg/dL. All infants with direct bilirubin levels of > 1 mg/dL, however, should be evaluated for cholestasis[2]. Biliary atresia (BA) and choledochal cysts are known to cause obstructive jaundice, and conjugated hyperbilirubinemia will be observed. Jaundice develops in the first weeks of life in BA, whereas in choledochal cysts, it may develop at any time during infancy or childhood, or may be recognized incidentally. In both cases there is an indication for surgery or endoscopic retrograde cholangiopancreatography (ERCP)[3,4]. The present study opens a discussion on BA and choledochal cysts.

BILIARY ATRESIA

BA is characterized by progressive fibro-obliteration and destruction of the intrahepatic and/or extrahepatic bile ducts in the neonatal period, and is the most common cause of cholestasis in infants. If left untreated, it quickly advances to biliary cirrhosis and death[3]. In the 1950s, with the development of Kasai portoenterostomy by Dr. Morio Kasai, it became possible to treat BA surgically, although early diagnosis and treatment increase the effectiveness of surgery[5]. BA is the most common indication for liver transplantation (LT) in childhood, which can be performed successfully if surgical treatment fails or decompensated cirrhosis develops[6].

Epidemiology

Different frequencies of BA have been reported in different geographical regions, reported as 22371 live births in North America[7], 17049 live births in the United Kingdom[8], 18400 live births in France[9], 1.06 cases *per* 10000 live births in Korea[10], 9640 live births in Japan[11] and 1.7–1.85 *per* 10000 live births in Taiwan[12], with a greater incidence in rural locations than in urban areas reported. The reason for the higher incidence in the East than in the West is unknown, although different studies have suggested that ethnicity may play a role and that an association with human leukocyte antigen (HLA) molecules exists, suggesting that the dominant HLA molecule in a population is correlated with BA[13].

Clinical phenotypes

BA has been identified in embryonic or syndromic, and perinatal or non-syndromic forms, the latter of which accounts for more than two-thirds of all cases. The perinatal, or non-syndromic, type is generally not accompanied by other anomalies, although the association of the embryonic or syndromic type with multiple anomalies is more common (Table 1)[14]—the most common being situs inversus and intra-abdominal vascular anomalies, in addition to BA with splenic malformation (BASM) syndrome. In an earlier study by the author involving 59 BA patients, BASM was identified in seven (11%) cases, with the most common associated anomalies being midgut malrotation (in all patients), polysplenia/asplenia (in four and one patient) and preduodenal portal vein (in five patients)[15].

In a third clinical form or variant of BA, an extrahepatic cyst similar to a choledochal cyst accompanied by a fibrosing obstruction has been described, which has been reported in studies to account for 5%–10% of the total BA[16]. In all forms, bile duct proliferation and portal fibrosis are common histological features and are not distinctive[17], although a cholangiogram may reveal features specific to each form[18].

Clinical features

BA with extrahepatic cysts can be identified early with antenatal ultrasonography. Indirect findings can also be observed through antenatal ultrasonography in species with BASM[19], with the first symptom being jaundice (conjugated hyperbilirubinemia)[20]. In the embryonal type, jaundice is noticeable at birth, that is, there is no jaundice-free interval, while in the postnatal type, the physiological jaundice is followed by conjugated hyperbilirubinemia. Jaundice lasting more than 2 wk is always pathological and should be investigated. A greenish-yellow color is observed in conjugated hyperbilirubinemia, and is unlikely to occur after 8 wk. Acholic stool and dark urine usually accompany jaundice, with acholic stool usually presenting at 2 wk of age that is almost indisputable at one month of age[21]. The color of the stool may sometimes be light and not definitely acholic, and the recognition of acholic stool by parents may be delayed if the diaper is stained with dark urine.

Familial transmission is unlikely in BA. In our case series, we found the rate of consanguineous marriage to be higher in cholestatic cases not linked to BA (mostly idiopathic neonatal cholestasis) than in those with BA (56% *vs* 24%)[22]. Babies with BA are usually term and of normal birth weight. In the most common perinatal type, weight gain is normal in the first weeks, but begins to decrease in

Table 1 Associated anomalies of embryonic or syndromic biliary atresia

Origin of anomaly	Description
Splenic anomalies	Asplenia, double splen, polysplenia
Cardiovascular anomalies	Interrupted/absent inferior vena cava, dextrocardia, left atrial isomerism, other cardiac anomalies (pulmonary stenosis, ASD, VSD, PDA, total anomalous pulmonary venous return, coarctation of the aorta, TOF, hypoplastic left heart syndrome)
Portal vein and hepatic artery anomalies	Predudodenal portal vein, anomaly originated hepatic artery
Abdominal anomalies	Situs inversus, midgut malrotation, intestinal atresia (esophageal, duodenal or jejunal), anular pancreas, short pancreas
Renal anomalies	Renal agenesis, hypoplastic or polycystic kidneys
Other uncommon anomalies	Primary ciliary dyskinesia, caudal regression syndrome

ASD: Atrial septal defect; PDA: Patent ductus arteriosus; TOF: Tetralogy of Fallot; VSD: Ventricular septal defect.

untreated patients. Bleeding may occur due to vitamin K malabsorption; hepatomegaly and splenomegaly are signs of cirrhosis and portal hypertension, and ascites will be observed in decompensated cases[20].

Pathogenesis

The pathogenesis of BA is not yet fully known, although it has been suggested that it may stem from abnormalities in the duct morphogenesis, or genetic or postnatal factors that lead to progressive fibro-obliteration in the duct morphology (while the bile duct tree is present at birth)[23].

Defect in morphogenesis

The coexistence of other organ anomalies in the embryonal type of BA suggests the presence of an abnormality in the embryonal development process. Bile ducts emerge as a result of a series of processes in which the fetal ductal plate is remodeled at the level of the intrahepatic bile ducts of the porta hepatis. If there is a failure in the remodeling, a ductal plate malformation (DPM) develops with fetal configurations in the intrahepatic bile ducts. DPM has also been described in extrahepatic BA[24], with suggestions that ducts are present in morphogenesis, but lack periductular mesenchymal tissue support, with bile leakage causing inflammation and progressive ductal fibro-obliteration. Whether inflammation is a cause or an effect, however, is unknown.

Viral infections

Previous data indicating that diagnoses of BA in infants are seen more frequently in the autumn and spring suggest that a viral agent may be behind the development of BA in the perinatal period. No association has been identified with hepatitis A, B or C, or Rubella. Cytomegalovirus (CMV), Reovirus and Rotavirus are the most studied viruses. In a study conducted in a developed nation, the high CMV seroprevalence of mothers of infants with BA and the detection of CMV DNA in the hepatocytes suggested that CMV may play a role in the pathogenesis[25], while a further study identified no CMV DNA in the porta hepatis specimens of a group of patients with BA[26], meaning that further studies of the role of CMV are required.

Reovirus type 3 and group C rotavirus have been shown to cause fibro-obliterative cholangiopathy in several experimental studies, although any relationship between these viruses and BA in humans has yet to be proven[27,28].

Environmental toxins

After an outbreak of BA in lambs and calves in Australia, it was concluded that BA had developed in the offspring of pregnant animals exposed to certain environmental toxins. In experiments, an isoflavonoid named biliatresone, isolated from the *Dysphania* plant in the epidemic region of Australia was found to cause a loss of cilia in cholangiocytes, and was associated with bile duct injury[29]. BA in pregnant women has not been linked to any known environmental toxin exposure.

Maternal microchimerism

Previous studies have associated immunodysregulation with BA, and it has been suggested that maternal microchimerism plays a role in its pathogenesis. There have also been studies specifying an increased number of maternal cells in the sinusoids and portal areas of patients with BA, and another suggesting the presence of a graft-versus-host disease caused by engrafted maternal effector T lymphocytes[30]. There may be particular factors causing the second hit, however further studies will be needed to clarify this issue.

Genetic factors

The absence of Mendelian inheritance in the postnatal type and the presence of an unaffected sibling by BA in monozygotic twins suggest an absence of genetic origin in this type. It has been suggested, however, that genetic factors may play a role in the etiology of the embryonal type, accompanied by other congenital anomalies. Studies have identified different gene loci, although it cannot be said with any certainty that they cause BA alone. The *CFC1* gene encodes the cilium-associated protein inversin and the cryptic protein that provide signaling during embryonic development. PKD1L1 encodes Polycystin 1 Like 1 and regulates cilier functions, and both gene defects are associated with visceral heterotaxy. Heterozygous *CFC1* and PKD1L1 mutations have been determined in some patients with BASM[31,32]. *XPNPEP1* (mediates the metabolism of inflammatory mediators in epithelial cells) and *ADD3* (plays a role in the spectrin-actin network in the biliary tract) mutations have been observed in some patients with BA[33]. The genes associated with other diseases have also been found in patients with BA, including *JAG1* (Alagille syndrome), *MYO5B* (microvillus inclusion disease), *ABCC2* (Dubin-Johnson syndrome), *ABCB11* (PFIC type 2), *UG1A1* (Crigler-Najjar syndrome), *MLL2* (Kabuki syndrome), *RFX6* (Mitchell-Riley syndrome), *ERCC4* (Fanconi anemia) and *KCNH1* (Zimmermann-Laband syndrome)[34].

Diagnosis

The early recognition of BA is important for the effectiveness of surgery, although centers follow different diagnostic algorithms based on their own experience. Diagnosing the disease as early as possible and performing the Kasai procedure before 2 mo of age (especially before 30–45 d) increases the effectiveness of the procedure and delays LT[5]. The average age at which the Kasai procedure is performed, however, usually exceeds 2 mo. In an earlier study by the author, the parents of patients diagnosed with BA noticed jaundice on the postnatal 11th day, although the average age at which patients are referred to us as a tertiary hospital is 58 d[35], due primarily to the similarity of the symptoms to common benign causes, such as physiological jaundice or breast milk jaundice. It may also be missed in well-baby visits, as jaundice may not be visible in the first days of life. The European Society for Paediatric Gastroenterology Hepatology and Nutrition and the North American Society for Pediatric Gastroenterology, Hepatology and Nutrition (NASPGHAN) recommend the evaluation of total and direct serum bilirubin in newborns whose jaundice persists after 2 wk of age, and the referral of those with high serum direct bilirubin levels (direct bilirubin levels > 1.0 mg/dL or > 17 mmol/L) to a pediatric gastroenterologist or hepatologist[2]. A physical examination can thus be considered an important screening test, and so looking for signs of cholestatic jaundice during well-baby and vaccination visits by primary healthcare givers is advised.

Being a common disease, BA screening tests have been developed to extend the transplant-free period through early diagnosis and treatment. BA meets the requirements for inclusion in the newborn screening program[35]. One screening method involves the use of a stool color card, with a card carrying photos of normal and pale stools being given to the parents who are advised to contact their healthcare providers upon encountering an abnormal stool color. Stool color may also be discussed with healthcare providers during the 1st-month well-baby visit. Stool color tests were first applied in Japan and Taiwan. In Japan, the sensitivity, specificity, positive predictive value (PPV) and negative predictive value (NPV) of the test have been reported to be 76.5%, 99.9%, 12.7% and 99.9%, respectively, in the 1st month[21]; while in Taiwan, the sensitivity, specificity, PPV and NPV of the test at 2 mo is reported to be 89.7%, 99.9%, 28.6% and 99.9%, respectively[12]. Since the age of performing a Kasai operation with the screening test in these two countries has shortened significantly when compared to the pre-screening test (59.7 d *vs* 70.3 d in Japan, and 48.2 d *vs* 59.9 d in Taiwan) countries[35] such as Germany, Canada, Switzerland and Brazil have also started to implement this screening program. The main advantage of the stool color card method is its non-invasive nature. In a few studies in which a serum/plasma conjugated bilirubin measurement approach is applied, as an alternative method, the sensitivity and specificity of high conjugated bilirubin levels in predicting BA have been reported as 100% and 99.9%, respectively[36,37]. While this method can also facilitate the early diagnosis of other liver diseases associated with direct bilirubinemia, there are such disadvantages as its invasive nature, and uncertainties of its cost-effectivity and which thresholds to use. There have been studies identifying cholic acid and chenodeoxycholic acid in dried blood specimens[38,39] and urinary oxysterols[40] as potential markers in the screening of BA, although these metabolic products need to be tested in prospective studies.

There is no single test for the diagnosis of BA. As in all diseases, family history and birth characteristics should first be questioned as a family history of cholestasis and preterm birth suggest neonatal hepatitis rather than BA. Unlike metabolic diseases, infants with BA appear well unless cirrhosis develops, and vomiting/feeding intolerance is not expected. Despite conjugated hyperbilirubinemia, pruritus is uncommon in BA. Acholic stool may initially be absent and some stools may contain bile pigment, although acholic stool may also be observed in neonatal hepatitis, but as fibroobliteration progresses in BA, acholic stool persists. Persistent pigmented stool is not an expected finding in BA[20]. Transaminases and gamma-glutamyl transferase (GGT) are almost always elevated in BA, and GGT is disproportionately higher than transaminases, while this is opposite in neonatal hepatitis. GGT

continues to rise over time. In one study, the mean GGT levels in infants aged < 2, 2–3 and 3–4 mo were recorded as 371.6, 600.5 and 697.2 respectively[41].

Ultrasound is widely used for the evaluation of the biliary tract and liver, and the sonographic findings of patients with BA are gall bladder absence, hypoplastic gall bladder, triangular sign, absence of gallbladder contractility after feeding, and polysplenia and vascular anomalies in syndromic types [42]. Most, but not all of those with BA have a hypoplastic or absent gallbladder, and so normal ultrasonography does not exclude BA. Absence of gallbladder results are variable and may occur in 0%–53% of cases. Previous studies have reported a triangular sign to be more sensitive (58%–100%) and specific (83%–100%) for the prediction of BA, while others say report gallbladder abnormalities (short, lack of lumen) to be more sensitive (50%–100%) and specific (82%–95%)[43]. There are reports of 100% sensitivity and NPV in the identification of BA together with gallbladder anomalies and GGT[44]. In our series, GGT, pale stool and abnormal ultrasonography had maximum sensitivity and PPV (sensitivity and PPV were both 95%, diagnostic accuracy 70%)[22].

Hepatobiliary scintigraphy has been used for the diagnosis of BA. The passage of the radionuclide into the intestine is a good finding in excluding BA, although an absence of intestinal transit in hepatobiliary scintigraphy can also be seen in intrahepatic cholestasis besides BA. In a recent meta-analysis, the sensitivities and specificities of hepatobiliary scintigraphy were reported to be 84%–100% and 35%–93%, while PPV was 64.5% and NPV was 97.2%[45]. In some centers, phenobarbital is used for 5 days prior to examination to increase the sensitivity, although hepatobiliary scintigraphy may delay a diagnosis, leading some centers to exclude hepatobiliary scintigraphy from their BA diagnostic algorithm[20].

Magnetic resonance cholangiopancreatography (MRCP) is a non-invasive imaging method that is used for selective biliary imaging. In the diagnosis of BA, the sensitivity and specificity of MRCP have been reported as 85%–100% and 36%–96%, respectively. Previous studies have reported that MRCP and ultrasonography had better sensitivity and specificity[23,45].

It is not easy to diagnose BA through solely non-invasive methods. Extrahepatic bile ducts can be visualized with ERCP with high sensitivity (86%–100%) and specificity (79%–94%), and with high PPV (88%–96%) and NPV (100%)[46,47], although the procedure requires an experienced endoscopist and a neonatal duodenoscope, which very few centers keep. In a large patient-series study, the success of the ERCP technique was reported to be 89.2%[46].

Among the histopathological findings of BA are duct/ductular bile plugs, ductular reaction and bile duct proliferation, portal stromal edema, marked portal fibrosis, pseudorosette formation, peribiliary neutrophilic infiltrates and interlobular bile duct injury (Figure 1). Giant cell transformation may be observed in BA, but not as intense as in neonatal hepatitis[48]. A multicenter study concluded that duct/ductal bile plugs and portal stromal edema were the strongest independent histologic predictors of obstruction[17]. The sensitivity and specificity of histological findings are over 90%, although histopathological findings similar to those seen in BA may also be observed with other neonatal cholestasis diseases [such as alpha 1 antitrypsin deficiency, progressive familial intrahepatic cholestasis (PFIC), cystic fibrosis], though not necessarily in the early period[49,50]. The absence of an extrahepatic biliary tree in intraoperative cholangiography is, therefore, the leading indicator of BA[2]. In our center, where the pathological differential diagnosis of cholestasis cannot be sufficiently performed, suspected BA cases are referred immediately to the pediatric surgery department for intraoperative cholangiography in the early period. As a result, 68% of cases undergoing intraoperative cholangiography were diagnosed with BA and underwent the Kasai procedure[22]. This procedure can also be carried out laparoscopically[51]. If BA is confirmed, the Kasai procedure can be performed in the same session or in a second session. If extrahepatic bile ducts are present, a liver biopsy is taken and the procedure is terminated.

While performing all these diagnostic procedures, we recommend each center use the procedures they are most experienced with to make the diagnosis as early as possible and to avoid any delay.

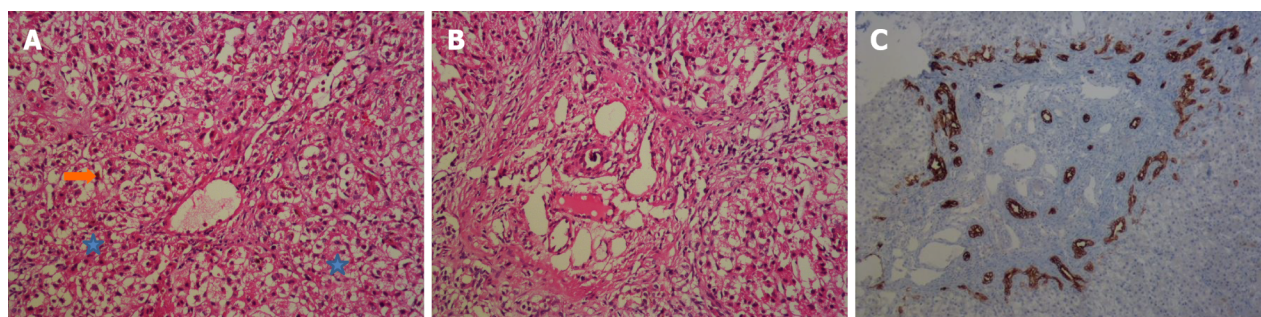
In recent years there have been studies reporting the high sensitivity and specificity (> 90%) of serum matrix metalloproteinase-7 as a biomarker for the diagnosis of BA[52,53].

Differential diagnosis

As several diseases can cause neonatal cholestasis, efforts should focus both on the identification of BA and the exclusion of other diseases.

Choledochal cysts: Infants with choledochal cysts sometimes present with cholestasis. Generally, ultrasonography is sufficient to distinguish choledochal cysts from BA, although it may be difficult to identify the cystic dilated BA form, and so other diagnostic tests can be performed.

Alagille syndrome: This is a cholestatic disease that is characterized by bile duct paucity, and that can be difficult to recognize in the neonatal period. A typical facial appearance (prominent forehead, deep-set eyes, pointed chin and straight nose), and ocular, cardiac, renal and skeletal anomalies may accompany. In Alagille, GGT can reach very high values. If a differential diagnosis is difficult, a liver biopsy can be performed before resorting to intraoperative cholangiography. Bile duct proliferation is a prominent feature in BA, while bile duct paucity is present in Alagille[54].



DOI: 10.4292/wjgpt.v13.i4.33 Copyright ©The Author(s) 2022.

Figure 1 Liver biopsy of a patient with biliary atresia. A: Cholestasis (arrow) and ballooning degeneration (asterisks) (hematoxylin-eosin, magnification × 100); B: Portal fibrosis (hematoxylin-eosin, magnification × 100); C: Bile duct proliferation (Cytokeratin 19, magnification × 100).

PFIC

PFIC 1-2 is the cause of cholestasis when GGT is normal, while PFIC-3 is the cause of cholestasis with high GGT. Persistent acholic stool is not an expected finding in PFIC-3[55].

Cystic fibrosis

Cystic fibrosis may cause neonatal cholestasis, and GGT may increase in cystic fibrosis. Persistent acholic stool is not an expected finding. Family history, abnormal neonatal screening test, and presence of meconium ileus or steatorrhea are strong indicators of cystic fibrosis[56].

Bile acid synthesis disorders

Bile acid biosynthesis defects are a known cause of neonatal cholestasis. Acholic stool may be observed in some cases. It is differentiated from BA when the GGT level is normal or low. Where possible, it can be confirmed through the measurement of urine bile acids, which will be normal or low[57].

Inborn errors of metabolism

Several inborn metabolism errors can lead to neonatal cholestasis that may be difficult to distinguish from BA[2]. In our center we routinely check glucose (for hypoglycemia), blood gasses, serum amino acids, urine organic acid and lactate-pyruvate levels while making differential diagnoses of cholestasis. Acyl carnitine profile, succinyl acetone and galactose-1-phosphate uridylyltransferase enzyme activity can be planned in some cases.

Endocrine disorders

As the initial differential diagnosis in our center, we routinely check fasting glucose, serum thyroid-stimulating hormone, free t4, morning fasting cortisol and adrenocorticotrophic hormone for the evaluation of the hypopituitarism, hypothyroidism and adrenal insufficiency causing cholestasis[1].

Infections

All patients with cholestasis should be tested for urinary infection, regardless of whether they have acholic stool or not, for which a urine culture should be taken[58]. CMV infection is the most common of all congenital infections around the world, and is confirmed by the presence of serum CMV immunoglobulin M, or by the more sensitive blood or urinary CMV polymerase chain reaction. However, two significant problems may be encountered here. First, CMV infection and BA may coexist, and second, the patient may have CMV viremia rather than CMV infection and so we recommend intraoperative cholangiography so as not to delay diagnosis in the absence of other findings of CMV (intracranial calcification, chorioretinitis, deafness). Although there are inter-communal differences, toxoplasma, rubella, herpes and syphilis are rare, but should be investigated[59]. Although hepatitis b and c rarely cause neonatal cholestasis, they should be tested[1].

Alpha 1 antitrypsin deficiency

Alpha 1 antitrypsin deficiency with a ZZ phenotype may cause neonatal cholestasis, and acholic stool may even be observed. A normal serum alpha 1 antitrypsin level, which is an acute-phase reactant, does not exclude alpha 1 antitrypsin deficiency. If there is a strong suspicion of alpha 1 antitrypsin deficiency, such as the presence of family history, a phenotype analysis and liver biopsy may be performed[60], although intraoperative cholangiography should not be delayed by such diagnostic procedures.

Gestational alloimmune liver disease

Gestational alloimmune liver disease should also be considered in patients with cirrhosis and liver

failure in the neonatal period. High bilirubin levels are always present in gestational alloimmune liver disease, while transaminases may not be too high. Ferritin and alpha-fetoprotein are high but not specific to the disease. Hypoglycemia, marked coagulopathy, hypoalbuminemia, edema and death are important findings. Recurrent miscarriages, history of siblings with neonatal hemochromatosis, intrauterine growth retardation, oligohydramnios and premature birth are greater indicators of gestational alloimmune liver disease than BA[61].

Treatment

In cases where the extrahepatic biliary tree cannot be visualized in intraoperative cholangiography, bile drainage is provided *via* Kasai hepatoportoenterostomy. A biliary anastomosis is performed at the liver hilum involving the creation of a Roux-en-Y bowel loop[6]. The syndromic type does not benefit from the Kasai procedure. If the Kasai portoenterostomy is successful, bilirubin will begin to decrease within a few weeks. If there is no improvement in cholestasis, early LT is inevitable. Should the Kasai procedure be unsuccessful, revisional surgery is not recommended as the chance of success is not high, leading to increased adhesions and complicating a subsequent LT. If cholestasis improves while cholestasis recurs, however, second surgery may be considered[62]. In the original Kasai portoenterostomy, fibrous biliary remnants from the hepatic hilum are resected and a jejunal anastomosis is performed. There have been several modifications to this technique over time. In the “extended Kasai portoenterostomy” technique, a deeper and longer incision is made into the portal hilus to the bifurcation of the portal vein. The rationale for this technique is that ducts may be present along the entire line and therefore this entire area should be included in the hepaticojejunostomy. It has been suggested that an extended Kasai portoenterostomy is superior to the traditional technique[63]. The Kasai procedure can also be performed laparoscopically, and it has been suggested that the success of laparoscopic surgery is similar to that of open surgery, offering better perioperative results such as fewer intraoperative blood transfusions and the early initiation of postoperative oral feeding. A laparoscopic Kasai procedure may reduce postoperative complications that necessitate re-laparotomy in LT, such as bowel perforation, re-bleeding or portal vein reconstruction.

Adjuvant treatments

The use of corticosteroids to increase choleresis in the postoperative period was shown not to be beneficial in the START study[64], and there may even be negative effects on growth, although some centers still use corticosteroids. Another drug used to increase choleresis is ursodeoxycholic acid—a hydrophilic bile acid. Although there have been a few studies reporting that ursodeoxycholic acid improves liver enzymes, reduces itching and improves weight gain, others state that it does not change the LT requirement[65]. We use it in doses of 15–30 mg/kg/day in our center.

Nutrition

Patients with BA can encounter malabsorption and malnutrition due to chronic liver disease, absence of gallbladder and cholestasis. The daily calorific requirements of these patients increase, and it should be ensured that patients maintain a 125–150 percent intake of the recommended dietary calorie allowance. Enteral nutrition is usually required, and should include middle-chain triglycerides (MCT) due to their ability to be absorbed directly through the portal vein. Some 30%–70% of the energy derived from fats can be obtained from MCT, although the diet should also contain long-chain fatty acids to avoid essential fatty acid deficiencies. If necessary, tube feeding (nasogastric or gastrostomy) should be provided[66]. In the presence of cholestasis, vitamins A, D, E and K should be given to prevent the development of fat-soluble vitamin deficiency, with vitamin A 5000–25000 IU/day, vitamin E 25 IU/kg day, vitamin D 1200–4000 IU/day and vitamin K 2.5 mg three times a week recommended. Vitamin levels and prothrombin time should be monitored regularly[20].

Complication

Patients who have undergone a Kasai portoenterostomy procedure are at risk of ascending cholangitis due to the resulting abnormal biliary anatomy. More than two-thirds of cases experience at least one episode of cholangitis, and each attack can shorten the time to LT. Although the effectiveness of antibiotic prophylaxis is uncertain, 4–5 mg/kg/ trimethoprim is used daily for 3–12 mo[2], after which, prophylaxis can be given in cases with frequent cholangitis attacks.

Prognosis

Survival rates without LT range from 41%–87% at 5 years, 35%–76% at 10 years and 26%–60% at 20 years[29], although this may vary depending on the success of the Kasai procedure. There are several factors affecting the success of the Kasai procedure, the most important of which is the timing of the operation. The performing of the Kasai procedure at the age of < 60 d gives the best (up to 90%) results in the maintenance of bile flow, while the outcomes after > 90 d are the worst (20%–25%)[5,45]. The second factor is whether a visible bile duct exists to be anastomized during the operation[66], and those with a visible duct in porto hepatitis have a good prognosis. The third factor is the experience of the surgical team. Serum bilirubin levels have prognostic value for the success of the Kasai procedure. The

complete improvement of jaundice within 3 mo of a Kasai hepatoportoenterostomy is considered the best prognostic marker. In a large prospective cohort study, 2 years transplant-free survival was significantly higher in the TB < 2.0 mg/dL group than in the TB ≥ 2 mg/dL group (86% *vs* 20%)[67]. If jaundice persists, survival rates drop.

LT

Overall, more than 60% of patients require LT, and with the advances in surgical techniques, new immunosuppressive therapies and advances in infection treatment, LT can be successfully performed in cases of BA. Unless there are significant complications (*e.g.*, hepatopulmonary syndrome, sepsis, *etc.*), the success of LT is higher than 95% in patients > 10 kg or > 2 years of age[68]. Accordingly, certain conditions should be met for transplantation, among which progressive liver dysfunction (cirrhosis) is the most common. Growth retardation is another indication for transplantation, with cases of moderate and severe growth retardation despite nutritional support, in particular, being considered. Another LT indication is the primary failure of the Kasai procedure, with persistent jaundice after the operation indicating early LT. The guidelines of the American Association for the Study of Liver Diseases, the American Society of Transplantation and the NASPGHAN, it is recommended that "BA patients who are post-hepatoportoenterostomy should be promptly referred for LT evaluation if the total bilirubin is greater than 6 mg/dL 3 mo after hepatoportoenterostomy; and liver transplant evaluation should be considered in BA patients with a total bilirubin of 2–6 mg/dL"[68]. In general, LT success is high in patients with BA. In a large study involving 1818 children who underwent LT for BA, the 1- and 5-year patient survivals for patients transplanted younger than 2 years and older than 2 years were, 95.2%, 93.8%, and 97.8 % and 97.1%, respectively[69].

CHOLEDOCHAL CYSTS

Choledochal cysts are rare congenital anomalies of the biliary system, and can be intrahepatic, extrahepatic or both. They are more common in females than males (3:1 to 4:1), and while the incidence is 1:100000 in live births in Western countries, this can reach as high as 1:1000 in live births in Asia. The progression of liver damage due to recurrent cholangitis and the malignant transformation of choledochal cysts is an important disease[53].

Types

There are five types of choledochal cysts (Table 2 and Figure 2), among which type Ia, Ic and IVa choledochal cysts are associated with pancreatobiliary junction anomalies[4].

Clinical features

Choledochal cysts can produce symptoms at any age, including infancy, childhood or adulthood. Less than a quarter of cases are diagnosed at under 1 year of age, while most are symptomatic under 10 years of age[53]. The most common symptom in children is jaundice, while the classic triad of abdominal pain and jaundice with a palpable mass in the right upper quadrant is uncommon in children. Abdominal pain in children is usually associated with pancreatitis, as in adults, and nausea, vomiting and fever can be observed in those with cholangitis[70].

Pathogenesis

The pathogenesis of choledochal cysts is not yet as well-known as BA, although several theories have been put forward. The first relates to the reflux of pancreatic fluid into the bile duct due to an abnormality in the common bile duct and the pancreatic duct union (pancreaticobiliary maljunction or malunion) in the proximal of the Oddi sphincter, resulting in epithelial damage and subsequent weakness in the bile duct wall[71]. Normally, the common bile duct and pancreatic duct join just before entering the duodenum and open into the papillae vateria. In a pancreaticobiliary junction anomaly, however, the bile duct and pancreatic duct unite outside the duodenal wall, and enter *via* a common channel, which means that the Oddi sphincter cannot perform its anti-regurgital function. Pancreaticobiliary junction anomalies can result from a migration abnormality during the embryological period. The second theory is that an abnormal union leads to mechanical dilation, while a third suggestion relates to the presence of a congenital weakness in the duct wall that may even be segmental. Viral infection during the intrauterine period may result in an abnormality in the formation of the biliary epithelium[72]. Fourth, there may be genetic or environmental toxin exposure, with studies suggesting that common choledochal cysts are seen together with other anomalies as a result of this, including BA, duodenal atresia, anal atresia, congenital absence of the portal vein, and autosomal recessive and autosomal dominant polycystic kidney disease[73].

Histology

An acute and chronically inflamed fibrotic cyst wall is frequently observed in children. In adults,

Table 2 Classification of the choledochal cysts	
Type	Description
Type I	Cystic dilatation of the common bile duct. Also cysts there may be at extrahepatic right and left hepatic ducts and at common hepatic ducts. Intrahepatic bile ducts are unaffected
Type Ia	Large saccular cystic dilatation of the common bile duct, with dilatation of the common hepatic duct and the right and left hepatic duct
Type Ib	Focal and segmental dilation of the common bile duct
Type Ic	Diffuse fusiform dilation of the common bile duct
Type II	Common bile duct diverticulum
Type III	Cysts in the intraduodenal part of the common bile duct – known as choledochoceles
Type IV	Multiple extrahepatic alone, or multiple extrahepatic and intrahepatic cysts together
Type IVa	Extrahepatic and intrahepatic cysts
Type IVb	Multiple extrahepatic cysts (common hepatic duct, common bile duct and intraduodenal common bile duct)
Type V	One or more cystic dilatation of the intrahepatic bile duct. Multiple intrahepatic bile duct cysts are defined as Caroli disease

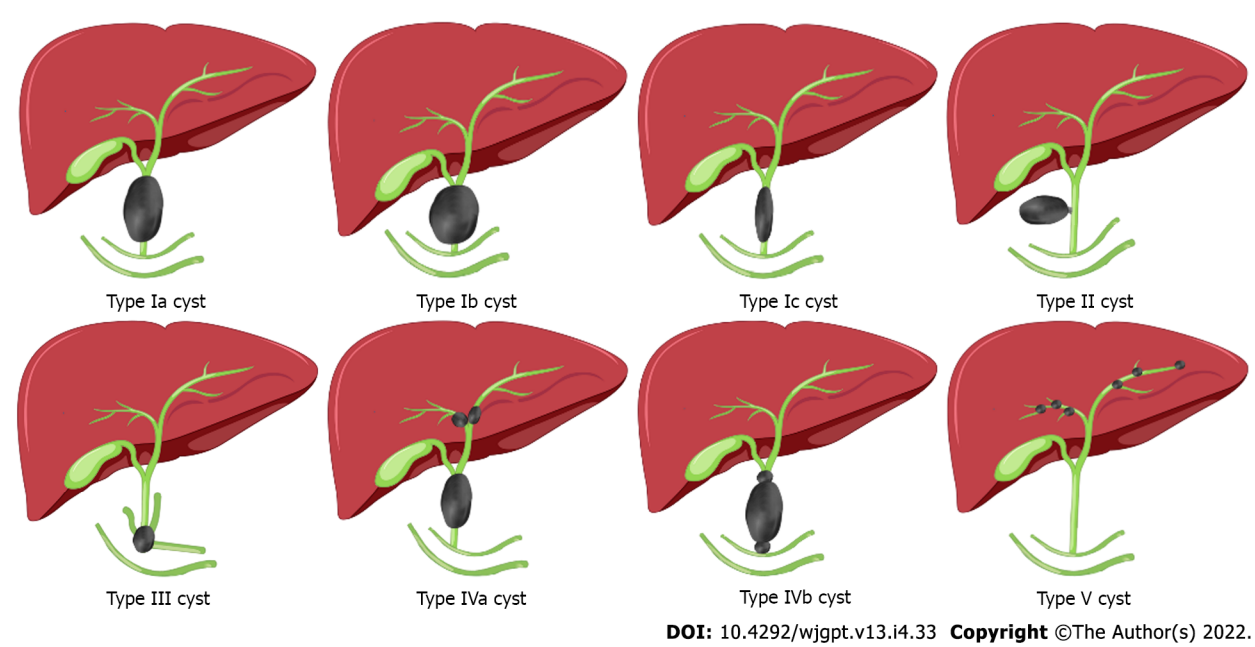


Figure 2 Classification of choledochal cysts[4].

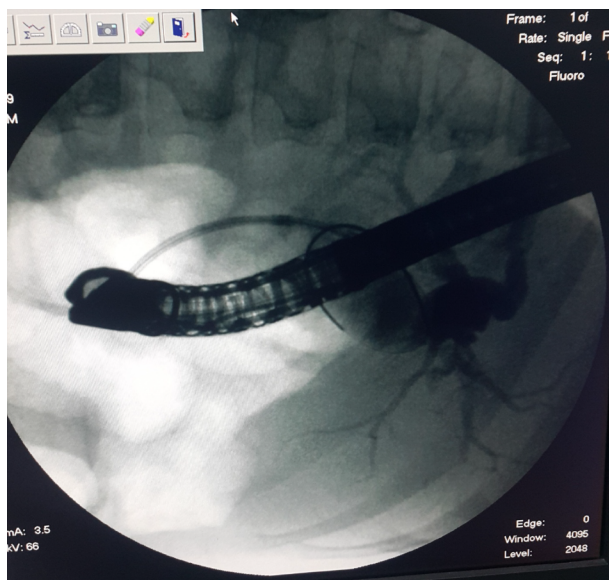
metaplasia and biliary intraepithelial neoplasia, which are precursors of cholangiocarcinoma, may also be observed[53].

Diagnosis

The initial examination of a patient with jaundice or right upper quadrant pain should involve ultrasonography, on which intrahepatic and/or extrahepatic cysts will be well-defined. The subsequent diagnosis is confirmed with MRCP, which can also accurately identify any biliary or pancreatic duct anomalies and variations. ERCP (Figure 3) can be used, offering the advantage of preemptive treatment by sphincterotomy in the presence of bile duct or pancreaticoduodenal junction obstructions, or in the presence of cholangiocarcinoma[53]. In our center, ERCP is performed for Type-I and Type-III cysts.

Treatment

The timing of surgery for cysts is controversial. The treatment of choledochal cysts depends on the type of cyst, the age of the patient and the presence of recurrent cholangitis. Patients with choledochal cysts experience cholangitis attacks at different frequencies, and such attacks may complicate surgery due to adhesions. In addition, liver fibrosis of varying degrees may be observed in patients with choledochal cysts. Choledochal cysts have malignancy potential, with the risk being higher in older ages (0.4% in



DOI: 10.4292/wjgpt.v13.i4.33 Copyright ©The Author(s) 2022.

Figure 3 An endoscopic retrograde cholangiopancreatography image of type IVa choledochal cyst.

those under the age of 18, and between 5% and 50% in adults). Elderly adults are at the greatest risk, and Type I and Type IV cysts have the highest risk of malignancy[74]. Although the risk is lower in other cysts, such risks still exist, and given all the above reasons, it would be prudent to treat them without delay after diagnosis. In cases diagnosed in the neonatal period, surgical treatments can be performed successfully when the patient is a few months old, while the success of surgical treatment in older children is similar to that of adults.

The standard approach in Type-I and Type-IV cysts is complete cyst excision and Roux-en-Y choledochojejunostomy. Intrahepatic cysts in type IVa choledochal cysts should be excised due to the risk of cholangitis and the malignancy potential, and a hepatic segmentomy may be required. For Type-IVa cysts, a hepaticojejunostomy is performed, while for Type-II cysts, cyst excision is sufficient[72]. If type III cysts are symptomatic, they are treated with endoscopic sphincterotomy, and although the risk of malignant transformation is low, surgical treatment may be required in asymptomatic or symptomatic cases. A mucosal biopsy should be taken from the cyst wall during ERCP to evaluate whether the cyst mucosa has a duodenal or biliary epithelium. Endoscopic or surgical excisions may be required in the presence of biliary epithelium, as the risk of malignancy from the biliary epithelium is higher than that of the duodenal epithelium[75]. If Type-V cysts cause frequent cholangitis and the cysts are segmental, a resection or hepatectomy can be performed. LT may be required in symptomatic cysts with diffuse distribution[72].

In cysts extending distally, the pancreaticobiliary junction is preserved during surgical treatment, while the cystic mucosa in this part should be excised due to the risk of malignancy in remnant tissues [76].

Biliary tract surgery is a complex procedure. The common treatment option for choledochal cysts is the traditional open surgery technique, but with the development of laparoscopic techniques in recent years, choledochal cysts have come to be treated laparoscopically in children. It has been suggested that laparoscopic cyst excision and Roux-en-Y hepaticojejunostomy in children provide better intraoperative and postoperative results than open surgery[76].

Monitoring

There is no widely accepted follow-up procedure for patients who have undergone surgery, although we recommend that patients be followed up for anastomotic stricture and malignancy. We periodically check liver enzymes, ultrasonography and carbohydrate antigen 19-9, and as such patients may still have cholangitis, appropriate antibiotics should be administered.

CONCLUSION

In conclusion, BA and choledochal cysts are diseases that cause obstructive cholestasis. While the diagnosis of BA can be rather complicated, it is important to diagnose as early as possible and to perform a Kasai hepatopertoenterostomy before the age of 2 mo for a good prognosis. All patients with persistent acholic stool and elevated GGT should be evaluated in terms of BA. Normal ultrasonography

will not rule out BA, and such patients are candidates for intraoperative cholangiography. Choledochal cysts can present symptoms at any age, and since recurrent cholangitis attacks will lead to chronic liver disease, and due to their malignant potential, treatment and long-term follow-up are important.

ACKNOWLEDGEMENTS

We thank the Department of Medical Pathology, Çukurova University School of Medicine for the liver photos.

FOOTNOTES

Author contributions: Islek A substantially contributed to the conception and design of the paper and the acquisition, analysis and interpretation of the data; Islek A and Tumgor G drafted the article and made critical revisions related to the intellectual content of the manuscript and approved the final version of the article to be published.

Conflict-of-interest statement: All the authors report no relevant conflicts of interest for this article.

Open-Access: This article is an open-access article that was selected by an in-house editor and fully peer-reviewed by external reviewers. It is distributed in accordance with the Creative Commons Attribution NonCommercial (CC BY-NC 4.0) license, which permits others to distribute, remix, adapt, build upon this work non-commercially, and license their derivative works on different terms, provided the original work is properly cited and the use is non-commercial. See: <https://creativecommons.org/licenses/by-nc/4.0/>

Country/Territory of origin: Turkey

ORCID number: Ali Islek 0000-0001-6172-7797; Gokhan Tumgor 0000-0002-3919-002X.

S-Editor: Fan JR

L-Editor: A

P-Editor: Fan JR

REFERENCES

- 1 **Satrom KM**, Gourley GR, Neonatal jaundice and disorders of bilirubin metabolism. In: Suchy FJ, Sokol RJ, Balistreri WF, Bezerra JA, Mack CL, Shneider BL, editors. *Liver Disease in Children* 5th ed. Cambridge: Cambridge University Press; 2021: 182-203
- 2 **Fawaz R**, Baumann U, Ekong U, Fischler B, Hadzic N, Mack CL, McLin VA, Molleston JP, Neimark E, Ng VL, Karpen SJ. Guideline for the Evaluation of Cholestatic Jaundice in Infants: Joint Recommendations of the North American Society for Pediatric Gastroenterology, Hepatology, and Nutrition and the European Society for Pediatric Gastroenterology, Hepatology, and Nutrition. *J Pediatr Gastroenterol Nutr* 2017; **64**: 154-168 [PMID: 27429428 DOI: 10.1097/MPG.0000000000001334]
- 3 **Haber BA**, Russo P. Biliary atresia. *Gastroenterol Clin North Am* 2003; **32**: 891-911 [PMID: 14562580 DOI: 10.1016/s0889-8553(03)00049-9]
- 4 **Todani T**, Watanabe Y, Toki A, Morotomi Y. Classification of congenital biliary cystic disease: special reference to type Ic and IVA cysts with primary ductal stricture. *J Hepatobiliary Pancreat Surg* 2003; **10**: 340-344 [PMID: 14598133 DOI: 10.1007/s00534-002-0733-7]
- 5 **Kelley-Quon LI**, Shue E, Burke RV, Smith C, Kling K, Mahdi E, Ourshalimian S, Fenlon M, Dellinger M, Shew SB, Lee J, Padilla B, Inge T, Roach J, Marwan AI, Russell KW, Ignacio R, Fialkowski E, Nijagal A, Im C, Azarow KS, Ostlie DJ, Wang K. The need for early Kasai portoenterostomy: a Western Pediatric Surgery Research Consortium study. *Pediatr Surg Int* 2022; **38**: 193-199 [PMID: 34854975 DOI: 10.1007/s00383-021-05047-1]
- 6 **Liu L**, Wei L, Qu W, Liu Y, Zeng Z, Zhang H, Li M, Liu J, Wang HL, Li K, He Y, Jia J, Sun L, Zhao X, Zhu Z. Impact of the Kasai Procedure and the Length of Native Liver Survival Time on Outcomes of Liver Transplantation for Biliary Atresia. *Liver Transpl* 2022; **28**: 224-235 [PMID: 34482616 DOI: 10.1002/lt.26287]
- 7 **Hopkins PC**, Yazigi N, Nylund CM. Incidence of Biliary Atresia and Timing of Hepatoporeostomy in the United States. *J Pediatr* 2017; **187**: 253-257 [PMID: 28746031 DOI: 10.1016/j.jpeds.2017.05.006]
- 8 **Livesey E**, Cortina Borja M, Sharif K, Alizai N, McClean P, Kelly D, Hadzic N, Davenport M. Epidemiology of biliary atresia in England and Wales (1999-2006). *Arch Dis Child Fetal Neonatal Ed* 2009; **94**: F451-F455 [PMID: 19457876 DOI: 10.1136/adc.2009.159780]
- 9 **Chardot C**, Buet C, Serinet MO, Golmard JL, Lachaux A, Roquelaure B, Gottrand F, Broué P, Dabadie A, Gauthier F, Jacquemin E. Improving outcomes of biliary atresia: French national series 1986-2009. *J Hepatol* 2013; **58**: 1209-1217 [PMID: 23402746 DOI: 10.1016/j.jhep.2013.01.040]
- 10 **Lee KJ**, Kim JW, Moon JS, Ko JS. Epidemiology of Biliary Atresia in Korea. *J Korean Med Sci* 2017; **32**: 656-660 [PMID: 28244293 DOI: 10.3346/jkms.2017.32.4.656]

- 11 **Nio M**, Ohi R, Miyano T, Saeki M, Shiraki K, Tanaka K; Japanese Biliary Atresia Registry. Five- and 10-year survival rates after surgery for biliary atresia: a report from the Japanese Biliary Atresia Registry. *J Pediatr Surg* 2003; **38**: 997-1000 [PMID: [12861525](#) DOI: [10.1016/s0022-3468\(03\)00178-7](#)]
- 12 **Hsiao CH**, Chang MH, Chen HL, Lee HC, Wu TC, Lin CC, Yang YJ, Chen AC, Tiao MM, Lau BH, Chu CH, Lai MW; Taiwan Infant Stool Color Card Study Group. Universal screening for biliary atresia using an infant stool color card in Taiwan. *Hepatology* 2008; **47**: 1233-1240 [PMID: [18306391](#) DOI: [10.1002/hep.22182](#)]
- 13 **Muraji T**, Tanaka H, Ieiri S. Ethnic variation in the incidence of biliary atresia correlates with the frequency of the most prevalent haplotype in its population. *Hum Immunol* 2018; **79**: 668-671 [PMID: [30006139](#) DOI: [10.1016/j.humimm.2018.07.001](#)]
- 14 **Lakshminarayanan B**, Davenport M. Biliary atresia: A comprehensive review. *J Autoimmun* 2016; **73**: 1-9 [PMID: [27346637](#) DOI: [10.1016/j.jaut.2016.06.005](#)]
- 15 **Ozden O**, Kilic SS, Alkan M, Tumgor G, Tuncer R. Biliary Atresia Splenic Malformation Syndrome: A Single Center Experience. Biliary Atresia Splenic Malformation Syndrome: A Single Center Experience. *Acta Medica* 2019; **50**: 36-41 [DOI: [10.32552/2019.ActaMedica.355](#)]
- 16 **Caponcelli E**, Knisely AS, Davenport M. Cystic biliary atresia: an etiologic and prognostic subgroup. *J Pediatr Surg* 2008; **43**: 1619-1624 [PMID: [18778995](#) DOI: [10.1016/j.jpedsurg.2007.12.058](#)]
- 17 **Russo P**, Magee JC, Anders RA, Bove KE, Chung C, Cummings OW, Finegold MJ, Finn LS, Kim GE, Lovell MA, Magid MS, Melin-Aldana H, Ranganathan S, Shehata BM, Wang LL, White FV, Chen Z, Spino C; Childhood Liver Disease Research Network (ChILDReN). Key Histopathologic Features of Liver Biopsies That Distinguish Biliary Atresia From Other Causes of Infantile Cholestasis and Their Correlation With Outcome: A Multicenter Study. *Am J Surg Pathol* 2016; **40**: 1601-1615 [PMID: [27776008](#) DOI: [10.1097/PAS.0000000000000755](#)]
- 18 **Napolitano M**, Franchi-Abella S, Damasio BM, Augdal TA, Avni FE, Bruno C, Darge K, Ključevšek D, Littooij AS, Lobo L, Mentzel HJ, Riccabona M, Stafrace S, Toso S, Woźniak MM, Di Leo G, Sardanelli F, Ording Müller LS, Petit P. Practical approach for the diagnosis of biliary atresia on imaging, part 2: magnetic resonance cholecystopancreatography, hepatobiliary scintigraphy, percutaneous cholecysto-cholangiography, endoscopic retrograde cholangiopancreatography, percutaneous liver biopsy, risk scores and decisional flowchart. *Pediatr Radiol* 2021; **51**: 1545-1554 [PMID: [33974103](#) DOI: [10.1007/s00247-021-05034-7](#)]
- 19 **Napolitano M**, Franchi-Abella S, Damasio MB, Augdal TA, Avni FE, Bruno C, Darge K, Ključevšek D, Littooij AS, Lobo L, Mentzel HJ, Riccabona M, Stafrace S, Toso S, Woźniak MM, Di Leo G, Sardanelli F, Ording Müller LS, Petit P. Practical approach to imaging diagnosis of biliary atresia, Part 1: prenatal ultrasound and magnetic resonance imaging, and postnatal ultrasound. *Pediatr Radiol* 2021; **51**: 314-331 [PMID: [33201318](#) DOI: [10.1007/s00247-020-04840-9](#)]
- 20 **Bezerra JA**, Asai A, Tiao G, Mullapudi B, Balistreri WF. Biliary Atresia and Other Disorders of The Extrahepatic Bile Ducts. In: Suchy FJ, Sokol RJ, Balistreri WF, Bezerra JA, Mack CL, Shneider BL, editors. *Liver Disease in Children* 5th ed. Cambridge: Cambridge University Press; 2021: 162-181
- 21 **Gu YH**, Yokoyama K, Mizuta K, Tsuchioka T, Kudo T, Sasaki H, Nio M, Tang J, Ohkubo T, Matsui A. Stool color card screening for early detection of biliary atresia and long-term native liver survival: a 19-year cohort study in Japan. *J Pediatr* 2015; **166**: 897-902.e1 [PMID: [25681196](#) DOI: [10.1016/j.jpeds.2014.12.063](#)]
- 22 **Ağın M**, Tümgör G, Alkan M, Özden Ö, Satar M, Tuncer R. Clues to the diagnosis of biliary atresia in neonatal cholestasis. *Turk J Gastroenterol* 2016; **27**: 37-41 [PMID: [26728861](#) DOI: [10.5152/tjg.2015.150379](#)]
- 23 **Asai A**, Miethke A, Bezerra JA. Pathogenesis of biliary atresia: defining biology to understand clinical phenotypes. *Nat Rev Gastroenterol Hepatol* 2015; **12**: 342-352 [PMID: [26008129](#) DOI: [10.1038/nrgastro.2015.74](#)]
- 24 **Pacheco MC**, Campbell KM, Bove KE. Ductal plate malformation-like arrays in early explants after a Kasai procedure are independent of splenic malformation complex (heterotaxy). *Pediatr Dev Pathol* 2009; **12**: 355-360 [PMID: [19883236](#) DOI: [10.2350/09-01-0598-OA.1](#)]
- 25 **Fischler B**, Ehrnst A, Forsgren M, Orvell C, Nemeth A. The viral association of neonatal cholestasis in Sweden: a possible link between cytomegalovirus infection and extrahepatic biliary atresia. *J Pediatr Gastroenterol Nutr* 1998; **27**: 57-64 [PMID: [9669727](#) DOI: [10.1097/00005176-199807000-00010](#)]
- 26 **Jevon GP**, Dimmick JE. Biliary atresia and cytomegalovirus infection: a DNA study. *Pediatr Dev Pathol* 1999; **2**: 11-14 [PMID: [9841700](#) DOI: [10.1007/s100249900083](#)]
- 27 **Daniel E**, Fleck-Deverian S, Rosenthal P. Has Rotavirus Vaccination Decreased the Prevalence of Biliary Atresia? *J Clin Gastroenterol* 2019; **53**: e348-e351 [PMID: [30222646](#) DOI: [10.1097/MCG.0000000000001121](#)]
- 28 **Averbukh LD**, Wu GY. Evidence for Viral Induction of Biliary Atresia: A Review. *J Clin Transl Hepatol* 2018; **6**: 410-419 [PMID: [30637219](#) DOI: [10.14218/JCTH.2018.00046](#)]
- 29 **Lorent K**, Gong W, Koo KA, Waisbourd-Zinman O, Karjoo S, Zhao X, Sealy I, Kettleborough RN, Stemple DL, Windsor PA, Whittaker SJ, Porter JR, Wells RG, Pack M. Identification of a plant isoflavonoid that causes biliary atresia. *Sci Transl Med* 2015; **7**: 286ra67 [PMID: [25947162](#) DOI: [10.1126/scitranslmed.aaa1652](#)]
- 30 **Muraji T**, Hosaka N, Irie N, Yoshida M, Imai Y, Tanaka K, Takada Y, Sakamoto S, Haga H, Ikehara S. Maternal microchimerism in underlying pathogenesis of biliary atresia: quantification and phenotypes of maternal cells in the liver. *Pediatrics* 2008; **121**: 517-521 [PMID: [18310200](#) DOI: [10.1542/peds.2007-0568](#)]
- 31 **Tran KT**, Le VS, Dao LTM, Nguyen HK, Mai AK, Nguyen HT, Ngo MD, Tran QA, Nguyen LT. Novel findings from family-based exome sequencing for children with biliary atresia. *Sci Rep* 2021; **11**: 21815 [PMID: [34750413](#) DOI: [10.1038/s41598-021-01148-y](#)]
- 32 **Berauer JP**, Mezina AI, Okou DT, Sabo A, Muzny DM, Gibbs RA, Hegde MR, Chopra P, Cutler DJ, Perlmutter DH, Bull LN, Thompson RJ, Loomes KM, Spinner NB, Rajagopalan R, Guthery SL, Moore B, Yandell M, Harpavat S, Magee JC, Kamath BM, Molleston JP, Bezerra JA, Murray KF, Alonso EM, Rosenthal P, Squires RH, Wang KS, Finegold MJ, Russo P, Sherker AH, Sokol RJ, Karpen SJ; Childhood Liver Disease Research Network (ChILDReN). Identification of Polycystic Kidney Disease 1 Like 1 Gene Variants in Children With Biliary Atresia Splenic Malformation Syndrome. *Hepatology* 2019; **70**: 899-910 [PMID: [30664273](#) DOI: [10.1002/hep.30515](#)]
- 33 **Garcia-Barceló MM**, Yeung MY, Miao XP, Tang CS, Cheng G, So MT, Ngan ES, Lui VC, Chen Y, Liu XL, Hui KJ, Li

- L, Guo WH, Sun XB, Tou JF, Chan KW, Wu XZ, Song YQ, Chan D, Cheung K, Chung PH, Wong KK, Sham PC, Cherny SS, Tam PK. Genome-wide association study identifies a susceptibility locus for biliary atresia on 10q24.2. *Hum Mol Genet* 2010; **19**: 2917-2925 [PMID: 20460270 DOI: 10.1093/hmg/ddq196]
- 34 **Sangkhathat S**, Laochareonsuk W, Maneechay W, Kayasut K, Chiengkriwate P. Variants Associated with Infantile Cholestatic Syndromes Detected in Extrahepatic Biliary Atresia by Whole Exome Studies: A 20-Case Series from Thailand. *J Pediatr Genet* 2018; **7**: 67-73 [PMID: 29707407 DOI: 10.1055/s-0038-1632395]
 - 35 **Rabbani T**, Guthery SL, Himes R, Shneider BL, Harpavat S. Newborn Screening for Biliary Atresia: a Review of Current Methods. *Curr Gastroenterol Rep* 2021; **23**: 28 [PMID: 34817690 DOI: 10.1007/s11894-021-00825-2]
 - 36 **Powell JE**, Keffler S, Kelly DA, Green A. Population screening for neonatal liver disease: potential for a community-based programme. *J Med Screen* 2003; **10**: 112-116 [PMID: 14561261 DOI: 10.1177/096914130301000303]
 - 37 **Harpavat S**, Garcia-Prats JA, Anaya C, Brandt ML, Lupo PJ, Finegold MJ, Obuobi A, ElHennawy AA, Jarriel WS, Shneider BL. Diagnostic Yield of Newborn Screening for Biliary Atresia Using Direct or Conjugated Bilirubin Measurements. *JAMA* 2020; **323**: 1141-1150 [PMID: 32207797 DOI: 10.1001/jama.2020.0837]
 - 38 **Zhou K**, Lin N, Xiao Y, Wang Y, Wen J, Zou GM, Gu X, Cai W. Elevated bile acids in newborns with Biliary Atresia (BA). *PLoS One* 2012; **7**: e49270 [PMID: 23166626 DOI: 10.1371/journal.pone.0049270]
 - 39 **Gustafsson J**, Alvelius G, Björkhem I, Nemeth A. Bile acid metabolism in extrahepatic biliary atresia: lithocholic acid in stored dried blood collected at neonatal screening. *Ups J Med Sci* 2006; **111**: 131-136 [PMID: 16553252 DOI: 10.3109/2000-1967-017]
 - 40 **Konishi KI**, Mizuochi T, Takei H, Yasuda R, Sakaguchi H, Ishihara J, Takaki Y, Kinoshita M, Hashizume N, Fukahori S, Shoji H, Miyano G, Yoshimaru K, Matsuura T, Sanada Y, Tainaka T, Uchida H, Kubo Y, Tanaka H, Sasaki H, Murai T, Fujishiro J, Yamashita Y, Nio M, Nittono H, Kimura A. A Japanese prospective multicenter study of urinary oxysterols in biliary atresia. *Sci Rep* 2021; **11**: 4986 [PMID: 33654186 DOI: 10.1038/s41598-021-84445-w]
 - 41 **Shen Q**, Tan SS, Wang Z, Cai S, Pang W, Peng C, Chen Y. Combination of gamma-glutamyl transferase and liver stiffness measurement for biliary atresia screening at different ages: a retrospective analysis of 282 infants. *BMC Pediatr* 2020; **20**: 276 [PMID: 32498678 DOI: 10.1186/s12887-020-02172-z]
 - 42 **Mittal V**, Saxena AK, Sodhi KS, Thapa BR, Rao KL, Das A, Khandelwal N. Role of abdominal sonography in the preoperative diagnosis of extrahepatic biliary atresia in infants younger than 90 days. *AJR Am J Roentgenol* 2011; **196**: W438-W445 [PMID: 21427309 DOI: 10.2214/AJR.10.5180]
 - 43 **Yoon HM**, Suh CH, Kim JR, Lee JS, Jung AY, Cho YA. Diagnostic Performance of Sonographic Features in Patients With Biliary Atresia: A Systematic Review and Meta-analysis. *J Ultrasound Med* 2017; **36**: 2027-2038 [PMID: 28556285 DOI: 10.1002/jum.14234]
 - 44 **Wang G**, Zhang N, Zhang X, Zhou W, Xie X, Zhou L. Ultrasound characteristics combined with gamma-glutamyl transpeptidase for diagnosis of biliary atresia in infants less than 30 days. *Pediatr Surg Int* 2021; **37**: 1175-1182 [PMID: 34008061 DOI: 10.1007/s00383-021-04923-0]
 - 45 **Negm AA**, Petersen C, Markowski A, Luettig B, Ringe KI, Lankisch TO, Manns MP, Ure B, Schneider AS. The Role of Endoscopic Retrograde Cholangiopancreatography in the Diagnosis of Biliary Atresia: 14 Years' Experience. *Eur J Pediatr Surg* 2018; **28**: 261-267 [PMID: 28403505 DOI: 10.1055/s-0037-1602260]
 - 46 **Keil R**, Snajdauf J, Rygl M, Pycha K, Kotalová R, Drábek J, Stovicek J, Procke M. Diagnostic efficacy of ERCP in cholestatic infants and neonates--a retrospective study on a large series. *Endoscopy* 2010; **42**: 121-126 [PMID: 20140829 DOI: 10.1055/s-0029-1215372]
 - 47 **Rastogi A**, Krishnani N, Yachha SK, Khanna V, Poddar U, Lal R. Histopathological features and accuracy for diagnosing biliary atresia by prelaparotomy liver biopsy in developing countries. *J Gastroenterol Hepatol* 2009; **24**: 97-102 [PMID: 19196397 DOI: 10.1111/j.1440-1746.2008.05737.x]
 - 48 **Russo P**, Magee JC, Boitnott J, Bove KE, Raghunathan T, Finegold M, Haas J, Jaffe R, Kim GE, Magid M, Melin-Aldana H, White F, Whittington PF, Sokol RJ; Biliary Atresia Research Consortium. Design and validation of the biliary atresia research consortium histologic assessment system for cholestasis in infancy. *Clin Gastroenterol Hepatol* 2011; **9**: 357-362.e2 [PMID: 21238606 DOI: 10.1016/j.cgh.2011.01.003]
 - 49 **Ranucci G**, Della Corte C, Alberti D, Bondioni MP, Boroni G, Calvo PL, Cananzi M, Candusso M, Clemente MG, D'Antiga L, Degrossi I, De Ville De Goyet J, Di Dato F, Di Giorgio A, Vici CD, Ferrari F, Francalanci P, Fuoti M, Fusaro F, Gaio P, Grimaldi C, Iascone M, Indolfi G, Iorio R, Maggiori G, Mandato C, Matarazzo L, Monti L, Mosca F, Nebbia G, Nuti F, Paoletta G, Pinon M, Roggero P, Sciveres M, Serranti D, Spada M, Vajro P, Nicastro E. Diagnostic approach to neonatal and infantile cholestasis: A position paper by the SIGENP liver disease working group. *Dig Liver Dis* 2022; **54**: 40-53 [PMID: 34688573 DOI: 10.1016/j.dld.2021.09.011]
 - 50 **Alkan M**, Tutus K, Fakioglu E, Ozden O, Hatipoglu Z, Iskit SH, Tuncer R, Zorludemir U. Laparoscopy-Assisted Percutaneous Cholangiography in Biliary Atresia Diagnosis: Comparison with Open Technique. *Gastroenterol Res Pract* 2016; **2016**: 5637072 [PMID: 26819607 DOI: 10.1155/2016/5637072]
 - 51 **Jiang J**, Wang J, Shen Z, Lu X, Chen G, Huang Y, Dong R, Zheng S. Serum MMP-7 in the Diagnosis of Biliary Atresia. *Pediatrics* 2019; **144** [PMID: 31604829 DOI: 10.1542/peds.2019-0902]
 - 52 **Soares KC**, Goldstein SD, Ghaseb MA, Kamel I, Hackam DJ, Pawlik TM. Pediatric choledochal cysts: diagnosis and current management. *Pediatr Surg Int* 2017; **33**: 637-650 [PMID: 28364277 DOI: 10.1007/s00383-017-4083-6]
 - 53 **Kamath BM**, Baker A, Houwen R, Todorova L, Kerkar N. Systematic Review: The Epidemiology, Natural History, and Burden of Alagille Syndrome. *J Pediatr Gastroenterol Nutr* 2018; **67**: 148-156 [PMID: 29543694 DOI: 10.1097/MPG.0000000000001958]
 - 54 **Baker A**, Kerkar N, Todorova L, Kamath BM, Houwen RHJ. Systematic review of progressive familial intrahepatic cholestasis. *Clin Res Hepatol Gastroenterol* 2019; **43**: 20-36 [PMID: 30236549 DOI: 10.1016/j.clinre.2018.07.010]
 - 55 **van de Peppel IP**, Bertolini A, Jonker JW, Bodewes FAJA, Verkade HJ. Diagnosis, follow-up and treatment of cystic fibrosis-related liver disease. *Curr Opin Pulm Med* 2017; **23**: 562-569 [PMID: 28837442 DOI: 10.1097/MCP.0000000000000428]
 - 56 **Clayton PT**. Disorders of bile acid synthesis. *J Inherit Metab Dis* 2011; **34**: 593-604 [PMID: 21229319 DOI: 10.1007/s10545-011-9111-1]

- 10.1007/s10545-010-9259-3]
- 57 **Lane E**, Murray KF. Neonatal Cholestasis. *Pediatr Clin North Am* 2017; **64**: 621-639 [PMID: [28502442](#) DOI: [10.1016/j.pcl.2017.01.006](#)]
- 58 **Neu N**, Duchon J, Zachariah P. TORCH infections. *Clin Perinatol* 2015; **42**: 77-103, viii [PMID: [25677998](#) DOI: [10.1016/j.clp.2014.11.001](#)]
- 59 **Strnad P**, McElvaney NG, Lomas DA. Alpha₁-Antitrypsin Deficiency. *N Engl J Med* 2020; **382**: 1443-1455 [PMID: [32268028](#) DOI: [10.1056/NEJMra1910234](#)]
- 60 **Kasko O**, Klose E, Rama G, Newberry D, Jnah A. Gestational Alloimmune Liver Disease: A Case Study. *Neonatal Netw* 2018; **37**: 271-280 [PMID: [30567809](#) DOI: [10.1891/0730-0832.37.5.271](#)]
- 61 **Bondoc AJ**, Taylor JA, Alonso MH, Nathan JD, Wang Y, Balistreri WF, Bezerra JA, Ryckman FC, Tiao GM. The beneficial impact of revision of Kasai portoenterostomy for biliary atresia: an institutional study. *Ann Surg* 2012; **255**: 570-576 [PMID: [22258066](#) DOI: [10.1097/SLA.0b013e318243a46e](#)]
- 62 **Ramachandran P**, Safwan M, Srinivas S, Shanmugam N, Vij M, Rela M. The extended Kasai portoenterostomy for biliary atresia: A preliminary report. *J Indian Assoc Pediatr Surg* 2016; **21**: 66-71 [PMID: [27046977](#) DOI: [10.4103/0971-9261.176941](#)]
- 63 **Bezerra JA**, Spino C, Magee JC, Shneider BL, Rosenthal P, Wang KS, Erlichman J, Haber B, Hertel PM, Karpen SJ, Kerkar N, Loomes KM, Molleston JP, Murray KF, Romero R, Schwarz KB, Shepherd R, Suchy FJ, Turmelle YP, Whittington PF, Moore J, Sherker AH, Robuck PR, Sokol RJ; Childhood Liver Disease Research and Education Network (ChILDREN). Use of corticosteroids after hepatopuertoenterostomy for bile drainage in infants with biliary atresia: the START randomized clinical trial. *JAMA* 2014; **311**: 1750-1759 [PMID: [24794368](#) DOI: [10.1001/jama.2014.2623](#)]
- 64 **Stringer MD**, Davison SM, Rajwal SR, McClean P. Kasai portoenterostomy: 12-year experience with a novel adjuvant therapy regimen. *J Pediatr Surg* 2007; **42**: 1324-1328 [PMID: [17706489](#) DOI: [10.1016/j.jpedsurg.2007.03.026](#)]
- 65 **Superina R**, Magee JC, Brandt ML, Healey PJ, Tiao G, Ryckman F, Karrer FM, Iyer K, Fecteau A, West K, Burns RC, Flake A, Lee H, Lowell JA, Dillon P, Colombani P, Ricketts R, Li Y, Moore J, Wang KS; Childhood Liver Disease Research and Education Network. The anatomic pattern of biliary atresia identified at time of Kasai hepatopuertoenterostomy and early postoperative clearance of jaundice are significant predictors of transplant-free survival. *Ann Surg* 2011; **254**: 577-585 [PMID: [21869674](#) DOI: [10.1097/SLA.0b013e3182300950](#)]
- 66 **Shneider BL**, Magee JC, Karpen SJ, Rand EB, Narkewicz MR, Bass LM, Schwarz K, Whittington PF, Bezerra JA, Kerkar N, Haber B, Rosenthal P, Turmelle YP, Molleston JP, Murray KF, Ng VL, Wang KS, Romero R, Squires RH, Arnon R, Sherker AH, Moore J, Ye W, Sokol RJ; Childhood Liver Disease Research Network (ChILDREN). Total Serum Bilirubin within 3 Months of Hepatopuertoenterostomy Predicts Short-Term Outcomes in Biliary Atresia. *J Pediatr* 2016; **170**: 211-7.e1 [PMID: [26725209](#) DOI: [10.1016/j.jpeds.2015.11.058](#)]
- 67 **Squires RH**, Ng V, Romero R, Ekong U, Hardikar W, Emre S, Mazariegos GV. Evaluation of the pediatric patient for liver transplantation: 2014 practice guideline by the American Association for the Study of Liver Diseases, American Society of Transplantation and the North American Society for Pediatric Gastroenterology, Hepatology and Nutrition. *Hepatology* 2014; **60**: 362-398 [PMID: [24782219](#) DOI: [10.1002/hep.27191](#)]
- 68 **Arnon R**, Annunziato RA, D'Amelio G, Chu J, Shneider BL. Liver Transplantation for Biliary Atresia: Is There a Difference in Outcome for Infants? *J Pediatr Gastroenterol Nutr* 2016; **62**: 220-225 [PMID: [26418214](#) DOI: [10.1097/MPG.0000000000000986](#)]
- 69 **Silva-Baez H**, Coello-Ramírez P, Ixtabalán-Escalante EM, Sotelo-Anaya E, Gallo-Morales M, Cordero-Estrada E, Sainz-Escarrega VH, Ploneda-Valencia CF. Treatment of choledochal cyst in a pediatric population. A single institution experience of 15-years. Case series. *Ann Med Surg (Lond)* 2016; **5**: 81-85 [PMID: [26900456](#) DOI: [10.1016/j.amsu.2015.12.054](#)]
- 70 **Singham J**, Yoshida EM, Scudamore CH. Choledochal cysts: part 1 of 3: classification and pathogenesis. *Can J Surg* 2009; **52**: 434-440 [PMID: [19865581](#)]
- 71 **Jabłońska B**. Biliary cysts: etiology, diagnosis and management. *World J Gastroenterol* 2012; **18**: 4801-4810 [PMID: [23002354](#) DOI: [10.3748/wjg.v18.i35.4801](#)]
- 72 **Iwata F**, Uchida A, Miyaki T, Aoki S, Fujioka T, Yamada J, Joh T, Itoh M. Familial occurrence of congenital bile duct cysts. *J Gastroenterol Hepatol* 1998; **13**: 316-319 [PMID: [9570247](#) DOI: [10.1111/j.1440-1746.1998.01562.x](#)]
- 73 **Sastry AV**, Abbadessa B, Wayne MG, Steele JG, Cooperman AM. What is the incidence of biliary carcinoma in choledochal cysts, when do they develop, and how should it affect management? *World J Surg* 2015; **39**: 487-492 [PMID: [25322698](#) DOI: [10.1007/s00268-014-2831-5](#)]
- 74 **Law R**, Topazian M. Diagnosis and treatment of choledochoceles. *Clin Gastroenterol Hepatol* 2014; **12**: 196-203 [PMID: [23660418](#) DOI: [10.1016/j.cgh.2013.04.037](#)]
- 75 **Ten Hove A**, de Meijer VE, Hulscher JBF, de Kleine RHJ. Meta-analysis of risk of developing malignancy in congenital choledochal malformation. *Br J Surg* 2018; **105**: 482-490 [PMID: [29480528](#) DOI: [10.1002/bjs.10798](#)]
- 76 **Sun R**, Zhao N, Zhao K, Su Z, Zhang Y, Diao M, Li L. Comparison of efficacy and safety of laparoscopic excision and open operation in children with choledochal cysts: A systematic review and update meta-analysis. *PLoS One* 2020; **15**: e0239857 [PMID: [32986787](#) DOI: [10.1371/journal.pone.0239857](#)]



Published by **Baishideng Publishing Group Inc**
7041 Koll Center Parkway, Suite 160, Pleasanton, CA 94566, USA

Telephone: +1-925-3991568

E-mail: bpgoffice@wjgnet.com

Help Desk: <https://www.f6publishing.com/helpdesk>

<https://www.wjgnet.com>

