



# Identification of a novel heterozygous variant in the *PEX26* gene in an infant: a case report

Yuan Huang<sup>#</sup>, Lingling Liu<sup>#</sup>, Feng Fang<sup>^</sup>, Hua Zhou, Xinglou Liu

Department of Pediatrics, Tongji Hospital, Tongji Medical College, Huazhong University of Science and Technology, Wuhan, China

**Contributions:** (I) Conception and design: X Liu; (II) Administrative support: All authors; (III) Provision of study materials or patients: F Fang, H Zhou; (IV) Collection and assembly of data: Y Huang; (V) Data analysis and interpretation: Y Huang, L Liu; (VI) Manuscript writing: All authors; (VII) Final approval of manuscript: All authors.

<sup>#</sup>These authors contributed equally to this work as co-first authors.

**Correspondence to:** Xinglou Liu, PhD. Department of Pediatrics, Tongji Hospital, Tongji Medical College, Huazhong University of Science and Technology, No. 1095 Jiefang Avenue, Wuhan 430030, China. Email: liuxinglou@163.com.

**Background:** The protein PEX26 is involved in the biogenesis and maintenance of peroxisomes, which are organelles within cells. Dysfunction of PEX26 results in peroxisome biogenesis disorders (PBDs) complementation group 8 (CG8), leading to Zellweger spectrum disorders (ZSDs). These disorders present as a syndrome with multiple congenital anomalies, varying in clinical severity.

**Case Description:** We present the case of a 7-month-old boy who exhibited hepatic impairment with hepatomegaly, sensorineural hearing loss, developmental delay, abnormal ossification, and mild craniofacial dysmorphism. Tandem mass spectrometry analysis of plasma isolated from whole blood revealed a significant increase in the levels of very long chain fatty acids (VLCFAs) C26:0, C26:0/C22:0, and C24:0/C22:0, consistent with peroxisomal fatty acid oxidation disorder. Exome sequencing identified two variants in the *PEX26* gene (c.347T>C and c.616C>T), with the latter being a suspected pathogenic variation. The variant can lead to a defect in the *PEX26* gene, resulting in impaired peroxisome biogenesis,  $\beta$ -oxidation of VLCFAs, and disruption of other biochemical pathways. Ultimately, this cascade of events manifests as ZSDs. Currently, symptomatic supportive treatment is the main approach for managing this condition and regular follow-up is being conducted for the patient.

**Conclusions:** The present study introduces a novel heterozygous variant comprising two previously unidentified variants in the *PEX26* gene, thereby expanding the range of known genetic alterations and highlighting the effectiveness of highly efficient exome sequencing in patients with undetermined multiple system dysfunctions.

**Keywords:** Peroxisome; *PEX26*; peroxisome biogenesis disorder (PBD); Zellweger spectrum disorders (ZSDs); case report

Submitted Sep 06, 2023. Accepted for publication Dec 10, 2023. Published online Jan 15, 2024.

doi: 10.21037/tp-23-454

**View this article at:** <https://dx.doi.org/10.21037/tp-23-454>

<sup>^</sup> ORCID: Yuan Huang, 0000-0003-0512-0063; Feng Fang, 0000-0002-4468-6206.

## Introduction

Peroxisomes are single-membrane organelles that play pivotal roles in various metabolic pathways, including  $\beta$ -oxidation of very long-chain fatty acids (VLCFA), detoxification of hydrogen peroxide and glyoxylate, as well as synthesis of ether phospholipids, docosahexaenoic acid (DHA), and bile acids (1). Impairment of peroxisome biogenesis or maintenance causes peroxisome biogenesis disorders (PBDs), which represent a heterogeneous group of mostly autosomal recessive disorders. Approximately 80% of PBD patients fall under the Zellweger syndrome spectrum (ZSS) (2), which arises from defects in peroxin (PEX) genes and is categorized into 14 complementation groups (CGs) (3). Clinical manifestations encompass Zellweger spectrum disorders (ZSDs) and rhizomelic chondrodysplasia punctata (RCDP).

The *PEX26* gene is identified as the causative gene for PBD CG8 (4,5), which accounts for 3.4% of cases with PBD and 4.2% of cases with ZSDs (6). The gene is composed of six exons and is located on chromosome 22q11.21. The PEX26 protein, a 34-kDa type-II peroxisomal membrane protein (PMP), plays a critical role in the import of matrix proteins. This protein consists of 305 amino acids and comprises an extensive N-terminal domain, followed by a single transmembrane domain (TMD) and a concise C-terminal domain that extends

into the peroxisome matrix (4). PEX26 recruits Pex1-Pex6 complex through its N-terminal Pex6-binding domain (aa29–174) to form peroxisome exportomer complex (7). This complex functions as a unit for relocating the ubiquitinated import receptor Pex5 (Ub-Pex5) from the peroxisomal membrane to the cytosol, facilitating repeated rounds of import of peroxisomal matrix proteins (4,6–9). The C-terminal region contains two Pex19-binding sites referred to as Pex19-binding domain 1 and Pex19-binding domain 2. These domains play a role in targeting PEX26 to peroxisomes (10,11).

The phenotypes caused by biallelic pathogenic variants in the *PEX26* gene encompass a spectrum of clinical manifestations that are consistent with ZSDs, ranging from severe PBD 7A (PBD7A) to milder PBD 7B (PBD7B). Infants with PBD7A typically present symptoms such as poor feeding, seizures, hepatic dysfunction, and severe hypotonia, often resulting in early mortality. Older children exhibit significant developmental delay, retinal dystrophy, and sensorineural hearing loss. Most patients also display typical craniofacial features including a high forehead, hypoplastic supraorbital ridges, midface hypoplasia, epicanthal folds, and a large anterior fontanel. Patients with PBD7B exhibit abnormalities resembling PBD7A, albeit with less severity, and typically survive until early childhood, occasionally reaching their third decade or beyond (12,13). In the present case study, we have identified a novel heterozygous variant comprising two previously unidentified variants in the *PEX26* gene in a male infant presenting with PBD7B. We present this article in accordance with the CARE reporting checklist (available at <https://tp.amegroups.com/article/view/10.21037/tp-23-454/rc>).

### Highlight box

#### Key findings

- The present study reports a novel heterozygous variant in the *PEX26* gene identified through exome sequencing in an infant male exhibiting multiple systemic anomalies.

#### What is known and what is new?

- The dysfunction of the PEX26 protein results in Zellweger spectrum disorders (ZSDs) with varying degrees of clinical phenotypic severity. Symptomatic supportive treatment and regular follow-up are the main management. A total of 24 genotypes and 29 variants have been documented in *PEX26*.
- The present study reports a novel heterozygous variant comprising two previously unidentified variants in the *PEX26* gene to expand the spectrum of genetic alterations.

#### What is the implication, and what should change now?

- The application of exome sequencing is particularly valuable in the diagnosis of ZSDs. The lack of a curative therapy for ZSDs necessitates the importance of continuous monitoring, as pathologies may gradually manifest and progress over time.

## Case presentation

The patient, a 7-month-old male infant, was admitted to our hospital due to hepatic function damage persisting for 2 months. He was delivered at full term, weighing 2.7 kg and measuring 51 cm in length. By the time he was admitted, his weight (7.5 kg) fell within the 10th percentile on standardized growth curves provided by Capital Institute of Pediatrics (14), while his length was at the 25th percentile. Physical examination revealed a high forehead and an unclosed flat anterior fontanelle measuring 4 cm  $\times$  4 cm. He exhibited involuntary babbling and laughter but showed no response to his name, with intermittent gaze-

**Table 1** Mutation information of the *PEX26* gene in the patient

Gene	Nucleotide and amino acid change	gnomAD MAF	ACMG rating of variation	The mode of inheritance	Parent of origin
<i>PEX26</i>	NM_001127649.3: exon2: c.347T>C (p.Leu116Pro)	–	Clinical significance is unclear	Autosomal recessive inheritance	Parent 1
	NM_001127649.3: exon3: c.616C>T (p.Gln206*)	–	Suspected pathogenicity	Autosomal recessive inheritance	Parent 2

\*, termination. gnomAD, The Genome Aggregation Database; MAF, minor allele frequency; ACMG, American College of Medical Genetics and Genomics.

following ability. Motor milestones included head control achieved at 3 months of age and rolling over accomplished at 5 months old. However, he had not yet attained independent sitting ability at 7 months old. Pulmonary rales or cardiac murmurs were absent upon auscultation. A blunted liver edge could be palpated approximately 2 cm below the costal margin. The vertebral column displayed physiological curvature, and muscular tension appeared normal in this child born from a non-consanguineous marriage. All procedures performed in this study were in accordance with the ethical standards of the institutional and/or national research committee(s) and with the Helsinki Declaration (as revised in 2013). Written informed consent was obtained from the guardian of the patient for the publication of this case report and accompanying images. A copy of the written consent is available for review by the editorial office of this journal.

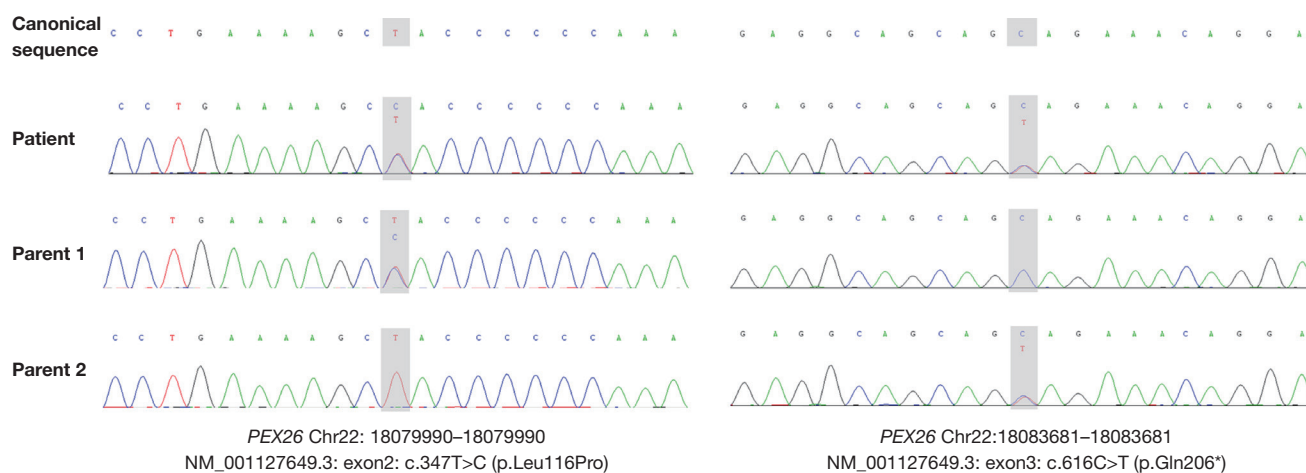
The auditory brainstem response exhibited aberrant findings, and abdominal ultrasound revealed hepatic protrusion of 2 cm below the right costal margin with unremarkable morphology. The inner diameters of gallbladder cross section (5.2 cm × 0.9 cm) and the spleen thickness (2.6 cm) were normal. Bilateral hip X-ray revealed small femoral head epiphyses with fragmented changes indicative of developmental dysplasia of the hip. No abnormalities were found in electrocardiography, the chest X-ray, or cerebral magnetic resonance imaging (MRI).

Blood alanine aminotransferase measured at 540 U/L (normal 0–40 U/L) and aspartate aminotransferase at 1,408 U/L (normal 0–40 U/L) exhibited significant elevation, while total bile acid (21.2 µmol/L, normal 0–12 µmol/L) slightly exceeded the anticipated range. The serum albumin (47.7 g/L), gamma-glutamyl transpeptidase (27 U/L), total bilirubin (5.2 µmol/L), alkaline phosphatase (291 U/L), creatine kinase (180 U/L), lactic dehydrogenase (372 U/L), plasma ammonia concentration (25.4 µmol/L), and blood lactate concentration (1.09 mmol/L) demonstrated normal findings. Blood coagulation

function was within the normal range. Levels of vitamin D (62 ng/mL) and serum calcium (2.2 mmol/L) were within the reference values. Blood levels of immunoglobulins and complement C3 and C4 were within normal limits. Ceruloplasmin measured at 0.3 g/L was in the normal range. Alpha fetoprotein (AFP) measured at 1,621 ng/mL indicated rapid hepatocyte proliferation following injury. The results of the tests for Epstein-Barr virus, human cytomegalovirus, and hepatitis virus were negative. The gas chromatography-mass spectrometry (GC-MS) analysis of the urine specimen revealed elevated levels of octanoic acid, octanedioic acid, and sebacic acid. Tandem mass spectrometry showed elevated levels of plasma very long chain fatty acid (VLCFA) C26:0 (5.057 µmol/L, normal 0.51±0.132 µmol/L), C26:0/C22:0 (0.420, normal 0.017±0.006), and C24:0/C22:0 (1.993, normal 0.883±0.277), consistent with peroxisomal fatty acid oxidation disorder. The level of C22:0 was decreased while that of C24:0 was normal.

Subsequent exome sequencing identified compound heterozygous variants in exon2 [c.347T>C (p.Leu116Pro)] and exon3 [c.616C>T (p.Gln206\*)] of the *PEX26* gene (Table 1). The former missense variant is predicted to be deleterious by SIFT (<http://sift.jcvi.org/>), Polyphen2\_HDIV&HVAR (<http://genetics.bwh.harvard.edu/pph2/>), Mutation Taster (<https://www.mutationtaster.org/>), and Mutation Assessor (<http://mutationassessor.org/>), while the latter is a nonsense variant and suspected to be pathogenic variant as it may mediate mRNA degradation leading to downregulation of gene expression. Both variants are absent in the Genome Aggregation Databases (gnomAD), indicating their rarity in populations. The parents have a non-consanguineous marriage and each of them is heterozygous to one of the two variants as determined by Sanger sequencing (Figure 1). The involvement of any other phenotypically related variant in this case was not identified (Table S1).

Based on physical examination, conventional laboratory



**Figure 1** The exome sequencing followed by Sanger validation. The *PEX26* gene harbored two novel variants, namely c.347T>C (Leu116Pro) and c.616C>T (Gln206\*), each parent is heterozygous to one of the two variants. \*, termination.

assessment, imaging procedures, and exome sequencing, we concluded that the patient may have suffered from PBD7B. Currently there are no curative therapies available for ZSDs.

## Discussion

To date, a total of 24 genotypes and 29 variants have been documented in the *PEX26* gene. The “lovd” database (<https://www.lovd.nl/>) has reported an additional 21 unique variants without any documented cases (Table S2). In this study, we have identified two novel mutants: c.347T>C (p.Leu116Pro) and c.616C>T (p.Gln206\*) (Table 2) (Figure 2). Among these genotypes, more than half are homozygotes and present as PBD7A. Among these variants, the majority are missense mutations, while some are frameshift mutations leading to premature termination and null mutations. It has been observed that the instability of *PEX26* and its insufficient binding to Pex1-Pex6 are most likely responsible for the development of PBD CG8 (23). While the physiological splice variant *PEX26* $\Delta$ ex5 lacking a TMD remains functional (15). These findings suggest that null mutations and mutations affecting the formation of peroxisome exportomer complex will result in PBD CG8, while variants involving other domains, such as TMD and heptad repeats, may only cause minor or negligible phenotypic abnormalities. Peroxisome exportomer complex plays a crucial role in maintaining peroxisomal homeostasis by preventing pexophagy (8). As an important pexophagic signal, Ub-*PEX5* recruits NBR1, a Ub-binding

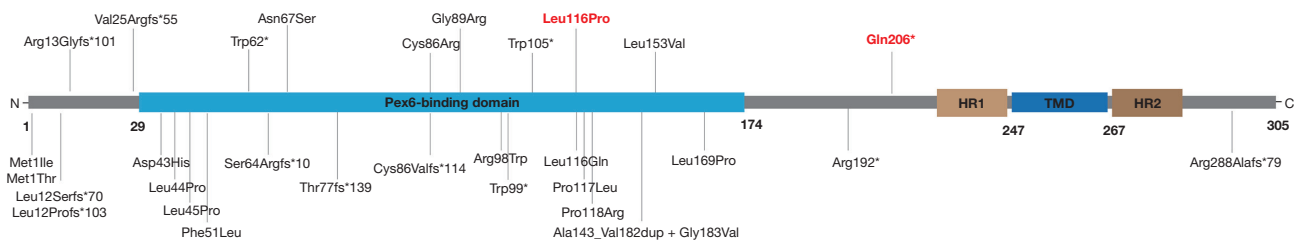
pexophagy receptor, to the peroxisomal membrane and triggers pexophagy. Diminished or impaired function of the peroxisome exportomer complex leads to a delayed clearance of Ub-*PEX5* from the peroxisomal membrane, resulting in an upregulation of pexophagy. Inhibiting excessive pexophagy using autophagic inhibitors restores normal levels of peroxisomes count, PTS1-protein import efficiency, and VLCFA  $\beta$ -oxidation in cells with mutations in *PEX1* gene (27). However, Klouwer *et al.* observed that despite the use of autophagy inhibitors resulting in an increased abundance of PMPs, there was no corresponding enhancement in peroxisomal functionality (28). Further research is still required for the clinical application of autophagy inhibitors. The identified missense mutation [c.347 T>C (p.Leu116Pro)] reported here is located within the crucial Pex6-binding domain and has potential to disrupt the peroxisome exportomer complex formation. Multiple mutation prediction software indicates that this mutation is deleterious.

The biochemical abnormalities of ZSDs involves the accumulation of VLCFA, phytanic acid, pristanic acid, pipercolic acid, and C27-bile acid intermediates in plasma and reduced levels of plasmalogens in erythrocytes (6,13). The potential clinical relevance of these biochemical abnormalities has been summarized in a review conducted by Klouwer *et al.* (29): tissue accumulation of VLCFA may lead to damage in the brain, nerves, and adrenal glands. DHA deficiency affects brain function and vision. The excessive presence of pristanic acid can impair cerebral function. The presence of bile acid intermediates, namely

**Table 2** Recorded mutations in the *PEX26* gene

No.	Mutation	Zygoty	Number of patients	Reference
1	T35insC (Leu12Profs*103)	Hom	3	(5)
2	296G>A (Trp99*)	Hom	4	(2)
3	230+1G>T (Thr77fs*139)	Hom	1	(15)
4	73_79delGTGCGCG (Val25Argfs*55)	Hom	1	(16)
5	185G>A (Trp62*)	Hom	1	(16)
6	315G>A (Trp105*)	Hom	1	(16)
7	256T>C (Cys86Arg)	Hom	1	(17)
8	265G>A (Gly89Arg)	Hom	2	(5)
9	200A>G (Asn67Ser)	Hom	1	(18)
10	153C>A (Phe51Leu)	Hom	6	(19)
11	506T>C (Leu169Pro)	Hom	1	(20)
12	347T>A (Leu116Gln)	Hom	1	(21)
13	34del (Leu12Serfs*70)	Hom	1	(22)
14	292C>T (Arg98Trp)	Hom	10	(5,15)
15	292C>T (Arg98Trp), 254insT (Cys86Valfs*114)	Het	1	(5,15)
16	292C>T (Arg98Trp), 131T>C (Leu44Pro)	Het	2	(15,23)
17	292C>T (Arg98Trp), 426_548dup122bpinsT (Ala143_Val182dup+Gly183Val)	Het	1	(15)
18	292C>T (Arg98Trp), 574C>T (Arg192*)	Het	2	(2)
19	292C>T (Arg98Trp), 3G>A (Met1Ile)	Het	1	(24)
20	292C>T (Arg98Trp), 127G>C (Asp43His)	Het	1	(24)
21	2T>C (Met1Thr), 134T>C (Leu45Pro)	Het	1	(5,15)
22	350C>T (Pro117Leu), 457C>G (Leu153Val) + 861del C (Arg288Alafs*79)	Het	2	(15,23)
23	37_38delAG (Arg13Glyfs*101), 667+2T>C	Het	2	(2,25)
24	192_216del25 (Ser64Argfs*10), 353C>G (Pro118Arg)	Het	2	(2,25,26)
25	347T>C (Leu116Pro), 616C>T (Gln206*)	Het	1	This study

\*, termination. fs, frameshift; Hom, homozygote; Het, heterozygote.



**Figure 2** Recorded variants in the *PEX26* gene and corresponding sequence annotations within the *PEX26* protein (refer to *Table 2*). Red font: variants documented in this case. TMD, transmembrane domain; HR, heptad repeat.



3 $\alpha$ ,7 $\alpha$ ,12 $\alpha$ -trihydroxycholestanoic acid (THCA) and 3 $\alpha$ ,7 $\alpha$ -dihydroxycholestanoic acid (DHCA), has been observed in the brain and liver and is believed to contribute to central nervous system damage and liver toxicity. Deficiency in plasmalogens leads to growth retardation, psychomotor impairment, cataracts, and anomalies in bone development. Klouwer *et al.* also found that there is a significant positive correlation between plasma levels of C26:0 and the C26:0/C22:0 ratio as well as dried blood spot levels of C26:0-lysoPC and the severity of ZSDs (30). However, it should be noted that biochemical tests may appear normal or mildly abnormal in some patients with mild ZSDs probably due to limited disease progression. This was observed in our case where only VLCFA accumulation was detected. Further testing using fibroblasts obtained from patients can help establish pathogenicity. Unfortunately, this test could not be conducted in our case due to a refusal for a skin biopsy. Given the heterogeneous nature of the disorder which may impede clinical diagnosis considering that evidence of biochemical abnormalities may be limited or absent in individuals with mild ZSDs, exome sequencing, as employed in our case, proves particularly valuable for diagnosing ZSDs (31).

The predominant clinical manifestations in this case included hepatic impairment with hepatomegaly, sensorineural hearing loss, developmental delay, abnormal ossification such as a large anterior fontanelle and developmental dysplasia of the hip, mild craniofacial dysmorphology such as a high forehead. According to the severity scoring system developed by Klouwer *et al.* (30), this patient scored one point for each of the following domains: growth, facial morphology, hearing loss, liver function abnormalities, and skeletal anomalies. We deemed it necessary to continue monitoring despite not requiring additional care. Hepatic involvement may exhibit age-related variability, therefore regular evaluation of hepatic function through liver function tests, liver ultrasonography, liver elastography, and liver biopsy should be considered to assess the extent of hepatic injury and fibrosis (13,26). Cholic acid (CA) therapy has demonstrated therapeutic efficacy in young patients with less severe liver damage (32,33). Other symptomatic treatments include oral administration of vitamin K and D supplements. A diet low in phytanic acid content and oral DHA therapy are recommended to improve partial biochemical abnormalities. As sensorineural hearing loss may worsen over time, the use of hearing aids or cochlear implant has been proposed for ameliorating this condition. Regular evaluation of other

health indicators such as skeletal function, nutrition, growth, psychomotor skills, renal and adrenal abnormalities, vision should be conducted to monitor disease progression and for the implementation of timely symptomatic treatment. Additionally, regular reevaluation of cerebral MRI of the head during follow-up is recommended because pathologies may gradually manifest and progress over time (17,34).

In recent years, researchers have recognized that pexophagy plays a crucial role in the pathogenesis of PBDs caused by variants in *PEX1*, *PEX6*, and *PEX26* genes. Therefore, targeting pexophagy may represent a promising therapeutic strategy for these patients (8). Prior to the availability of an effective treatment, early prenatal testing or preimplantation genetic diagnosis is necessary for families with a recurrence risk of PBD disorders (35).

## Conclusions

Biallelic pathogenic variants in the *PEX26* gene give rise to a spectrum of multiple congenital disorders known as ZSDs. Through exome sequencing, we identified two novel variants in the *PEX26* gene in a male patient. The missense mutation c.347T>C (p.Leu116Pro) is located within the crucial Pex6-binding domain and is predicted to be deleterious by multiple mutation prediction software. The nonsense mutation c.616C>T (p.Gln206\*) is suspected to be a pathogenic variant. The predominant clinical manifestations observed in this patient included hepatic impairment with hepatomegaly, sensorineural hearing loss, developmental delay, abnormal ossification and mild craniofacial dysmorphology. Currently, there are no curative therapies available for ZSDs; therefore, symptomatic supportive treatment has been provided to the patient who is undergoing regular follow-up appointments. This report expands upon the spectrum of known mutants in *PEX26* and highlights the effectiveness of highly efficient exome sequencing in patients presenting with undefined multiple system dysfunctions.

## Acknowledgments

We are grateful to the patient and his family for their contributions to this work.

*Funding:* None.

## Footnote

*Reporting Checklist:* The authors have completed the CARE

reporting checklist. Available at <https://tp.amegroups.com/article/view/10.21037/tp-23-454/rc>

*Peer Review File:* Available at <https://tp.amegroups.com/article/view/10.21037/tp-23-454/prf>

*Conflicts of Interest:* All authors have completed the ICMJE uniform disclosure form (available at <https://tp.amegroups.com/article/view/10.21037/tp-23-454/coif>). The authors have no conflicts of interest to declare.

*Ethical Statement:* The authors are accountable for all aspects of the work in ensuring that questions related to the accuracy or integrity of any part of the work are appropriately investigated and resolved. All procedures performed in this study were in accordance with the ethical standards of the institutional and/or national research committee(s) and with the Helsinki Declaration (as revised in 2013). Written informed consent was obtained from the guardian of the patient for the publication of this case report and accompanying images. A copy of the written consent is available for review by the editorial office of this journal.

*Open Access Statement:* This is an Open Access article distributed in accordance with the Creative Commons Attribution-NonCommercial-NoDerivs 4.0 International License (CC BY-NC-ND 4.0), which permits the non-commercial replication and distribution of the article with the strict proviso that no changes or edits are made and the original work is properly cited (including links to both the formal publication through the relevant DOI and the license). See: <https://creativecommons.org/licenses/by-nc-nd/4.0/>.

## References

- Wanders RJ, Waterham HR. Biochemistry of mammalian peroxisomes revisited. *Annu Rev Biochem* 2006;75:295-332.
- Yik WY, Steinberg SJ, Moser AB, et al. Identification of novel mutations and sequence variation in the Zellweger syndrome spectrum of peroxisome biogenesis disorders. *Hum Mutat* 2009;30:E467-80.
- Fujiki Y, Okumoto K, Mukai S, et al. Peroxisome biogenesis in mammalian cells. *Front Physiol* 2014;5:307.
- Matsumoto N, Tamura S, Fujiki Y. The pathogenic peroxin Pex26p recruits the Pex1p-Pex6p AAA ATPase complexes to peroxisomes. *Nat Cell Biol* 2003;5:454-60.
- Matsumoto N, Tamura S, Furuki S, et al. Mutations in novel peroxin gene PEX26 that cause peroxisome-biogenesis disorders of complementation group 8 provide a genotype-phenotype correlation. *Am J Hum Genet* 2003;73:233-46.
- Waterham HR, Ebberink MS. Genetics and molecular basis of human peroxisome biogenesis disorders. *Biochim Biophys Acta* 2012;1822:1430-41.
- Guder P, Lotz-Havla AS, Woidy M, et al. Isoform-specific domain organization determines conformation and function of the peroxisomal biogenesis factor PEX26. *Biochim Biophys Acta Mol Cell Res* 2019;1866:518-31.
- Nazarko TY. Pexophagy is responsible for 65% of cases of peroxisome biogenesis disorders. *Autophagy* 2017;13:991-4.
- Tamura S, Matsumoto N, Takeba R, et al. AAA peroxins and their recruiter Pex26p modulate the interactions of peroxins involved in peroxisomal protein import. *J Biol Chem* 2014;289:24336-46.
- Yagita Y, Hiromasa T, Fujiki Y. Tail-anchored PEX26 targets peroxisomes via a PEX19-dependent and TRC40-independent class I pathway. *J Cell Biol* 2013;200:651-66.
- Halbach A, Landgraf C, Lorenzen S, et al. Targeting of the tail-anchored peroxisomal membrane proteins PEX26 and PEX15 occurs through C-terminal PEX19-binding sites. *J Cell Sci* 2006;119:2508-17.
- Braverman NE, Raymond GV, Rizzo WB, et al. Peroxisome biogenesis disorders in the Zellweger spectrum: An overview of current diagnosis, clinical manifestations, and treatment guidelines. *Mol Genet Metab* 2016;117:313-21.
- Enns GM, Ammous Z, Himes RW, et al. Diagnostic challenges and disease management in patients with a mild Zellweger spectrum disorder phenotype. *Mol Genet Metab* 2021;134:217-22.
- Capital Institute of Pediatrics, Coordinating Study Group of Nine Cities on the Physical Growth and Development of Children. Growth standardized values and curves based on weight for length/height, body mass index for Chinese children under 7 years of age. *Zhonghua Er Ke Za Zhi* 2009;47:281-5.
- Weller S, Cajigas I, Morrell J, et al. Alternative splicing suggests extended function of PEX26 in peroxisome biogenesis. *Am J Hum Genet* 2005;76:987-1007.
- Ebberink MS, Mooijer PA, Gootjes J, et al. Genetic classification and mutational spectrum of more than 600 patients with a Zellweger syndrome spectrum disorder. *Hum Mutat* 2011;32:59-69.
- Stowe RC, Agarwal S. Novel PEX26 Mutation Causing Zellweger Syndrome Presenting as Feeding Intolerance

- and Hypotonia. *Pediatr Neurol* 2017;75:96-7.
18. Khan HH, Mew NA, Kaufman SS, et al. Unusual Cystic Fibrosis Transmembrane Conductance Regulator Mutations and Liver Disease: A Case Series and Review of the Literature. *Transplant Proc* 2019;51:790-3.
  19. Tanaka AJ, Okumoto K, Tamura S, et al. A newly identified mutation in the PEX26 gene is associated with a milder form of Zellweger spectrum disorder. *Cold Spring Harb Mol Case Stud* 2019;5:a003483.
  20. Kim YJ, Abe Y, Kim YJ, et al. Identification of a Homozygous PEX26 Mutation in a Heimler Syndrome Patient. *Genes (Basel)* 2021;12:646.
  21. Semenova NA, Kurkina MV, Marakhonov AV, et al. A novel mutation in the PEX26 gene in a family from Dagestan with members affected by Zellweger spectrum disorder. *Mol Genet Metab Rep* 2021;27:100754.
  22. He Y, Lin SB, Li WX, et al. PEX26 gene genotype-phenotype correlation in neonates with Zellweger syndrome. *Transl Pediatr* 2021;10:1825-33.
  23. Furuki S, Tamura S, Matsumoto N, et al. Mutations in the peroxin Pex26p responsible for peroxisome biogenesis disorders of complementation group 8 impair its stability, peroxisomal localization, and interaction with the Pex1p x Pex6p complex. *J Biol Chem* 2006;281:1317-23.
  24. Neuhaus C, Eisenberger T, Decker C, et al. Next-generation sequencing reveals the mutational landscape of clinically diagnosed Usher syndrome: copy number variations, phenocopies, a predominant target for translational read-through, and PEX26 mutated in Heimler syndrome. *Mol Genet Genomic Med* 2017;5:531-52.
  25. Steinberg S, Chen L, Wei L, et al. The PEX Gene Screen: molecular diagnosis of peroxisome biogenesis disorders in the Zellweger syndrome spectrum. *Mol Genet Metab* 2004;83:252-63.
  26. Warren M, Mierau G, Wartchow EP, et al. Histologic and ultrastructural features in early and advanced phases of Zellweger spectrum disorder (infantile Refsum disease). *Ultrastruct Pathol* 2018;42:220-7.
  27. Law KB, Bronte-Tinkew D, Di Pietro E, et al. The peroxisomal AAA ATPase complex prevents pexophagy and development of peroxisome biogenesis disorders. *Autophagy* 2017;13:868-84.
  28. Klouwer FCC, Falkenberg KD, Ofinan R, et al. Autophagy Inhibitors Do Not Restore Peroxisomal Functions in Cells With the Most Common Peroxisome Biogenesis Defect. *Front Cell Dev Biol* 2021;9:661298.
  29. Klouwer FC, Berendse K, Ferdinandusse S, et al. Zellweger spectrum disorders: clinical overview and management approach. *Orphanet J Rare Dis* 2015;10:151.
  30. Klouwer FCC, Meester-Delver A, Vaz FM, et al. Development and validation of a severity scoring system for Zellweger spectrum disorders. *Clin Genet* 2018;93:613-21.
  31. Ventura MJ, Wheaton D, Xu M, et al. Diagnosis of a mild peroxisomal phenotype with next-generation sequencing. *Mol Genet Metab Rep* 2016;9:75-8.
  32. Steinberg SJ, Dodt G, Raymond GV, et al. Peroxisome biogenesis disorders. *Biochim Biophys Acta* 2006;1763:1733-48.
  33. Berendse K, Klouwer FC, Koot BG, et al. Cholic acid therapy in Zellweger spectrum disorders. *J Inherit Metab Dis* 2016;39:859-68.
  34. Weller S, Rosewich H, Gärtner J. Cerebral MRI as a valuable diagnostic tool in Zellweger spectrum patients. *J Inherit Metab Dis* 2008;31:270-80.
  35. Al-Sayed M, Al-Hassan S, Rashed M, et al. Preimplantation genetic diagnosis for Zellweger syndrome. *Fertil Steril* 2007;87:1468.e1-3.

**Cite this article as:** Huang Y, Liu L, Fang F, Zhou H, Liu X. Identification of a novel heterozygous variant in the *PEX26* gene in an infant: a case report. *Transl Pediatr* 2024;13(1):192-199. doi: 10.21037/tp-23-454