



Original research

Influence of standard corneal cross-linking in keratoconus patients on macular profile

Mohammad Mirzaei^a, Masood Bagheri^{a,b,*}, Arash Taheri^a

^a Department of Ophthalmology, Nikookari Eye Center, Tabriz University of Medical Sciences, Tabriz, Iran

^b Students Research Committee, Tabriz University of Medical Sciences, Tabriz, Iran

Received 15 January 2018; revised 28 May 2018; accepted 9 June 2018

Available online 29 June 2018

Abstract

Purpose: To determine the effect of corneal cross-linking (CXL) on retinal structure and function.

Methods: The current study was conducted on 42 eyes of 21 patients with keratoconus (KCN) who were candidates for CXL due to disease progression. The Optovue optical coherence tomography (OCT) (Optovue Inc., Fremont, USA) from macula and multifocal electroretinography (mERG) were performed on all patients prior to surgery and at 1- and 6- month follow-up. Structural and functional parameters of macula including retinal thickness in OCT, and amplitude and latency of electroretinogram were compared between eyes that underwent surgery and control fellow eyes during the study period.

Results: A statistically significant increase in central foveal, foveal, parafoveal, and perifoveal thickness was observed at 1-month follow-up. The changes were non-significant at 6 months. Although a statistically significant reduction in amplitude and increase in latency in both rings 2 and 3 were observed at 1 month in mERG, only amplitude changes in ring 2 remained significant at 6 months.

Conclusion: Transient anatomical and functional alterations following CXL were observed in the current study.

Copyright © 2018, Iranian Society of Ophthalmology. Production and hosting by Elsevier B.V. This is an open access article under the CC BY-NC-ND license (<http://creativecommons.org/licenses/by-nc-nd/4.0/>).

Keywords: Corneal cross-linking; Keratoconus; Ultraviolet; Optical coherence tomography; Phototoxicity; Multifocal electroretinography

Introduction

Keratoconus (KCN) is a bilateral, non-inflammatory, and progressive ectasia, and its characteristic findings are corneal thinning and protrusion.¹ Clinical findings of the disease include progressive myopia associated with irregular astigmatism as well as characteristic finding in slit-lamp examinations.² Its prevalence is 1 per 2000 persons, and it is the most common cause of corneal transplantation in developed countries.^{1,3} Therapeutic interventions for such patients range from hard contact lenses to intra-stromal corneal rings and corneal transplantation. In the meantime, the corneal cross-

linking (CXL) to prevent the progression of the disease has become more popular in the last decade.

Cross-linking is a bond that links one polymer chain to another and can be a covalent or ionic bond in which the physical features of the polymer is changed.⁴ This procedure is extensively used in biology engineering to increase material strength and in dentistry for the hardening of filling materials.^{5,6} Riboflavin, also called vitamin B2, is a photosensitizer, health-essential, colored micronutrient for humans and animals. In the CXL procedure, a combination of riboflavin and ultraviolet-A (UV-A) is used to strengthen the biomechanical characteristics of the cornea. Riboflavin solely has no cross-linking property, but following absorption of UV-A energy, its electrons jump to higher level orbits, and its circular structure splits, which leads to oxygen free-radical and superoxide anions formation.^{7,8} These hyper-active molecules can cause cross-linking in corneal collagen, proteoglycan, and/or nucleic

* Corresponding author.

E-mail address: bagheri.m1368@gmail.com (M. Bagheri).

Peer review under responsibility of the Iranian Society of Ophthalmology.

acids through forming covalent bonds.⁹ For the first time in 1970, Siegel et al.^{10,11} described the cross-linking reaction in which the lysyl oxidase catalyzed the production of aldehyde bonds in collagen and elastin. The CXL was conducted for the first time in 2003 on human eyes¹²; henceforward several clinical trials were conducted to evaluate its effectiveness on the prevention of KCN progression.^{13,14} Recent studies showed that the CXL with riboflavin drops can biochemically increase the strength and stability of cornea.¹⁵ The procedure can increase the intra- or inter-fibrillar cross-links following photosensitized oxidation resulted by exposing riboflavin as a photomediator to UV-A.¹⁶ In the presence of riboflavin, almost 95% of irradiated UV-A are absorbed in 300 μm of the anterior corneal stroma, and to increase its penetration, the corneal epithelium is usually removed before applying the riboflavin. Hence, according to most studies, after removing the epithelium, at least 400 μm corneal thickness is required to prevent corneal endothelium damage.

Although CXL is generally considered a safe procedure, possible side effects have been reported including delay in corneal epithelium improvement, as well as bacterial, herpetic, and *Acanthamoeba* keratitis,^{17–19} corneal edema,¹⁵ reduced corneal sensitivity,^{20,21} affecting cornea limbal stem cells by inhibiting their growth and development,²² stromal sterilized infiltration, corneal haziness,²³ corneal thinning and toxicity,^{24–26} reduced permeability and drug penetration,²⁷ postsurgical pain,²⁸ persistent corneal edema, and endothelial cells damage.²⁹ As most of UV-A is absorbed by the cornea and lens, possible side effects on deeper layers such as the retina have not been extensively investigated.

Although most ultraviolet-B (UV-B) radiation striking the human eye is absorbed either by the cornea or by the high level of ascorbic acid in aqueous humor, a certain proportion is able to reach the lens epithelium where it can cause damage. UV-A light is able to reach more deeply into the lens where it can react with various chromophores to generate hydrogen peroxide, superoxide anion, and singlet oxygen.³⁰

There is evidence that UV and short wave light may have hazardous effect on the retina, so it is necessary to investigate possible changes in the retina following CXL. Evolving evidence shows that cumulative long-term exposure to UV radiation may be harmful to the retina and possibly leads to age-related macular degeneration (AMD), irrespective of age. Although much research was conducted to discover this relationship, the cellular and molecular mechanisms of retinal phototoxicity are still unknown.³¹

The current study aimed at evaluating the possible anatomical and functional changes in retinal and macular regions after CXL, using quantitative metrics measured by Optovue optical coherence tomography (OCT) and multifocal electroretinography (mERG).

Methods

All patients with KCN who were candidate for CXL (CCL-Vario Crosslinking; Peschke Meditrade GmbH, Zurich, Switzerland) and visited in the cornea clinic at ophthalmology

center in Tabriz, Iran, during March 2015 to October 2017 were included.

All patients underwent full ophthalmology examinations, uncorrected visual acuity (UCVA), best spectacle-corrected visual acuity (BSCVA), measuring refraction and evaluation of corneal topography using a Pentacam (Oculus, Germany). Thirty patients with KCN and without corneal scar who were the candidates for cross-linking due to disease progression (0.5 diopter increase in maximum keratometry or corneal steep meridian keratometry, increased topographic astigmatism over 0.5 diopter, or at least 20 μm corneal thickness decrease during 6 months) were enrolled in the study. Lack of willingness to cooperate with the study, comorbidity of retinchoroidal disease, history of any intraocular surgery, history of laser surgery, the thinnest point of the corneal thickness <400 μm , crystalline lens opacity, severe dry eye, autoimmune systemic diseases, and need for cross-linking in the opposite eye within the 6-month follow-up period were the exclusion criteria.

The protocol of cross-linking used in the current study was the standard protocol, called the Dresden Protocol, as described elsewhere.¹² Briefly, after local anesthesia with ocular topical anesthetics (Tetracaine hydrochloride ophthalmic solution 0.5%), central 8 mm epithelial zone was removed. After application of 0.1% riboflavin-5'-phosphate and 20% dextran solution on the epithelium free surface every 3–5 min for 30 min, UV-A irradiation (370 nm, 3 mW/cm²) during the 30 min alongside the application of the aforementioned solution for every 5 min was performed. At the end of surgery, topical antibiotics were administered and bandage soft contact lens were placed.

Optovue OCT (Optovue Inc., Fremont, USA) and mERG (Diagnosys LLC, Littleton, MA, USA) of macula were performed for all patients before CXL and repeated in 1 and 6 months after surgery. The macular parameters including macular thickness in central fovea (center point of fovea), fovea (the central 1 mm of macula), parafovea (the area located between fovea and perifovea with a radius of 3 mm), and perifovea (outermost area outside the parafovea with a radius of 5 mm) regions were separately measured in full, inner, and outer retinal maps (according to the analysis and calculations of the Optovue OCT). The segmentation was performed automatically by the device software. The mERG amplitude and latency changes were extracted up to 20° for 5 pericentral rings around the central fovea, by the mERG, and compared to fellow control eyes of the same patients. All images were provided under the constant condition using the same software. The electroretinography was performed monocularly, after maximally dilation of pupils with 1% tropicamide eye drops (after 30 min) and 15 min of adaptation in a bright room based on the International Society for Clinical Electrophysiology of Vision (ISCEV) guidelines.^{32–34} To reduce patients' discomfort, the anesthetic eye drop (Anestocaine; Sina Darou, Tehran, Iran) was used before tests.

In all stages, the patients' BSCVA was measured using the Snellen chart and exchanged to the logarithm of the minimum of angle resolution (logMAR) for statistical analyses.

Finally, the collected data were analyzed with IBM SPSS software (version 13; SPSS, Chicago, IL) using the paired samples *t* test, independent *t* test, and the Wilcoxon and the Mann-Whitney U tests. Data obtained from macular thickness had normal distribution in all full, inner, and outer retinal maps whereas based on mERG findings, the amplitude and latency in both groups had non-normal distribution. Hence, a non-parametric test was used.

The aims and objectives of the study as well as the follow-up procedure were explained to the patients, and they were enrolled into the study by interest, and informed consents were obtained. This study was approved by the review board ethics committee of the training hospital and Tabriz University of Medical Sciences, Tabriz, Iran.

Results

A total of 30 patients who met the inclusion criteria were enrolled into the study and underwent corneal standard cross-linking based on the evidence of KCN progression. The opposite eyes of the patients were followed up as the control group. Out of the enrolled patients, 5 subjects withdrew from the study due to lack of interest, and 4 patients were excluded due to the need for cross-linking to the opposite eye. Finally, 42 eyes from 21 patients with KCN were studied. 12 (57.1%) patients were male, and 9 (42.9%) were female. The mean age of the patients was 20.9 ± 5.95 years, ranging from 10 to 32. Nine patients (42.9%) and 12 (57.1%) underwent CXL on their right and left eyes based on clinical indication, respectively. The means of UCVA and

BSCVA for the cross-linked eyes were 0.27 ± 0.08 and 0.72 ± 0.16 , respectively, and in the opposite eyes, they were 0.30 ± 0.10 and 0.81 ± 0.17 , respectively. Visual changes in the cross-linked eyes in 1- and 6-month follow-ups were statistically insignificant ($P = 0.073$ and 0.094 , respectively).

The mean thickness of macula in central fovea, fovea, parafovea, and perifovea before surgery in the eyes that underwent cross-linking were 213.14 ± 18.56 (ranged 182–265), 251.28 ± 20.12 (218–291), 325.38 ± 11.72 (307–352), and 295.61 ± 11.38 (280–318) micro-meters (μm), respectively; the means in the control eyes were 214.2 ± 25.59 (183–281), 252.55 ± 21.93 (217–293), 324.9 ± 17.46 (302–353), and 297.1 ± 16.97 (276–327) μm , respectively.

In addition, the mean inner retinal thickness in central fovea, fovea, parafovea, and perifovea regions before surgery in the eyes that underwent cross-linking were 29 ± 18.24 (6–71), 65.9 ± 11.66 (51–91), 126.95 ± 9.21 (111–142), and 111.35 ± 5.68 (103–125) μm , respectively. The means in the control eyes were 32.5 ± 22.19 (13–86), 68.95 ± 11.48 (50–91), 127.15 ± 15.11 (88–146), and 110.4 ± 9.88 (85–125) μm , respectively.

The mean outer retinal thickness in the central fovea, fovea, parafovea, and perifovea regions before surgery in the eyes that underwent cross-linking were 184.1 ± 10.30 (164–207), 180.5 ± 23.46 (117–206), 199.15 ± 8.79 (174–210), and 184.15 ± 7.80 (173–196) μm , respectively; the means in the control eyes were 183.75 ± 15.28 (158–207), 185.5 ± 11.29 (167–202), 198.1 ± 18.45 (179–234), and 186.9 ± 17.63 (168–217) μm , respectively (Table 1).

Table 1
Macular thickness in central fovea, fovea, parafovea, and perifovea separated in full/inner/outer retina before corneal cross-linking (CXL), 1- and 6-month follow-up in both eyes.

	CXL			Control			P value			
	Before	1 m	6 m	Before	1 m	6 m	CXL		Control	
							Before-1 m	Before-6 m	Before-1 m	Before-6 m
Full retinal map										
Foveal thickness	251.28 (20.12)	254.28 (24.47)	250.52 (20.29)	252.55 (21.93)	253.80 (19.38)	254.20 (20.45)	0.052	0.053	0.260	0.097
Central foveal thickness	213.14 (18.56)	214.76 (21.05)	212.85 (18.61)	214.20 (25.59)	219.60 (31.75)	213.60 (25.94)	0.251	0.436	0.310	0.163
Parafoveal thickness	325.38 (11.72)	325.52 (16.91)	318.76 (23.66)	324.90 (17.46)	327.30 (12.60)	327.65 (13.08)	0.934	0.166	0.155	0.059
Perifoveal thickness	295.61 (11.38)	297.76 (11.43)	295.95 (12.00)	297.10 (16.97)	297.70 (16.29)	297.55 (15.97)	0.163	0.617	0.443	0.216
Inner retinal map										
Foveal thickness	65.90 (11.66)	70.75 (12.34)	65.45 (12.00)	68.95 (11.48)	70.35 (11.31)	69.60 (10.77)	0.000	0.165	0.092	0.173
Central foveal thickness	29.00 (18.24)	35.60 (15.68)	29.60 (16.69)	32.50 (22.19)	32.60 (20.58)	32.80 (20.36)	0.019	0.644	0.151	0.141
Parafoveal thickness	126.95 (9.21)	135.35 (7.52)	129.15 (8.39)	127.15 (15.11)	128.20 (16.13)	127.10 (15.17)	0.000	0.051	0.091	0.910
Perifoveal thickness	111.35 (5.68)	117.05 (4.41)	112.30 (6.03)	110.40 (9.88)	110.85 (10.85)	110.45 (10.27)	0.000	0.053	0.875	0.970
Outer retina map										
Foveal thickness	180.50 (23.46)	185.70 (13.29)	185.30 (9.52)	185.50 (11.29)	186.65 (10.51)	186.15 (9.85)	0.250	0.266	0.385	0.235
Central foveal thickness	184.10 (10.30)	180.05 (17.38)	182.80 (11.78)	183.75 (15.28)	179.65 (17.64)	180.80 (17.00)	0.300	0.546	0.153	0.159
Parafoveal thickness	199.15 (8.79)	194.65 (14.95)	195.35 (9.79)	198.10 (18.45)	198.30 (15.06)	197.60 (16.21)	0.173	0.054	0.901	0.580
Perifoveal thickness	184.15 (7.80)	183.45 (11.45)	182.80 (7.40)	186.90 (17.63)	186.40 (15.16)	186.41 (16.58)	0.712	0.900	0.558	0.053

Central fovea (center point of fovea), fovea (the central 1 mm of macula), parafovea (the area located between fovea and perifovea with a radius of 3 mm), and perifovea (the outermost area outside the parafovea with a radius of 5 mm).

CXL: Corneal cross-linking, Thickness unit: μm .

Numbers are Mean \pm SD.

In the analysis of macular thickness changes, the results of the paired samples *t* test showed no significant changes in central fovea, fovea, parafovea, and perifovea regions of full and outer retinal maps in the intervention group before and after cross-linking. Nevertheless, in 1-month follow-up, the changes in each of the 4 regions showed significant changes in the inner retinal map assessments. The macular thickness in inner retinal map for central fovea, fovea, parafovea, and perifovea regions increased from 29 ± 18.24 , 65.9 ± 11.66 , 126.95 ± 9.21 , 111.35 ± 5.68 to 35.6 ± 15.68 ($P = 0.019$), 70.75 ± 12.34 ($P < 0.000$), 135.35 ± 7.52 ($P < 0.000$), and $117.05 \pm 4.41 \mu\text{m}$ ($P < 0.000$), respectively. The increasing trend of macular thickness was not observed in 6-month follow-up examinations, and the changes in macular thickness in all evaluated regions were statistically insignificant. Also, macular thickness the control eyes in 1- and 6-month follow-ups showed no clinically significant changes compared to the baseline values (Table 1).

Data obtained from mERG were assessed as mean amplitude and latency in hexagonal regions of 5 concentric rings (Fig. 1). The mERG findings showed that the mean amplitude in 5 concentric rings around central fovea in the eyes that underwent cross-linking were 22.67 ± 19.79 , 45.50 ± 18.59 , 26.22 ± 13.65 , 17.87 ± 8.42 , and $15.08 \pm 7.99 \text{ nV/deg}^2$, respectively, and 22.31 ± 19.50 , 44.76 ± 21.83 , 28.14 ± 12.44 , 18.58 ± 9.51 , and $16.66 \pm 7.51 \text{ nV/deg}^2$ in the control eyes,

respectively. Also, mean latency in 5 concentric rings around central fovea in the CXL eyes were 38.12 ± 7.63 , 34.52 ± 4.14 , 34.22 ± 1.99 , 36.76 ± 5.02 , and 35.39 ± 0.95 milli-second (ms), respectively, while it was 37.32 ± 11.81 , 34.49 ± 3.06 , 35.02 ± 4.18 , 35.58 ± 2.64 , and 36.42 ± 2.19 ms in the control eyes, respectively.

Baseline values were similar statistically before surgery between the groups (Table 2).

In functional evaluations of macula by the mERG, the amplitude and latency measures of the rings 2 and 3 showed statistically significant changes at 1-month follow-up, compared with the pre-surgical measures. Changes in other rings were statistically insignificant in the 1-month follow-up assessments. The mean amplitude in the ring 2 reduced from 45.50 ± 18.59 in pre-surgical evaluations to $25.25 \pm 21.52 \text{ nV/deg}^2$ ($P = 0.011$) and in the ring 3 from 26.22 ± 13.65 to $14.20 \pm 10.93 \text{ nV/deg}^2$ ($P = 0.033$) in the 1-month follow-up. In addition, the mean latency increased significantly in the ring 2 from 34.52 ± 4.14 in pre-surgical assessments to $38.67 \pm 8.36 \text{ ms}$ ($P = 0.047$) and in the ring 3 from 34.22 ± 1.99 to $37.62 \pm 6.04 \text{ ms}$ ($P = 0.008$) in the 1-month follow-up.

Also, the amplitude changes in the ring 2 were statistically significant in the 6-month follow-up, while this parameter showed no significant changes in other regions. The mean amplitude in the ring 2 reduced from 45.50 ± 18.59 in

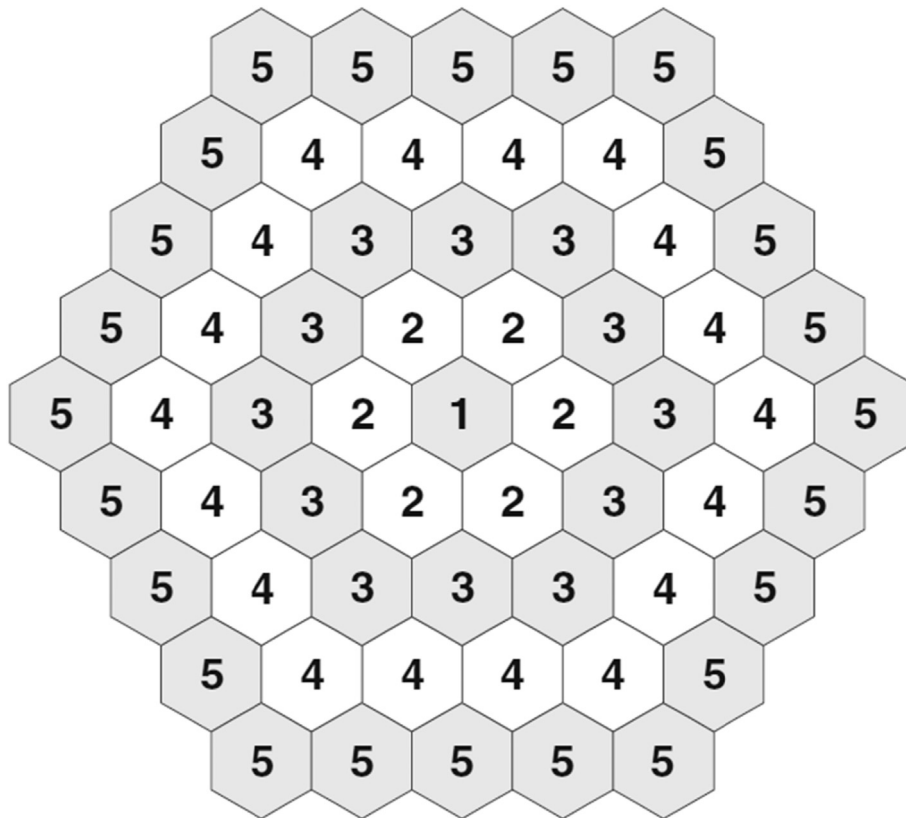


Fig. 1. Grouping of the 61 hexagons into concentric rings in multifocal electroretinography (mERG). (Extracted from Jonathan S. Lyos and Matthew L. Severns; Using Multifocal ERG ring ratio to detect and follow Plaquenil retinal toxicity: a review. Doc Ophthalmol 2009; 118:29–36).

Table 2
Amplitude and latency of multifocal electroretinography (mERG) in 1–5 rings before corneal cross-linking (CXL), 1- and 6-month follow-up in both eyes.

	CXL			Control			P value			
	Before	1 m	6 m	Before	1 m	6 m	CXL		Control	
							Before-1 m	Before-6 m	Before-1 m	Before-6 m
Ring1										
Latency	38.12 (7.63)	38.14 (7.36)	37.36 (7.03)	37.32 (11.81)	34.55 (9.17)	37.70 (11.28)	1.000	0.157	0.055	0.910
Amplitude	22.67 (19.79)	19.42 (20.09)	21.05 (20.01)	22.31 (19.50)	23.96 (15.83)	25.29 (16.70)	0.747	0.889	0.423	0.074
Ring2										
Latency	34.52 (4.14)	38.67 (8.36)	35.90 (4.88)	34.49 (3.06)	34.06 (3.20)	33.87 (2.98)	0.047	0.309	0.604	0.204
Amplitude	45.50 (18.59)	25.25 (21.52)	32.95 (19.38)	44.76 (21.83)	45.80 (21.02)	45.70 (25.42)	0.011	0.028	0.959	0.950
Ring3										
Latency	34.22 (1.99)	37.62 (6.04)	35.47 (2.76)	35.02 (4.18)	34.55 (4.41)	35.57 (4.19)	0.008	0.009	0.183	0.339
Amplitude	26.22 (13.65)	14.20 (10.93)	17.92 (12.22)	28.14 (12.44)	25.95 (12.93)	26.28 (14.53)	0.033	0.115	0.120	0.210
Ring4										
Latency	36.76 (5.02)	39.04 (7.34)	36.68 (5.98)	35.58 (2.64)	35.31 (1.95)	35.51 (2.27)	0.054	0.575	0.871	0.837
Amplitude	17.87 (8.42)	10.97 (8.11)	13.03 (7.63)	18.58 (9.51)	18.83 (10.42)	18.53 (10.15)	0.107	0.233	0.938	0.950
Ring5										
Latency	35.39 (0.95)	35.35 (3.57)	35.93 (2.51)	36.42 (2.19)	36.50 (2.35)	36.23 (1.79)	0.652	0.917	0.910	0.200
Amplitude	15.08 (7.99)	10.07 (8.06)	9.91 (7.89)	16.66 (7.51)	16.32 (8.37)	16.18 (8.35)	0.126	0.393	0.255	0.203

CXL: Corneal cross-linking, mERG: Multifocal electroretinography, Amplitude unit: nV/deg², Latency unit: ms. Numbers are Mean \pm SD.

pre-surgical assessments to 32.95 ± 19.38 ms ($P = 0.028$) in the 6-month follow-up. The latency changes were insignificant in all under study regions in the 6-month follow-up (Table 2).

In the 1- and 6-month follow-ups, no significant changes were observed in the control eyes (Table 2).

Discussion

CXL is a therapeutic option for progressive KCN.¹⁴ As with other new treatments, its safety is of particular importance. Previous studies have emphasized that in combination with riboflavin and in the presence of a minimal corneal thickness of 400 μ m, insignificant amounts of UV-A radiance reach inner ocular tissues, including the lens and retina, and that there is no evidence of UV-A induced damage in these tissues during CXL procedure.³⁵ Recent in vitro studies have revealed that corneal endothelial damage due to UV exposure is a possible risk.³⁶ Furthermore, some in vivo reports have raised concerns for corneal endothelial damage after standard CXL procedure.^{15,37} Therefore, it is possible that other intra-ocular complications occur after CXL.

The adverse effects of UV radiation on the eye have been suspected and recently have been studied in the field of epidemiology. Some studies evaluated the phototoxic effects of UV-A radiation on intraocular structures such as crystalline lens. Several in vivo and in vitro studies also considered UV light as a risk factor of lens damage and cataract. Different hypotheses also justified such toxic effects by the induced oxidative stress.³⁸ Azzam et al. reported that UV-A can imitate the senile cataract morphology and make changes in lens optics by damaging the lens cell membrane.³⁹ Another study by Hedge et al. indicated UV light as one of the most important risk factors for the induction of cataract. They also added that this effect is probably formed through the creation

of oxygen free-radicals in aqueous humor and crystalline lens.⁴⁰ However, a recent study on the intraocular complications of CXL evaluated the changes of crystalline lens density following the CXL procedure in patients with KCN and reported no significant changes in the density of crystalline lens following the procedure compared with the control group, based on the Pentacam Scheimpflug imaging system evaluations.⁴¹

Based on the extensive literature review conducted, this is, to the best of our knowledge, one of the few studies investigating CXL adverse event on macular profile among patients with progressive KCN. The study findings showed that the CXL had some transient changes that may be due to toxicity on macula, and alterations mostly involved inner areas of the retina. However, retinal changes were eliminated over time, and only small retinal functional changes were observed in 6-month follow-up evaluations.

Light toxicity frequently affects outer retina and retinal pigment epithelium (RPE) early after exposure. Chromophores are theorized to mediate the light-induced damage to the retina. Chromophores usually exist in the retina and RPE, namely the photoreceptors, flavoproteins, heme proteins, melanosomes, and lipofuscin. Therefore, RPE and outer retina are expected to be influenced more than inner retina.⁴² However, in our study, the micro-anatomical changes were more profound in inner layers. On the other hand, it should be noted that presence of astigmatism influenced the OCT measurements, and corneal characteristics were changed following CXL that had been taken approximately 3 months or more to be stabilized.⁴³ So, corneal characteristics alterations might explain the micro-anatomical changes of inner retina in the OCT. It should be noted that the lack of examination of corneal characteristic changes, as one of the important contributing factors of OCT analysis, was one of our study disadvantages.

The small sample size was one of the limitations of the current study. On the other hand, light toxicity starts early after exposure, so early changes after CXL may remain undetectable. Further studies on larger populations and more frequent evaluations in shorter intervals after the CXL are recommended. Future studies may use adaptive optics to show ultrastructural changes. Also, the complementary tests for more anatomical evaluations of the macula such as ganglion cell complex thickness, and functional evaluations such as microperimetry, color vision test (CVT), macular autofluorescence pigment density (MAFPD), and photostress recovery time (PSRT) may show the retinal changes after CXL.

References

- Rabinowitz YS. Keratoconus. *Surv Ophthalmol*. 1998;42(4):297–319. Matched ISSN: 0039-6257.
- Mihaltz K, Kovacs I, Takacs A, Nagy ZZ. Evaluation of keratometric, pachymetric, and elevation parameters of keratoconic corneas with pentacam. *Cornea*. 2009;28(9):976–980. Matched ISSN: 0277-3740.
- de Sanctis U, Loiacono C, Richiardi L, Turco D, Mutani B, Grignolo FM. Sensitivity and specificity of posterior corneal elevation measured by Pentacam in discriminating keratoconus/subclinical keratoconus. *Ophthalmology*. 2008;115(9):1534–1539. Matched ISSN: 0161-6420.
- Sorkin N, Varssano D. Corneal collagen crosslinking: a systematic review. *Ophthalmologica*. 2014;232(1):10–27. Matched ISSN: 0030-3755.
- Wollensak G, Spörl E, Seiler T. Treatment of keratoconus by collagen cross linking. *Ophthalmologie*. 2003;100(1):44–49. Matched ISSN: 0941-293X.
- Sung HW, Chang WH, Ma CY, Lee MH. Crosslinking of biological tissues using genipin and/or carbodiimide. *J Biomed Mater Res A*. 2003;64(3):427–438. Matched ISSN: 1549-3296.
- Wollensak G. Crosslinking treatment of progressive keratoconus: new hope. *Curr Opin Ophthalmol*. 2006;17(4):356–360. Matched ISSN: 1040-8738.
- Kamaev P, Friedman MD, Sherr E, Muller D. Photochemical kinetics of corneal cross-linking with riboflavin. *Invest Ophthalmol Vis Sci*. 2012;53(4):2360–2367. Matched ISSN: 0146-0404.
- Pacifici RE, Davies KJ. Protein degradation as an index of oxidative stress. *Methods Enzymol*. 1990;186(1):485–502. Matched ISSN: 0076-6879.
- Siegel RC, Pinnell SR, Martin GR. Cross-linking of collagen and elastin: properties of lysyl oxidase. *Biochemistry*. 1970;9(23):4486–4492. Matched ISSN: 0006-2960.
- Siegel RC. Biosynthesis of collagen crosslinks: increased activity of purified lysyl oxidase with reconstituted collagen fibrils. *Proc Natl Acad Sci USA*. 1974;71(12):4826–4830. Matched ISSN: 0027-8424.
- Wollensak G, Spoerl E, Seiler T. Riboflavin/ultraviolet-a-induced collagen crosslinking for the treatment of keratoconus. *Am J Ophthalmol*. 2003;135(5):620–627. Matched ISSN: 0002-9394.
- O'Brart DP, Kwong TQ, Patel P. Long-term follow-up of riboflavin/ultraviolet A (370 nm) corneal collagen cross-linking to halt the progression of keratoconus. *Br J Ophthalmol*. 2013;97(4):433–437. Matched ISSN: 0007-1161.
- Caporossi A, Mazzotta C, Baiocchi S. Long-term results of riboflavin ultraviolet a corneal collagen cross-linking for keratoconus in Italy: the Siena eye cross study. *Am J Ophthalmol*. 2010;149(4):585–593. Matched ISSN: 0002-9394.
- Sharma A, Nottage JM, Mirchia K, Sharma R, Mohan K, Nirankari VS. Persistent corneal edema after collagen cross – linking for keratoconus. *Am J Ophthalmol*. 2012;154(6):922–926. Matched ISSN: 0002-9394.
- Hafezi F, Mrochen M, Iseli HP, Seiler T. Collagen crosslinking with ultraviolet-A and hypoosmolar riboflavin solution in thin corneas. *J Cataract Refract Surg*. 2009;35(4):621–624. Matched ISSN: 0886-3350.
- Rama P, di Matteo F, Matuska S, Paganoni G, Spinelli A. Acanthamoeba keratitis with perforation after corneal crosslinking and bandage contact lens use. *J Cataract Refract Surg*. 2009;35(4):788–791. Matched ISSN: 0886-3350.
- Perez-Santonja JJ, Artola A, Javaloy J, Alio JL, Abad JL. Microbial keratitis after corneal collagen crosslinking. *J Cataract Refract Surg*. 2009;35(6):1138–1140. Matched ISSN: 0886-3350.
- Kymionis GD, Portaliou DM, Bouzoukis DI, et al. Herpetic keratitis with iritis after corneal crosslinking with riboflavin and ultraviolet A for keratoconus. *J Cataract Refract Surg*. 2007;33(11):1982–1984. Matched ISSN: 0886-3350.
- Wasilewski D, Mello GH, Moreira H. Impact of collagen crosslinking on corneal sensitivity in keratoconus patients. *Cornea*. 2013;32(7):899–902. Matched ISSN: 0277-3740.
- Kontadakis GA, Kymionis GD, Kankariya VP, Pallikaris AI. Effect of corneal collagen crosslinking on corneal innervation, corneal sensitivity, and tear function of patients with keratoconus. *Ophthalmology*. 2013;120(5):917–922. Matched ISSN: 0161-6420.
- Thorsrud A, Nicolaissen B, Drolsum L. Corneal collagen crosslinking in vitro: inhibited regeneration of human limbal epithelial cells after riboflavin-ultraviolet-A exposure. *J Cataract Refract Surg*. 2012;38(6):1072–1076. Matched ISSN: 0886-3350.
- Greenstein SA, Fry KL, Bhatt J, Hersh PS. Natural history of corneal haze after collagen crosslinking for keratoconus and corneal ectasia: Scheimpflug and biomicroscopic analysis. *J Cataract Refract Surg*. 2010;36(12):2105–2114. Matched ISSN: 0886-3350.
- Holopainen JM, Krootila K. Transient corneal thinning in eyes undergoing corneal cross-linking. *Am J Ophthalmol*. 2011;152(4):533–536. Matched ISSN: 0002-9394.
- Kymionis GD, Portaliou DM, Diakonou VF, Kounis GA, Panagopoulou SI, Grentzelos MA. Corneal collagen cross-linking with riboflavin and ultraviolet-A irradiation in patients with thin corneas. *Am J Ophthalmol*. 2012;153(1):24–28. Matched ISSN: 0002-9394.
- Kymionis GD, Kounis GA, Portaliou DM, et al. Intraoperative pachymetric measurements during corneal collagen cross-linking with riboflavin and ultraviolet A irradiation. *Ophthalmology*. 2009;116(12):2336–2339. Matched ISSN: 0161-6420.
- Stewart JM, Lee OT, Wong FF, Schultz DS, Lamy R. Cross-linking with ultraviolet-A and riboflavin reduces corneal permeability. *Invest Ophthalmol Vis Sci*. 2011;52(12):9275–9278. Matched ISSN: 0146-0404.
- Ghanem VC, Ghanem RC, Rd Oliveira. Postoperative pain after corneal collagen cross-linking. *Cornea*. 2013;32(1):20–24. Matched ISSN: 0277-3740.
- Skuta GL, Cantor LB, Weiss JS. Refractive surgery. *Am Acad Ophthalmol*. 2016-2017:123–124.
- Cantor LB, Rapuano CJ, Cioffi GA. Fundamental and principles of ophthalmology. *Am Acad Ophthalmol*. 2016–2017:232–238.
- Kraljević Pavelić S, Klobučar M, Sedić M, et al. UV-induced retinal proteome changes in the rat model of age-related macular degeneration. *Biochim Biophys Acta (BBA) – Mol Basis Dis*. 2015;1852(9):1833–1845.
- Lyons JS, Severns ML. Detection of early hydroxychloroquine retinal toxicity enhanced by ring ratio analysis of multifocal electroretinography. *Am J Ophthalmol*. 2007;143(5):801–809. Matched ISSN: 0002-9394.
- Marmor MF, Hood DC, Keating D. Guidelines for basic multifocal electroretinography (mfERG). *Doc Ophthalmol*. 2003;106(2):105–115. Matched ISSN: 0012-4486.
- Hood DC, Bach M, Brigell M. ISCEV guidelines for clinical multifocal electroretinography. *Doc Ophthalmol*. 2008;116(1):1–11. Matched ISSN: 0012-4486.
- Spoerl E, Mrochen M, Sliney D, Trokel S, Seiler T. Safety of UVA-riboflavin cross-linking of the cornea. *Cornea*. 2007;26(4):385–389. Matched ISSN: 0277-3740.
- Wollensak G, Spörl E, Reber F, Pillunat L, Funk R. Corneal endothelial cytotoxicity of riboflavin/UVA treatment in vitro. *Ophthalmic Res*. 2003;35(6):324–328. Matched ISSN: 0030-3747.
- Bagga B, Pahuja S, Murthy S, Sangwan VS. Endothelial failure after collagen cross-linking with riboflavin and UV-A: case report with literature review. *Cornea*. 2012;31(10):1197–1200. Matched ISSN: 0277-3740.

38. Varma SD, Kovtun S, Hegde KR. Role of UV irradiation and oxidative stress in cataract formation. Medical prevention by nutritional antioxidants and metabolic agonists. *Eye Contact Lens*. 2011;37(4):233–245. Matched ISSN: 1542-2321.
39. Azzam N, Levanon D, Dovrat A. Effects of UV-A irradiation on lens morphology and optics. *Exp Gerontol*. 2004;39(1):139–146. Matched ISSN: 0531-5565.
40. Hegde KR, Kovtun S, Varma SD. Induction of ultraviolet cataracts in vitro: prevention by Pyruvate. *J Ocul Pharmacol Therapeut*. 2007;23(5): 492–502. Matched ISSN: 1080-7683.
41. Baradaran-Rafii A, Amiri MA, Mohaghegh S, Zarei-Ghanavati M. Lens densitometry after corneal cross-linking in patients with keratoconus using a Scheimpflug camera. *J Ophthalmic Vis Res*. 2015;10(2): 118–122.
42. Busch EM, Gorgels TG, van Norren D. Temporal sequence of changes in rat retina after UV-A and blue light exposure. *Vis Res*. 1999;39(7): 1233–1247. Matched ISSN: 0042-6989.
43. Derakhshan A, Shandiz JH, Ahadi M, Daneshvar R, Esmaily H. Short-term outcomes of collagen crosslinking for early keratoconus. *J Ophthalmic Vis Res*. 2011;6(3):155–159.