

Femoral Hernia in Children: How to Avoid Misdiagnosis?

Basma Haggui, Saida Hidouri, Amine Ksia, Sana Mosbahi, Marwa Messaoud, Lassaad Sahnoun, Mongi Mekki, Mohsen Belghith, Abdellatif Nouri

Department of Pediatric Surgery, Medical School of Monastir, Fattouma Bourguiba Hospital, Monastir University, Research Laboratory LR12SP13, Tunisia

Abstract

Background: Femoral hernias are an uncommon groin pathology among pediatric patients. Therefore, they are frequently misdiagnosed. In the present study, we review our experience with this rare surgical entity during the past 25 years. **Methods:** The medical records of 19 patients who underwent 22 femoral hernia repairs between January 1994 and December 2019 were retrospectively analysed. **Results:** Patients' age ranged from 2 to 12 years (mean age was 5.5 years) with an approximately equal sex ratio (10 girls/9 boys). There were three bilateral cases identified separately. They were discovered and managed at different times. All the children were referred with a groin lump, but the correct pre-operative diagnosis was made in only 13 cases (59%). In the remaining cases, four were identified intraoperatively following negative exploration for a supposed inguinal hernia. The other five were found to have a femoral hernia 1 month to 12 months after ipsilateral inguinal hernia repair. All patients underwent elective surgery. The femoral canal was closed using either Lytle or McVay procedure. Recurrence occurred in only one patient 2 months after initial repair. **Conclusion:** Femoral hernias are often misdiagnosed. Pre-operative diagnosis can be obtained through careful clinical assessment. In equivocal cases, ultrasonography and laparoscopy could be useful. A correct pre-operative diagnosis will lead to suitable treatment, thus avoiding unnecessary reoperations and their related complications.

Keywords: Children, femoral hernia, inguinal hernia, paediatric surgery

INTRODUCTION

Femoral hernias rarely occur in children, with an incidence < 1% of all paediatric groin hernias.^[1,2] In adults, making the diagnosis may be problematic and expectedly is more challenging in the paediatric age group.^[3-6] Pre-operative misdiagnosis is common.^[7] Due to its close relationship to other groin bulges and its infrequency, femoral hernia may lead to misinterpretation and subsequently inappropriate treatment.^[1,8] Since this entity is so unusual in children, there is a risk that if incarceration happens, the condition may also be mistaken and surgery delayed.^[9]

The main goal of the present study is to discuss tools for diagnosis of paediatric femoral hernias through a report of our experience with this rare pathology and review of literature.

PATIENTS AND METHODS

We retrospectively identified 19 children who underwent femoral hernia repair between January 1994 and December

2019 in the department of paediatric surgery of Monastir. We recorded sex, age at presentation, laterality, previous inguinal surgery, presenting symptoms, pre-operative diagnosis, intraoperative findings, complications and follow-ups. Femoral hernia diagnosis was essentially made by clinical examination.

RESULTS

A total of 19 patients had 22 femoral hernia repairs over a 25-year period. All were aged between 2 and 12 years, with a mean age of 5.5 years. The majority of patients (94.7%) were under 10 years old (18 patients of 19). Hernias were almost equally distributed between males and females, 10 girls (52.6%) and 9 boys (47.3%). They were right sided in 13 cases, left sided in 3 cases and bilateral in 3 others. Bilateral

Address for correspondence: Dr. Amine Ksia,

Department of Pediatric Surgery, Medical School of Monastir, Fattouma Bourguiba Hospital, Monastir University, Tunisia Research Laboratory, LR12SP13, Tunis, Tunisia.
E-mail: amineks@yahoo.fr

Received: 21-05-2020 Revised: 05-07-2020 Accepted: 10-10-2020 Available Online: 20-07-2021

Access this article online

Quick Response Code:



Website:
www.afrijaedsurg.org

DOI:
10.4103/ajps.AJPS_74_20

This is an open access journal, and articles are distributed under the terms of the Creative Commons Attribution-NonCommercial-ShareAlike 4.0 License, which allows others to remix, tweak, and build upon the work non-commercially, as long as appropriate credit is given and the new creations are licensed under the identical terms.

For reprints contact: WKHLRPMedknow_reprints@wolterskluwer.com

How to cite this article: Haggui B, Hidouri S, Ksia A, Mosbahi S, Messaoud M, Sahnoun L, *et al.* Femoral hernia in children: How to avoid misdiagnosis? Afr J Paediatr Surg 2021;18:164-7.

cases were identified separately and the surgeries were carried out at different times. All hernias were reducible without episodes of bowel obstruction.

All patients were referred with a groin lump. Pre-operative diagnosis of femoral hernia was correctly established in 13 cases (59%). Of the 9 misdiagnosed cases (41%), 4 were found to have a femoral hernia intraoperatively following a negative inguinal exploration. The five others were found to have femoral hernia 1 month to 12 months after inguinal hernia repair of a presumed inguinal hernia [Figure 1].

Concomitant inguinal hernia occurred on the ipsilateral side in one case and contralateral side in two others. Femoral approach was used in 18 cases (81.81%) and inguinal approach in the other 4 (18.18%). A hernial sac was identified and inspected in 20 cases, of which 13 were empty and 7 contained omentum easily reduced into the abdominal cavity. There was no clear comment about sac identification in the remaining two operative notes. The hernial sac was closed using a high purse-string ligature and then resected in 19 cases [Figure 2]. The remaining case underwent a simple reduction of hernia content without resection.

The femoral ring was closed in all cases using Lytle procedure [Figure 3] in 18 cases and MacVay in the other four. Non-absorbable suture material was used in six cases and absorbable in three others. In the remaining cases, the suture material type was not mentioned in the report notes.

There was no immediate complication. All the children were discharged on the day of the operation. Only one case of recurrent right femoral hernia was diagnosed 2 months postoperatively. Femoral hernia diagnosis was correctly established preoperatively and the child underwent femoral hernia repair, but the hernial sac was not identified at the first intervention. The patient was reoperated on using Lytle procedure with a good outcome.

Subsequently, none of the patient has had another groin hernia on either side during the post-operative follow-up period between 3 months and 25 years.

DISCUSSION

Femoral hernia is an uncommon surgical entity in the paediatric population and the diagnosis remains a challenge.^[10] Distinct from adults, incidence rates were similar by sex but, like adults, right-sided hernias dominate.^[11] These facts are in accordance with our findings.

Although the aetiology of femoral hernia is still imprecise, McVay and Savage had proposed the hypothesis that a congenitally narrow insertion of the posterior inguinal wall on to Cooper's ligament results in enlargement of the femoral ring and predisposes to herniation in the event of high intra-abdominal pressure.^[12] However, a large series of post-mortem examination did not reveal congenital femoral hernia sac.^[9] Fresno *et al.* reported on children who developed



Figure 1: Right femoral hernia diagnosed in the 1st month postoperatively

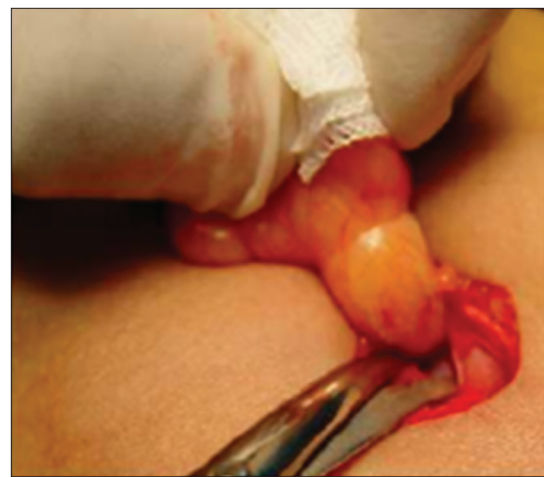

Figure 2: Hernial sac removal

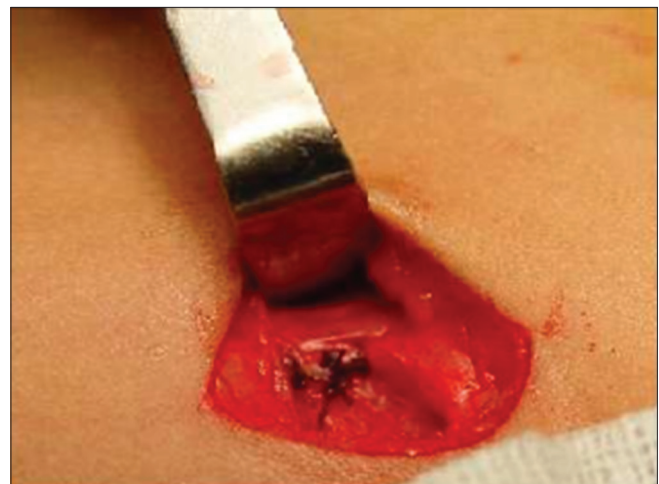

Figure 3: Femoral ring closure using Lytle procedure

symptoms in the neonatal period that led to the thought that there must be some congenital anatomic causal factors.^[13]

Femoral hernias are only appropriately diagnosed in 53% of cases. Thus, they are sometimes managed as regular inguinal

hernias with open approaches.^[2,8] In our series, the diagnosis was missed in 41% of cases. This was attributed to their relative infrequency and clinical presentation that may simulate other groin pathologies such as inguinal hernia, lymphadenitis, encysted hydrocele and torsion of an ectopic testis or ovary.^[9,11]

Incorrect diagnosis and treatment may be complicated by necrosis and perforation of the intestines with increased morbidity.^[11] Several authors reported strangulation rates of 10% to 40% for femoral hernias in the paediatric group.^[14] Femoral hernia diagnosis is mainly made by careful physical examination of soft and non-tender protrusion in the femoral triangle.^[15] It presents as a bulge below and lateral to the pubic tubercle, in a location inferior and lateral to that of the frequently occurring indirect hernia, and which is not controlled by digital occlusion of the internal inguinal ring.^[11,16-18]

In our series, nine patients were treated under the diagnosis of inguinal hernia. We think that the reasons for this misdiagnosis were most likely to be: (1) Failure to consider the diagnosis and inadequate physical assessment. (2) Rarity of femoral hernia and the higher incidence of inguinal hernia in this age group. Femoral hernia incidence in children has been estimated to be <0.5% of all groin hernias.^[3,6] (3) Non-inclusion of the femoral hernia in the differential diagnosis of groin area swellings.

In five of these nine cases, a history of ipsilateral inguinal hernia repair was found. The adequacy of the original repair may have been a femoral hernia predisposing factor, as it may weaken the femoral region.^[19] In the usual inguinal herniorrhaphy, the inguinal ligament may be under tension, so the femoral canal is opened wider than before operation resulting in femoral hernia formation.^[20]

A recent study examined the groin anatomy during laparoscopic operation for a recurrent inguinal hernia and concluded that patients who previously underwent Shouldice or Bassini sutured repair had severe anatomical changes predisposing to inguinal hernia recurrence and femoral hernia formation.^[21]

In the remaining misdiagnosed cases in this series (four cases of nine), patients were found to have femoral hernia repair after negative inguinal exploration. The absence of a presumed indirect inguinal hernia sac or a seeming indirect inguinal hernia recurrence suggests femoral hernia and should lead to femoral canal examination.^[14,22]

Appropriate femoral hernia diagnosis is made by careful medical history taking and clinical examination.^[23] However, there are known limitations to clinical appraisal. A considerable proportion of patients with signs evocative of hernia are found to have confusing physical examination findings. In this patient group, ultrasound can be employed as a safe and non-invasive diagnostic tool to confirm the femoral hernia diagnosis and show the hernia content.^[15,24,25] Ultrasound examination was not done in our series, but a study by Chen reported a correct

pre-operative diagnosis of uncommon groin hernias in all cases when using sonography.^[26,27]

In the pre-laparoscopic era, groin swelling mistaken as inguinal hernia was common and led to needless inguinal hernia repair.^[28] Laparoscopy has been recognised as a means to decrease misdiagnosis, as it visualises all possible hernia orifices and allows an objective view of the anatomy of rare groin hernias.^[15,29] Therefore, laparoscopic groin exploration may be a precious tool in the management of supposed recurrent inguinal hernias.^[8] Laparoscopic femoral hernia repair in children is reported to be technically achievable involving posterior approaches, as stated by several studies.^[8] Adibe reported a procedure in which the femoral sac was twisted and tied under laparoscopy, and the medial pectineal and inguinal ligaments were closed externally.^[10,30] We suggest that recurrent inguinal hernias should be explored by laparoscopy, given the high frequency of femoral hernias in such cases [Figure 4].

Although several procedures of femoral hernia repair are reported, the crucial elements in reducing morbidity seem to be early elective surgery, identification and ligation of the sac and femoral ring repair.^[11] In most series, paediatric femoral hernias are managed using the conventional McVay procedure, in which femoral ring closure is carried out by the apposition of the transversal fascia and Cooper's ligament through the open anterior approach.^[10] The majority of our patients (18 cases) underwent femoral hernia repair using Lytle procedure; After removal of the sac, a purse-string suture or interrupted sutures approximate Gimbernat's ligament anteriorly and medially, the pectineal fascia posteriorly and the femoral sheath laterally.^[31] Coley used this technique in 69 children without complications or recurrences.^[32]

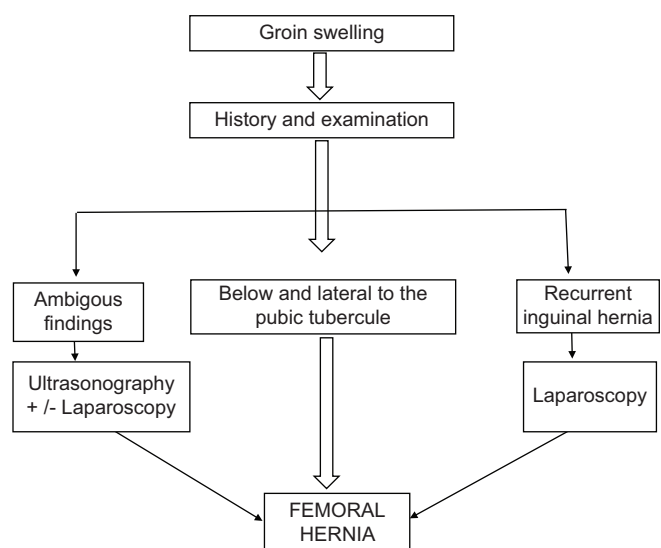


Figure 4: Algorithm for the diagnosis of femoral hernia

Apart from the only case of recurrence which was attributed to an inadequate operative technique, there was no other complication or recurrence in this series.

CONCLUSION

Femoral hernia diagnosis remains challenging. Attentive clinical assessment is the main diagnostic tool. Ultrasonography and laparoscopy are adjuncts that may significantly reduce misdiagnosis and incorrect treatment. A high index of suspicion is necessary in cases of negative intraoperative findings of presumed inguinal hernia and in patients with recurrent inguinal hernias.

Financial support and sponsorship

Nil.

Conflicts of interest

There are no conflicts of interest.

REFERENCES

- Nayeem N. Femoral hernia in children. *Br J Clin Pract* 1990;44:383.
- De Caluwé D, Chertin B, Puri P. Childhood femoral hernia: A commonly misdiagnosed condition. *Pediatr Surg Int* 2003;19:608-9.
- Baum RK. Femoral hernias in paediatric patients. *J Surg* 1960;99:904-5.
- Lickley HL, Trusler GA. Femoral hernia in children. *J Pediatr Surg* 1966;1:338-41.
- Immordino PA. Femoral hernia in infancy and childhood. *J Pediatr Surg* 1972;7:40-3.
- Burke J. Femoral hernia in childhood. *Ann Surg* 1967;166:287-9.
- Wright MF, Scollay JM, McCabe AJ, Munro FD. Paediatric femoral hernia – The diagnostic challenge. *Int J Surg* 2011;9:472-4.
- Lee SL, DuBois JJ. Laparoscopic diagnosis and repair of pediatric femoral hernia. Initial experience of four cases. *Surg Endosc* 2000;14:1110-3.
- Goodhead B. Strangulated femoral hernia in child aged 6 years. *Br Med J* 1964;2:1052-3.
- Tainaka T, Uchida H, Ono Y, Tanano A, Shiota C, Yokota K, *et al.* A new modification of laparoscopic percutaneous extraperitoneal closure procedure for repairing pediatric femoral hernias involving a special needle and a wire loop. *Nagoya J Med Sci* 2015;77:531-5.
- Radcliffe G, Stringer MD. Reappraisal of femoral hernia in children. *Br J Surg* 1997;84:58-60.
- McVay CB, Savage LE. Etiology of femoral hernia. *Ann Surg* 1961;154:25-32.
- Fresno OJ, Sanchez MA, Rollán V. Femoral hernia in childhood: Review of 38 cases. *Pediatr Surg Int* 1997;12:520-1.
- Büchin P, Steinau G, Ophoff K, Dreuw B, Truong SN, Schumpelick V. Femoral hernia in childhood: Evaluation of sonography as a diagnostic aid. *Hernia* 1999;3:19-21.
- Tröbs RB, Yilmaz B, Bahr M, Cernaianu G, Vahdad RM. Single-port laparoscopic percutaneous extraperitoneal closure of femoral hernia in children and adolescents: Case series. *Hernia* 2017;21:443-7.
- Wright JE. Femoral hernia in childhood. *Pediatr Surg Int* 1994;9:167-9.
- Tam PK, Lister J. Femoral hernia in children. *Arch Surg* 1984;119:1161-4.
- Anderas P, Jona JZ, Glicklich M, Cohen RD. Femoral hernias in children. An infrequent problem. *Arch Surg* 1987;122:950-1.
- Glassow F. Femoral hernia: Review of 1,143 consecutive repairs. *Ann Surg* 1966;163:227-32.
- Ludington LG. Femoral hernia and its management, with particular reference to its occurrence following inguinal herniorrhaphy. *Ann Surg* 1958;148:823-6.
- Henriksen NA, Thorup J, Jorgensen LN. Unsuspected femoral hernia in patients with a preoperative diagnosis of a recurrent inguinal hernia, author reply. *Hernia* 2012;16:571.
- Kocijan R, Sandberg S, Chan YW, Hollinsky C. Anatomical changes after inguinal hernia treatment: A reason for chronic pain and recurrent hernia? *Surg Endosc* 2010;24:395-9.
- Al-Shanafey S, Giacomantonio M. Femoral hernia in children. *J Pediatr Surg* 1999;34:1104-6.
- Ho-Gil Y, Kwang-Man L, Un-Jong C. The diagnostic concordance of femoral hernia and the factors influencing diagnosis. *J Korean Surg Soc* 2009;76:179-86.
- Temiz A, Akcora B, Temiz M, Canbolant E. A rare and frequently unrecognized pathology in children: Femoral hernia. *Hernia* 2008;12:553-6.
- Robinson P, Hensor E, Lansdown MJ, Ambrose NS, Chapman AH. Inguinofemoral hernia: Accuracy of sonography in patients with indeterminate clinical features. *AJR Am J Roentgenol* 2006;187:1168-78.
- Chen KC, Chu CC, Chou TY, Wu CJ. Ultrasonography for inguinal hernias in boys. *J Pediatr Surg* 1998;33:1784-7.
- Chapman WH, Barcia PJ. Femoral hernia in children: An infrequent problem revisited. *Mil Med* 1991;156:631-3.
- Schier F. Laparoscopic inguinal hernia repair—a prospective personal series of 542 children. *J Pediatr Surg* 2006;41:1081-4.
- Adibe OO, Hansen EN, Seifarth FG, Burnweit CA, Muensterer OJ. Laparoscopic-assisted repair of femoral hernias in children. *J Laparoendosc Adv Surg Tech A* 2009;19:691-4.
- Palot JP, Avisse C. Open techniques of femoral hernia repair. *Abdom Wall Hernias* 2001;66:439-48.
- Coley WB, Hoguet JP. Operative treatment of hernia: A consideration of 8589 cases of hernia treated by radical operation from 1891 to 1918, with special reference to methods of operating and end results. *Ann Surg* 1918;68:255-68.