



Acute post-partum vision loss due to pilocytic astrocytoma

Natalie A. Homer^{a,*}, Aliza Epstein^a, Vikram D. Durairaj^{a,b}, Min Wang^c, Gowtham Jonna^d, Marie Somogyi^{a,b}

^a TOC Eye and Face, 3705 Medical Parkway, Suite 120, Austin, TX, 78705, USA

^b Department of Ophthalmology, Dell Medical School, University of Texas at Austin, 1501 Red River St, Austin, TX, 78701, USA

^c Department of Pathology, Dell Medical School, University of Texas at Austin, 1501 Red River St, Austin, TX, 78701, USA

^d Retina Research Center, 3705 Medical Parkway, Suite 420, Austin, TX, 78705, USA

ARTICLE INFO

Keywords:

Optic nerve glioma
Optic nerve tumor
Proptosis
Choroidal folds
Case report

ABSTRACT

Purpose: We report an unusual case of a thirty-three-year-old woman who presented with acute unilateral vision loss following pregnancy and was ultimately discovered to have a pilocytic astrocytoma of the optic nerve.

Observations: A thirty-three-year-old previously healthy female presented one month following Caesarean section with unilateral vision loss. She was found to have significantly decreased visual acuity, an afferent pupil deficit, proptosis, optic nerve edema and choroidal folds. Imaging revealed a large lesion of the optic nerve. Biopsy was performed and pathologic analysis revealed a pilocytic astrocytoma, WHO grade 1. The patient opted for close observation without further management and demonstrated mild improvement in visual function.

Conclusions/Importance: Optic pathway gliomas (OPG) most commonly present in the pediatric patient population with painless proptosis, slowly progressive vision loss, and clinical findings of chronic optic neuropathy. (Farazdaghi et al., 2019 Sep) 1 Acute presentations of this disease in adulthood are rare. This case demonstrates a rare case of acute optic nerve glioma presentation during the post-partum period.

1. Introduction

Optic pathway gliomas (OPG) most commonly present in the pediatric patient population with painless proptosis, slowly progressive vision loss, and clinical findings of chronic optic neuropathy.¹ Acute presentations of this disease in adulthood are rare.

1.1. Case report

A thirty-three-year-old previously healthy female presented with a one-month history of unilateral vision loss following an uncomplicated Caesarean section. Her post-operative course was complicated by an intestinal ileus, associated with nausea and vomiting, requiring endoscopy and nasogastric tube placement under anesthesia. Upon awakening from the uncomplicated gastrointestinal procedures, the patient noted acute vision loss in the left eye. Formal evaluation revealed 20/30 vision on the right, count-fingers vision on the left, a brisk left afferent pupillary defect and 2 mm of relative left globe proptosis (Fig. 1A–B). Upon dilated examination, she was found to have diffuse optic nerve head edema, subretinal fluid and choroidal folds (Fig. 2A). Optometric

examination of the left eye one-year prior denoted 20/30 visual acuity, a reactive pupil without afferent pupillary defect and normal-appearing optic nerve. B-scan ultrasound revealed a large intraconal mass with posterior globe flattening (Fig. 2B). MRI confirmed a large fusiform lesion of the left optic nerve with homogenous enhancement (Fig. 3A), and canalicular and prechiasmatic atrophy and T2 hyperintensity (Fig. 3B). Her history did not include any stigmata of Neurofibromatosis, and oral steroid therapy was initiated with minimal visual improvement. Incisional biopsy was pursued via a medial lid crease orbitotomy. A grossly enlarged optic nerve was encountered with a hypervascular nerve sheath (Fig. 4A). The optic nerve sheath was incised revealing underlying gelatinous material (Fig. 4B). Extensive intra-sheath exploration confirmed absence of organized hemorrhage. Pathologic evaluation revealed low-grade spindle-shaped pilocytic (hair-like) astrocytes and glial filaments, admixed with eosinophilic Rosenthal fibers (Fig. 5), conferring a diagnosis of pilocytic astrocytoma, WHO grade 1. Five-percent of tumor cell nuclei stained weakly (1–2+ intensity) positive for progesterone receptor. Estrogen receptor staining was negative.

The patient was continued on oral prednisone post-operatively. One-month post-biopsy, she reported subjective improvement in color vision,

* Corresponding author.

E-mail address: natalie.a.homer@gmail.com (N.A. Homer).

<https://doi.org/10.1016/j.ajoc.2020.100897>

Received 2 April 2020; Received in revised form 6 July 2020; Accepted 16 August 2020

Available online 20 August 2020

2451-9936/© 2020 Published by Elsevier Inc. This is an open access article under the CC BY-NC-ND license (<http://creativecommons.org/licenses/by-nc-nd/4.0/>).

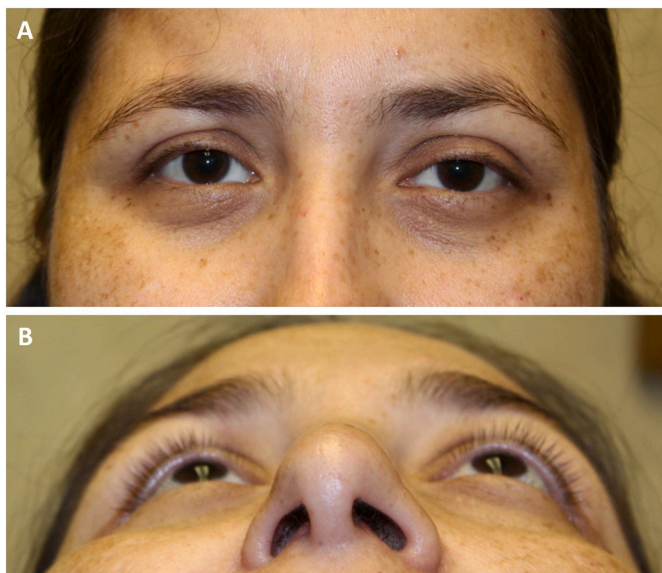

Fig. 1. Clinical photographs of the patient in (A) frontal and (B) worm's eye view, demonstrating 2 mm of relative left globe proptosis.

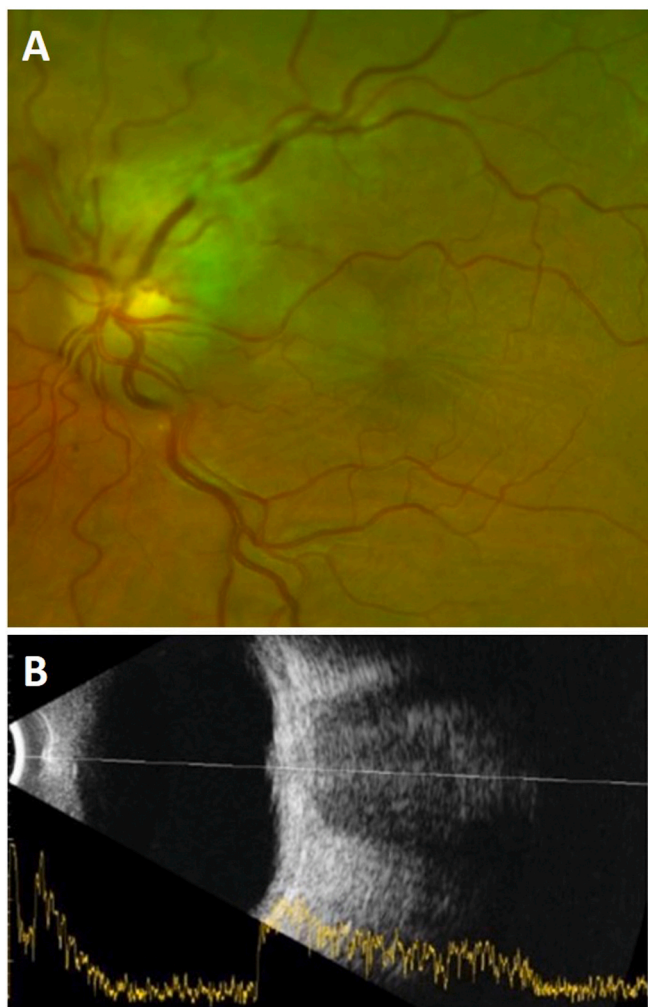


Fig. 2. Patient (A) fundus photograph showing optic disc edema, choroidal folds and subretinal fluid. (B) B-scan ultrasonography demonstrated a retrobulbar mass.

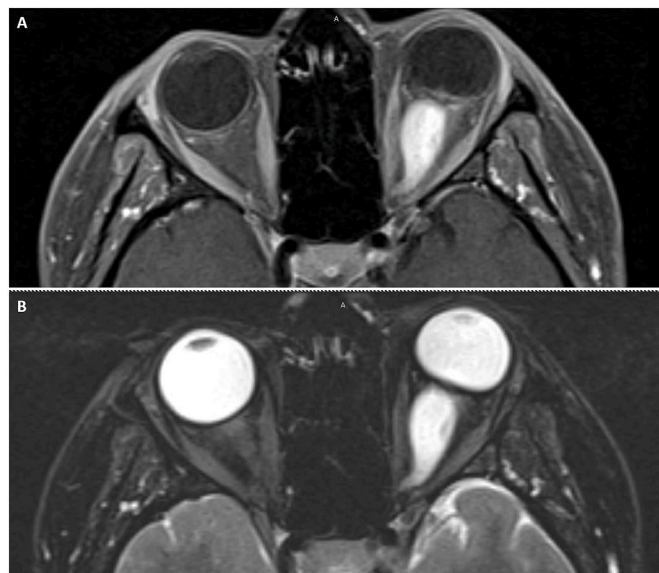


Fig. 3. MRI (A) T1- and (B) T2-weighted, fat-suppressed images demonstrating an enhancing fusiform lesion of the left optic nerve with posterior globe flattening.

and was found to have a Snellen visual acuity of 20/100 with resolution of optic disc edema. Further management options, including radiotherapy, chemotherapy, and enucleation with nerve extirpation were discussed in detail at tumor board. The patient opted for conservative management with close observation and serial visual field testing.

2. Discussion

Optic pathway gliomas are low-grade neoplasms that primarily affect children, with fewer than 10% presenting after the second decade of life.² OPGs affect the intraorbital optic nerve in 25% of cases.¹ Lesions may be associated with systemic neurofibromatosis type 1, but also occur sporadically, with sporadic lesions portending a higher rate of chiasmal progression.¹ These lesions typically induce painless axial globe proptosis, progressive vision loss and clinical stigmata of compressive optic neuropathy. The patient herein instead presented with sudden vision change and an edematous optic nerve with adjacent subretinal fluid, favoring an acute process.

While optic nerve tumor biopsy is not universally advocated given risk for surgical morbidity, a recent review demonstrated pathologic evaluation to prove an unanticipated diagnosis in 93.3% of patients with progressive optic neuropathy.³ While the patient described herein showed lesion radiographic findings characteristic with an OPG, the patient's atypical age and acute presentation warranted biopsy to exclude a high-grade lesion. Biopsy may also help to guide treatment and ultimately prevent contralateral vision loss.

Acute OPG presentation in the peri- and post-partum period is rare and the causative mechanism unknown.⁴⁻⁶ Though gestational hormonal shifts have been speculated to influence tumor growth, a series of 34 pregnant patients with non-optic pathway gliomas showed continued progression after delivery.⁷ While a review of non-optic pathway gliomas found frequent report of WHO grade II-VI lesion progression during pregnancy, low-grade tumor expansion was rare.⁷⁻¹⁰ Progesterone receptor positivity has been reported in astrocytomas, and found to correlate with higher tumor grades.¹¹ Alternatively, an inverse relationship has been determined between lifetime estrogen levels and optic nerve glioma development.¹⁰ A chiasmal OPG biopsied from a pregnant woman was negative for estrogen and progesterone receptors.⁴ In our patient, negative estrogen receptor and very weak progesterone receptor stains argue against a direct hormonal influence on tumor progression.

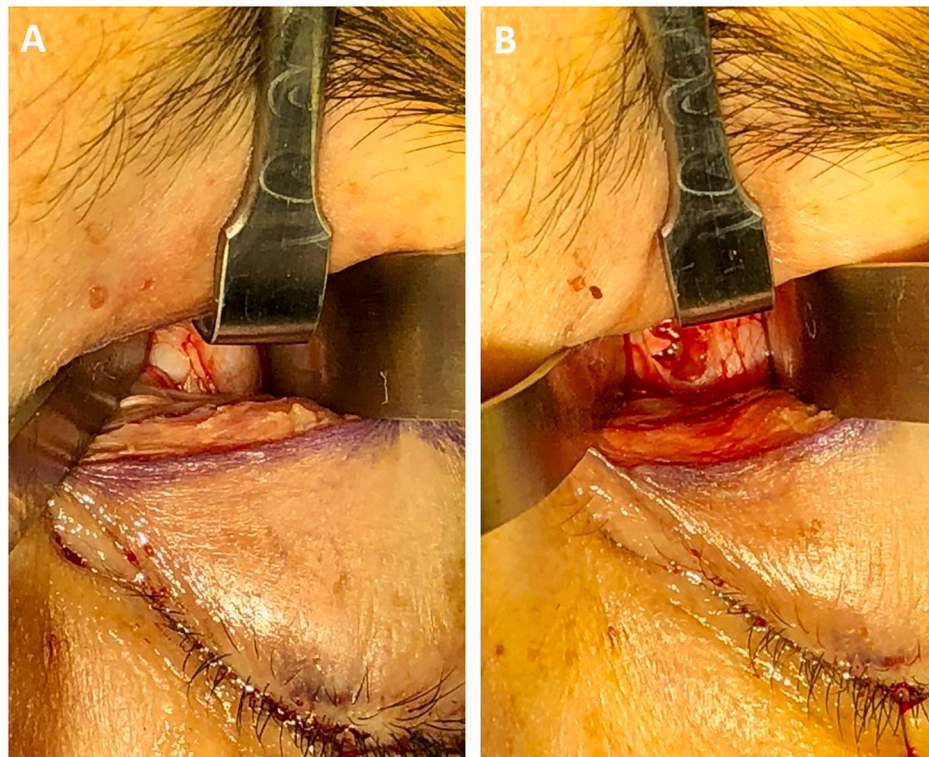


Fig. 4. Intraoperative photographs of a medial lid crease orbitotomy demonstrating (A) fusiform enlargement of the optic nerve, and (B) dural window with underlying gelatinous material.

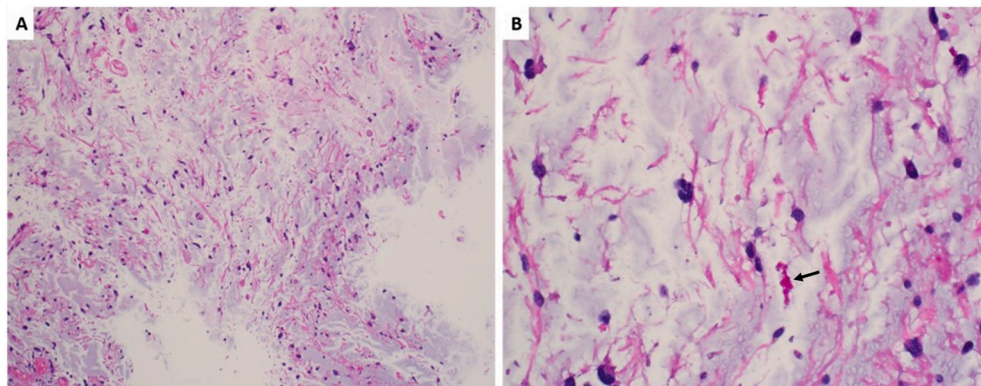


Fig. 5. Surgical pathology on (A) low and (B) high magnification displaying low-grade spindle-shaped pilocytic (hair-like) astrocytes and glial filaments, with admixed (black arrow) eosinophilic Rosenthal fibers.

The impact of alternative upregulated peripartum growth factors should be considered. Another mechanism proposed is intraslesional hemorrhage and hypercoagulability as inciting factors in the acutely symptomatic intraorbital OPG during pregnancy.⁵

Traditional management options for OPGs include observation, chemotherapy and targeted radiation. More recently, targeted therapy with mitogen-activated protein (MAP) kinase pathway inhibitors and systemic *anti*-VEGF have been successfully trialed.¹ Optic canal decompression has resulted in improved vision in select cases.⁴ Surgical enucleation is often reserved for intracranial or intracanalicular involvement, or for painful and/or disfiguring proptosis in low-vision eyes.

3. Conclusions

This case demonstrates a rare case of acute optic nerve glioma

progression during the post-partum period.

Patient consent

Consent to publish this case report has been obtained from the patient in writing.

Funding

No funding or grant support.

Authorship

All authors attest that they meet the current ICMJE criteria for Authorship.

Declaration of competing interest

VDD serves as a consultant for Stryker, Genentech and Horizon Therapeutics.

The following authors have no financial disclosures: NH, AE, MW, GJ, MS.

Acknowledgements

None.

References

1. Farazdaghi MK, Katowitz WR, Avery RA. Current treatment of optic nerve gliomas. *Curr Opin Ophthalmol*. 2019 Sep;30(5):356–363.
2. Dutton JJ. Gliomas of the anterior visual pathway. *Surv Ophthalmol*. 1994;38:427–452.
3. Levin MH, Ney JJ, Venneti S, et al. Optic nerve biopsy in the management of progressive optic neuropathy. *J Neuro Ophthalmol*. 2012 Dec;32(4):313–320.
4. Bayley JC, Goethe EA, Srinivasan VM, Klisch TJ, Mandel JJ, Patel AJ. Newly diagnosed optic pathway glioma during pregnancy. *World Neurosurg*. 2019 July;127:58–62.
5. Yokoyama S, Takayama K, Sueda M, Ishikawa Y, Hirano H. Optic nerve glioma manifesting as intratumoral hemorrhage in a pregnant woman—case report. *Neurol Med -Chir*. 2003 Nov;43(11):559–562.
6. Topliss DJ. Optic-nerve glioma and pregnancy. *Med J Aust*. 1989 Mar 6;150(5):287–288.
7. Peeters S, Pagès M, Gauchotte G, et al. Interactions between glioma and pregnancy: insight from a 52-case multicenter series. *J Neurosurg*. 2017;128:3–13.
8. Pallud J, Mandonnet E, Deroulers C, et al. Pregnancy increases the growth rates of world health organization grade II gliomas. *Ann Neurol*. 2010;67:398–404.
9. Yust-Katz S, de Groot JF, Liu D, et al. Pregnancy and glial brain tumors. *Neuro Oncol*. 2014;16:1289–1294.
10. Nuzzi R, Scalabrin S, Becco A, Panzica G. Sex hormones and optic nerve disorders: a review. *Front Neurosci*. 2019;13:57, 2019 Feb 11.
11. Tavares CB, Gomes-Braga Fd, Costa-Silva DR, et al. Expression of estrogen and progesterone receptors in astrocytomas: a literature review. *Clinics*. 2016;71(8):481–486. [https://doi.org/10.6061/clinics/2016\(08\)12](https://doi.org/10.6061/clinics/2016(08)12).