




Monitoring the Progress of Treatment in Fracture Non-Union: The Role of Alkaline Phosphatase and Ultrasonography*

Monitoramento da evolução do tratamento da ausência de consolidação da fratura: Papel da fosfatase alcalina e da ultrassonografia

Dhanji S. Chaudhary¹ Jayur J. Solanki¹ Tarun Verma¹ Viswanath H. Chavali¹ 

¹Department of Orthopedics, Medical College Baroda and SSG Hospital, Vadodara, Gujarat, India

Rev Bras Ortop 2021;56(6):796-803.

Address for correspondence Dr. Viswanath H. Chavali, M.S. Orthopaedic Surgery, A109, Swami Residency, Near Airforce Station, Makarpura Road, Vadodara, Gujarat, India (e-mail: vhcindia@gmail.com).

Abstract

Objective To evaluate the role of serum alkaline phosphatase (ALP) and ultrasonography (USG) in monitoring the progress of treatment in diaphyseal non-unions.

Methods This prospective observational cohort study included adult patients with diaphyseal fractures of major long bones previously treated with internal fixation and eventually resulting in non-union. Following the definitive treatment for non-union, the patients were followed-up periodically for six months, and serial monitoring of the levels of ALP and USG were performed along with radiographs (X-rays) to ascertain the status of the union.

Results After an initial rise at seven weeks, ALP levels declined to normal values in fractures which united, whereas they remained high in cases of persistent non-union. Similarly, after an elevation of the vascular resistive index (RI) at around 12 weeks in all the patients, it decreased in cases progressing to union, while it remained persistently high even at 24 weeks in fractures failing to unite. Cases of persistent non-union continued to show hypoechogenic callus at 24 weeks instead of converting into hyperechogenic callus, as observed in cases which progressed to union.

Conclusion Significant changes suggestive of union appeared simultaneously on the X-rays, USG and ALP levels during the follow-up. However, a serial examination of the ALP levels and USG during the follow-up gave a hint of the direction of progress in the healing process of fracture non-union. Their role in monitoring the outcome of non-union is more complimentary than supplementary to the X-rays.

Keywords

- ▶ bony callus
- ▶ ultrasonography
- ▶ alkaline phosphatase

* Study developed at the Department of Orthopedics, Medical College Baroda SSG Hospital, Vadodara, Gujarat, India.

received
July 15, 2020
accepted
October 2, 2020

DOI <https://doi.org/10.1055/s-0041-1724072>.
ISSN 0102-3616.

© 2021. Sociedade Brasileira de Ortopedia e Traumatologia. All rights reserved.

This is an open access article published by Thieme under the terms of the Creative Commons Attribution-NonDerivative-NonCommercial-License, permitting copying and reproduction so long as the original work is given appropriate credit. Contents may not be used for commercial purposes, or adapted, remixed, transformed or built upon. (<https://creativecommons.org/licenses/by-nc-nd/4.0/>)

Thieme Revinter Publicações Ltda., Rua do Matoso 170, Rio de Janeiro, RJ, CEP 20270-135, Brazil

Resumo

Objetivo Avaliar o papel da concentração sérica de fosfatase alcalina (FA) e da ultrassonografia no monitoramento do progresso do tratamento da ausência de consolidação em fraturas diafisárias.

Métodos Este estudo de coorte observacional prospectivo incluiu pacientes adultos com fraturas diafisárias dos principais ossos longos previamente submetidas a fixação interna sem consolidação. Após o tratamento definitivo, os pacientes foram avaliados periodicamente por seis meses, com realização seriada de ultrassonografia, determinação da concentração de FA, e radiografias para verificar a presença de consolidação.

Resultados Após um aumento inicial em sete semanas, os níveis de FA voltaram ao valor normal em pacientes com fraturas consolidadas, mas continuaram elevados nos casos de ausência de consolidação. Da mesma forma, após uma elevação do índice de resistência (IR) vascular em cerca de 12 semanas em todos os pacientes, o IR diminuiu nos casos que progrediram para consolidação, mas continuou alto até as 24 semanas em fraturas não consolidadas. Os casos com ausência de consolidação ainda apresentavam calo hipoecogênico às 24 semanas, que não se converteu no calo hiperecogênico observado nos casos que progrediram para consolidação.

Conclusão Alterações significativas sugestivas de consolidação foram simultaneamente observadas nas radiografias, na ultrassonografia e na concentração de FA durante o período de acompanhamento. No entanto, a realização seriada de exames da concentração de FA e de ultrassonografia durante o acompanhamento indicou o progresso da consolidação da fratura. Seu papel no monitoramento da ausência de consolidação é mais complementar do que suplementar à radiografia.

Palavras-chave

- ▶ calo ósseo
- ▶ ultrassonografia
- ▶ fosfatase alcalina

Introduction

Fracture non-union is an outcome difficult to predict, and even though it is an established complication, in the clinical practice, both clinicians and patients deem it a poor outcome.¹ There is variability in the clinical assessment of the status of union in fractures and a lack of consensus on the the reliability of various methods to assess the progress of the union. Clinical appreciation combined with X-rays is used for the assessment of both acute fractures and non-unions, even though other methods to monitor and document bone healing, like computed tomography (CT), magnetic resonance imaging (MRI), bone scintigraphy etc., have been used sparingly in select cases. However, in addition to the concern regarding availability, these advanced investigations represent an added financial burden and/or pose a risk of radiation exposure to the patient. The objective of the present study was to evaluate the role of alternative investigative methods: serum alkaline phosphatase (ALP) and ultrasonography (USG), and compare them with the conventional radiograph (X-ray) in monitoring the progress of treatment in diaphyseal non-unions. In addition to being inexpensive and easily available, USG and the measurement of the levels of ALP were selected to represent physical and biochemical markers of union respectively.

Methodology

This prospective observational study was performed at a state-run tertiary care hospital attached to a postgraduate

teaching institute from April 2018 to September 2019, with due permission from the Institutional Ethics Committee. Diaphyseal fractures of major long bones that is, the femur, tibia (with or without the fibula), humerus and the radius and ulna (individually / combined), previously treated with any type of internal fixation in adults (> 18years), and eventually resulting in non-union, were included in the study. Only those patients with normal liver function confirmed by USG and serum biochemical tests were included in the study. The treatment of non-union remained independent of the study. All patients were followed up for six months at six-week intervals. At each follow-up visit, all patients were assessed clinically and by plain radiographs for signs of union. In addition to serial ALP measurements, at each follow-up, the fractures were evaluated by USG for echogenicity and measurement of the vascular resistive index (RI) of the callus. The measurement of the ALP levels was performed spectrophotometrically using the p-nitrophenylphosphate (PNPP) kinetic International Federation of Clinical Chemistry (IFCC) method with a laboratory reference range of 28 IU/L to 111 IU/L. The USG was performed using a Philips (Amsterdam, The Netherlands) iU22 camera equipped with a linear probe with a resolution of 12 MHz to 5MHz, MSK Superficial program and 3D Power Color Doppler. Whereas the authors evaluated fracture healing using plain radiographs, the USG examination of the fracture was performed by an independent radiologist without the knowledge of the X-ray status. – Fig. 1 shows a brief overview of the methodology.

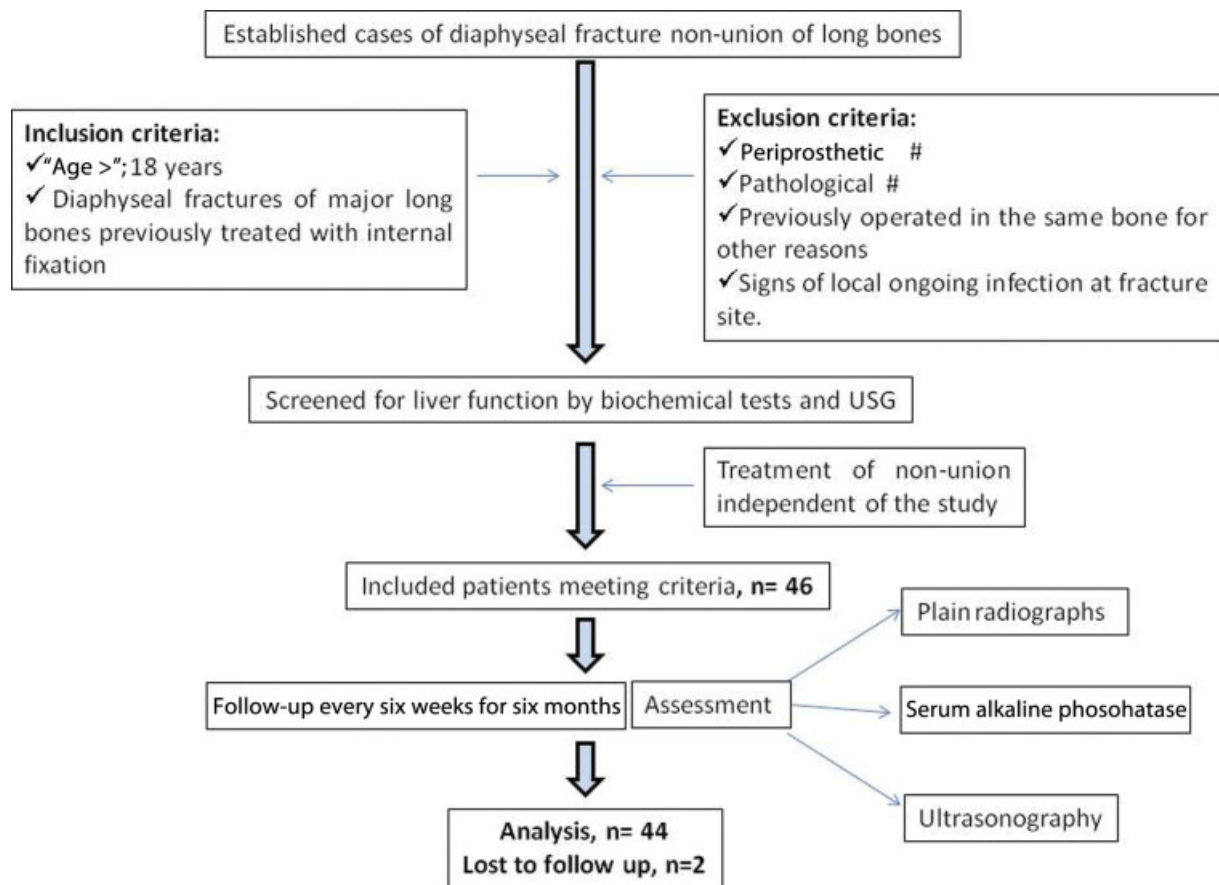


Fig. 1 Flowchart showing the basic methodology applied to the present study.

Observations and Results

The sample for the final follow-up and analysis was composed of 44 patients (36 male, 8 female). These included 20 cases of upper-limb and 24 cases of lower-limb diaphyseal non-unions. Morphologically, there were 24 cases of atrophic, 6 cases of hypertrophic and 14 cases of comminuted non-unions. The average age of the patients was 37 (range: 18 to 75) years. In total, 28 patients underwent cancellous/tricortical/fibular bone grafting, 6 were stabilized by additional fixation, 4 patients were subjected to implant extraction followed by functional bracing, 4 patients were treated by late dynamisation of statically interlocked nail, and the remaining 2 were treated by an Ilizarov ring fixator. ► **Table 1** shows a summary of the observations with reference to the outcome of the study. Illustrative cases are shown in ► **Figs. 2, 3 and 4**.

X-ray

We considered a fracture radiologically united only when the X-rays showed bridging bone across the fracture in both orthogonal views. A total of 30 patients showed signs of union, and 14 patients showed persistent non-union on the X-rays at the final follow-up (► **Figs. 2d, 3d and 4d**). During the follow-up, calluses were observed as early as 12 weeks and as late as 24 weeks. The average union time as assessed by the X-rays was of 18.8 (range: 12 to 24) weeks. Bone grafting ($n=22$) showed more promising results in achieving union.

Serum Alkaline Phosphatase

It has been our observation that patients with established non-union who present within six months of the primary surgery usually have ALP levels > 110 IU/L. The average ALP level as measured when the patients were recruited to the study was of 120 (range: 42 to 202) IU/L. The average peak level reached during the study was of 180 (range: 136 to 216) IU/L. The levels of ALP initially increased in all cases and reached a peak at around 7 weeks. In fractures which progressed toward union, the ALP levels dropped to normal by the end of the study period, whereas, in cases which failed to unite, the ALP levels continued to remain high following the initial spike until the end of the study period (► **Fig. 5**). The average ALP level at the end of the study period in united and persistent non-union cases were of 94 IU/L and 128 IU/L respectively.

Ultrasonography

The assessment of union in fractures by USG was performed qualitatively, by the echogenicity of the callus, and quantitatively, by measuring the vascular RI.²

In the sample, there were established cases of non-union. Hence, a hypochoic structure (fibrous tissue) was observed since the first day of recruitment. However, in contrast to the homogeneously hypochoic signals of a newly-formed hematoma converting to soft callus, in our cases, gray-scale USG at recruitment showed heterogenous-hypochoic signals due to

Table 1 Summary of the observations regarding the outcomes of the study

Outcome→	Union	Non-union	Total/Gross
Parameters ↓			
Number of cases	30	14	44
Type of non-union			
Atrophic	18	6	24
Hypertrophic	4	2	6
Comminuted	8	6	14
Average level of serum alkaline phosphatase (28–111 IU/L)			
At admission	121	118	120
At the final follow-up	94	128	105
Peak value during the study	179	181	180
Average resistive index (ultrasonography)			
At admission	0.28	0.12	0.22
At the final follow-up	0.22	0.9	0.44
Peak value during the study	0.79	1.04	0.87
Follow-up (weeks)			
Peak level of serum alkaline phosphatase	7.2	6.9	7.0
Peak value of the resistive index	14.4	21.4	16.6
Hyperechoic callus on ultrasonography	20	Not observed	20
Callus on X-ray (union time)	18.8	Not observed	18.8

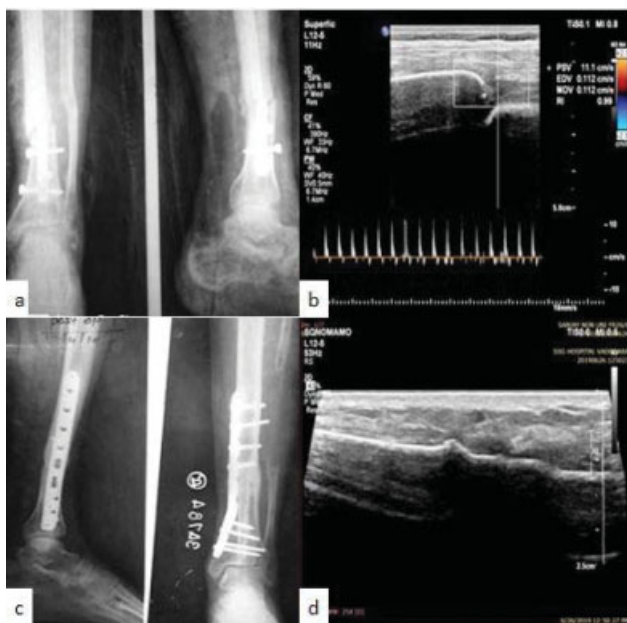

Fig. 2 Illustrative Case1. (A) X-ray showing non-union of the distal tibia; (B) ultrasonography (USG) showing fracture gap with high resistive index; (C) fracture union after bone grafting at 24 weeks; and (D) USG at 24 weeks showing hyperechoic signals and absent vascular resistance.

the fibrosclerosis that had ensued within the non-union (► **Figs. 2b, 3b** and **4b**). The average time taken for hyperechoic callus suggestive of mineralization to appear in uniting fractures was of 20 (range: 18 to 24) weeks. In cases which failed to unite, the USG examination continued to show hypoechogenicity at 24 weeks (► **Fig. 4d**).

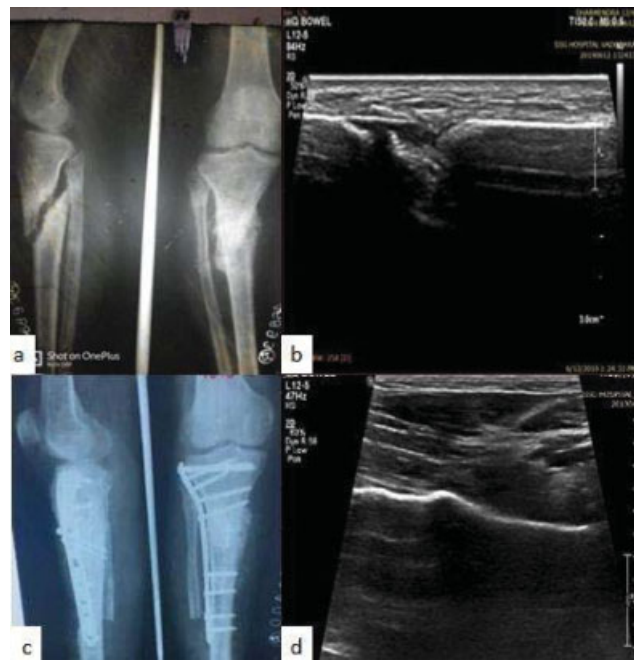

Fig. 3 Illustrative Case2. (A) X-ray showing non-union of the proximal tibia; (B) USG showing heterogenous hypoechoic signals of non-union; (C) fracture union after bone grafting at 18 weeks; and (D) USG at 18 weeks showing hyperechoic signals.

The average of RI score as measured when the patients were recruited to the study was of 0.22, with 30 patients showing non-recordable levels (due to fibrosclerosis). Irrespective of the outcome, a steady elevation in RI scores was observed in all

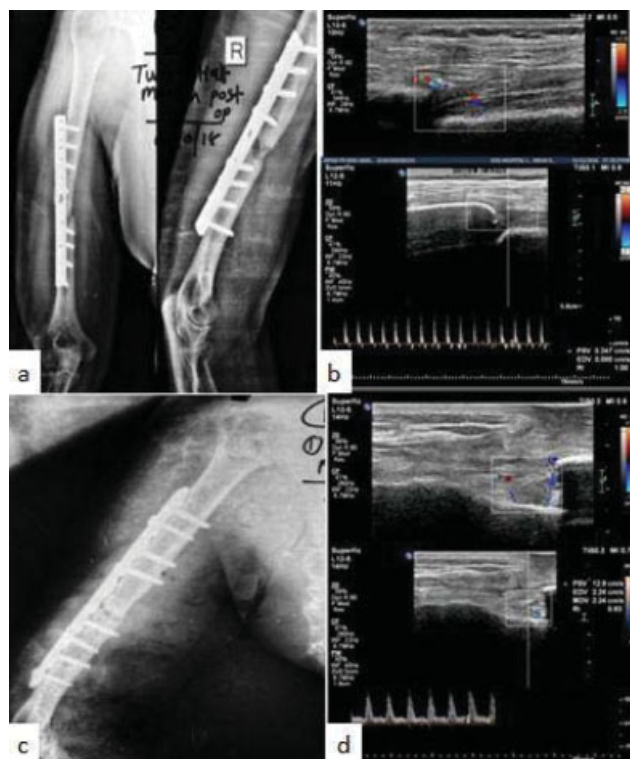


Fig. 4 Illustrative Case3. (A) X-ray showing non-union shaft of the humerus; (B) USG showing fracture gap with high resistive index; (C) persistent fracture non-union after 24 weeks of the revision surgery; and (D) USG at 24 weeks showing fracture gap, hypoechoic signals and high vascular resistance.

cases until around 12 to 18 weeks. The RI scores decreased following their elevation in patients progressing to union. In fractures failing to unite, they persistently remained high even at 24 weeks (► **Fig. 6**). The average RI scores at the final follow-up in united and persistent non-union cases were of 0.22 and 0.90 respectively (► **Fig. 2d, 3d and 4d**).

A gross analysis of the findings of the study (► **Table 2**) was attempted using the frequency with which all parameters that is, the X-ray, ALP levels, hyperechoic callus and RI scores, showed positive signs of union at different intervals during the follow up. Bridging callus on X-ray, ALP levels within the laboratory reference range, hyperechoic signals on gray-scale USG and a lower RI score as compared with the previous reading on the Doppler USG were considered signs of progress of the union. In the present analysis, the cases of each parameter were mutually inclusive for that follow-up time. The earliest time when the ALP levels and the USG predicted a possible outcome of the treatment (12 to 18 weeks) coincided with the early changes observed on the X-rays.

Discussion

The non-union of diaphyseal fractures to long bones, which otherwise have a lower incidence, represent an uphill task to the treating surgeon. Although much information is available in the literature regarding non-union, to the best of our knowledge, we could not find any perfectly-matching study that described the monitoring of the progress of the treatment in cases of long-bone non-union. A detailed evaluation of studies regarding the value of the laboratory and imaging

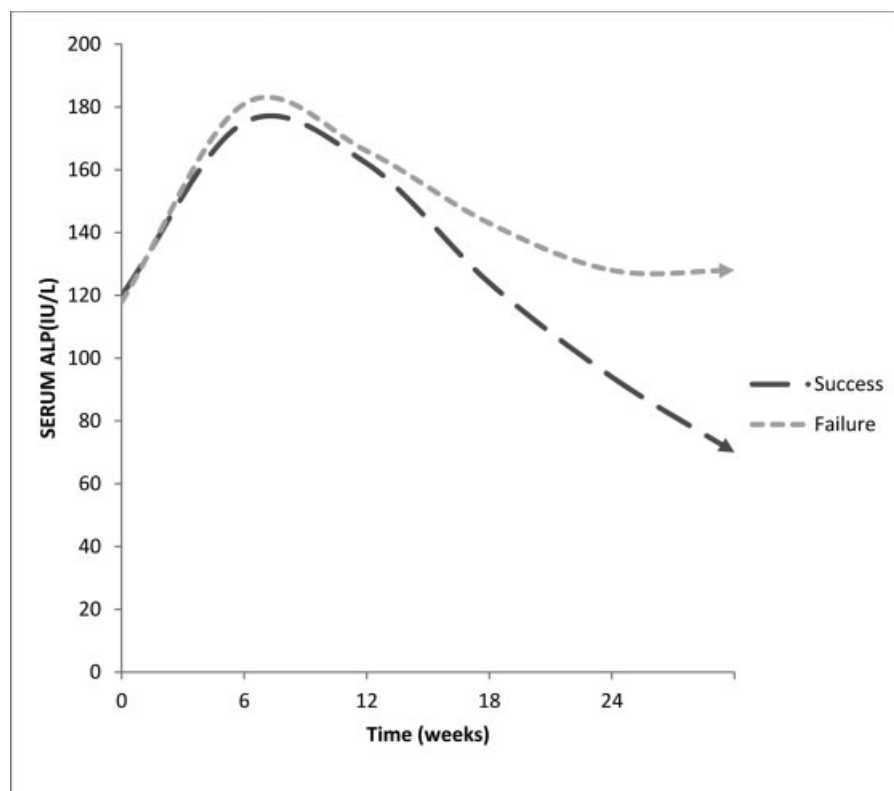


Fig. 5 Trend of average serum alkaline phosphatase levels in cases of union and non-union.

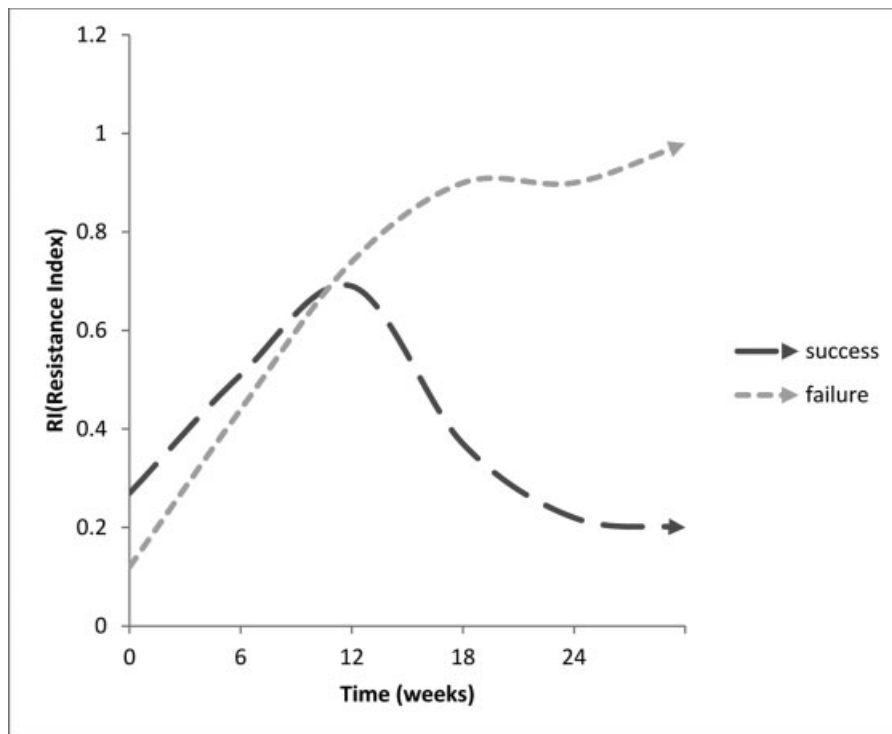


Fig. 6 Trend of average vascular resistive index in cases of union and non-union.

Table 2 Analysis of the findings of the present study

Investigation	Number of patients			
	At 6 weeks	At 12 weeks	At 18 weeks	At 24 weeks
X-ray (bridging callus)	0	4	22	30
Level of serum alkaline phosphatase (< 111 IU/L)	0	0	8	30
Ultrasonography (hyperechoic signal+ decreasing resistive index)	0	0	20	30

studies in cases of long-bone non-union in animals was performed by Zimmermann et al.³ However, most of these studies cannot be properly reproduced in the routine clinical practice. Clinical improvement, such as painless weight bearing, use of the affected extremity, and lack of swelling and tenderness have always comforted both patient and surgeon as a reflection of a fair progress. Supportive radiological evidences such as that of X-rays and CT scans have reinforced such clinical impressions. In the qualitative assessment, the line, margins and gaps of the fracture, the external callus, the callus-to-cortex ratio and the bridging callus are examined. Advanced diagnostic methods, like dual-energy X-ray absorptiometry (DEXA) scans, multidirectional CT and laboratory tests, like the measurement of the levels of bone-specific alkaline phosphatase, matrix metalloproteinases and specific growth factors⁴ etc., have booked a place in theoretical texts, but have yet to find place in the routine clinical practice.

Several studies⁵⁻⁸ have been published supporting the evidence that the ALP levels can be used as an adjunct biomarker to the clinical and radiological evidences of healing. In clinical trials,^{9,10} ALP levels showed a significantly higher

baseline and a tendency towards a slow increase during the first two months of healing in acute fractures, and this might help to predict delayed fracture healing. This increase in ALP activity observed is assumed to happen due to the rising concentration of the bone isoenzyme of ALP during the healing process,¹¹ and it coincides with the beginning of mineralization.¹² In line with the studies related to biological markers in acute fractures, ALP levels temporarily increased after the intervention for up to seven weeks in all patients, followed by normalization in those showing signs of union in the present study. Based on this, we believe that, as observed in acute fractures, serial ALP measurements have significance in monitoring the treatment of fracture non-unions as well.

The evaluation of the callus by USG has been well described in the literature, which reports that the callus can be observed much sooner on the USG than on plain X-rays.¹³⁻¹⁶ Significant changes in the mineral composition of the callus during fracture healing changes the speed of the reflected wave (echo) picked up by the transducers. Based on this echo pattern, the callus is labeled either as hypoechoic or hyperechoic.¹⁷ Early (soft) calluses in fresh fractures are seen as homogenous-hypoechoic which, with mineralization, mature

to homogenous-hyperechoic (hard) calluses over time. The presence of a hyperechoic ultrasonographic signal from the fracture site was found to have 100% of correlation with the presence of a hard callus on the biopsy.¹⁴ Fractures which fail to progressively unite show persistence of the hypoechogenic pattern. Fibrous tissue is seen as a heterogenous hypoechoic structure in cases of non-union.¹² Chachan et al.¹⁸ compared the efficacy of plain radiography versus USG in monitoring fracture healing, and found the sensitivity and specificity of USG to diagnose fracture union to be of 100% and 80% respectively. In the present study, over the course of up to 16 weeks, all patients showed hypoechoic calluses, which converted to hyperechoic calluses in the patients showing signs of union, and remained hypoechoic in those with persistent non-union. Fibrosclerotic tissue within the non-union site was a significant limiting factor in the qualitative evaluation of the callus by USG in the present study. In our sample consisting exclusively of cases of non-union, the absence of hematoma-induced periosteal reaction and mixed echogenic images due to a standstill in the initial healing process might have been the factors that led to the underestimation of the onset of healing as diagnosed by USG.

The process of fracture healing can be followed with color Doppler imaging and spectral analysis.¹⁹ The USG is able to follow the formation of new vessels at the fracture site and to assess flow characteristics in them during the development of the fracture callus. In addition to following the formation of new vessels at the fracture site, Doppler USG can measure the RI, which reflects the resistance to blood flow caused by a microvascular bed distal to the site of measurement. In patients with normal callus development, the caliber of the afferent vessels progressively increases, and their number decreases. The RI progressively increases, up to

values similar to those of nutrient vessels (0.36 to 0.90). Within the second month of the fracture, a muscular tunic develops in the vessel wall, converting to a mature vessel with the progressing mineralization of the cortex, thus causing the RI to progressively decrease and finally disappear.¹¹ On the other hand, patients with non-union and delayed healing have persistent higher resistance related to a poor formation of neovasculature and increasing peripheral resistance in the residual vessels because of the fibrosclerotic involution of bone healing¹¹ (→Fig. 7). In consistence with the aforesaid description, in the present study, the RI steadily increased until around 12 weeks in all patients; subsequently, at 24 weeks, patients who progressed to union showed low RIs, and those who progressed toward non-union had persistently high RIs.

A gross analysis of the findings of the present study showed that changes in ALP levels, USG and X-rays occurred simultaneously during the follow-up in cases of fracture non-union. None of them proved superior in terms of early prediction of the outcome. Nevertheless, a serial examination of ALP levels and USG during the follow-up gave a hint of the direction of progress in the healing process of the fracture. There is still a great need for scientific research before biological markers like the ALP can be used to make major treatment decisions. Although USG has been established to be a reliable technique for the early diagnosis of healing in acute fractures, its role in outcome evaluation in cases of non-union is yet to be determined. Whereas spot X-rays provide qualitative information regarding the changes during fracture healing, isolated ALP and USG findings have no defined laboratory limits for the period of follow-up after fixation, which can be used to separate individual cases into favorable and unfavorable categories. Furthermore, the USG requires training and

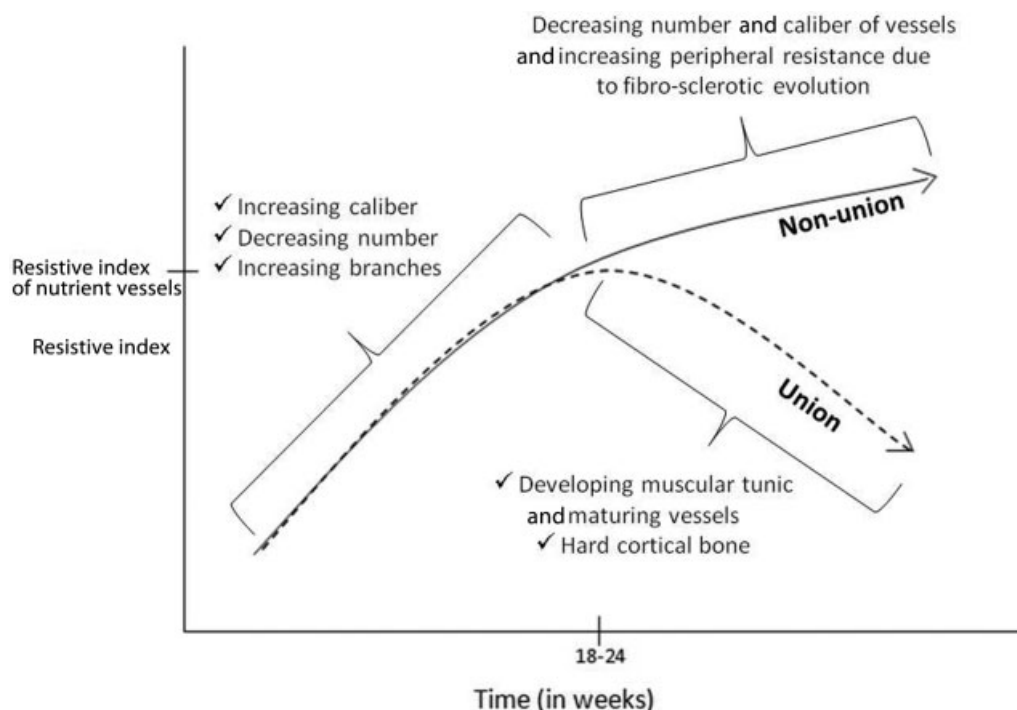


Fig. 7 Vascular changes and their effect on the resistive index in cases of union and non-union.

technical expertise to demonstrate the required results. This could possibly be a limitation to the widespread use of USG for such cases. Although the equipment is easy to procure, not all institutions have on staff professionals trained to evaluate the healing process. Moreover, a study on the cost-effectiveness of USG could further validate the role of USG in monitoring fracture healing. The conventional plain radiograph will surely remain a popular method of assessment because of its long time-tested history, practicality, and lower costs.^{1,18}

Conclusion

The limited sample size of the present study ruled out any statistical conclusion. Significant changes suggestive of union were simultaneously observed on X-rays, USG and ALP levels during the follow-up. The earliest period when ALP levels and USG predicted a possible outcome coincided with the early changes observed on the X-rays. However, the serial evaluation of ALP levels and USG definitely gave a hint regarding the direction of the progress of the treatment. At present, their role in monitoring the outcome of non-union is more complimentary than supplementary to the X-rays.

Financial Support

There was no financial support from public, commercial, or non-profit sources.

Conflict of Interests

The authors have no conflict of interests to declare.

References

- Nandra R, Grover L, Porter K. Fracture non-union epidemiology and treatment. *Trauma* 2016;18(01):3–11
- Wawrzyk M, Sokal J, Andrzejewska E, Przewratil P. The role of ultrasound imaging of callus formation in the treatment of long bone fractures in children. *Pol J Radiol* 2015;80:473–478
- Zimmermann G, Müller U, Wentzensen A. The value of laboratory and imaging studies in the evaluation of long-bone non-unions. [published correction appears in *Injury*. 2007;38(10):1224] *Injury* 2007;38(Suppl 2):S33–S37
- Taniguchi T, Matsumoto T, Shindo H. Changes of serum levels of osteocalcin, alkaline phosphatase, IGF-I and IGF-binding protein-3 during fracture healing. *Injury* 2003;34(07):477–479
- Ajai S, Sabir A, Mahdi AA, Srivastava RN. Evaluation of serum alkaline phosphatase as a biomarker of healing process progression of simple diaphyseal fractures in adult patients. *Int Res J Biol Sci* 2013;2:40–43
- Nilsson BE, Westlin NE. The plasma concentration of alkaline phosphatase, phosphorus and calcium following femoral neck fracture. *Acta Orthop Scand* 1972;43(06):504–510
- Muljačić A, Poljak-Guberina R, Turčić J, Živković O, Guberina M, Klaić B. The changes of bone-specific alkaline phosphatase (BALP) associated with callus formation and rate of bone healing. *Croat Chem Acta* 2010;83(03):315–321
- Das S, Ghosh S, Pal K, Chaudhuri A, Datta S. Changes in biochemical markers in blood and urine in case of malunion and non-union after fracture of long bones. *Saudi J Sports Med* 2015;15(03):269–275
- Emami A, Larsson A, Petrén-Mallmin M, Larsson S. Serum bone markers after intramedullary fixed tibial fractures. *Clin Orthop Relat Res* 1999;368:220–229
- Oni OO, Mahabir JP, Iqbal SJ, Gregg PJ. Serum osteocalcin and total alkaline phosphatase levels as prognostic indicators in tibial shaft fractures. *Injury* 1989;20(01):37–38
- Bowles SA, Kurdy N, Davis AM, France MW, Marsh DR. Serum osteocalcin, total and bone-specific alkaline phosphatase following isolated tibial shaft fracture. *Ann Clin Biochem* 1996;33(Pt 3):196–200
- Kachewar SG, Kulkarni DS. Utility of diagnostic ultrasound in evaluating fracture healing. *J Clin Diagn Res* 2014;8(03):179–180
- Craig JG, Jacobson JA, Moed BR. Ultrasound of fracture and bone healing. *Radiol Clin North Am* 1999;37(04):737–751
- Moed BR, Kim EC, van Holsbeeck M, et al. Ultrasound for the early diagnosis of tibial fracture healing after static interlocked nailing without reaming: histologic correlation using a canine model. *J Orthop Trauma* 1998;12(03):200–205
- Allen GM, Wilson DJ. Ultrasound and the diagnosis of orthopaedic disorders. *J Bone Joint Surg Br* 1999;81(06):944–951
- Moed BR, Subramanian S, van Holsbeeck M, et al. Ultrasound for the early diagnosis of tibial fracture healing after static interlocked nailing without reaming: clinical results. *J Orthop Trauma* 1998;12(03):206–213
- Cunningham JL, Kenwright J, Kershaw CJ. Biomechanical measurement of fracture healing. *J Med Eng Technol* 1990;14(03):92–101
- Chachan S, Tudu B, Sahu B. Ultrasound monitoring of fracture healing: is this the end of radiography in fracture follow-ups? *J Orthop Trauma* 2015;29(03):e133–e138
- Sun MH, Leung KS, Zheng YP, et al. Three-dimensional high frequency power Doppler ultrasonography for the assessment of microvasculature during fracture healing in a rat model. *J Orthop Res* 2012;30(01):137–143