


Treatment of Naturally Degenerated Canine Lumbosacral Intervertebral Discs with Autologous Mesenchymal Stromal Cells and Collagen Microcarriers: A Prospective Clinical Study

Frank Steffen¹, Alessandro Bertolo², Remo Affentranger³,
Stephen J. Ferguson³, and Jivko Stoyanov^{2,4} 

Cell Transplantation
2019, Vol. 28(2) 201–211
© The Author(s) 2018
Article reuse guidelines:
sagepub.com/journals-permissions
DOI: 10.1177/0963689718815459
journals.sagepub.com/home/ctj


Abstract

Intervertebral disc (IVD) degeneration is a frequent disease in modern societies and at its later stages is likely to cause chronic low back pain. Although many studies have been published, the available treatments for IVD degeneration fail to promote regeneration or even marginal repair of the IVD structure. In this study, we aimed to establish veterinary canine patients as a translational large animal model that recapitulates IVD degeneration that occurs in humans, and to investigate the suitability of intradiscal application of mesenchymal stromal cells (MSC). Twenty client-owned dogs diagnosed with spontaneous degenerative lumbosacral IVD and low back pain were included in the study. Autologous MSC were isolated from bone marrow and cultured for 2 weeks. Prior to injection, MSC were attached on collagen microcarriers for delivery, with or without TGF- β 1 crosslinking. After decompressive spinal surgery, dogs received an intradiscal injection of MSC-microcarriers ($n = 11$), MSC-TGF- β 1-microcarriers ($n = 6$) or microcarriers only (control, $n = 3$). MSC-microcarriers were initially evaluated *in vitro* and *in vivo*, to test cell chondrogenic potential and biomechanical properties of the microcarriers, respectively. Clinical performance and Pfirrmann grading were evaluated at 10 months after the injection by magnetic resonance imaging. MSC differentiated successfully *in vitro* towards chondrogenic phenotype and biomechanical tests showed no significant differences of IVD stiffness after microcarrier injection. *In vivo* injection was successful in all dogs, without any visible leakage, and clinical functioning was restored back to normality. However, postoperative Pfirrmann grade remained identical in all dogs, and formation of Schmorl's nodes was detected in 45% of dogs. This side effect was reduced by halving the injection volume, which was then observed only in 11% of dogs. In conclusion, we observed marked clinical improvement in all groups, despite the formation of Schmorl's nodes, but microcarriers and MSC failed to regenerate the structure of degenerated IVD.

Keywords

degenerated intervertebral discs, canine model, mesenchymal stromal cells, prospective clinical study

Introduction

Low back pain caused by intervertebral disc (IVD) degeneration¹ is one of the most common contemporary medical problems in people^{2,3}. Despite improved diagnostic and therapeutic options, including advanced diagnostic imaging techniques and numerous conservative and surgical treatment procedures, these measures remain ineffective in a certain percentage of affected people. Since IVD degeneration is incurable, all available treatment strategies are mainly focused on pain relief only, while the underlying aetiology remains unaddressed. Therefore, progression of segmental

¹ Vetsuisse faculty of the University of Zurich, Zurich, Switzerland

² Swiss Paraplegic Research, Nottwil, Switzerland.

³ Institute for Biomechanics, ETH, Zurich, Switzerland

⁴ Institute for Surgical Technology and Biomechanics, University of Bern, Bern, Switzerland

Submitted: August 27, 2018. Revised: October 22, 2018. Accepted: November 1, 2018.

Corresponding Author:

PD Dr. Jivko Stoyanov, PhD, Swiss Paraplegic Research, Guido A. Zäch Strasse 4, 6207 Nottwil, Switzerland.
Email: jivko.stoyanov@paraplegie.ch



disease due to ongoing disc degeneration has stimulated a large interest in developing strategies with the potential to regenerate – or at least repair and preserve the functioning of the IVD structure. Among these, intradiscal injection of mesenchymal stromal cells (MSC) has become highly topical in experimental and clinical investigations⁴.

The advantages of using MSC include their availability from various adult tissues – such as bone marrow and adipose tissue^{5,6} – their multilineage potential⁷ and their beneficial immunomodulatory properties and ability to reduce local inflammation⁸. Although *in vitro* studies demonstrated that MSC transplanted into degenerated IVD maintained viability, proliferation and differentiation⁹, the translation of these positive results into a clinical setting is challenging for various reasons. On the analytical side, evidence for IVD regeneration can only be obtained histologically by demonstrating increased numbers of disc chondrocytes and increase of proteoglycan content. Because it is unethical to obtain intact disc tissue from living human patients, magnetic resonance imaging (MRI) is the only available technique. MRI can detect only changes of disc hydration as a signal in the nucleus pulposus, which is an indirect measure associated to proteoglycan content and, ultimately, changes in disc size (which fluctuates diurnally). A more intense signal of the nucleus pulposus in T2-weighted MRI images after MSC transplantation is regarded to be equivalent to increased synthesis of proteoglycans by disc chondrocytes. MRI investigations of disc regeneration have yielded conflicting results. On the one hand, in small laboratory animals and experimental dogs with artificially induced disc degeneration, there was an increase in signal paralleled by proliferation of disc chondrocytes and reversal of histological signs of degeneration¹⁰. On the other hand, in clinical studies, visible effects for regeneration evidenced by increased fluid signal seen by MRI were only present in a small percentage of cases in people and absent in the only canine study^{11,12}.

Nevertheless, the use of dogs for veterinary clinical studies presents several advantages: (i) The procedure we applied in veterinary patients would replicate closely the standard in human clinical trial conditions. (ii) Dogs involved in the study naturally developed IVD degeneration and the typical associated pain, establishing a strong link to human complaints. (iii) The size of the dogs included in the study – comparable to humans – prevented any issue of scaling up, which might occur with experimental models like rodents. (iv) Finally, the methods of evaluation – functional score and MRI appearance – are very similar to those used in human medicine. For these four reasons, a canine clinical model of IVD degeneration was selected as a translational approach for testing the suitability of autologous MSC-based, IVD-injection therapy.

Recently, we published our results from a pilot clinical study investigating a therapy with autologous bone marrow-derived MSC in the absence of extracellular matrix carrier in dogs with spontaneous IVD degeneration, in which we could not find MRI proof for improvement of disc morphology¹².

We further hypothesized that the difficult environment – under constant load, hypoxic conditions¹³ and limited room to divide – might lead to an absence of visible disc regeneration. To address these problems, we designed collagen microcarriers based on a medical device approved for human use as a support to deliver MSC into the disc. This scaffold provides mechanical strength and can be used to immobilize growth factors¹⁴ – such as transforming growth factor- β 1 (TGF- β 1) – in order to keep them locally at a sufficient concentration, thus promoting the desired differentiation conditions. Additionally, microcarriers have the advantage of being injectable and thus are uncomplicated to deliver into a patient's discs during surgery.

The purpose of the present translational clinical investigation was three-fold. First, to assess *in vitro* the suitability of microcarriers to support chondrogenic differentiation of canine MSC; second, to investigate *ex vivo* the injectability, biomechanical strength and leakage behaviour of collagen-based microcarriers using canine lumbosacral segments dissected from Beagle dogs; and third, to test the safety and effectiveness in clinically affected dogs – measured by an improved Pfirrmann score – of intradiscal injection of MSC-microcarrier, with or without TGF- β 1 crosslinking, into spontaneously degenerated lumbosacral IVD. Dogs were followed prospectively using a clinical scoring system and MRI.

Materials and Methods

Mechanical Testing on Isolated Cadaveric Lumbosacral Segments

Leftover material from an unrelated study was used for this testing in order to minimize the use of experimental animals. Lumbosacral segments from six healthy and young adult Beagle dogs were used for biomechanical testing. The dogs were bred for experimental use and served as controls in a pharmacological study (Novartis Pharma AG, Basel, Switzerland). After euthanasia and necropsy the lumbosacral joint (L6-S2) was isolated from the cadavers and freed from muscles leaving the ligamentous structures intact. The spinal specimens were then donated to our institution and stored at -20°C .

After thawing, the proximal and distal ends of the spinal specimens were embedded in polymethylmethacrylate (PMMA) for uniform transmission of the loading forces (Fig. 2A). The prepared spinal specimens were mounted on a testing machine (Instron Electropulse E 10000) and exposed to cyclic loading. For testing, the distal vertebral body/PMMA was fixed to the Instron base plate, while the top pot with the embedded proximal vertebral body could move freely (Fig. 2A). For each test, the samples were loaded 5600 times in combined compression and bending by applying 20–200 N axial compression through a pin offset 25 mm from the centre vertical axis of the specimen and machine actuator. The loading frequency was 2 Hz and the

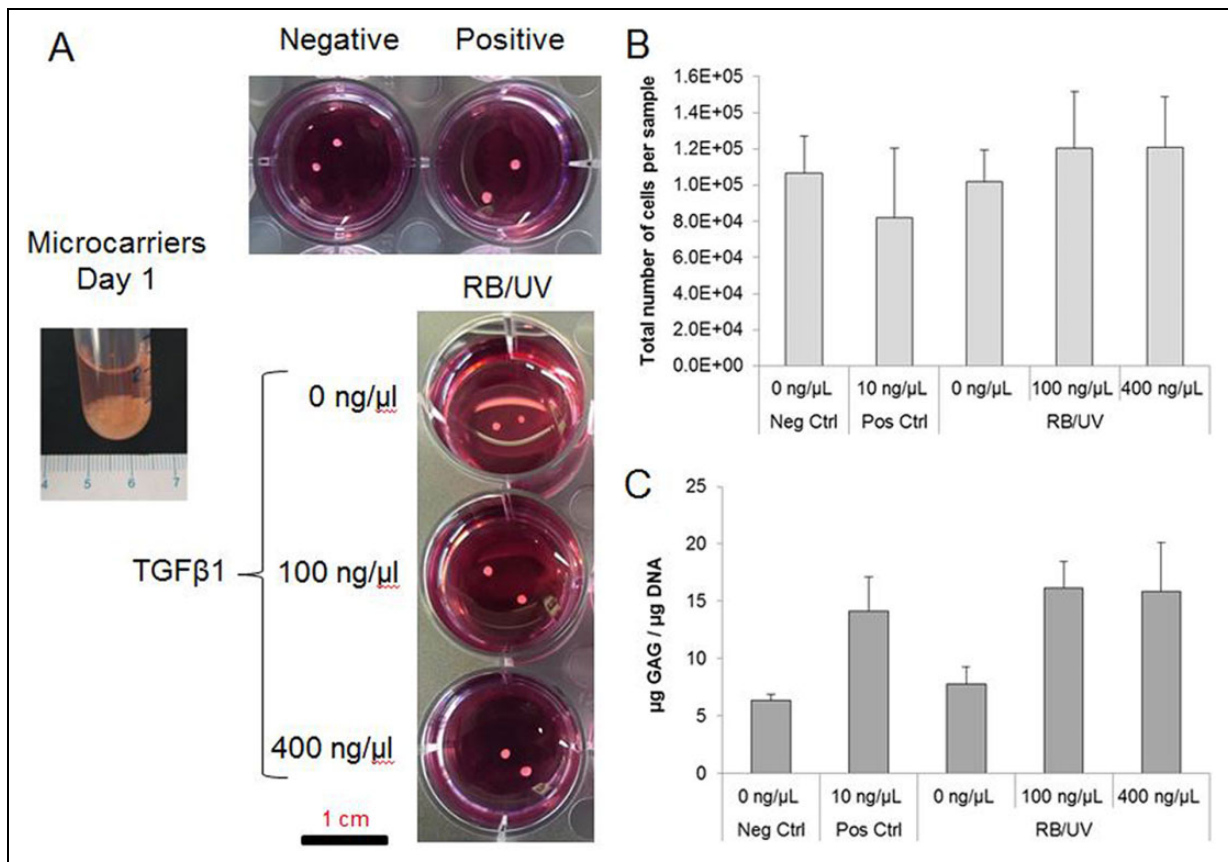


Fig. 1. *In vitro* assessment of chondrogenic potential of canine MSC. MSC ($n = 4$) were seeded on microcarriers crosslinked by RB/UV with 0, 100 or 400 ng/mL TGF β 1, or not crosslinked (controls), and cultured for 28 days. (A) Starting from a suspension, at the end of the assay MSC-microcarriers fused together to form a single and small construct. (B) The total amount of cells per sample was similar between groups, however the accumulation of glycosaminoglycan (C) was significantly higher in presence of TGF β 1, both crosslinked or in suspension.

data were acquired at 10 Hz. The loading protocol was defined that 100 loading steps were applied on each of the four positions of the pin (the actuator and pin were rotated 90° sequentially to anterior–right–posterior–left), and this was repeated for 14 loading cycles. Therefore, 14 (full loading cycles) \times 4 (positions) \times 100 (loading steps) = 5600 loading steps in total were applied. Each specimen was tested sequentially three times, (1) in the intact condition, (2) after 72 h of the nucleus pulposus digestion injected with a papain solution (120 U/mL, Sigma, Buchs, Switzerland) and (3) after injection of 0.5 ml microcarrier solution (250 mg collagen/5 mL phosphate-buffered saline solution (PBS), AppliChem, Axonlab, Baden, Switzerland) - previously stained with coomassie blue (AppliChem) - into the digested nucleus pulposus through the ventral annulus. In total, 18 tests were performed and evaluated. To determine whether there was leakage of the microcarriers during the loading procedure, the specimens were filmed (time lapse, one picture every two seconds) and visually observed. After the loading procedure, the lumbosacral disc was cut in a transverse plane and the cut surfaces were examined for presence of stained microcarrier solution.

Clinical Study

Study population. Twenty client-owned dogs were recruited from consecutive appointments at the neurological service of the clinic for small animals, Vetsuisse faculty of the University of Zurich. Dogs were included in the study when clinical signs and MRI findings confirmed the diagnosis of degenerative lumbosacral stenosis (DLSS) caused by a degenerated and centrally protruded L7-S1 disc. Only dogs diagnosed with overt compression of the cauda equina nerve roots by a protruded and degenerated IVD were selected. Breeds included: Belgian Malinois, Labrador Retriever, German Shepherd, Berger Blanc Suisse, Rhodesian Ridgeback, German Longhair and Dalmatian. Fourteen dogs were male, six dogs were female, and the median weight was 34.5 kg (range 25–42 kg) with a median age of 6 years (range 3–8 years old). Written owner consent was obtained for all animals. Since the dogs included in this study were clinical patients with a clear indication for decompressive surgery and not experimental animals, intradiscal injection of MSC-microcarrier could be performed concomitantly without any additional invasive procedures. All dogs presented with a

complaint of chronic history of back pain suggestive of a lesion in the lumbosacral area. A standardized owner questionnaire was used to collect historical details. All dogs were examined by a board-certified veterinary neurologist and subjected to a standardized clinical examination. Clinical signs of back pain for all dogs included caudal lumbar pain that manifested as difficulties jumping and occasional crying during exercise. Pain could be elicited when pressure was applied to the lumbosacral junction and during the lordosis test of the caudal lumbar spine in all dogs. The results of the clinical assessment and owner questionnaire were combined and expressed in a custom-designed score to quantify the dogs' clinical status. A dog without lumbosacral pain and normal neurological function of the cauda equina received a score of 21. Diagnosis of DLSS was confirmed by MRI demonstrating compression of the nerve roots of the cauda equina due to protrusion of a degenerated lumbosacral disc.

MSC isolation, culture and cell-microcarrier preparation. Autologous bone marrow-derived MSC were harvested and isolated from clinically affected dogs, as published previously^{12,15}. Briefly, bone marrow was obtained under general anaesthesia from the iliac crest. Bone marrow samples were diluted in 3.8% sodium citrate (AppliChem) to prevent clotting. After addition of PBS, samples were centrifuged at 500g for 10 minutes. The isolated cells (including erythrocytes) were counted and plated at a density of 5×10^7 cells/cm² in α -MEM (Amimed – Bio Concept, Allschwil, Switzerland) supplemented with 10% foetal bovine serum (FBS), 100 units/mL penicillin/streptomycin (both Gibco – LuBioScience, Lucerne, Switzerland) and 2.5 μ g/mL amphotericin B (AppliChem) at 37°C, 5% CO₂ and 5% O₂. After 2 days, non-adherent cells were removed, while adherent cells were washed with PBS and then cultured as described above, except medium was supplemented with 5 ng/mL human recombinant basic fibroblast growth factor (bFGF, Peprotech – LuBioScience).

After 8–10 days – depending on how fast cells were growing – MSC were detached, counted and seeded at a density of 3×10^6 cells/250 mg on collagen microcarriers (MSC-microcarrier)¹⁶, with or without crosslinking with 100 ng/mL of human recombinant TGF- β 1 (Peprotech) by riboflavin (RB) (AppliChem) and UV radiation (MSC-TGF- β 1-microcarriers)¹⁴. Briefly, the preparation of microcarriers was achieved by shearing of a sterile collagen sponge pad soaked in PBS in Dispomix Drive system (Axonlab). Then, microcarriers were incubated for 2 h at 37°C in 160 μ M RB solution, followed by 250 mJ/sec UVA irradiation for 5 min into a UV crosslinker (Stratalinker – Stratagene, Basel, Switzerland), and three washes in PBS. TGF- β 1 was covalently bound to activated microcarriers for 2 h at room temperature, followed by quenching with 50 mM glycine (AppliChem) and three washes in PBS. Finally, cell attachment to scaffolds was promoted by incubating cell suspension with microcarriers in non-adherent propylene tubes (Falcon). MSC-microcarrier and MSC-TGF- β 1-microcarriers were

left to settle 2 days in a hypoxic culture medium at 37°C, 5% CO₂ and 5% O₂. Before injection, both preparations were washed with PBS. The whole protocol, from bone marrow sampling to cell-microcarriers injection, lasted between 12 to 14 days.

MSC transplantation. Clinically affected dogs underwent a decompressive surgical procedure consisting of a dorsal laminectomy of the most caudal aspect of L7 and S1. After gentle retraction of the cauda equine nerve roots, the underlying dorsal annulus fibrosus was exposed and the injection site of MSC-microcarrier suspension could be easily identified. The procedure has been published in detail previously¹².

Dogs were randomly assigned to groups receiving an injection consisting of a suspension of MSC and microcarriers (group 1; $n = 11$), MSC and microcarriers crosslinked with TGF- β 1 (group 2; $n = 6$) and microcarriers only (control group; $n = 3$) in PBS. Initially, 1 mL of the suspension was injected into degenerated IVD (group 1), but the volume was reduced to 0.5 mL (group 2 and control group) after interim analysis of follow-up MRI, to prevent the potential formation of Schmorl's nodes. The suspension was injected into the L7/S1 IVD, at a depth of 1 cm into the centre (nucleus pulposus), using a 0.7 mm needle (22G) and a 2 ml syringe. After injection, the vertebral canal was flushed with physiologic saline and the wound was closed in a routine manner.

Post-operative care consisted of administration of parenteral buprenorphine (0.02 mg/kg iv; Temgesic, Reckitt Benckiser AG) for the first 24 h, and carprofen (4 mg/kg post-operatively; Canidryl, Dr. E. Gräub AG) for 6 days. Post-operative exercise consisted of short walks of 5 min three times daily during the first week, followed by increased exercise on the leash in a stepwise manner over 4 weeks. After this initial period of restricted activity, dogs were gradually familiarized to unlimited activity for a further 4 weeks.

Follow-up – clinical status, owner assessment and diagnostic imaging for evaluation of regenerative effects. Dogs were examined 1 day after surgery and 10 months post-operatively, as described previously by our group¹². Briefly, clinical assessment consisted of a physical and neurological examination performed by a board-certified neurologist (FS) to identify neurological deficits and signs of pain. For the late follow-up, the standardized owner questionnaire was again used to evaluate the dogs' condition during unrestricted, daily exercise. If dogs developed clinical signs before the 10 months follow-up, they were assessed and scored clinically and underwent an intermediate MRI examination.

MRI of the lumbosacral junction was performed to support the clinical diagnosis of DLSS and to assess the degenerative stage of the IVD using the Pfirrmann scheme validated for dogs¹⁷, prior to and after treatment. A 3 T MRI system (Philips Ingenia 3 T with dStream body coil solution;

Philips AG) was used. Dogs were positioned in dorsal recumbence with the pelvic limbs in extension. T2-weighted and T1-weighted turbo spin echo sequences were obtained.

In-Vitro Testing of Canine MSC on Crosslinked Microcarriers

Preparation of crosslinked microcarriers was performed as already described in our previous work¹⁶. Briefly, microcarriers were incubated for 2 h at 37°C in 160 µM RB solution (AppliChem), followed by 250 mJ/sec UV-A irradiation for 5 min into a UV crosslinker (Stratalinker). TGF-β1 (Peprotech) was covalently bound to activated microcarriers for 2 h at room temperature in a final volume of 500 µL, and then quenched with 50 mM glycine (AppliChem). Crosslinked microcarriers were used as a support for chondrogenic differentiation. Cell attachment to scaffolds was promoted by incubating cell suspension with microcarriers in non-adherent propylene tubes (Falcon; Faust, Schaffhausen, Switzerland).

Chondrogenic culture. To induce chondrogenesis, microcarriers were cross-linked with 0, 100 ng/ml and 400 ng/mL TGF-β1 before cell attachment. 5 mg of cross-linked microcarriers and 3 × 10⁵ canine MSC ($n = 4$) were cultured for 28 days under hypoxic conditions (5% O₂), in medium consisting of DMEM/Ham's F12 (Gibco), supplemented with 2.5% FBS, 40 ng/mL dexamethasone (AppliChem), 50 µg/mL ascorbate-2-phosphate (Sigma), 50 µg/mL L-proline (Sigma), 100 U/mL penicillin/streptomycin, 2.5 µg/ml amphotericin B and 1X ITS-X supplement (10 µg/ml Insulin, 5.5 µg/ml Transferrin and 0.67 ng/ml Selenium; Gibco). As controls, non-cross-linked MSC-microcarriers were differentiated in absence (negative) or presence (positive) of 10 ng/ml TGF-β1 in culture medium. All media were changed three times per week.

Cell counting. At the end on the differentiation assay, MSC-microcarriers were digested with 0.3% pronase (Invitrogen) and 0.05% collagenase type II (Gibco) in DMEM/Ham's F12, supplemented with 10% FBS, 100 U/mL penicillin/streptomycin and 2.5 µg/ml Amphotericin B at 37°C for 2 h. After washing with PBS, cells were counted using trypan blue dye in Neubauer chamber (Bioswisstec, Schaffhausen, Switzerland).

Glycosaminoglycan (GAG) quantification. GAG accumulation was quantified with alcian blue binding assay after 6 h digestion of three constructs per sample at 60°C with 125 µg/ml papain (Sigma) in 5 mM L-cysteine-HCl (Fluka-Sigma), 5 mM Na-citrate, 150 mM NaCl, 5 mM EDTA (all AppliChem). GAG accumulation was determined by binding to alcian blue (Sigma), absorption was measured at 595 nm and quantified against chondroitin sulphate (Sigma) reference standards¹⁸. Total double stranded DNA was measured for

each sample after papain digestion. The amount of DNA was determined using SYBR green (Invitrogen) fluorescent assay (absorption measured at 535 nm), quantified by referring to calf thymus DNA standards (Sigma).

Statistical Analysis

Differences in mechanical behaviour of IVD *ex vivo* were assessed by Kruskal–Wallis test, while changes in cell counts and GAG accumulation was analysed by non-parametric Mann–Whitney–Wilcoxon *U* test for dependent variables. For all tests, $p < 0.05$ was considered significant. Data analysis was performed with SPSS 25.0 for Windows (SPSS Inc., Chicago, IL, USA).

Results

Chondrogenic Differentiation In Vitro of Canine MSC on TGF-β1 Crosslinked Microcarriers

Prior to MSC seeding, microcarriers were crosslinked with 0, 100 and 400 ng/mL TGF-β1 by RB/UV (MSC-TGF-β1-microcarriers). As controls, MSC were seeded on microcarriers not crosslinked and cultured with (positive control) or without (negative control) 10 ng/mL TGF-β1 in solution. Starting with an initial loose consistency at day 1, MSC-TGF-β1-microcarriers ($n = 4$) fused together and formed, after 28 days in culture, a single solid spherical construct per well in all groups (Fig. 1A). Compared to controls, MSC-TGF-β1-microcarriers showed no significant variations in the number of cells retained per sample; on average 1.06 × 10⁵ cells/sample (Fig. 1B). GAG accumulation was quantified by alcian blue precipitation reaction (Fig. 1C) and in the absence of TGF-β1, cells accumulated almost 50% less GAG (7 µg GAG/µg DNA) compared to positive control (14 µg GAG/µg DNA; $p < 0.05$). The crosslinked MSC-TGF-β1 group promoted similar to the positive control proteoglycan accumulation (16 µg GAG/µg DNA).

Biomechanical Testing on Isolated Cadaveric Lumbosacral Segments

Before IVD loading tests (Fig. 2A), some samples showed stiffness and alignment changes after digestion of the nucleus pulposus (Fig. 2B). The injection of microcarriers into the digested IVD led to a restoration of disc height and orientation. During IVD loading, every test was filmed in time lapse and visually evaluated. The tests showed that in all cases ($n = 6$) the injected microcarriers were not expelled during loading. After loading tests, IVD were transversely sectioned, and retention of pre-stained with coomassie blue microcarriers in situ was observed in all specimens (Fig. 2C).

To have an objective measure of possible mechanical changes due to digestion and microcarrier injection, a stiffness analysis was performed. Stiffness evaluation per loading step was defined as the maximum gradient in the linear region of the force-displacement curve. Since every sample

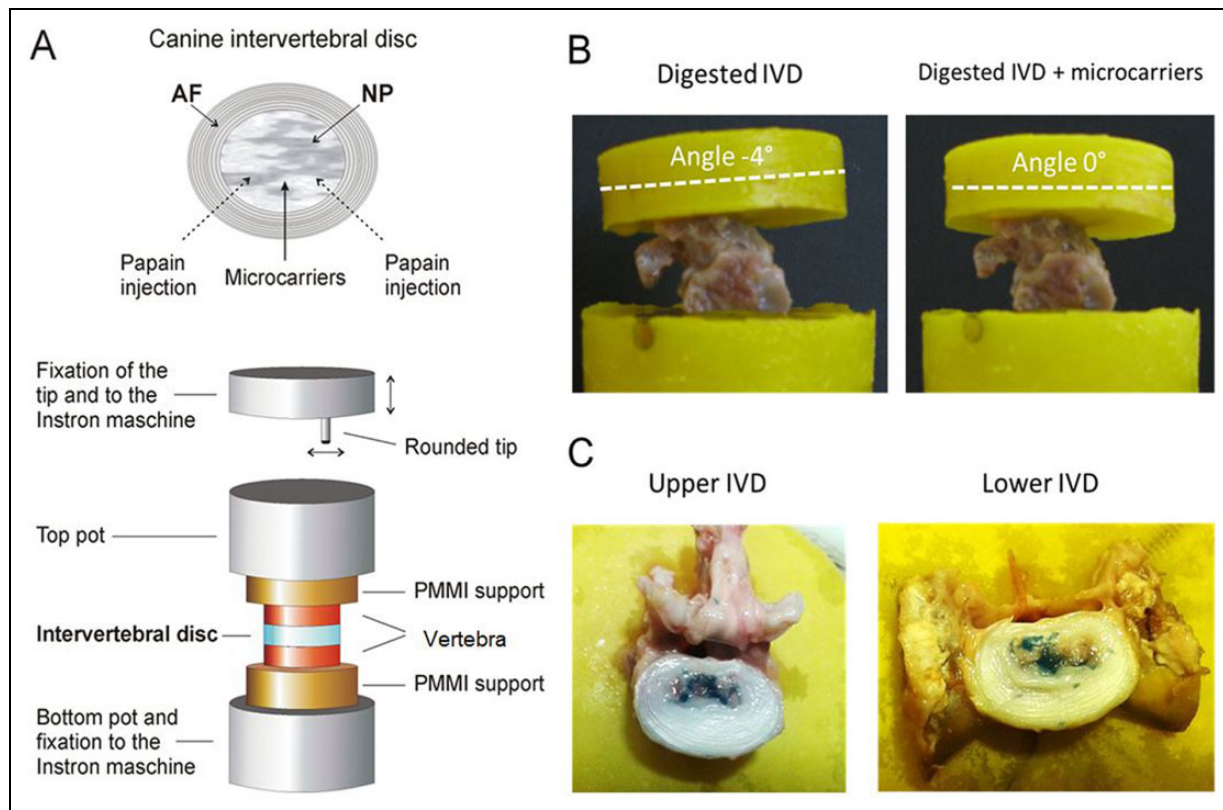


Fig. 2. *Ex vivo* stiffness evaluation of canine IVD, before and after microcarrier injection. (A) The procedure used to test IVD stiffness is summarized in the diagram. Preceding loading test, nucleus pulposus was digested with papain (injected laterally into the disc) for 72 hours. (B) Following digestion, the upper part of IVD segment was inclined due to heterogeneous structural impairment of the disc, and injection of microcarriers restored the alignment. The IVD segment was then fixed to the Instron machine and loaded 5600 times (20 N to 200 N) with the loading point offset 25 mm from the centre axis. (C) After injection of the microcarrier (stained with coomassie blue) and the loading procedure, no microcarriers were visually extruded and the transversal cut of the IVD shows blue areas indicating retainment of the injected microcarriers.

was loaded on four positions (anterior–right–posterior–left) and the test consisted of multiple loading cycles over time, a mean stiffness for each position and each loading cycle was calculated. The stiffness values for all the positions were compared within the three conditions (non-digested, digested, digested with microcarriers). It was expected that the non-digested and the digested samples would show different stiffness parameters and that with the injection of the collagen microcarriers into the digested discs the stiffness would tend to go back to non-digested state. Some of the samples showed a minor tendency towards such behaviour, but these improvements were not statistically significant (data not shown).

Feasibility, Safety and Clinical Outcome

Dogs treated with microcarriers improved in terms of pain and disability score (Table 1). The median pre-operative score of dogs treated with MSC-microcarriers ($n = 11$) was 14.0 (range 12–19) and improved to a median final post-operative score of 20 (range 20–21). Dogs injected with

MSC-TGF- β 1-microcarriers ($n = 6$), had a median pre-operative score of 16.0 (range 13–16) and a post-operative score of 20.5 (range 20–21). In the group of dogs treated with microcarriers only ($n = 3$), the pre-operative score was 14.0 (range 11–16) and the score improved to 21 (range 20–21) at the end of the study. When mean values of postoperative improvement were compared, they were 6 and 7 score points respectively for the MSC-microcarriers treated dogs and the microcarriers-only treated dogs. After 10 months, follow-up MRI showed no changes of the Pfirrmann score of degenerated IVD injected with MSC-microcarriers (Fig. 3A), MSC-TGF- β 1-microcarriers (Fig. 3B) and microcarriers only (Fig. 3C). Therefore, pre- and post-operative score in all dogs were identical (Table 2).

Although intradiscal injections were well-tolerated clinically by 18 dogs, 2 dogs developed clinical signs consisting of increased pain in the lower back, reluctance to rise and move and occasional vocalization during exercise during the follow-up period. Clinical signs occurred 3–4 months after intradiscal injection of an MSC-microcarrier. In both dogs, the neurological examination revealed a short-stridden gait

Table 1. Pre- and Post-Operative Clinical Scores of the Dogs Suffering Degenerative Lumbosacral Stenosis.

	Dog breed	Pre-operative score	Intermediate post-operative score*	Final post-operative score
MSC + microcarriers	German Shepherd	15	–	21
	German Shepherd	18	–	21
	Berger Blanc Suisse	14	–	21
	Border Collie	15	–	21
	Labrador Retriever	14	12	19
	Belgian Malinois	15	–	21
	Belgian Malinois	12	–	21
	Labrador Retriever	15	17	20
	Belgian Malinois	14	–	21
	Dalmatian	11	–	21
MSC + TGFβ1 crosslinked microcarriers	German Shepherd	19	–	21
	German Shepherd	16	–	21
	German Shepherd	13	–	20
	Rhod. Ridgeback	16	–	21
	German Longhair	16	–	20
	German Shepherd	14	–	21
	German Shepherd	16	–	20
Microcarriers only	Labrador Retriever	14	–	21
	Belgian Malinois	16	–	21
	German Shepherd	11	–	20

*Intermediate post-operative scoring was performed only in dogs that developed clinical signs during the follow-up period.

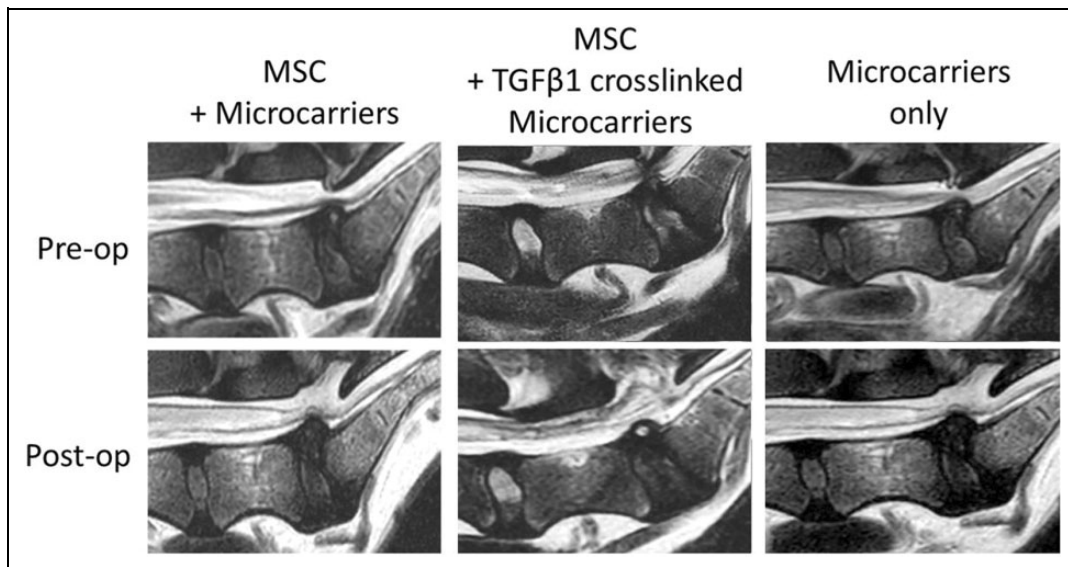


Fig. 3. Magnetic resonance imaging of pre- and post-operative IVD. Sagittal T2-weighted MRI of spontaneously degenerated lumbo-sacral discs treated with MSC + microcarriers ($n = 11$), MSC + TGFβ1 crosslinked microcarriers ($n = 6$) and microcarriers only ($n = 3$, control group). Injection into L7/S1 was performed ventrally, and microcarriers were injected at both side of IVD to obtain a more uniform spread into the nucleus pulposus. After 10 months, MRI follow-up showed neither improvement nor deterioration of the IVD morphology.

in the pelvic limbs, an abnormal posture with flexion of the caudal lumbar area and the tail was carried in low position. Painful reactions could be elicited during palpation of the lumbo-sacral area and lordosis. Neurological deficits were not detected in any of the dogs and the physical examination and blood haematology and chemistry did not reveal any

abnormalities. Both dogs underwent an intermediate MRI examination to investigate the source of the clinical problem. MRI showed specific morphological abnormalities/lesions absent on pre-operative images (Fig. 4A). Specifically, the lesions were characterized by focal and rounded hyperintensities in the subchondral marrow on T2-weighted images of

Table 2. Evaluation of Pre- and Post-Operative Degree of Degeneration of L7-S1 Intervertebral Discs in the Treated Dogs, Based on the Pfirrmann Grading Scale.

	Dog breed	Pre-operative degree	Intermediate post-operative degree*	Final post-operative degree
MSC + microcarriers	German Shepherd	3	–	3
	German Shepherd	3	–	3
	Berger Blanc Suisse	3	–	3
	Border Collie	3	–	3
	Labrador Retriever	3	3 SN	4 SN
	Belgian Malinois	3	–	3 SN
	Belgian Malinois	4	–	4 SN
	Labrador Retriever	3	3 SN	3 SN
	Belgian Malinois	3	–	3 SN
	Dalmatian	3	–	3
	German Shepherd	3	–	3
MSC + TGFβ1 crosslinked microcarriers	German Shepherd	3	–	3
	German Shepherd	4	–	4
	Rhod. Ridgeback	3	–	3
	German Longhair	4	–	4 SN
	German Shepherd	2	–	2
	German Shepherd	3	–	3
	Labrador Retriever	3	–	3
Microcarriers only	Labrador Retriever	3	–	3
	Belgian Malinois	3	–	3
	German Shepherd	3	–	3

*Intermediate post-operative scoring was performed only in dogs that developed clinical signs during the follow-up period; SN = Schmorl's nodes.

L7 and S1 (Fig. 4B). T1-weighted images (Fig. 4C) revealed defects in the endplates at the level of the previously described hyperintensities approximately at the level of the nucleus pulposus. After administration of intravenous contrast medium (Fig. 4D), there was marked enhancement in the area of the hyperintensities and endplate defects. No contrast accumulation was observed within the IVD or paravertebral structures (Fig. 4). Morphology and signal changes of the lesions fulfilled the diagnostic criteria for Schmorl's nodes (SN) – nucleus pulposus protrusion into vertebral body – as described in people and dogs^{19,20}. Six dogs (30%) developed SN: five dogs injected with MSC-microcarriers (1 mL injection volume), and one dog with MSC-TGF-β1-microcarriers and microcarriers only (0.5 mL injection volume). We observed that the reduction of injection volume from 1 mL to 0.5 mL decreased the risk of SN formation (from 45% to 11%). Four of six dogs affected with SN did not display clinical signs and only two dogs described above had transient lumbosacral pain.

The two dogs with lumbosacral pain were treated with non-steroidal anti-inflammatory drugs (Carprofen 4mg/kg orally every 24 hours) and antibiotics (Clavaseptin 12.5 mg/kg orally every 12 hours for 14 days; Vetoquinol AG) and were returned to limited exercise and rest. Following these measures, a return to normal function was observed within 10 days. After a follow-up at 10 months, the dogs were without lumbosacral pain and had clinical scores comparable to those of the unaffected dogs (20 for both). Interestingly, SN formation was associated with an increased Pfirrmann score at the time of the final MRI only in one affected dog.

Discussion

The present investigation demonstrated that MSC seeded on collagen microcarriers can be easily administered and the constructs remain in situ after intradiscal injection in canine lumbosacral discs. However, MRI showed no signs of disc regeneration based upon the Pfirrmann grade, meaning that the degeneration status of the IVD did not improve after 10 months post-operative in any of the three groups. Concomitantly, we did not observe any progression of IVD degeneration by stab of the thin needle (0.7 mm–1.0 mm int./ext. diameter) through which the microcarriers were injected.

Recently, we published a study in which dogs suffering IVD degeneration were treated with autologous bone marrow-derived MSC in absence of injectable scaffold, in which similarly, we were not able to demonstrate any apparent regenerative effect of the treatment. In fact, progression of degeneration (1 Pfirrmann grade) was observed in dogs receiving MSC whereas in dogs with only saline injection, the Pfirrmann grade remained the same 12 months post injection¹². There are various causes for the modest effectiveness of disc regeneration in the naturally degenerated disc. Once injected into the IVD, MSC will face the challenges of a difficult environment, under constant load and hypoxic conditions¹³. Additionally, after removal of degenerated disc tissue, the implanted cells may need too much time to differentiate and generate new disc tissue and a more probable scenario might be that undesired scar tissue (collagen type-I) is formed instead²¹, or cells which leaked out of the disc and reached bone surfaces form osteophytes²². To

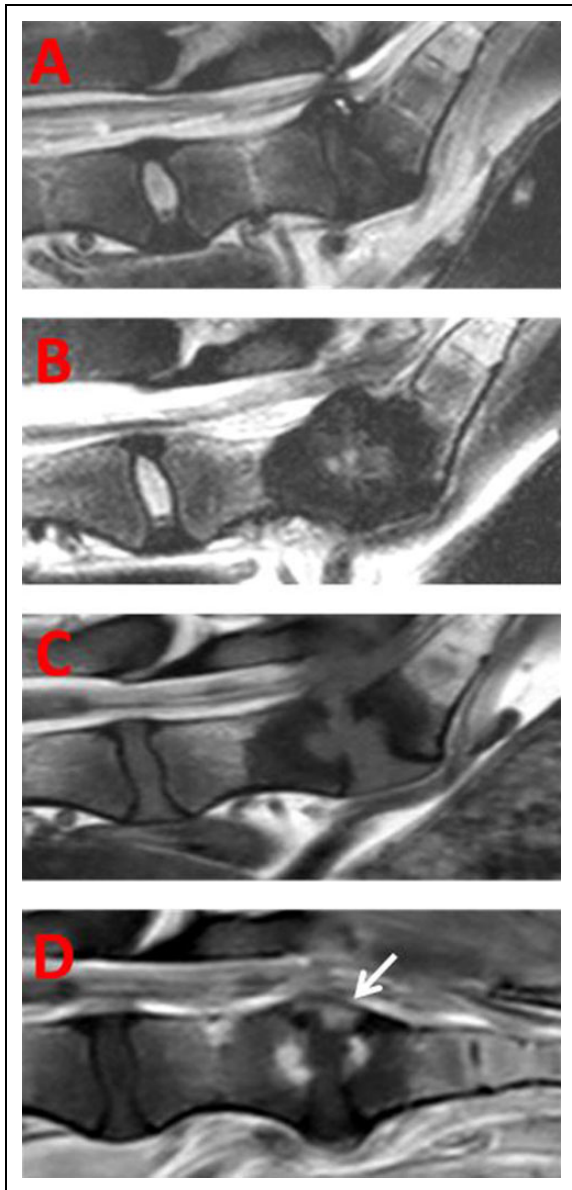


Fig. 4. Morphology and signal changes occurring with Schmorl's nodes formation. Pre-operative T2-weighted MRI (A) and different sequences of an intermediate post-operative MRI study (B-D) of the lumbosacral area of a six-year-old Labrador Retriever that developed clinical signs three months after injection of MSC + microcarrier into L7-S1. T2-weighted MRI (B) with diffuse hyperintense signal in the area of nucleus pulposus, adjacent endplate and subchondral bone marrow. T1-weighted MRI (C) demonstrating focal defects in the endplates of L7 and S1. Gadolinium enhanced T1-weighted MRI (D) with marked contrast uptake within the subchondral bone marrow at the level of the endplate defects. There is also a small area of contrast uptake in the dorsal annulus indicating a fissure in the degenerated annulus fibrosus and ingrowth of vessels (white arrow).

address these problems, we pre-cultured MSC in hypoxic conditions (5% O₂) and transferred them on collagen microcarriers in the role of three-dimensional (3D) scaffolds, to

improve cell viability and accelerate the process of matrix production after intradiscal injection. Additionally, we used microcarriers crosslinked with immobilized TGF- β 1 in order to keep the growth factor at high local concentration¹⁴, thus hoping to recreate improved cell differentiation conditions, as we could prove *in vitro*. However, despite clinical improvement of the treated dogs after the injection of MSC-TGF- β 1-microcarriers, there was no MRI-detectable improvement of IVD morphology reflected by the Pfirrmann score.

Marked clinical improvement was noted in all groups, suggesting that improved function was rather due to the concomitant surgical decompression than being related to intradiscal cell therapy. However, these results cannot be translated directly into the human situation because functional differences between groups may become obvious in people due to improvements in pain that can only be obtained by verbal communication as used in the Oswestry disability index, which includes more thorough testing procedures and verbal communication allowing a more precise grading than was possible in animals. Lack of precise description of pain sensation and disability represent the main problems when animal models are used for translational comparative studies.

From a biomechanical point of view, we evaluated the apparent disc stiffness throughout the *ex vivo* testing and registered the mechanical changes. As expected from a viscoelastic material, every IVD showed certain creep behaviour. Creeping in the IVD occurs partly due to viscoelastic effects, but primarily by water expulsion from the tissue. Creep was observed in all specimens. However, no consistent differences were found between the groups. The evaluation of the apparent stiffness did not show significant differences between the three groups (non-digested IVD, digested IVD and microcarriers + digested IVD), for any of the loading cycles evaluated (i.e. short- or long-term). From a morphological point of view, microcarriers can serve as a scaffold for repopulation of local IVD cells and also as a spacer, but with no demonstrable mechanical advantage.

In the *ex vivo* experiment, no leakage was observed during mechanical loading after injection of stained microcarriers. Leakage, that is, extrusion of injected MSC through the puncture site of the dorsal annulus fibrosus, has been associated with both lack of regeneration of the IVD and adverse side-effects. A previous study reported that less than 1% of labelled MSC were detected in the nucleus pulposus after injection of MSC in saline²³. In addition, extruded MSC have been associated with osteophyte-formation at the puncture site representing a potentially painful complication²². Consequently, prevention of cell leakage was a main focus of our study and other groups' investigation. A recent experimental study in rabbit discs demonstrated that MSC in collagen microspheric microcarriers resulted in a reduced risk for osteophyte formation at the puncture site because they remained *in situ*²⁴. Based upon these experimental results, newly designed clinical trials were expected to outperform

the modest results of previous clinical trials in people and dogs using MSC suspension in saline injected into the IVD.

However, our clinical investigation demonstrated that prevention of extrusion did not enhance disc regeneration based upon assessment of improved Pfirrmann grade and moreover, bears the risk of a previously undescribed side effect consisting of the formation of Schmorl's nodes (SN). SN are protrusions of disc material into the vertebral body and contact the subchondral bone marrow where it induces inflammation. This is the first evidence of this previously undescribed, undesired side effect in intradiscal cell therapies. Focal failure of endplate is a key element in the pathophysiology of SN. Various pathologies involving the spine may weaken the IVD and vertebral endplates, allowing SN to form. Specifically, trauma, IVD degeneration, congenital abnormalities and autoimmune mechanisms were identified as aetiologies²⁵. In the present study, the association between SN and intradiscal injection of MSC-microcarriers was straightforward. The most likely hypothesis is that SN resulted from increased focal pressure on the endplate by the microcarrier deposit. Clinically, SN are often incidental findings and remain clinically silent in people (14). As only two of six dogs with SN were clinically affected in the present study, this seems to apply also to veterinary patients. We could reduce the occurrence of SN from 45% to 11% of the cases, by decreasing the injection volume of from 1 mL to 0.5 mL. As a direct consequence we recommend using lower injection volumes in IVD cellular therapy, especially when scaffolds are used.

As limitations of the study, we could not introduce any segmental stabilization of the lumbosacral vertebra – in addition to microcarrier injection – to neutralize biomechanics because this would have changed the study. Furthermore, due to the restricted number of dogs, we could not test more than one cell concentration (3×10^6 MSC/dog) per IVD treated. Assignment of dogs to the different groups was performed in a consecutive way, that is, the first group was treated with MSC-microcarriers, followed by the second group with MSC-TGF- β 1-microcarriers. Since the interim analysis of the follow-up MRI revealed no improvement of the Pfirrmann grade in the group treated with MSC-microcarriers, we opted to stop the recruitment, resulting in an uneven distribution of dogs per group. In addition, the relatively low number of clinical cases precluded the use of inferential statistics which may have affected some of the results of this investigation. In the small microcarriers-only group one of the dogs started with a very low clinical score of 11 due to incontinence and improved with nine score points, reaching the average for all groups end score of 20, potentially introducing an outlier bias.

In conclusion, injection of MSC seeded on microcarriers into IVD prevented leakage of MSC but did not regenerate the canine lumbosacral IVD. Formation of SN was an undesired side effect of this treatment protocol; however, the clinical outcome was not affected by this complication.

Partially, the risk of this complication can be reduced by lowering the injection volume.

Ethical Approval

Injection of MSC into the dogs' IVD was performed concomitantly with the clinically indicated surgical decompression in all cases and ethical approval was not needed for this article.

Statement of Human and Animal Rights

Leftover lumbosacral segments from six healthy and young adult Beagle dogs were used for biomechanical testing (the dogs were bred for experimental use and served as controls in another, pharmacological, study by Novartis Pharma AG, Basel, Switzerland). The lumbosacral joint (L6-S2) was isolated from the cadavers and freed from muscles leaving the ligamentous structures intact. The spinal specimens were then donated to our institution and stored at -20°C .

Since the dogs included in this clinical study were not experimental animals but considered clinical patients with a clear indication for decompressive surgery, intradiscal injection of MSC-microcarrier could be performed concomitantly without any additional invasive procedures.

Statement of Informed Consent

Written informed consent was obtained from the owners of the patient dogs.


Declaration of Conflicting Interests

The author(s) declared no potential conflicts of interest with respect to the research, authorship, and/or publication of this article.

Funding

The author(s) disclosed receipt of the following financial support for the research, authorship, and/or publication of this article: This research was supported by the Swiss Paraplegic Foundation and the Swiss National Foundation (Grant number: CR2313_159744).

ORCID iD

Jivko Stoyanov  <https://orcid.org/0000-0001-6842-6284>

References

1. Luoma K, Riihimaki H, Luukkonen R, Raininko R, Viikari-Juntura E, Lamminen A. Low back pain in relation to lumbar disc degeneration. *Spine (Phila Pa 1976)*. 2000;25(4):487–92.
2. Wieser S, Horisberger B, Schmidhauser S, Eisenring C, Brugger U, Ruckstuhl A, Dietrich J, Mannion AF, Elfering A, Tamcan O, et al. Cost of low back pain in Switzerland in 2005. *Eur J Health Econ*. 2011;12(5):455–67.
3. Wenig CM, Schmidt CO, Kohlmann T, Schweikert B. Costs of back pain in Germany. *Eur J Pain*. 2009;13(3):280–6.
4. Zeckser J, Wolff M, Tucker J, Goodwin J. Multipotent mesenchymal stem cell treatment for discogenic low back pain and disc degeneration. *Stem Cells Int*. 2016;2016:3908389.
5. Kisiel AH, McDuffee LA, Masaoud E, Bailey TR, Esparza Gonzalez BP, Nino-Fong R. Isolation, characterization, and in vitro proliferation of canine mesenchymal stem cells derived from bone marrow, adipose tissue, muscle, and periosteum. *Am J Vet Res*. 2012;73(8):1305–17.

6. Ryu HH, Kang BJ, Park SS, Kim Y, Sung GJ, Woo HM, Kim WH, Kweon OK. Comparison of mesenchymal stem cells derived from fat, bone marrow, Wharton's jelly, and umbilical cord blood for treating spinal cord injuries in dogs. *J Vet Med Sci.* 2012;74(12):1617–30.
7. Kang BJ, Ryu HH, Park SS, Koyama Y, Kikuchi M, Woo HM, Kim WH, Kweon OK. Comparing the osteogenic potential of canine mesenchymal stem cells derived from adipose tissues, bone marrow, umbilical cord blood, and Wharton's jelly for treating bone defects. *J Vet Sci.* 2012;13(3):299–310.
8. Vela DC, Silva GV, Assad JA, Sousa AL, Coulter S, Fernandes MR, Perin EC, Willerson JT, Buja LM. Histopathological study of healing after allogenic mesenchymal stem cell delivery in myocardial infarction in dogs. *J Histochem Cytochem.* 2009;57(2):167–76.
9. Le Maitre CL, Baird P, Freemont AJ, Hoyland JA. An in vitro study investigating the survival and phenotype of mesenchymal stem cells following injection into nucleus pulposus tissue. *Arthritis Res Ther.* 2009;11(1):R20.
10. Hiyama A, Mochida J, Iwashina T, Omi H, Watanabe T, Serigano K, Tamura F, Sakai D. Transplantation of mesenchymal stem cells in a canine disc degeneration model. *J Orthop Res.* 2008;26(5):589–600.
11. Orozco L, Soler R, Morera C, Alberca M, Sanchez A, Garcia-Sancho J. Intervertebral disc repair by autologous mesenchymal bone marrow cells: a pilot study. *Transplantation.* 2011;92(7):822–8.
12. Steffen F, Smolders L, Roentgen A, Bertolo A, Stoyanov J. Bone marrow-derived mesenchymal stem cells as autologous therapy in dogs with naturally occurring intervertebral disc disease: Feasibility, safety and preliminary results. *Tissue Eng Part C Methods.* 2017;23(11):643–51.
13. Adams MA, Roughley PJ. What is intervertebral disc degeneration, and what causes it? *Spine (Phila Pa 1976).* 2006;31(18):2151–61.
14. Bertolo A, Arcolino F, Capossela S, Taddei AR, Baur M, Potzel T, Stoyanov J. Growth factors cross-linked to collagen microcarriers promote expansion and chondrogenic differentiation of human mesenchymal stem cells. *Tissue Eng Part A.* 2015;21(19-20):2618–28.
15. Bertolo A, Steffen F, Malonzo-Marty C, Stoyanov J. Canine mesenchymal stem cell potential and the importance of dog breed - implication for cell-based therapies. *Cell Transplant.* 2014;24(10):1969–80.
16. Bertolo A, Hafner S, Taddei AR, Baur M, Potzel T, Steffen F, Stoyanov J. Injectable microcarriers as human mesenchymal stem cell support and their application for cartilage and degenerated intervertebral disc repair. *Eur Cell Mater.* 2015;29:70–81.
17. Bergknut N, Auriemma E, Wijsman S, Voorhout G, Hagman R, Lagerstedt AS, Hazewinkel HA, Meij BP. Evaluation of intervertebral disk degeneration in chondrodystrophic and non-chondrodystrophic dogs by use of Pfirrmann grading of images obtained with low-field magnetic resonance imaging. *Am J Vet Res.* 2011;72(7):893–8.
18. Bjornsson S. Simultaneous preparation and quantitation of proteoglycans by precipitation with alcian blue. *Anal Biochem.* 1993;210(2):282–91.
19. Gendron K, Doherr MG, Gavin P, Lang J. Magnetic resonance imaging characterization of vertebral endplate changes in the dog. *Vet Radiol Ultrasound.* 2012;53(1):50–6.
20. Mattei TA, Rehman AA. Schmorl's nodes: current pathophysiological, diagnostic, and therapeutic paradigms. *Neurosurg Rev.* 2014;37(1):39–46.
21. Raj PP. Intervertebral disc: Anatomy-physiology-pathophysiology-treatment. *Pain Pract.* 2008;8(1):18–44.
22. Vadala G, Sowa G, Hubert M, Gilbertson LG, Denaro V, Kang JD. Mesenchymal stem cells injection in degenerated intervertebral disc: cell leakage may induce osteophyte formation. *J Tissue Eng Regen Med.* 2012;6(5):348–55.
23. Crevensten G, Walsh AJ, Ananthakrishnan D, Page P, Wahba GM, Lotz JC, Berven S. Intervertebral disc cell therapy for regeneration: mesenchymal stem cell implantation in rat intervertebral discs. *Ann Biomed Eng.* 2004;32(3):430–4.
24. Li YY, Diao HJ, Chik TK, Chow CT, An XM, Leung V, Cheung KM, Chan BP. Delivering mesenchymal stem cells in collagen microsphere carriers to rabbit degenerative disc: reduced risk of osteophyte formation. *Tissue Eng Part A.* 2014;20(9-10):1379–91.
25. Kyere KA, Than KD, Wang AC, Rahman SU, Valdivia-Valdivia JM, La Marca F, Park P. Schmorl's nodes. *Eur Spine J.* 2012;21(11):2115–21.