

Positive fibroblast growth factor receptor 3 immunoreactivity is associated with low-grade non-invasive urothelial bladder cancer

CÉDRIC POYET¹, THOMAS HERMANN¹, QING ZHONG², EVA DRESCHER¹, DANIEL EBERLI¹, MAXIMILIAN BURGER³, FERDINAND HOFSTAEDTER⁴, ARNDT HARTMANN⁵, ROBERT STÖHR⁵, ELLEN C. ZWARTHOF⁶, TULLIO SULSER¹ and PETER J. WILD²

¹Department of Urology, ²Institute of Surgical Pathology, University Hospital Zurich, University of Zurich, Zurich CH-8091, Switzerland; ³Department of Urology, University Hospital Regensburg; ⁴Institute of Pathology, University of Regensburg, Regensburg 93059, Germany; ⁵Institute of Pathology, University of Erlangen, Erlangen 91054, Germany; ⁶Department of Pathology, Erasmus Medical Center, Rotterdam 3015, The Netherlands

Received July 6, 2015; Accepted August 5, 2015

DOI: 10.3892/ol.2015.3691

Abstract. In addition to conventional clinicopathological parameters, molecular markers are also required in order to predict the course of disease in patients with urothelial bladder cancer (BC). Little is known about fibroblast growth factor receptor 3 (FGFR3) immunoreactivity and the clinical significance it may possess with regard to BC. The present study aimed to investigate the immunoreactivity of FGFR3 in primary urothelial bladder tumours, with regard to clinicopathological features and *FGFR3* mutation status. Tissue microarrays were used to immunohistochemically analyse *FGFR3* expression in 255 primary, unselected patients with BC. *FGFR3* mutations were detected using SNaPshot analysis. Positive FGFR3 immunoreactivity was identified in 113/207 analysable cases (54.6%), and was significantly associated with *FGFR3* mutation ($P < 0.001$), low tumour stage ($P < 0.001$), low histological grade ($P < 0.001$) and a papillary growth pattern ($P < 0.001$). Positive FGFR3 immunostaining ($P = 0.002$) and *FGFR3* mutation ($P = 0.002$) were found to be significantly associated with increased disease-specific survival following univariate analysis, demonstrating a median follow-up period of 75 months. Using multivariate analyses, FGFR3 immunoreactivity was found not to be independent of classical

pathological parameters. Immunohistochemical expression of FGFR3 is an early occurrence during the carcinogenesis of papillary non-invasive BC. The presence of FGFR3 immunoreactivity in non-invasive papillary urothelial carcinomas may be utilised as an indicator of tumours possessing low-grade features and good prognosis.

Introduction

The majority of patients (75-80%) exhibiting bladder cancer (BC) typically present with papillary non-invasive (stage pTa) or early invasive (stage pT1) urothelial tumours. The remaining 20-25% of patients demonstrate more advanced, muscle-invasive tumours ($\geq pT2$) (1). A total of 70% of patients exhibiting stage pTa or pT1 BC will undergo recurrence, and up to 25% will develop muscle-invasive tumours (2). Therefore, patients with BC must be carefully monitored for signs of disease recurrence or progression. However, to date, there are no established biomarkers in clinical practice that are able to predict the risk of tumour progression.

Based on genetic data, the 2004 World Health Organization (WHO) classification indicates that urinary bladder neoplasia may be subdivided into low- and high-grade lesions (3). There are two genetic subtypes of BC tumour, which possess marked differences in their levels of genetic instability, and correspond to morphologically distinct entities (4). The first of these subtypes, the genetically stable category, includes low-grade non-invasive papillary tumours. The second genetic subtype, the genetically unstable category, encompasses high-grade and invasive carcinomas, including pTaG3 and pTis, as well as $\geq pT1$, respectively (3). Burger *et al* (5) compared the WHO 1973 and 2004 tumour classification systems, and each system contributed significant information regarding the progression of BC. The inter-observer variability of the WHO 2004 grading system, however, remains an unsolved problem for surgical pathology.

Fibroblast growth factor receptors (FGFRs) control crucial signalling pathways, which are responsible for numerous

Correspondence to: Dr. Cédric Poyet, Department of Urology, University Hospital Zurich, University of Zurich, 10 Frauenklinikstrasse, Zürich CH-8091, Switzerland
E-mail: cedric.poyet@usz.ch

Abbreviations: BC, bladder cancer; FGFR, fibroblast growth factor receptor; TMA, tissue microarray; RFS, recurrence-free survival; DSS, disease-specific survival

Key words: fibroblast growth factor receptor 3 protein, urothelial cancer, molecular markers, grading, prognosis

cellular functions, including proliferation and migration (6). FGFRs have been revealed to possess an oncogenic role in numerous types of cancer (7). By contrast, FGFR signalling may also have a suppressive effect on tumours (6). It has been established that BC possesses a link with *FGFR* mutations, and ~50% of BCs possess somatic mutations within the *FGFR3* coding sequence (8). Mutation of *FGFR3* is a common feature of low-grade, non-invasive papillary urothelial BC, occurring in ~75% of cases (9-12); while occurring at a markedly lower frequency in high-grade invasive BC (13,14), and rarely with adjacent carcinoma *in situ* (9,14). Patients exhibiting primary BCs accompanied by an activating *FGFR3* mutation had significantly improved disease-specific survival (DSS) when compared with patients without *FGFR3* mutations (11,15). *FGFR3* and *TP53* mutations were revealed to be mutually exclusive and may represent two distinct pathways for the development of BC (11,16,17). In these pathways, bladder cancer lesions with activating *FGFR3* mutations represent a type of genetically stable, low-grade, papillary tumour. In addition, amalgamation of the analysis of *FGFR3* mutations and Ki-67 immunohistochemistry, defined as molecular grading, was revealed to be superior to other parameters for predicting the progression and survival of patients exhibiting BC (11).

FGFR3 mutation status in BC, and the association of BC with the expression of FGFR3 protein, has previously been examined (18,19). The combination of WHO 2004 grading with *FGFR3* mutation status facilitated improved risk stratification for patients exhibiting high-grade, non-muscle-invasive urothelial BC (5). However, studies of FGFR3 immunoreactivity and its clinical significance are uncommon (20,21). Immunohistochemical detection of the FGFR3 receptor may provide a simpler, cheaper and faster approach for histopathological practice, compared with the current method of determination of *FGFR3* mutation status. Overall, FGFR3 protein has significant potential for use as a diagnostic and prognostic marker, as well as a potential therapeutic target or screening tool (22).

In order to study the prognostic and diagnostic value of FGFR3 protein expression in urothelial BC, a large series of unselected primary urothelial BC tumours were analysed for FGFR3 immunoreactivity and *FGFR3* mutations in association with tumour stage, WHO 2004 grade, multifocality, presence of adjacent carcinoma *in situ* and patient outcome.

Patients and methods

Bladder cancer tissue microarray (TMA). As previously described (10), a TMA was generated using 255 consecutive, formalin-fixed, paraffin-embedded, primary urothelial BC tissue samples obtained from the Institute of Pathology, University of Regensburg (Regensburg, Germany). Clinical data were obtained from the Central Tumour Registry, Regensburg (Germany), and by telephone interviews when data could not be located. The Institutional Review Board of the University of Regensburg (Regensburg, Germany) approved the analysis of tissues from human subjects. Haematoxylin and eosin-stained slides of all tumour samples were evaluated by a single surgical pathologist (Dr Arndt Hartman). Tumour stages and grades were assigned according

to Union for International Cancer Control and WHO 2004 criteria (www.uicc.org/). The growth pattern was determined for all tumours classified as invasive (\geq pT1). Papillary growth was defined by the presence of a papillary tumour component (\geq 20%), possessing a histological grade identical to that of the invasive tumour. All other tumours were considered to possess a pattern of solid growth. Clinicopathological data are summarised in Table I. Retrospective clinical follow-up data were available regarding the end-points, defined as recurrence-free survival (RFS) and disease-specific survival (DSS), for all patients, and the median follow-up period was 75 months (range, 0-147 months). The median follow-up period for censored patients was 81 months. Recurrence was defined as the presence of cystoscopically visible tumours, and was further confirmed by histological verification. Data regarding progression-free survival (PFS) were not available.

Immunohistochemistry. Immunohistochemical analysis used an avidin-biotin peroxidase method with a diaminobenzidine chromogen. Following antigen retrieval (using a microwave oven at 250 W for 30 min), immunohistochemistry was performed using an automated NEXES immunostainer (Ventana Medical Systems, Inc., Tucson, AZ, USA) according to the manufacturer's instructions. The following primary antibody was used: anti-FGFR3 [rabbit monoclonal Immunoglobulin G, clone aa 359-372 (E10234); Spring Bioscience, Fremont, CA, USA; dilution 1:50]. FGFR3 immunoreactivity was scored as either negative or positive, irrespective of the staining intensity. Focal (partly positive stained urothelial tissue on the TMA section) or weak FGFR3 (positive but with reduced intensity) immunoreactivity was also considered to be positive.

***FGFR3* mutation analysis.** *FGFR3* mutation analysis was performed using the SNaPshot method as described previously (12,22), using the ABI PRISM SNaPshot Multiplex Kit (Applied Biosystems, Foster City, CA, USA). Three regions of the *FGFR3* gene, comprising all *FGFR3* mutations identified in BC (23), were simultaneously amplified in a multiplex polymerase chain reaction (PCR). Briefly, the multiplex PCR was performed in a volume of 15 μ l, containing 1X PCR buffer, 1.5 mmol/l MgCl₂, 0.5 U Taq polymerase (Promega Corporation, Madison, WI, USA), 0.17 mmol/l deoxynucleotide triphosphates (Roche Diagnostics, Basel, Switzerland), 10 pmol of exon 7 and exon 15 primers, 7.5 pmol of exon 10 primers (Invitrogen, Carlsbad, CA, USA), 5% glycerol (Fluka, Buchs SG, Switzerland), and 1-250 ng of genomic DNA. Cycling conditions were as follows: 5 min at 95°C, 35 cycles at 95°C for 45 sec, 60°C for 45 sec, and 72°C for 45 sec, followed by 10 min at 72°C. Following removal of excess primers and dNTPs, 8 SNaPshot primers for detection of 9 *FGFR3* mutations were annealed to the PCR products and extended using a labelled dideoxynucleotide. These extended primers were analysed using an ABI PRISM 3100 Genetic Analyzer automatic sequencer (Applied Biosystems, Foster City, CA, USA); the label attached to the incorporated nucleotide indicated the presence or absence of mutations. All mutations were verified using a second independent SNaPshot analysis.

Table I. Patient and tumour characteristics and results of molecular and immunohistochemical analyses.

Clinicopathological variable	Cases, n ^a (%)
Age at diagnosis, years ^b	
<70	141 (55.3)
≥70	114 (44.7)
Gender	
Female	64 (25.1)
Male	191 (74.9)
Tumour stage ^b	
PUNLMP	22 (8.6)
pTa	124 (48.6)
pT1	48 (18.8)
pT2	56 (22.0)
pT3	2 (0.8)
pT4	3 (1.2)
Histological grade ^c	
1	81 (31.8)
2	69 (27.1)
3	105 (41.2)
Histological grade ^d	
Low	150 (58.8)
High	105 (41.2)
Adjacent carcinoma <i>in situ</i>	
No	222 (87.1)
Yes	33 (12.9)
Multiplicity	
Solitary	53 (20.8)
Multifocal	202 (79.2)
Growth pattern	
Papillary	207 (81.5)
Solid	47 (18.5)
FGFR3 gene	
Wild-type	110 (52.9)
Mutation	98 (47.9)
FGFR3 immunohistochemistry	
Negative	94 (45.4)
Positive	113 (54.6)

^aOnly the initial biopsy of each patient is included. Total cases analysed, 255. ^bMedian, 68 years and range, 34-95 years. ^cStaging and grading according to the WHO 1973 classification system. ^dStaging and grading according to the WHO 2004 classification system. FGFR3, fibroblast growth factor receptor 3; PUNLMP, papillary urothelial neoplasia of low malignant potential. Certain cases were not analysed successfully due to insufficient material.

Statistical analysis. Statistical analyses were performed using the survival package in R version 3.0.3 (<http://www.r-project.org>) and SPSS version 22.0 (IBM SPSS, Armonk, NY, USA). $P < 0.05$ was considered to indicate a statistically significant difference. Associations between the measured parameters were obtained by applying two-sided χ^2 and Fisher's exact

tests. Non-parametric Kaplan-Meier estimators were used to analyse DSS. Point-wise bands at a confidence level of 0.95 were computed. Differences between survival estimates were evaluated using the Log-Rank test. Cox regression analysis was performed for the variables with regard to DSS. For the analysis of RFS, patients were censored when cystectomy was performed or at the time of their last tumour-free clinical follow-up appointment. For DSS analysis, patients were censored at their final tumour-free clinical follow-up appointment or at their date of mortality unrelated to the tumour.

Results

Positive FGFR3 immunoreactivity and FGFR3 mutations are associated with positive histopathological characteristics. FGFR3 staining of any intensity was classified as positive, and was observed in 113/207 patients. Positive staining was mainly present in pTa/pT1 tumours (64%; 89/140). In addition, activating mutations in the *FGFR3* gene were detected in 98/208 (47%) analysable BC tumours, of which 59% (83/140) were pTa and pT1 tumours.

Table II exhibits the associations between FGFR3 immunohistochemistry and various clinicopathological parameters. A positive FGFR3 staining pattern was largely observed in tumours classified as low-grade and stage pTa. In the low-grade tumour group, 69% of tumours were FGFR3 positive (Table II) and 74% carried *FGFR3* mutations (data not shown). Fig. 1A demonstrates a typical example of an FGFR3-negative invasive high-grade tumour, while Fig. 1B illustrates an example of an FGFR3 positive non-invasive low-grade tumour. In total, 69% of pTa lesions were positive for FGFR3, as demonstrated by immunostaining. Fig. 2A and B depict the significant association between tumour stage and grade, and FGFR3 immunoreactivity (both $P < 0.001$). Papillary non-invasive (pTa) and low-grade tumours were predominantly positive for FGFR3, as demonstrated by immunohistochemical analysis. There was a significant association between positive FGFR3 immunoreactivity and activating *FGFR3* mutations ($P < 0.001$; Fig. 2C).

Positive FGFR3 immunoreactivity was more frequent in tumours that did not possess adjacent carcinoma *in situ* ($P = 0.062$). Considering only those tumours with solid growth patterns, which are known to be associated with a worse prognosis (24), positive FGFR3 immunoreactivity was present in a minority of cases (25%; $P < 0.001$).

It was concluded that positive FGFR3 staining was associated with low tumour stage and grade, and with a papillary pattern of tumour growth (all $P < 0.001$). In a previous study (12), FGFR3 mutation status was observed to be associated with identical clinicopathological parameters such as positive FGFR3 staining in the present study.

FGFR3 is a prognostic biomarker for patients with BC. The end-points for the present study were RFS and DSS. Kaplan-Meier analyses for DSS are exhibited in Fig. 3A and B, and reveal that BC patients with positive FGFR3 staining had a significantly increased DSS compared with that of patients with negative FGFR3 staining ($P = 0.0018$). In a subgroup analysis for high-grade tumours, positive FGFR3

Table II. Comparison of FGFR3 immunoreactivity with clinicopathological and IHC parameters (n=207).

Clinicopathological variable	FGFR3 IHC staining pattern		P-value
	Negative, n	Positive, n	
Tumour stage ^a			<0.001 ^c
PUNLMP	6	8	
pTa	31	68	
pT1	20	21	
pT2	34	14	
pT3	0	2	
pT4	3	0	
Histological grade ^a			<0.001 ^c
1	23	35	
2	13	47	
3	58	31	
Histological grade ^b			<0.001 ^c
Low	36	82	
High	58	31	
Adjacent carcinoma <i>in situ</i> ^b			0.062
No	77	103	
Yes	17	10	
Multiplicity ^b			1.000
Solitary	20	25	
Multifocal	74	88	
Growth pattern ^{b,d}			<0.001 ^c
Papillary	63	103	
Solid	30	10	

^a χ^2 -test (two-sided); ^bFisher's exact test (two-sided). ^cA statistically significant difference. ^d One sample could not be evaluated for papillary or solid tumor growth. PUNLMP, papillary urothelial neoplasia of low malignant potential; FGFR3, fibroblast growth factor receptor 3; IHC, immunohistochemistry.

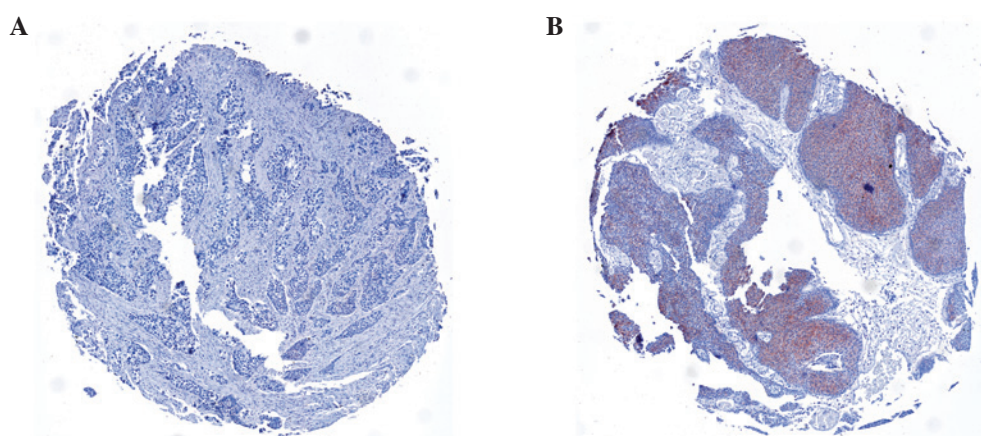


Figure 1. Immunohistochemical staining with FGFR3 antibody. (A) Representative image of negative FGFR3 staining in a high-grade invasive urothelial tumour. (B) Representative image of positive FGFR3 immunoreactivity in a low-grade non-invasive urothelial bladder cancer specimen. FGFR3, fibroblast growth factor receptor 3.

staining demonstrated a trend for improved prognosis (Fig. 3B), however this trend was not statistically significant (P=0.0991).

Fig. 3C summarises the results of the univariate survival analysis for DSS and indicates that positive FGFR3 staining is associated with longer DSS (hazard ratio, 0.35; 95%

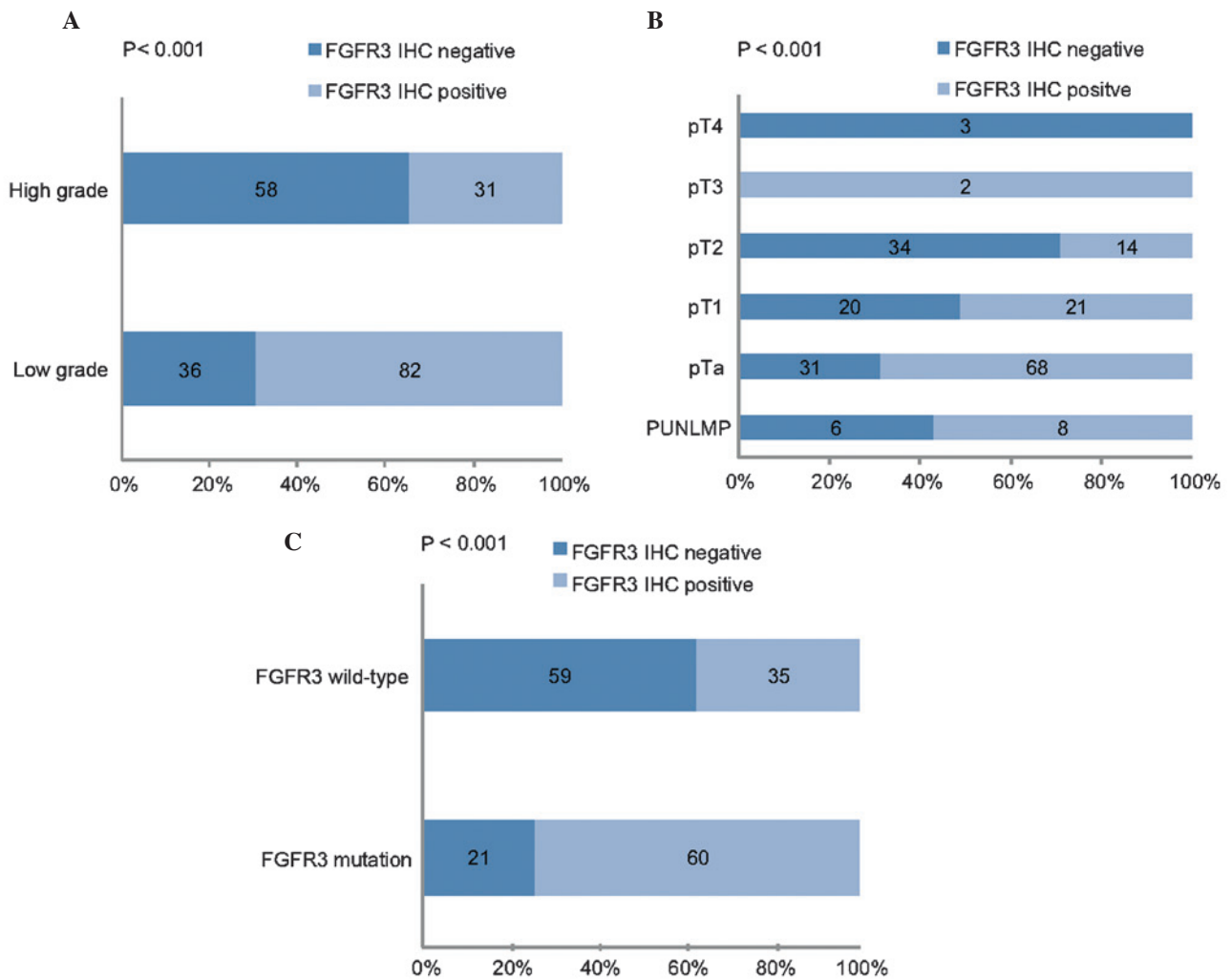


Figure 2. Comparison of FGFR3 staining intensity with (A) grade, (B) stage and (C) FGFR3 mutation of tumours. Frequency represents the percentage of tumours in a particular stage or grade. Dark blue bars represent FGFR3 negative staining and light blue bars represent FGFR3 positive staining. FGFR3, fibroblast growth factor receptor 3; IHC, immunohistochemistry; PUNLMP, papillary urothelial neoplasia of low malignant potential.

confidence interval, 0.18-0.70; $P=0.0030$). Multivariate Cox regression analysis revealed that FGFR3 immunoreactivity was not observed to be a significant parameter associated with DSS (data not shown). None of the investigated parameters demonstrated a correlation with RFS (data not shown).

Discussion

The present study aimed to investigate FGFR3 immunoreactivity as a potential prognostic biomarker and diagnostic tool in surgical pathology, for patients with BC. The results of the present study revealed that FGFR3 immunoreactivity of any intensity was markedly associated with a low tumour grade and stage, and longer DSS.

In the present study, increased protein expression was identified in 69% of pTa and 51% of pT1 tumours. This finding corresponds with the results of previous studies, which have previously investigated FGFR3 protein expression using immunohistochemistry, which have reported similar percentages of increased FGFR3 protein expression to those observed in the present study (18,19,23). Accordingly, the aforementioned studies identified a significant association between FGFR3 expression and tumour stage and grade.

By contrast, Matsumoto *et al* (25) identified no association between FGFR3 expression levels and pathological parameters, including grade and stage, potentially due to the low number of cases evaluated leading to a low statistical power ($n=126$).

Furthermore, the present study demonstrated a correlation between FGFR3 expression and *FGFR3* mutation. In the present study, 74% of tumours with positive FGFR3 expression demonstrated an *FGFR3* mutation. This association has additionally been verified using semi-quantitative reverse transcription-PCR, where FGFR3 messenger RNA expression was clearly associated with *FGFR3* mutation status (26). Similarly to the results of the present study, Tomlinson *et al* (18) demonstrated a significant association between FGFR3 expression levels and *FGFR3* mutation, as well as tumour grade and stage, respectively.

Previously, *FGFR3* mutation status has been demonstrated to be a marker for the prognosis of patients with BC (11,27,28). In the present study, the correlation between *FGFR3* mutations and tumours of low stage and grade was confirmed (9,11). Previous studies have investigated the use of FGFR3 expression as a predictor of prognosis in BC. While a number of authors were able to demonstrate a shorter RFS associated

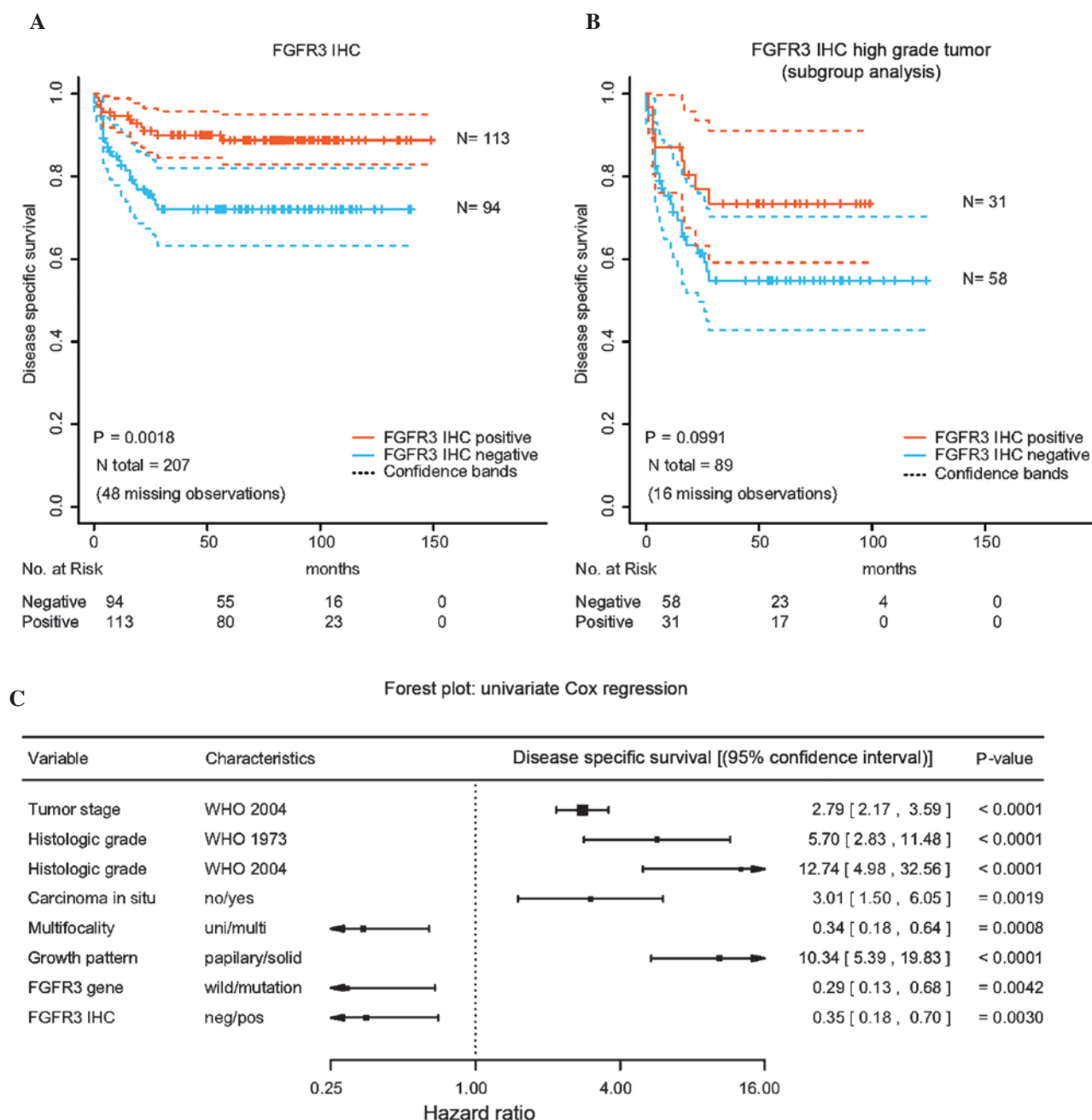


Figure 3. Kaplan-Meier survival plots with point-wise confidence bands (confidence level, 0.95) for disease-specific survival based on FGFR3 staining in (A) all (n=207) immunohistochemically analysable patients and in (B) a subgroup analysis (n=89) considering only high-grade tumours. Log-Rank tests were performed to test for equality in the survival expectation of each group. N-values represent the number of patients in each group. (C) A forest plot for the univariate Cox regression analysis of factors potentially affecting disease-specific survival of patients with urothelial bladder cancer. The dashed vertical line indicates the no effect point (a hazard ratio of 1.0). Horizontal lines represent 95% confidence intervals. The midpoint and the area of the box illustrate the mean effect estimate and the weight of each subgroup. FGFR3, fibroblast growth factor 3; IHC, immunohistochemistry; PUNLMP, papillary urothelial neoplasia of low malignant potential; WHO, world health organisation; uni/multi, solitary/multifocal; neg/pos, negative/positive.

with FGFR3 expression (20,29), Gudjonsson *et al* (21) did not identify any difference in time to recurrence. In general, the role of molecular markers for predicting BC recurrence appears to be limited, as reviewed by van Rhijn (30). Even the *FGFR3* mutation, which facilitates selective identification of non-muscle-invasive BC with good prognosis, did not predict recurrence in two studies investigating >200 patients, alone or in combination with other molecular markers (5,11). Therefore, it was not noteworthy that the present study was unable to predict recurrence using *FGFR3* mutation or expression.

To best of our knowledge, the present study is the first report of an association between FGFR3 protein expression and DSS. The present study demonstrated that in addition to *FGFR3* mutation, FGFR3 protein expression was able to predict longer DSS in patients with BC. However, FGFR3 protein expression did not remain an independent predictor of worse DSS following multivariate analysis.

FGFR3 mutation has been proven to be capable of predicting prognosis in several previous studies. Tomlinson *et al* (18), described the association between

FGFR3 mutation and protein expression levels, and identified a marked association between *FGFR3* protein expression and tumour grade and stage. However, data on progression and DSS were not presented. Bodoor *et al* (31) studied *FGFR3* protein expression and disease course and identified no association between *FGFR3* expression and overall survival, although data on DSS was not available. However, two recent studies reported no association between *FGFR3* protein expression and prognosis. Guancial *et al* (32) and Turo *et al* (33) investigated *FGFR3* protein expression in muscle-invasive BC and identified no association with overall survival. Guancial *et al* (32) investigated *FGFR3* protein expression in 231 primary invasive BCs, while Turo *et al* (33) studied *FGFR3* protein expression in 150 invasive BCs. Guancial *et al* (32) found *FGFR3* mutations in just 2% of all tumours, whereas Turo *et al* (33) did not investigate *FGFR3* mutation status.

In the present study it was revealed that *FGFR3* protein expression was increased in tumours of lower stage and grade. Consequently, *FGFR3* protein expression was associated with improved outcomes, as grading and staging are significant, well-known pathological predictors for disease progression in BC.

A significant limitation of the present study was that a major end-point for BC, PFS, was not able to be assessed in this cohort. *FGFR3* protein expression was not an independent marker, but was markedly influenced by the pathological parameters, stage and grade for the prediction of disease course. However, *FGFR3* protein expression has the potential to serve as an additional molecular marker, alongside tumour grading and staging, in the prediction of prognosis.

FGFR3 mutation analysis using the SNaPshot method has not been implemented in routine practice, due to the high associated costs and complexity. By contrast, *FGFR3* immunohistochemistry appears to be more convenient and feasible for use on a routine basis. Analysis of *FGFR3* protein expression may provide a tool for use in the assessment of the prognosis of patients exhibiting BC. The present study proposes to use *FGFR3* immunoreactivity as an additional diagnostic measure for grading in difficult cases, to better differentiate between low- and high-grade urothelial lesions.

The prognosis of non-muscle-invasive BC relies on clinicopathological variables to predict outcomes. The present study revealed that the *FGFR3* receptor is a significant, but not independent, marker for DSS of BC patients. The present study concluded that *FGFR3* protein expression and mutant *FGFR3* may provide prognostic information for non-invasive BC, and may aid pathologists with appropriate grading in difficult cases. In addition, loss of *FGFR3* expression may identify a subgroup of high-grade tumours with worse prognoses. Further prospective studies evaluating all end-points are required to confirm these data.

Acknowledgements

The authors would like to thank Rudolf Jung (Institute of Pathology, University of Erlangen, Erlangen, Germany), Martina Storz, Silvia Behnke, Susanne Dettwiler, and Andre Fitsche (All Institute of Surgical Pathology, University Hospital Zurich, University of Zurich, Zurich, Switzerland) for excellent technical assistance and Armin Pauer (Central

Tumor Registry, Regensburg, Germany) for help in obtaining the clinical data.

References

1. Heney NM: Natural history of superficial bladder cancer. Prognostic features and long-term disease course. *Urol Clin North Am* 19: 429-433, 1992.
2. Hall MC, Chang SS, Dalbagni G, Pruthi RS, Seigne JD, Skinner EC, Wolf JS Jr and Schellhammer PF: Guideline for the management of nonmuscle invasive bladder cancer (stages Ta, T1, and Tis): 2007 update. *J Urol* 178: 2314-2330, 2007.
3. Eble J, Sauter G, Epstein JI, Sesterhenn IA (eds): World Health Organization Classification of Tumours. Pathology and Genetics of Tumours of the Urinary System and Male Genital Organs. IARC Press, Lyon, 2004.
4. Wu XR. Urothelial tumorigenesis: A tale of divergent pathways. *Nat Rev Cancer* 5: 713-725, 2005.
5. Burger M, van der Aa MN, van Oers JM, Brinkmann A, van der Kwast TH, Steyerberg EC, Stoehr R, Kirkels WJ, Denzinger S, Wild PJ, *et al*: Prediction of progression of non-muscle-invasive bladder cancer by WHO 1973 and 2004 grading and by *FGFR3* mutation status: A prospective study. *Eur Urol* 54: 835-843, 2008.
6. Turner N and Grose R: Fibroblast growth factor signalling: From development to cancer. *Nat Rev Cancer* 10: 116-129, 2010.
7. Dieci MV1, Arnedos M, Andre F and Soria JC: Fibroblast growth factor receptor inhibitors as a cancer treatment: From a biologic rationale to medical perspectives. *Cancer Discov* 3: 264-279, 2013.
8. Cappellen D, De Oliveira C, Ricol D, de Medina S, Bourdin J, Sastre-Garau X, Chopin D, Thiery JP and Radvanyi F: Frequent activating mutations of *FGFR3* in human bladder and cervix carcinomas. *Nat Genet* 23: 18-20, 1999.
9. Billerey C, Chopin D, Aubriot-Lorton MH, Ricol D, Gil Diez de Medina S, Van Rhijn B, Bralet MP, Lefrere-Belda MA, Lahaye JB, Abbou CC, *et al*: Frequent *FGFR3* mutations in papillary non-invasive bladder (pTa) tumors. *Am J Pathol* 158: 1955-1959, 2001.
10. van Rhijn BW, Montironi R, Zwarthoff EC, Jöbsis AC and van der Kwast TH: Frequent *FGFR3* mutations in urothelial papilloma. *J Pathol* 198: 245-251, 2002.
11. van Rhijn BW, Vis AN, van der Kwast TH, Kirkels WJ, Radvanyi F, Ooms EC, Chopin D, Boevé ER, Jöbsis AC and Zwarthoff EC: Molecular grading of urothelial cell carcinoma with fibroblast growth factor receptor 3 and MIB-1 is superior to pathologic grade for the prediction of clinical outcome. *J Clin Oncol* 21: 1912-1921, 2003.
12. van Oers JM, Wild PJ, Burger M, Denzinger S, Stoehr R, Roskopf E, Hofstaedter F, Steyerberg EW, Klinkhammer-Schalke M, Zwarthoff EC, *et al*: *FGFR3* mutations and a normal CK20 staining pattern define low-grade noninvasive urothelial bladder tumours. *Eur Urol* 52: 760-768, 2007.
13. Hernández S, López-Knowles E, Lloreta J, Kogevinas M, Jaramillo R, Amorós A, Tardón A, García-Closas R, Serra C, Carrato A, *et al*: *FGFR3* and *TP53* mutations in T1G3 transitional bladder carcinomas: Independent distribution and lack of association with prognosis. *Clin Cancer Res* 11: 5444-5450, 2005.
14. Zieger K, Dyrskjøt L, Wiuf C, Jensen JL, Anderson CL, Jensen KM and Ørntoft TF: Role of activating fibroblast growth factor receptor 3 mutations in the development of bladder tumors. *Clin Cancer Res* 11: 7709-7719, 2005.
15. van Rhijn BW, van der Kwast TH, Liu L, Fleshner NE, Bostrom PJ, Vis AN, Alkhateeb SS, Bangma CH, Jewett MA, Zwarthoff EC, *et al*: The *FGFR3* mutation is related to favorable pT1 bladder cancer. *J Urol* 187: 310-314, 2012.
16. van Rhijn BW, van der Kwast TH, Vis AN, Kirkels WJ, Boevé ER, Jöbsis AC and Zwarthoff EC: *FGFR3* and *P53* characterize alternative genetic pathways in the pathogenesis of urothelial cell carcinoma. *Cancer Res* 64: 1911-1914, 2004.
17. Bakkar AA, Wallerand H, Radvanyi F, Lahaye JB, Pissard S, Lecerf L, Kouyoumdjian JC, Abbou CC, Pignon JC, Jaurand MC, *et al*: *FGFR3* and *TP53* gene mutations define two distinct pathways in urothelial cell carcinoma of the bladder. *Cancer Res* 63: 8108-8112, 2003.
18. Tomlinson DC, Baldo O, Harnden P and Knowles MA: *FGFR3* protein expression and its relationship to mutation status and prognostic variables in bladder cancer. *J Pathol* 213: 91-98, 2007.

19. Mhaweck-Fauceglia P, Cheney RT, Fischer G, Beck A and Herrmann FR: FGFR3 and p53 protein expressions in patients with pTa and pT1 urothelial bladder cancer. *Eur J Surg Oncol* 32: 231-237, 2006.
20. Maeng YH, Eun SY and Huh JS: Expression of fibroblast growth factor receptor 3 in the recurrence of non-muscle-invasive urothelial carcinoma of the bladder. *Korean J Urol* 51: 94-100, 2010.
21. Gudjónsson S, Bendahl PO, Chebil G, Höglund M, Lindgren D, Lundberg LM, Lövgren K, Fernö M, Månsson W and Liedberg F: Can tissue microarray-based analysis of protein expression predict recurrence of stage Ta bladder cancer? *Scand J Urol Nephrol* 45: 270-277, 2011.
22. di Martino E, Tomlinson DC and Knowles MA: A decade of FGF receptor research in bladder cancer: Past, present, and future challenges. *Adv Urol* 2012: 429213, 2012.
23. Gómez-Román JJ, Saenz P, Molina M, Cuevas González J, Escuredo K, Santa Cruz S, Junquera C, Simón L, Martínez A, Gutiérrez Baños JL, *et al*: Fibroblast growth factor receptor 3 is overexpressed in urinary tract carcinomas and modulates the neoplastic cell growth. *Clin Cancer Res* 11(2 Pt 1): 459-465, 2005.
24. Poyet C, Jentsch B, Hermanns T, Schweckendiek D, Seifert HH, Schmidpeter M, Sulser T, Moch H, Wild PJ, Kristiansen G: Expression of histone deacetylases 1, 2 and 3 in urothelial bladder cancer. *BMC Clin Pathol* 14: 10, 2014.
25. Matsumoto M, Ohtsuki Y, Ochiai K, Seike Y, Iseda N, Sasaki T, Okada Y, Kurabayashi A and Furihata M: Fibroblast growth factor receptor 3 protein expression in urothelial carcinoma of the urinary bladder, exhibiting no association with low-grade and/or non-invasive lesions. *Oncol Rep* 12: 967-971, 2004.
26. Bernard-Pierrot I, Brams A, Dunois-Lardé C, Caillaud A, Diez de Medina SG, Cappellen D, Graff G, Thiery JP, Chopin D, Ricol D and Radanyi F: Oncogenic properties of the mutated forms of fibroblast growth factor receptor 3b. *Carcinogenesis* 27: 740-747, 2006.
27. Lopez-Beltran A, Luque RJ, Alvarez-Kindelan J, Quintero A, Merlo F, Requena MJ and Montironi R: Prognostic factors in survival of patients with stage Ta and T1 bladder urothelial tumors: The role of G1-S modulators (p53, p21Waf1, p27Kip1, cyclin D1, and cyclin D3), proliferation index, and clinicopathologic parameters. *Am J Clin Pathol* 122: 444-452, 2004.
28. Hernández S, López-Knowles E, Lloreta J, Kogevinas M, Amorós A, Tardón A, Carrato A, Serra C, Malats N and Real FX: Prospective study of FGFR3 mutations as a prognostic factor in nonmuscle invasive urothelial bladder carcinomas. *J Clin Oncol* 24: 3664-3671, 2006.
29. Barbisan F, Santinelli A, Mazzucchelli R, Lopez-Beltran A, Cheng L, Scarpelli M, van der Kwast T and Montironi R: Strong immunohistochemical expression of fibroblast growth factor receptor 3, superficial staining pattern of cytokeratin 20, and low proliferative activity define those papillary urothelial neoplasms of low malignant potential that do not recur. *Cancer* 112: 636-644, 2008.
30. van Rhijn BW: Combining molecular and pathologic data to prognosticate non-muscle-invasive bladder cancer. *Urol Oncol* 30: 518-523, 2012.
31. Bodoor K, Ghabkari A, Jaradat Z, Alkhateeb A, Jaradat S, Al-Ghazo MA, Matalka I, Musleh H and Haddad Y: FGFR3 mutational status and protein expression in patients with bladder cancer in a Jordanian population. *Cancer Epidemiol* 34: 724-732, 2010.
32. Guancial EA, Werner L, Bellmunt J, Bamias A, Choueiri TK, Ross R, Schutz FA, Park RS, O'Brien RJ, Hirsch MS, *et al*: FGFR3 expression in primary and metastatic urothelial carcinoma of the bladder. *Cancer Med* 3: 835-844, 2014.
33. Turo R, Harnden P, Thygesen H, Fleischmann A, Thalmann GN, Seiler R, Cross WR and Knowles MA: FGFR3 expression in primary invasive bladder cancers and matched lymph node metastases. *J Urol* 193: 325-330, 2015.